

Subacute Sclerosing Panencephalitis: Evaluation with CT and MR

Jan Brismar, Generoso G. Gascon, Kristina Vult von Steyern, and Saeed Bohlega

PURPOSE: To evaluate the progression of CT and MR changes of the brain in subacute sclerosing panencephalitis (SSPE) as a basis for assessing the effects of different types of therapy. **METHODS:** Fifty-two patients with SSPE were examined, 44 with MR imaging and 42 with CT of the brain on one or more occasions. A total of 92 MR and 67 CT studies were performed. **RESULTS:** Correlation between the clinical status and the MR findings on admission was poor. Of 20 patients with clinically advanced disease, only 8 had marked MR abnormalities; 6 had normal or almost normal findings on MR examinations. Two of 4 patients with clinically mild disease had advanced MR changes. The progression of the MR findings appeared to follow a constant pattern. The earliest pathologic finding was focal, high-T2-intensity white matter changes; later atrophic changes followed. The atrophy lagged behind the white matter changes and was thus mild when white matter changes were moderate or severe. In the most advanced stage, when the patient was in a neurovegetative state, an almost total loss of white matter had usually taken place. At this stage, the corpus callosum was also thin. Basal ganglia changes, usually involving the putamina, were seen in one third of patients and cortical gray matter changes were seen in one fourth of patients examined with MR imaging. In 2 of 20 patients, MR changes regressed in parallel with clinical improvement following therapy, but in 5 patients clinical improvement was accompanied by progression of MR changes. **CONCLUSION:** The progress of MR abnormalities seen in patients with SSPE seems to follow a constant pattern, but the severity of MR changes does not always correlate well with the clinical findings. Caution must therefore be used when evaluating the effects of therapy.

Index terms: Brain, computed tomography; Brain, magnetic resonance; Encephalitis

AJNR Am J Neuroradiol 17:761-772, April 1996

Subacute sclerosing panencephalitis (SSPE) is an invariably fatal neurodegenerative disease, developing as a sequel to early childhood measles infection. Following the original measles infection, the virus becomes altered and remains dormant intracellularly, only to manifest as SSPE a decade or so later. The disease was originally described by Dawson in 1933 (1), and a major review article in 1964 (2) reported only 30 patients in North America. Increased aware-

ness led to the identification of more cases, and in 1980, 575 cases were registered in the United States (3). Measles vaccination has now all but eradicated the disease in developed countries, but SSPE is still endemic in many developing countries, where measles vaccination in early infancy has not yet reached the World Health Organization's goal of greater than 80% coverage. The disease also is of interest as a model for persistent viral infection of the brain. The histopathologic manifestations in the brain are indistinguishable from those of acquired immunodeficiency syndrome (AIDS) and from those seen in parainfectious and postinfectious encephalomyelitis (4).

The purpose of this study of 52 patients was to determine the time course for the development of neuroradiologic findings and to chart the distribution of lesions in order to establish a basis for the evaluation of possible effects of different types of therapy.

Received May 23, 1995; accepted after revision October 16.

From the Departments of Radiology (J.B., K.V.v.S.), Pediatrics (G.G.G.), and Medicine (S.B.), King Faisal Specialist Hospital and Research Centre, Riyadh, Saudi Arabia.

Address reprint requests to Jan Brismar, MD, PhD, Department of Radiology, MBC 28, King Faisal Specialist Hospital and Research Centre, PO Box 3354, Riyadh 11211, Saudi Arabia.

AJNR 17:761-772, Apr 1996 0195-6108/96/1704-0761

© American Society of Neuroradiology

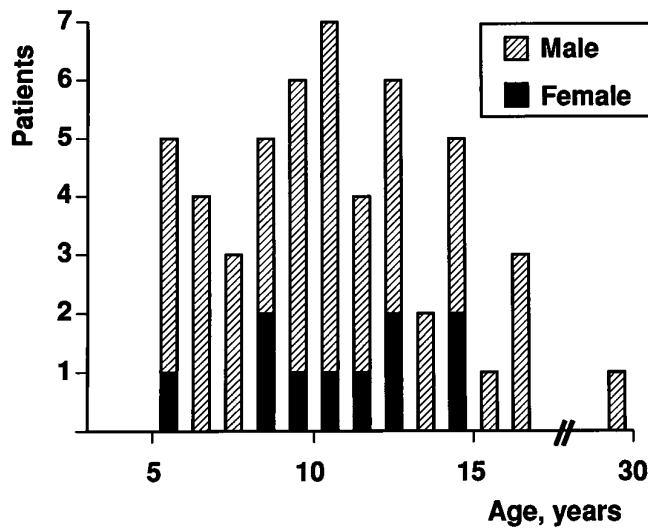


Fig 1. Sex and age of 52 patients with SSPE at initial CT or MR study.

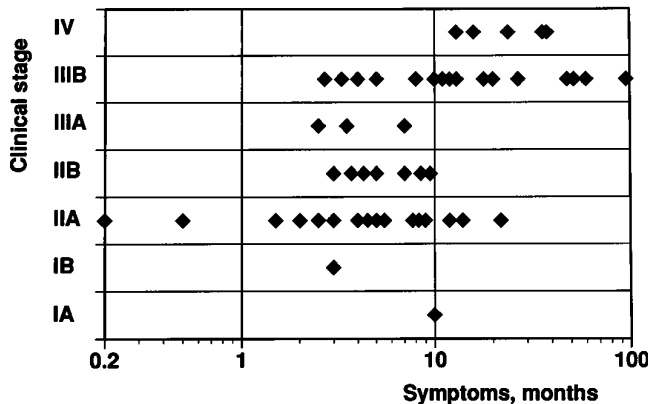


Fig 2. Clinical stage and duration of signs and symptoms at initial CT or MR study in 49 patients with SSPE (information was not available in 3 of a total of 52 patients). Note logarithmic time scale.

Subjects and Methods

During the last 8 years, we examined the brains of 52 patients with SSPE using magnetic resonance (MR) imaging and/or computed tomography (CT). Forty-two of the patients were male and 10 were female. The findings in 21 of these patients have been reported previously (5); the interpretation of the imaging findings in these patients has since been revised and a different scheme for clinical staging has been used. The age of the patients and the duration of their symptoms at the time of the initial CT or MR study are given in Figures 1 and 2. The age at the time of the original measles infection was known in only a few patients. All patients fulfilled generally accepted criteria for the diagnosis of SSPE (6) (ie, elevated serum and cere-

Two schemes for the clinical staging of subacute sclerosing panencephalitis (SSPE)

SSPE stages according to Jabbour

- J:I. Cerebral signs (mental, behavioral)
- J:II. Convulsive motor signs, myoclonus, incoordination, choreoathetosis, tremors
- J:III. Coma, opisthotonus, decerebrate rigidity; no responsiveness to any stimulus
- J:IV. Mutism, loss of cerebral cortex function, less frequent myoclonus, diminished hypertonia

SSPE stages according to Gascon

- G:IA. Behavioral, cognitive, and personality changes, walking
- G:IB. Aperiodic, myoclonic spasms
- G:IIA. Further mental deterioration, periodic generalized myoclonic spasms, possibly no walking because of drop spells
- G:IIB. Language difficulties, spasticity, ataxia, walking with assistance
- G:IIIA. Speaking less, visual difficulties; sitting up independently, possible standing, but no independent ambulation; frequent myoclonic spasms, possible seizures
- G:IIIB. No speech, poor comprehension, possible blindness, confinement to bed, dysphagia, possible need of tubal feeding, possible choreoathetosis
- G:IV. Neurovegetative stage, no spasms, very low background EEG activity

Note.—Gascon stage IA and IB are both included in Jabbour stage I; Gascon stage IIA, IIB, and IIIA are all included in Jabbour stage II; Gascon stage III B approximately equals Jabbour stage III; and Gascon stage IV approximately equals Jabbour stage IV.

brospinal fluid [CSF] antimeasles antibody titers and two of the following four criteria: typical clinical presentation, typical electroencephalographic [EEG] pattern, IgG in CSF greater than 20% of total protein, and typical findings on brain biopsy specimens). No brain biopsy was performed in this series. Information on the clinical stage of the disease (as defined in the Table) at presentation was available in 49 patients and appears in Figure 2. In the "Discussion," the clinical stages suggested by Jabbour et al (6) will be denoted as J:I to J:IV; the stages identified in our series (7) are designated G:I to G:IV. The relationship between the 2 clinical staging schemes is presented in the Table.

For the CT studies, 10-mm-thick contiguous sections were obtained. For contrast enhancement, iopromide, 2 mL/kg of body weight, was used. The MR studies were performed on a 1.5-T scanner using T1-weighted, 600–700/20/2 (repetition time/echo time/excitations), and dual-echo T2-weighted, 1800–2000/30–40,80/1–2, axial sections with 0- to 2.5-mm section gaps (depending on head size) and sagittal T1-weighted images. Gadopentetate dimeglumine, 0.2 mL/kg of body weight, was given in one patient. The CT and MR studies were evaluated retrospectively for enlargement of the CSF spaces and for white matter changes, and graded subjectively in a nonblinded manner as absent (0), mild (+), moderate (++), or marked/severe (+++).

In total, 92 MR examinations were performed in 44 patients and 67 CT examinations were performed in 42 patients. Contrast medium was used in 41 CT examinations (27 patients) and in one MR study. In 25 patients, CT and MR studies were performed less than a week apart.

Results

The radiologic findings in our series included atrophy, white matter changes (ie, lesions of high T2 intensity and low CT attenuation), gray matter changes (high T2 and decreased T1 intensity), and basal ganglia involvement. Radiologic staging of SSPE was as follows:

- stage 0: no atrophy or white matter changes
- stage 1: (+) white matter changes *or* atrophy
- stage 2: (+) white matter changes *and* atrophy
- stage 3: (++) white matter changes, 0 to + atrophy, or vice versa
- stage 4: (++) white matter changes *and* atrophy
- stage 5: (+++) white matter changes, 0 to ++ atrophy, or vice versa
- stage 6: (+++) white matter changes *and* atrophy

The results from radiologic staging using CT information as compared with MR information was evaluated in 25 patients who were examined with both techniques within 1 week. As expected, a marked understaging was achieved when CT examinations were used to stage the disease, mainly because white matter changes are difficult to see on CT scans. Thus, the radiologic staging was thereafter based on MR results alone (ie, MR stage). Enhancement following administration of contrast medium was never observed.

The severity of atrophy was correlated with the severity of white matter changes—both graded as 0, +, ++, or +++—as determined from all 92 MR studies. In 49 studies the atrophy and white matter changes were graded as being of equal severity. In only 3 studies (2 patients) did the atrophy seem slightly more pronounced than the white matter changes, whereas in 30 studies the white matter changes appeared worse than the atrophy. In 9 studies with marked white matter changes no atrophy was seen.

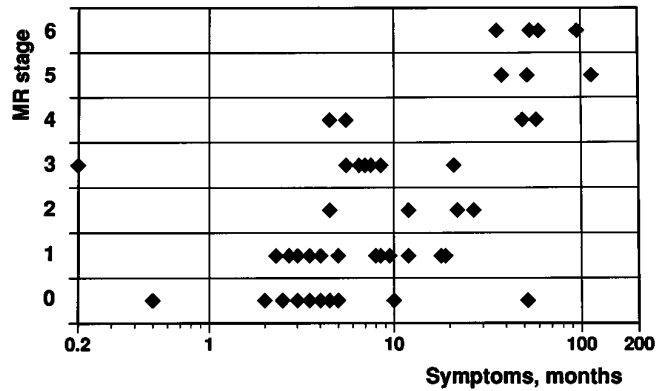


Fig 3. MR stage at the initial MR study in 44 patients with SSPE in relation to duration of symptoms (logarithmic scale).

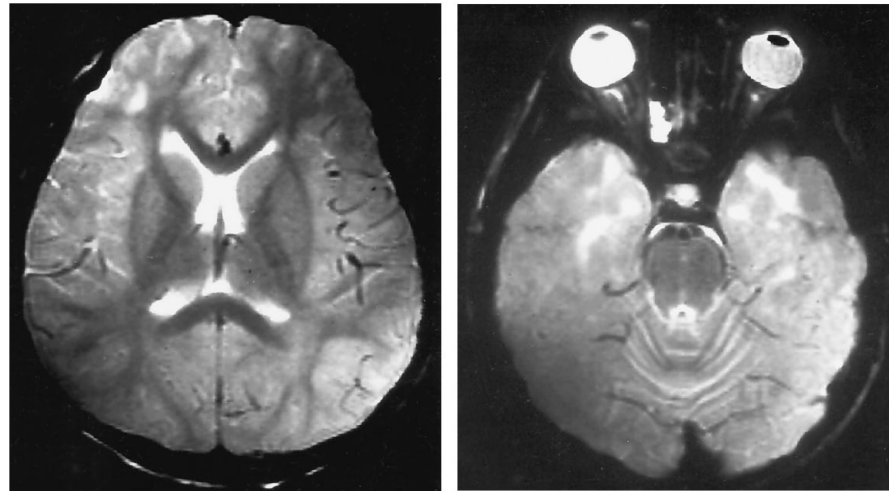
MR stage	IA	IB	IIA	IIB	IIIA	IIIB	IV
6						2	2
5		1				1	1
4		1			1	1	1
3			3	1	1	2	
2			2			2	
1			5	4		2	1
0	1	1	3	2	2	1	

Fig 4. Correlation between clinical stage and MR stage at the first MR study in 44 patients with SSPE.

Figure 3 plots the correlation between the initial MR stage and the duration of the symptoms. Although, as expected, there was a correlation between the duration of the disease and the MR stage, large variations did appear. Thus, one patient with only a 1-week history of symptoms already had moderate white matter changes, whereas another child with more than 4 years' history of symptoms still had normal MR findings.

The correlation between the clinical stage and the severity of the MR changes was also quite weak (Fig 4). Thus, several patients with severe clinical findings (stages G:IIIA, G:IIIB, or even G:IV) still had normal or almost normal MR findings (Fig 5). On the other hand, in two patients with mild clinical disease, the MR findings were markedly abnormal (Fig 6).

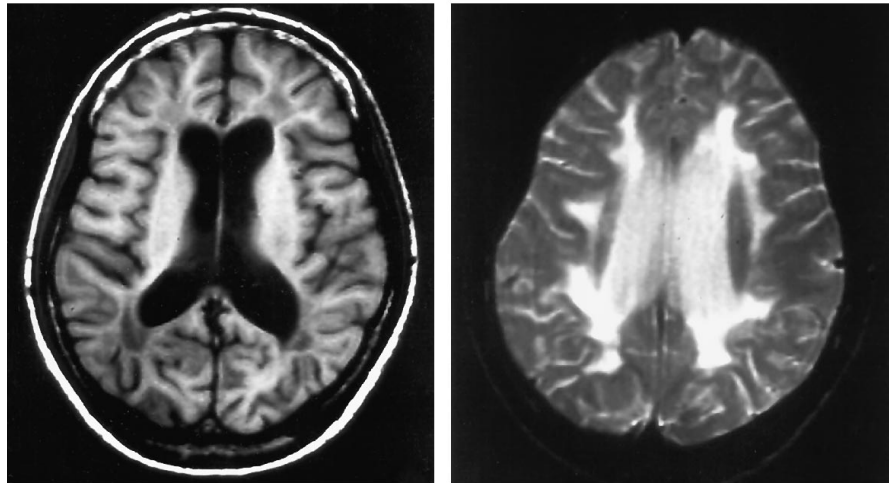
Fig 5. A 13-year-old boy with an 18-month history of SSPE, clinical stage G:IV. Despite the advanced disease, T2-weighted MR images (2000/80/2) show no atrophy and only mild white matter changes (MR stage 1). (Decreased signal over right posterior and left anterior part of the brain in both images is due to coil properties.)



A

B

Fig 6. A 14-year-old boy with a 52-month history of SSPE, clinical stage G:IB (3 years after this MR study the patient is still in clinical stage G:IB). Axial T1-weighted (600/20/2) and T2-weighted (2000/80/2) MR images show marked atrophy and moderately advanced white matter changes (MR stage 5). Corpus callosum was thin (not shown).



A

B

Cortical gray matter was involved in 11 of the 44 patients examined by MR imaging (Figs 7–9) (involvement was also seen in one patient studied only by CT). In 3 of the patients studied by MR imaging, the changes were minor; they were moderate in 7 and severe in 1. In 1 of these patients, the pons was also swollen and of high T2 intensity (Fig 7); in a second patient, high-T2-intensity lesions were seen in the left thalamus (Fig 8). In an additional patient with normal-appearing cortical gray matter, severe high-T2-intensity changes were present within the pons, brain stem, and cerebral peduncles. The gray matter changes were present on the initial MR study in 4 patients; in 8 patients gray matter changes developed between MR studies (Figs 7 and 9). No obvious correlation was

found between presence of gray matter changes and either the duration of the disease or the severity of other MR changes, but gray matter was usually affected only in patients with clinically advanced disease. Thus, in 3 of 4 patients with gray matter changes initially and in 6 of 8 patients in whom gray matter lesions developed during follow up, the disease was classified as stage G:III or G:IV.

The basal ganglia were involved in 18 patients, including 15 of 44 patients who were examined with MR imaging (Figs 10 and 11). Although evenly distributed among the different MR stages, and not correlated with the length of the clinical history, basal ganglia changes were seen mainly in patients with clinical stage G:IIIA disease or higher. Thus, all but 3 of 11 patients

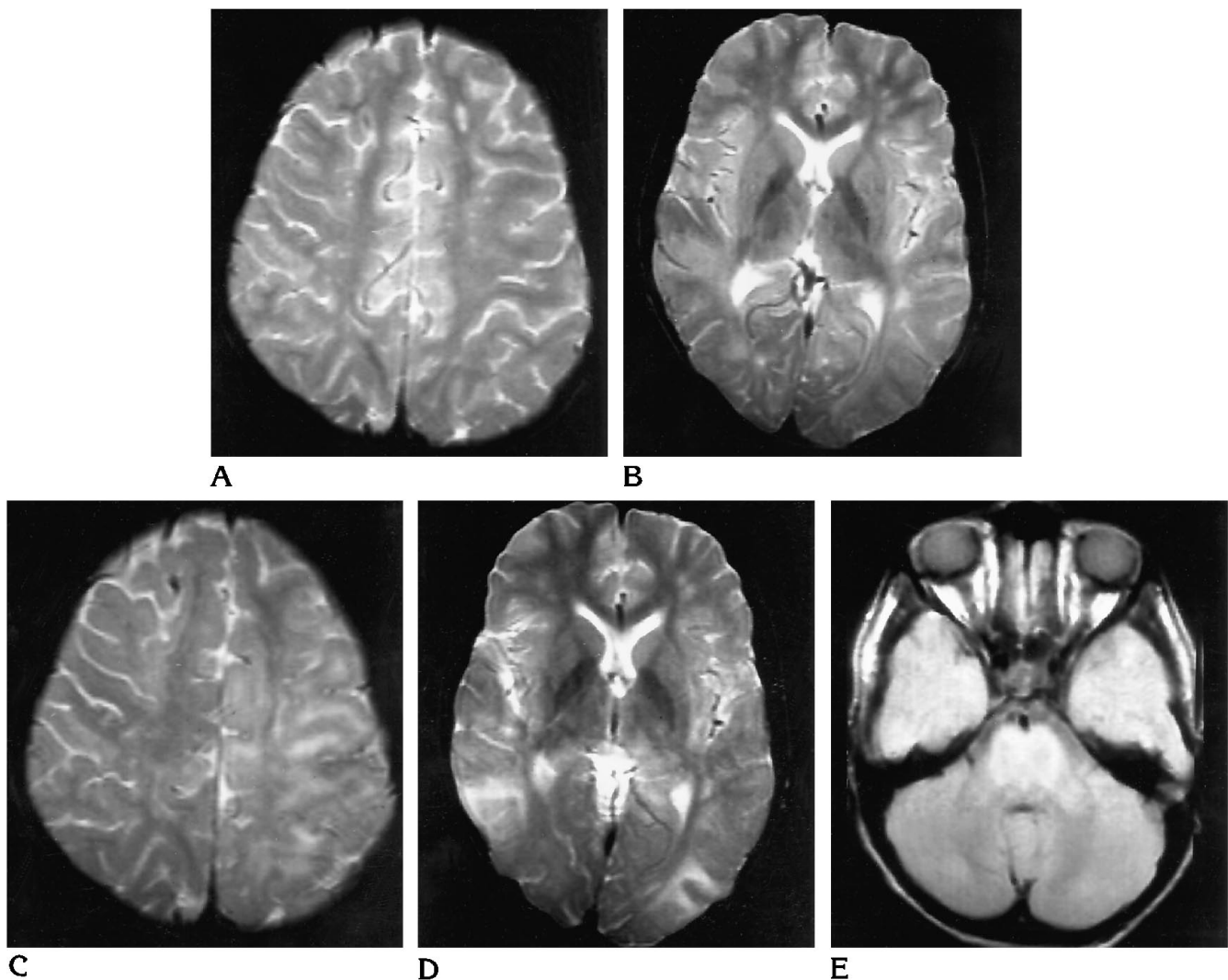


Fig 7. An 8-year-old boy with a 3-month history of SSPE, clinical stage G:IIA.
 A and B, T2-weighted (2000/80/2) MR images on admission show only mild focal high-T2-intensity subcortical white matter changes. The pons appeared normal (not illustrated). Interferon alfa combination therapy was started (MR stage 1).
 C and D, Three months later, the clinical status had progressed to stage G:IIIA. T2-weighted (2000/80/1) MR images show cortical gray matter changes and progression of the subcortical white matter changes (MR stage 3). (Hypointensity in right frontal region is caused by the ventricular catheter.)
 E, Proton density-weighted (2000/40/1) MR image obtained at same examination shows quite pronounced high-intensity changes involving the pons.

who had basal ganglia changes at the initial study were classified as having stage G:III disease or higher; all 7 patients in whom white matter changes developed during follow up had stage G:III or G:IV disease when the lesions were detected.

Discussion

SSPE is a dramatic disease, starting as minor disturbances in behavior in a previously entirely

healthy child. Myoclonic attacks then develop and become increasingly more frequent, dementia follows, and within months or a few years the child is comatose, void of higher brain functions. Neuronal and glial viral cell inclusions, subacute inflammatory changes, subacute demyelination, and extensive gliosis are characteristic pathohistologic features (3). It is now known that the disease is linked to a measles infection in early childhood.

The average age of onset of SSPE has been

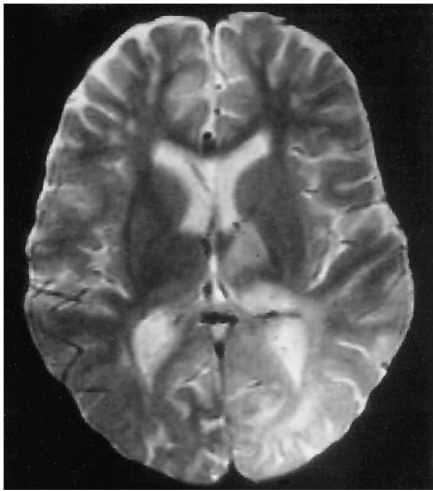


Fig 8. A 9-year-old boy with a 5-month history of SSPE, clinical stage G:IIA. An MR study obtained at admission (not shown) revealed only mild focal subcortical high-T2 white matter changes. Four months later, with the patient at clinical stage G:IIIB, T2-weighted (2000/80/1) MR image shows progress of high-intensity white matter changes, slight atrophy (MR stage 3), and extensive gray matter changes involving the left temporal (not shown) and parietooccipital regions. High T2 signal changes were also present in the left thalamus.

reported to vary from 9 to 13 years (3, 8); in our series it was 9 years. More than 90% of our patients were between 4 and 14 years old at the onset of symptoms, which is similar to other reports (8). Information about the date of the preceding measles infection was available for only a few of our patients. Other investigators have had such information available in 65% to 75% of cases (3, 8); in those series the average age at infection was between 2 and 3 years and the interval from the measles infection to the onset of SSPE symptoms averaged from 8 to 11 years.

It is still not known how the measles virus manages to survive clinically dormant for many years and why it becomes active again and causes SSPE. Possibly the immature immune system fails to destroy the virus completely, and the partially degraded virus remains in the central nervous system (CNS) (3, 9). Perhaps a simultaneous infection with another virus, such as Epstein-Barr virus, parainfluenza type 1 virus, or toxoplasmosis, might be involved in changing the properties of the measles virus (9) into those of a slow virus. Virus mutations may alter the surface antigen of the virus and thereby make it invisible to the immune response while it at the same time retaining the ability to reproduce and spread from cell to cell (10). Perhaps

nonproductive, cell-associated forms of the measles virus occur naturally during a measles infection but are kept passive by the hosts' defense mechanisms, such as interferon. If suppression then fails, for instance from development of viral forms less sensitive to interferon or from a too low production of interferon, the virus may reproduce and spread within the CNS, causing SSPE (11). This hypothesis receives some support from the finding that intraventricular interferon seems to induce a clinical improvement, or at least it temporarily arrests the disease in more than half the cases (7, 11, 12).

The initial symptoms of SSPE are usually behavioral changes, such as irritability, impaired school performance, disobedience, inappropriate affection, and withdrawal. These symptoms may be ongoing for several years (13), and may be recognized only in retrospect. Myoclonic spasms then appear, often seen as drop attacks. These are initially sporadic but may later occur at intervals of only a few seconds, and will eventually prevent the patient from ambulating. The mental deterioration progresses, and a characteristic EEG pattern develops with generalized brief, bilaterally synchronous bursts of spike-wave and/or slow-wave complexes. Spasticity and ataxia become prominent and may later be followed by choreoathetosis. Language difficulties progress, patients speak less and have poor verbal comprehension; visual problems may proceed to cortical blindness. Seizures follow; the patient becomes bedridden, and may need tubal feeding. The spasticity progresses to opisthotonus and the patient lapses into a coma. Terminally, the muscular hypertonia decreases, myoclonus disappears, and the patient passes into a neurovegetative state and eventually dies (2, 6, 8, 14).

Several different staging schemes have been suggested (2, 6, 13, 15) with different numbers of intermediate stages between the first stage, which includes only behavioral symptoms and perhaps mild myoclonic attacks, and the final stage of neurovegetation. The clinical staging system used to classify disease in our patients (Table) (7) was slightly modified from previously published schemes (2, 6) to separate the middle stages better.

In a few patients, positron emission tomography was performed (16–19). In one patient with rapidly progressing SSPE, the glucose metabolism of the cortical gray matter was markedly reduced; in a patient with slowly developing

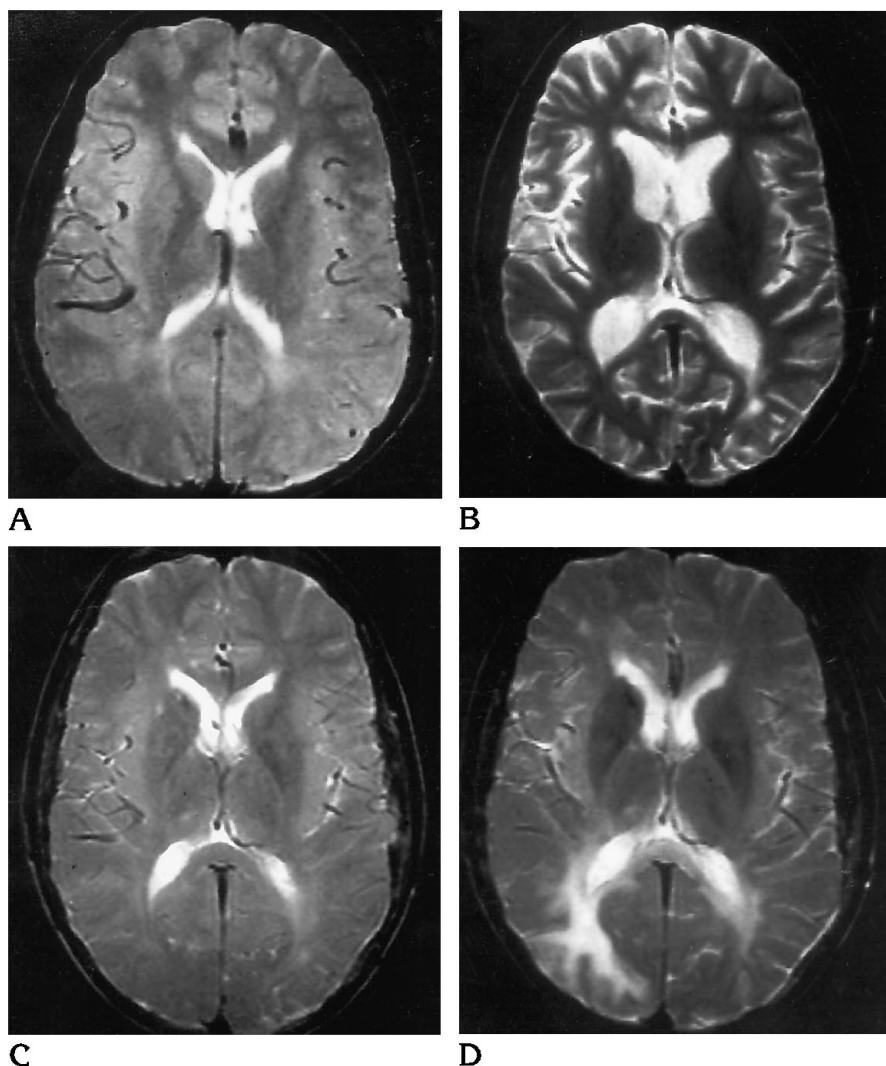


Fig 9. An 11-year-old boy with 9-month history of SSPE, clinical stage G:IIb.

A, T2-weighted (1800/80/2) MR image obtained at admission is normal except for mild focal high-T2 white matter changes (MR stage 1).

B, Seventeen months later, when the patient is still in stage G:IIb, T2-weighted (2000/80/2) MR image shows progressive atrophy (MR stage 3). Interferon alfa combination therapy was started after this study.

C, Sixteen months later, there was clinical improvement to stage G:IA. T2-weighted (2000/80/1) MR image also shows improvement, with only mild white matter changes apparent (MR stage 1).

D, Ten months later, the patient has progressed to clinical stage G:IIa. T2-weighted (2000/80/1) MR image shows an increase in subcortical white matter changes, involvement of the posterior limb of the internal capsule bilaterally, and gray matter changes in the right occipital lobe (MR stage 3).

disease, the PET findings were normal (16). One boy with stage J:II disease showed luxury perfusion in the anterior half of the cerebrum and a decrease in cerebral blood flow and oxygen metabolism in the right frontal watershed zone, where CT scans showed a low-density lesion. In another boy with stage J:III disease, a marked decrease of oxygen metabolism and cerebral blood flow was found in all regions except the occipital lobe (18). Huber et al (17, 19) hypothesized, on the basis of their results from seven PET studies in four patients and on previously reported results (16, 18), that inflammation with hypermetabolism in the basal ganglia inhibits the connection between frontal, temporal, and parietal areas, thus causing the symptoms of stage J:II. When the basal ganglia later become defective, the inhibition decreases and cortical activity increases. When the dis-

ease eventually progresses to involve midline structures and the brain stem, hypermetabolism in these structures causes decline of cortical functions and impairment of consciousness, which progress to decerebrate rigidity and stage J:III disease.

The time course of SSPE is variable (Figs 2, 9, 12). In 1969 a review of 274 published cases (2) concluded that only 31% of patients survived for more than 1 year after onset of symptoms, and that only 7 of 274 showed a remission. In contrast, in a large series of 118 cases from the Middle East, noteworthy improvements and plateaus occurred in more than half the patients (13), and in 6 patients substantial spontaneous long-term improvement took place (8, 20); in all 6 cases, previously bedridden patients, incapable of self-care, became ambulatory and were able to tend to their basic

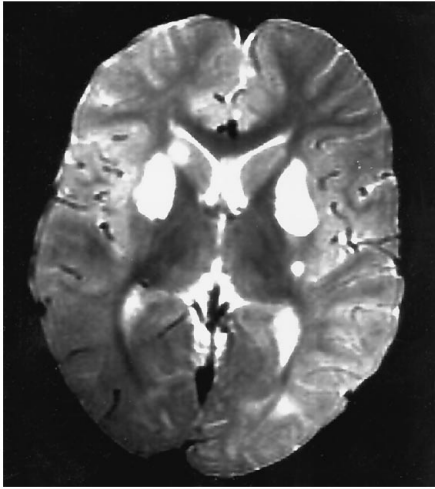


Fig 10. An 8-year-old boy with a 3-month history of SSPE, clinical stage G:IIIB. T2-weighted (2000/80/2) MR image at admission shows extensive high-intensity lesions in lentiform nuclei bilaterally and in right caudate head, and minimal subcortical white matter lesions (MR stage 1). A repeat MR study (not shown) after 7 months showed atrophy and high T2 intensity of lentiform nuclei and caudate heads but was otherwise unchanged.

needs. Similar cases of spontaneous long-term improvement (21–23) and of patients surviving for more than 10 years after diagnosis (like one of our patients) have been reported (20, 24–26). This variation in the natural course of the disease makes it difficult to evaluate the effects of therapy in small series (2, 27).

The uniformity of the mode of clinical progress in SSPE suggests a constant pattern of involvement of the CNS. Neuropathologic findings suggest that the disease initially affects the occipital regions of the cortex, progresses to the anterior parts of the cerebrum, and finally spreads to involve the subcortical structures, brain stem, and spinal cord (28). Involvement of cortical gray matter should then be responsible for the nonspecific symptoms of stage J:I. Others have claimed that an intact cerebral cortex is required to explain the appearance of the characteristic EEG changes in stage J:II disease (29); these EEG changes could then be triggered from affected centers in the brain stem and reach the cortex through intact pathways. This would be consistent with the normal findings of cortical biopsies seen early in the disease (28). Few patients (only one in our series) have been examined with MR imaging at this stage, and early gray matter changes have not been reported (the early gray matter involvement could of course be on a biochemical level, and not depictable with MR imaging).

In the next stage of the disease (J:II or G:IB), at the onset of myoclonic spasms, CT in 3 of 3 children showed abnormally small lateral ventricles (30). This finding was supported in a series of 15 patients (31) in which cerebral edema and diffuse low-attenuation white matter was found in 6 of 8 patients with J:II disease, but has been refuted in other reports (24, 32, 33). Thus, 7 patients examined during the first 4 months after onset of symptoms all had normal CT findings, without any sign of brain swelling (32); no evidence of brain swelling was found in any of 5 patients studied during the first year after onset of SSPE (only 1 of these patients was studied during the first 6 months) (24). In our series, none of 21 patients who were examined within 6 months of onset of symptoms (19 with MR imaging) showed signs of brain swelling.

Later subcortical white matter is involved with lesions identical to those of other slow virus infections of the brain, such as subacute AIDS encephalomyelitis. Immune complexes deposited in the walls of cerebral blood vessels are believed to cause damage to the blood brain barrier. The leakage of fluid and lymphocytes creates a perivascular edema and inflammation and is followed by demyelination (4). Radiologic evidence of barrier lesions has been documented in a few reports (24, 27, 34). One patient with rapidly progressing disease showed signs of acute white matter inflammation with multiple areas of contrast enhancement (24). Contrast enhancement has also been shown during an acute relapse of the disease (27). In two patients, contrast-enhanced CT scans showed normal findings, whereas radionuclide brain scans showed multiple lesions. The authors concluded that the latter technique was superior in detecting acute SSPE (34). No enhancement was observed in our series.

An alternative hypothesis would be that SSPE is primarily a subcortical disease. The whole clinical picture fits better with what neurologists would call a subcortical dementia (like Huntington disease, Parkinson disease, and so on) rather than a cortical dementia (like Alzheimer disease). The early MR changes primarily involve white matter and are more subcortical-occipital than frontal (Figs 7 and 9). It may be that the oligodendroglia (responsible for forming the myelin in the CNS) are first affected and then subsequently the basal ganglia and brain stem neurons. The myoclonic spasms are a brain stem myoclonus and occur early (stage

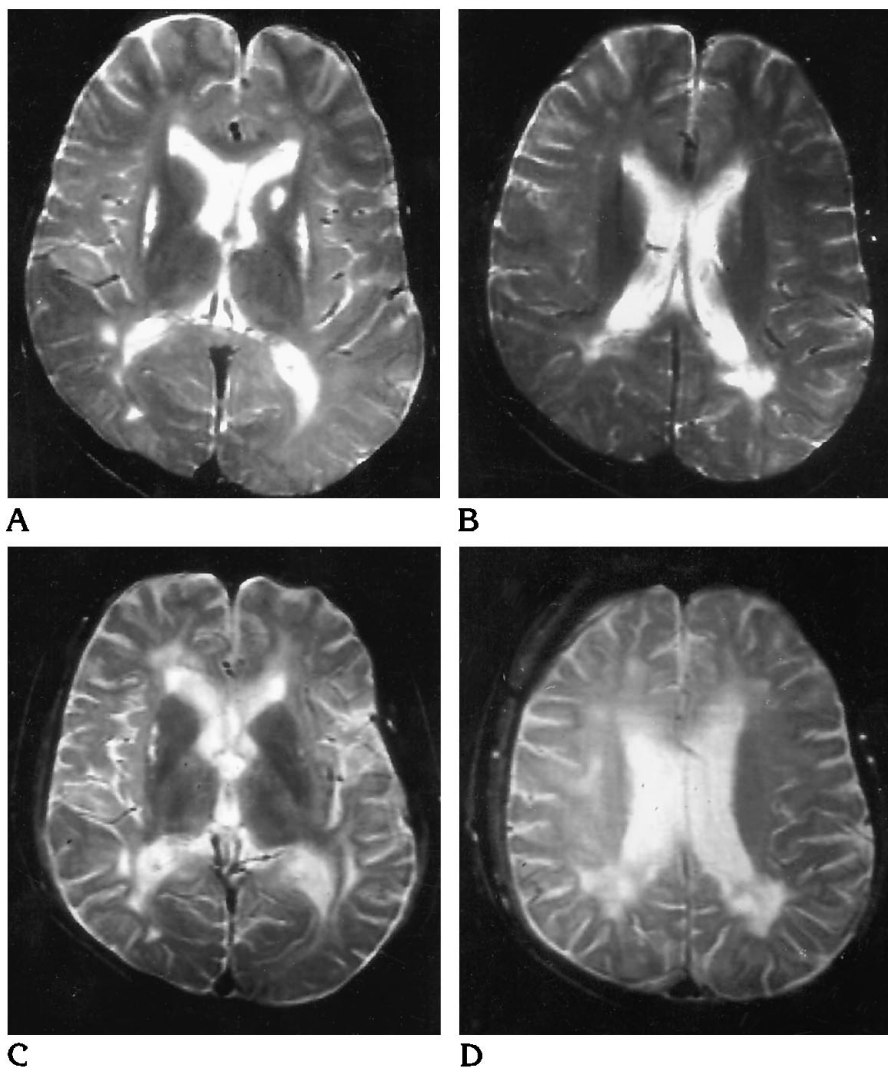


Fig 11. A 15-year-old boy with a 22-month history of SSPE, clinical stage G:IIIA.

A and B, Initial T2-weighted (2000/80/2) MR images show minimal prominence of sulci, mild white matter changes (MR stage 2), slitlike high-intensity putamina, and a high-intensity lesion in the left caudate head.

C and D, Twenty months later, after 13 months of interferon alfa combination therapy and clinical improvement to stage G:IA, T2-weighted (2000/80/1) MR images show progression of both atrophy and white matter changes (MR stage 3).

G:IB or G:IIA); the cortical atrophy occurs late. Most early behavioral changes can be explained by subcortical white matter involvement of associated areas (apraxia, agnosia) and brain stem reticular (thalamocortical) mechanisms (attention and concentration difficulties).

As the disease progresses, there is an increasing loss of white matter, and atrophy becomes a more prominent feature (24, 35, 36) (Fig 12). CT findings are often negative until this late stage. Thus, in a series of 76 patients, only 22 had abnormal CT findings (37): CT findings were normal in 25 of 33 patients with stage J:III disease, in 26 of 40 patients with stage J:II disease, and in all 3 patients with stage J:I disease. In another series, 11 of 14 patients (1 stage J:I, 9 stage J:II, and 1 stage

J:III) initially had normal CT findings (27). In the final stage of SSPE, most white matter is lost, the ventricles and extracerebral CSF spaces are severely widened, the corpus callosum is very thin, and posterior fossa structures are markedly atrophic (Fig 13).

Reported experiences with MR imaging in SSPE are limited (9, 25, 33, 38–44). MR imaging has major advantages in demonstrating white matter changes in SSPE (25, 33, 38, 39, 42). This was obvious from our comparison of the results of CT and MR examinations performed less than 1 week apart in 25 patients. In 11 of these patients, white matter changes were seen only on MR images.

On the initial MR study (Fig 3), all but 11 of our 44 patients had white matter changes. In 22

Fig 12. A 12-year-old boy with a 5-month history of SSPE, clinical stage G:IIIB.

A, CT scan at admission was normal, but 2 weeks later, a CT scan (not shown) revealed marked gray and white matter changes.

B, Three months later (clinical stage G:IV), there is further progression, with severe loss of brain tissue.

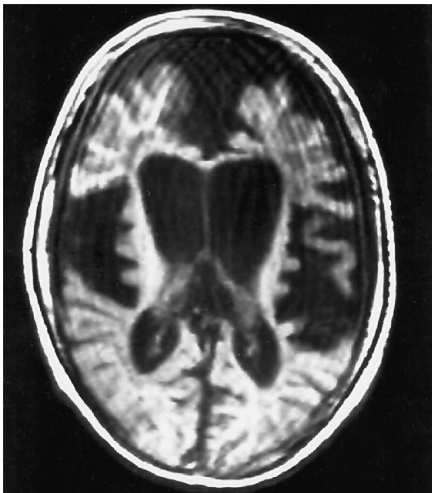
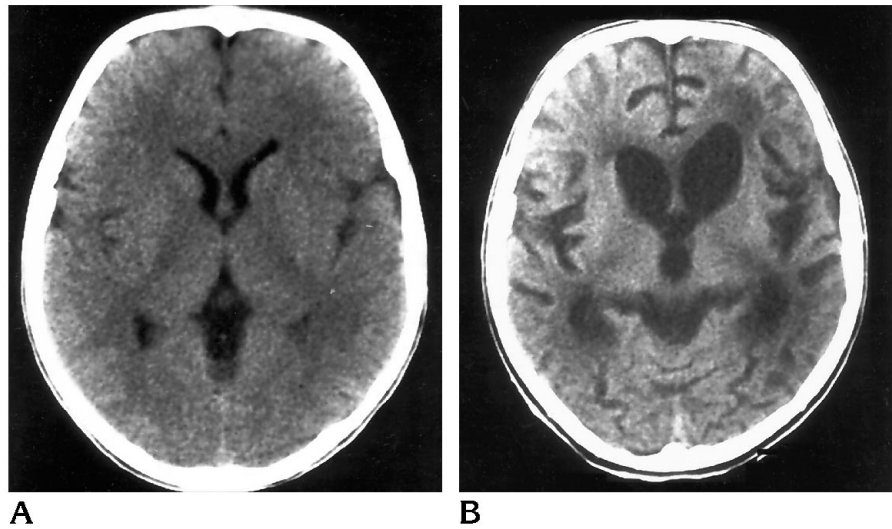


Fig 13. A 5-year-old boy with a 10-month history of SSPE, clinical stage G:IIIB. A CT scan at admission (not shown) revealed moderate atrophy and white matter changes. This T1-weighted (700/20/2) MR image obtained 44 months later shows severe loss of brain tissue (MR stage 6).

examinations with mild to moderate white matter changes, no atrophy was seen. In only 3 examinations (in 2 patients) was the atrophy more striking than the white matter disease.

In most patients the gray matter still appears normal on MR images, even in the most advanced clinical and MR stages; thus, in our series, signal intensity changes within the gray matter were seen in only 8 of 23 patients who were followed up with MR imaging to stage G:IIIB or G:IV disease. The gray matter lesions were not correlated with the severity of white matter changes or with atrophy (Figs 7 and 9). In 2 of our patients, central gray matter structures were involved; in 1 in addition to cortical

gray matter (Fig 7) and in the second the cortical gray matter appeared normal but extensive changes were found in the brain stem and pons. Similar findings have previously been reported. One patient with J:II disease seen 3 months after onset of symptoms had normal CT findings while MR showed extensive increased-T2-intensity white matter lesions involving the supratentorial white matter, the cerebellum, and the pons (42). Six months later these white matter changes had markedly improved and the posterior fossa changes had normalized, but putaminal lesions had developed.

Basal ganglia lesions are not infrequent in SSPE, and were eventually seen in 18 of our 52 patients. Such lesions were already present on the initial imaging study in 11 patients. They were not related to the severity of other MR changes (39, 41) (Figs 10 and 11), but occurred predominantly in patients whose disease was of longer duration and more clinically advanced.

The correlation between the clinical stage of SSPE disease and the MR findings is often poor (33, 43). Thus, patients bedridden with severe disease may still have normal findings at MR examinations (Fig 9). Improvement of MR findings despite progress of the disease has also been reported (44, 45). In several of our patients, different treatment regimens were tried; in later years this included combined oral isoprinosine-intraventricular interferon alfa therapy (7). In 8 of 20 patients on this latter regimen an arrest of disease or even an improvement of the clinical status was seen. In 2 patients this improvement was associated with a slight but

clear temporary improvement in the MR findings (Fig 9). In 1 patient the MR findings remained unchanged, in 5 patients the clinical improvement was accompanied by a progression of MR abnormalities (Fig 11), and in another 2 patients a slight improvement of MR findings was accompanied by clinical impairment. In view of the large variability in the natural course of SSPE, the results of therapy must therefore be considered questionable. It is most likely that, in order to alter significantly the course of the disease, therapy must be initiated at an early stage. Presently, the diagnosis of SSPE is usually not made until major, permanent brain damage has taken place. An increased awareness of the possibility of SSPE as the cause of behavioral changes in a patient with normal findings on CT or MR examinations of the brain is probably one of many prerequisites for better therapeutic results. It is hoped that an increased use of measles vaccine in developing countries will eventually decrease the risk of SSPE.

References

- Dawson JR Jr. Cellular inclusions in cerebral lesions of lethargic encephalitis. *Arch Neurol Psychiatry* 1934;31:685-700
- Freeman JM. The clinical spectrum and early diagnosis of Dawson's encephalitis: with preliminary notes on treatment. *J Pediatr* 1969;75:590-603
- Dyken PR. Subacute sclerosing panencephalitis: current status. *Neurol Clin* 1985;3:179-196
- Poser CM. Notes on the pathogenesis of subacute sclerosing panencephalitis. *J Neurol Sci* 1990;95:219-224
- Bohlega S, Al-Kawi MZ. Subacute sclerosing panencephalitis: imaging and clinical correlation. *J Neuroimag* 1994;4:71-76
- Jabbour JT, Garcia JH, Lemmi H, et al. Subacute sclerosing panencephalitis: a multidisciplinary study of eight cases. *JAMA* 1969;207:2248-2254
- Gascon G, Yamani S, Crowell J, et al. Combined oral isoprinosine-intraventricular α -interferon therapy for subacute sclerosing panencephalitis. *Brain Dev (Tokyo)* 1993;15:346-355
- Haddad FS, Risk WS, Jabbour JT. Subacute sclerosing panencephalitis in the Middle East: report of 99 cases. *Ann Neurol* 1977;1:211-217
- Case records of the Massachusetts General Hospital: weekly clinicopathological exercises. *N Eng J Med* 1986;314:1689-1700. Case 25-1986
- Cattaneo R, Schmid A, Rebmann G, et al. Accumulated measles virus mutations in a case of subacute sclerosing panencephalitis: interrupted matrix protein reading frame and transcription alteration. *Virology* 1986;154:97-107
- Carrigan DR, Kabacoff CM. Identification of a nonreproductive, cell-associated form of measles virus by its resistance to inhibition by recombinant human interferon. *J Virol* 1987;61:1919-1926
- Yalaz K, Anlar B, Oktem F, et al. Intraventricular interferon and oral inosiplex in the treatment of subacute sclerosing panencephalitis. *Neurology* 1992;42:488-491
- Risk WS, Haddad FS. The variable natural history of subacute sclerosing panencephalitis: a study of 118 cases from the Middle East. *Arch Neurol* 1979;36:610-614
- Chao D. Subacute inclusion body encephalitis: report of 3 cases. *J Pediatr* 1962;61:501-510
- Foley J, Williams D. Incussion encephalitis and its relation to subacute sclerosing-leuco-encephalitis. *Q J Med* 1953;22:157-194
- Yanai K, Iinuma K, Tada K, et al. Regional cerebral metabolic rate for glucose in subacute sclerosing panencephalitis. *Eur J Pediatr* 1987;146:288-289
- Huber M, Herholz K, Pawlik G, Szeliess B, Jürgens R, Heiss W-D. Cerebral glucose metabolism in the course of subacute sclerosing panencephalitis. *Arch Neurol* 1989;46:97-100
- Yoshikawa H, Fueki N, Yoneyama H, Ogawa M, Sakuragawa N. Positron emission tomography demonstrated localized luxury perfusion in subacute sclerosing panencephalitis. *J Child Neurol* 1990;5:311-315
- Huber M, Pawlik G, Bamborschke S, et al. Changing pattern of glucose metabolism during the course of subacute sclerosing panencephalitis as measured with ^{18}F FDG-positron-emission tomography. *J Neurol* 1992;239:157-161
- Risk WS, Haddad FS, Chemali R. Substantial long-term improvement in subacute sclerosing panencephalitis: six cases from the Middle East and a review of the literature. *Arch Neurol* 1978;35:494-502
- Resnick JS, Engel WK, Sever JL. Subacute sclerosing panencephalitis: spontaneous improvement in a patient with elevated measles antibody in blood and spinal fluid. *N Engl J Med* 1968;279:126-129
- Cobb WA, Marshall J, Scaravilli F. Long survival in subacute sclerosing panencephalitis. *J Neurol Neurosurg Psychiatry* 1984;47:176-183
- Furby A, Vallée L, Rosseaux M, Nuyts JP, Destée A. Rémissions prolongées dans la panécephalite sclérosante subaiguë: 2 cas. *Rev Neurol (Paris)* 1990;146:191-195
- Krawiecki NS, Dyken PR, Gammal T, DuRant RH, Swift A. Computed tomography in subacute sclerosing panencephalitis. *Ann Neurol* 1984;15:489-493
- Lum GB, Williams JP, Dyken PR, et al. Magnetic resonance and CT imaging correlated with clinical status in SSPE. *Pediatr Neurol* 1986;2:75-79
- Boucebci M, Boucheffa A, Abbad D, Taright F. Panécephalite sclérosante subaiguë. A propos de 8 cas dont 1 évoluant depuis 13 ans. *Encephale* 1987;13:279-284
- Mahdi AH, Familusi JB. Subacute sclerosing panencephalitis in Riyadh, Saudi Arabia. *Ann Trop Med* 1992;12:95-104
- Ohya T, Martinez AJ, Jabbour JT, Lemmi H, Duenas DA. Subacute sclerosing panencephalitis: correlation of clinical, neurophysiologic and neuropathologic findings. *Neurology* 1974;24:211-218
- Cobb W. The periodic events of subacute sclerosing panencephalitis. *Electroencephalogr Clin Neurophysiol* 1966;21:278-294
- Pedersen H, Wulff CH. Computed tomographic findings of early subacute sclerosing panencephalitis. *Neuroradiology* 1982;23:31-32
- Jayakumar PN, Taly AB, Arya BYT, Nagaraj D. Computed tomography in subacute sclerosing panencephalitis: report of 15 cases. *Acta Neurol Scand* 1988;77:328-330
- Begeer JH, Haaxma R, Snoek JW, Boonstra S, le Coultre R. Signs of focal posterior cerebral abnormality in early subacute sclerosing panencephalitis. *Ann Neurol* 1986;19:200-202

33. Miller DH, Robb SA, Ormerod IEC, et al. Magnetic resonance imaging of inflammatory and demyelinating white-matter diseases of childhood. *Dev Med Child Neurol* 1990;32:97-107
34. Dodson WE, Prensley AL, Siegel BA. Radionuclide imaging in subacute sclerosing panencephalitis. *Neurology* 1979;29:749-752
35. Duda EE, Huttenlocher PR, Patronas NJ. CT of subacute sclerosing panencephalitis. *AJNR Am J Neuroradiol* 1980;1:35-38
36. Manabe Y, Ono Y, Okuno T, et al. Serial CT scans in subacute sclerosing panencephalitis. *Comput Tomogr* 1981;5:25-30
37. Anlar B, Yalaz K, Ustacelebi S. Symptômes et signes cliniques, données du laboratoire dans 80 cas de panencéphalite sclérosante subaiguë. *Rev Neurol (Paris)* 1988;144:829-832
38. Takemoto K, Koizumi Y, Kogame S, et al. Magnetic resonance imaging of subacute sclerosing panencephalitis. *Jpn J Clin Radiol* 1986;31:999-1004
39. Murata R, Matsuoka O, Nakajima S, et al. Serial magnetic resonance imaging in subacute sclerosing panencephalitis. *Jpn J Psychiatr Neurol* 1987;41:277-282
40. Geller TJ, Vern BA, Sarwar M. Focal MRI findings in early SSPE. *Pediatr Neurol* 1987;3:310-312
41. Woodward KG, Weinberg PE, Lipton HL. Basal ganglia involvement in subacute sclerosing panencephalitis: CT and MR demonstration. *J Comput Assist Tomogr* 1988;12:489-451
42. Tsuchiya K, Yamauchi T, Furui S. MR imaging vs CT in subacute sclerosing panencephalitis. *AJNR Am J Neuroradiol* 1988;9:943-946
43. Dietrich RB, Vining EP, Taira RK, Hall TR, Phillipart M. Myelin disorders of childhood: correlation of MR findings and severity of neurological impairment. *J Comput Assist Tomogr* 1990;14:693-698
44. Winer JB, Pires M, Kermode A, Ginsberg L, Rossor M. Resolving MRI abnormalities with progression of subacute sclerosing panencephalitis. *Neuroradiology* 1991;33:178-180
45. Noetzel MJ, Dodson WE. Progressive CT abnormalities despite clinical improvement in SSPE treated with inosiplex. *Ann Neurol* 1983;13:457-460