
Use of Large-Caliber Coronary Guiding Catheters for Neurointerventional Applications

Christopher M. Putman and John C. Chaloupka

Summary: The use of certain large-caliber (ie, 7F to 9F) coronary guiding catheters for selected neuroendovascular procedures is described in the context of surveying recently developed neurovascular guiding catheters. These large-caliber guiding catheters have proved useful in situations requiring proximal access to tortuous brachiocephalic arteries, permitting coaxial delivery of relatively large neurointerventional devices, such as most detachable balloons and 5F percutaneous transluminal angioplasty catheters. These large-caliber coronary guiding catheters have some important advantages over both old and new neurovascular guiding catheters, including favorably pre-shaped configurations and superior torque control. These features permit relatively easy direct selective catheterization of unfavorable vascular anatomy resulting from dolichoectasia of the aortic arch and great vessels.

Index term: Catheters and catheterization, instruments

Although it is not mandatory to do so, many neuroendovascular therapeutic techniques are optimally performed by initially placing a guiding catheter into either the carotid or vertebral artery to permit coaxial delivery of various microcatheter systems into more distal vasculature (1, 2). When using either 0.018-in or 0.010-in microcatheter systems, any diagnostic catheter that will accept a 0.038-in guidewire can be used as a guiding catheter.

However, in situations requiring coaxial delivery of either detachable balloons or 5F percutaneous transluminal angioplasty catheters, a larger-caliber guiding catheter in the range of 7F to 10F is required. A variety of such guiding catheters has been available for such applications (Table 1). Not infrequently, however, positioning such guiding catheters by either direct selective catheterization or catheter exchange over a long guidewire can be either extremely challenging or time-consuming (if not occasionally impossible) owing to unfavorable ge-

ometry produced by dolichoectasia of the aortic arch and great vessels.

Recently, several vendors have been manufacturing a new generation of stiffer, preformed guiding catheters for neuroendovascular applications that tend to have large inner lumen diameters and are variably available in the size range of 5F to 9F (Table 1). Currently, several varieties of these smaller sized guiding catheters (ie, 5F and 6F) are available, and they have dramatically enhanced the ability to gain distal purchase into the internal carotid and vertebral arteries for coaxial delivery of many commonly used neuroendovascular devices. However, despite their larger inner lumen diameters, these smaller catheters are not large enough for use with many detachable balloons with percutaneous transluminal angioplasty (PTA) catheters.

Thus, there remains a need for larger diameter guiding catheters for use in neuroendovascular procedures. In contrast to the new smaller sized guiding catheters, there remains a paucity of new-generation larger guiding catheters (ie, 7F to 8F). Furthermore, the few such catheters that are currently available have the same problems as their older counterparts when used to attempt catheterization of dolichoectatic brachiocephalic vasculature.

It has been our recent experience that certain large-caliber coronary guiding catheters that are commercially available can be used to directly select brachiocephalic vessels with surprising technical ease. These catheters have favorable physical characteristics that make them quite compatible with some commonly used neuroendovascular techniques that are optimally performed coaxially through a large-caliber guiding catheter.

Received November 22, 1994; accepted after revision August 23, 1995.

From the Interventional Neuroradiology Service, Department of Radiology (C.M.P., J.C.C.), and the Department of Surgery (C.M.P., J.C.C.), Yale University School of Medicine, New Haven, Conn.

Address reprint requests to John C. Chaloupka, MD, Department of Radiology, Yale University School of Medicine, Box 208042, New Haven, CT 06520.

AJNR 17:697-704, Apr 1996 0195-6108/96/1704-0697 © American Society of Neuroradiology

TABLE 1: Interventional neuroradiology guiding catheters

Product Name	Outer Diameter, F (in, mm)	Inner Diameter, F (in, mm)	Length, cm	Shapes*
Titan‡	4.0 (0.052, 1.32)	3.2 (0.042, 1.07)	100	MP, S†
	5.0 (0.066, 1.68)	4.0 (0.052, 1.32)	100	MP, S†
	6.0 (0.079, 2.01)	5.0 (0.066, 1.68)	100	MP, S†
	7.0 (0.092, 2.34)	6.0 (0.079, 2.01)	100	MP, S†
	7.4 (0.096, 2.44)	6.4 (0.084, 2.11)	100	MP, S†
	8.0 (0.104, 2.64)	7.0 (0.092, 2.34)	100	MP, S†
	9.0 (0.117, 2.97)	8.0 (0.104, 2.67)	100	MP, S†
	10.0 (0.130, 3.30)	9.0 (0.117, 3.00)	100	MP, S†
Omniguide‡ and Omniguide-FLX‡ (± Hylite hydrophilic coating)	4.0 (0.052, 1.32)	3.2 (0.042, 1.07)	100	MP, S†
	5.0 (0.066, 1.68)	4.0 (0.052, 1.32)	100	MP, S†
	6.0 (0.079, 2.01)	5.0 (0.066, 1.68)	100	MP, S†
	7.0 (0.092, 2.34)	6.0 (0.079, 2.01)	100	MP, S†
	7.4 (0.096, 2.44)	6.4 (0.084, 2.13)	100	MP, S†
	8.0 (0.105, 2.64)	7.0 (0.092, 2.34)	100	MP, S†
Zeppelin‡ balloon guiding catheter	5.4 (0.070, 1.78)	3.2 (0.042, 1.07)	60/100/130	S (8-mm balloon)
	6.4 (0.084, 2.11)	4.0 (0.052, 1.32)	60/100/130	S (10-mm balloon)
	7.4 (0.096, 2.44)	5.0 (0.066, 1.68)	60/100/130	S (10-mm balloon)
	8.4 (0.109, 2.77)	6.0 (0.079, 2.01)	60/100/130	S (10-mm balloon)
	9.4 (0.122, 3.10)	7.0 (0.092, 2.34)	60/100/130	S (10-mm balloon)
Envoy§	5.0 (0.066, 1.68)	3.8 (0.050, 1.27)	90/100	S†, MP, Si2, HH, MC
	6.0 (0.079, 2.01)	4.7 (0.062, 1.57)	90/100	S†, MP, Si2, HH, MC
Fastguide	6.0 (0.079, 2.01)	4.0 (0.052, 1.32)	90/100	S†
Royal Flush¶	3.0 (0.039, 1.00)	2.0 (0.026, 0.66)	70/90/100/110	S†
	4.0 (0.052, 1.32)	3.0 (0.039, 0.99)	70/90/100/110	S†
	4.5 (0.059, 1.50)	3.4 (0.044, 1.12)	70/90/100/110	S†
	5.0 (0.066, 1.68)	3.7 (0.048, 1.22)	70/90/100/110	S†
	5.5 (0.072, 1.83)	4.2 (0.054, 1.37)	70/90/100/110	S†
	6.0 (0.079, 2.00)	4.5 (0.059, 1.50)	70/90/100/110	S†
	6.5 (0.085, 2.16)	5.0 (0.066, 1.68)	70/90/100/110	S†
	7.0 (0.092, 2.34)	5.2 (0.068, 1.73)	70/90/100/110	S†
Balt guiding catheter	3.0 (0.039, .095)	1.8 (0.024, 0.60)	100	S
	4.5 (0.059, 1.50)	3.0 (0.039, 1.00)	100	S
	5.0 (0.066, 1.67)	3.6 (0.047, 1.20)	100	S
	6.0 (0.079, 2.00)	4.5 (0.059, 1.50)	100	S
	7.0 (0.092, 2.33)	4.8 (0.063, 1.60)	100	S

* HH indicates headhunter; MC, modified cerebral; MP, multipurpose; S, straight; and Si2, Simmons 2.

† Able to be steam-shaped.

‡ Micro Interventional Devices, Inc, Sunnyvale, Calif.

§ Cordis Endovascular Systems, Inc, Miami Lakes, Fla.

|| Target Therapeutics, Fremont, Calif.

¶ Cook Cardiology, Cook Inc, Bloomington, Ind.

Technique

Our center has frequent occasion to use 7F to 9F guiding catheters for carotid balloon test occlusion, therapeutic carotid artery occlusion with detachable balloons, and PTA of the carotid system. We have frequently used a 7F guiding catheter for balloon test occlusions when a hand-tied, nondetachable latex balloon (BC 16 and 9, Ingenor, France) is mounted on a microcatheter. Alternatively, an 8F guiding catheter is needed if a 5F double-lumen balloon occlusion catheter (Meditech, Watertown, Mass) is used for temporary balloon test occlusion. In cases of planned permanent balloon occlusion, guiding catheters in the range of 7F to 10F may be required, depending on the size of the detachable balloon needed (2) (Figs 1 and 2) (Table 1). Summaries of the compatibility of the various

devices currently available and the guiding catheters are presented in Tables 1 to 4.

Recently, several preformed guiding catheters have become available that are specifically designed for neuroendovascular applications (Table 1). The Envoy guiding catheter (Cordis Endovascular Systems, Miami Lakes, Fla) is available in straight, angled (multipurpose C and D), Hicks headhunter and Simmons 2 shapes, providing an inner diameter of 0.062 in (1.6 mm) with a 6F outer diameter. The Fastguide (Target Therapeutics, Fremont, Calif) is a straight 6F hydrophilically coated, steerable guiding catheter that has a 0.052-in inner diameter. The Omniguide guiding catheter (Micro Interventional Systems, Inc, Sunnyvale, Calif) is available in 4F to 6F diameters with either straight or slightly curved tips. These

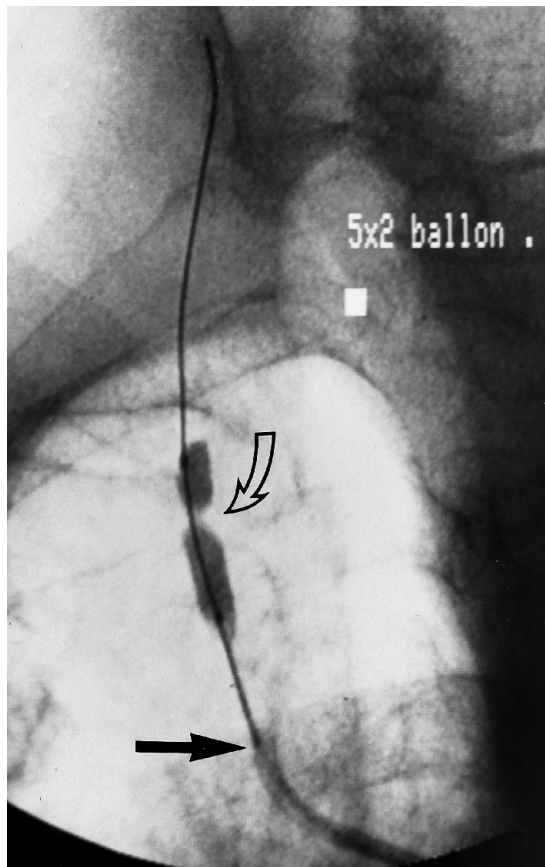


Fig 1. An 8F Judkins right 3.5 curve coronary guiding catheter (straight arrow) provides access to the right innominate artery for angioplasty of a severe stenosis of the proximal right common carotid artery. The angioplasty balloon (curved arrow) is positioned over a wire across the stenosis during inflation.




Fig 2. Coronary guiding catheters with a Judkins right 3.5 curve (A) and a Judkins right 4.0 curve (B) have a preformed curve similar to the Hinks headhunter catheter. The Judkins left 4.0 curve (C) can be used in a fashion similar to a reverse curve catheter to select dolioectactic vessels.

catheters are also thin-walled, allowing corresponding inner diameters of 0.042 to 0.066 in. None of these catheters however, provides sufficient inner diameter to permit coaxial delivery of the larger detachable balloons or PTA catheters.

Currently, only the Omniguide guiding catheter is available in large sizes (7F to 10F) with either a slightly angled or straight tip. Despite having some ability to steam-shape the tip of these catheters, direct catheterization of ectatic brachiocephalic vessels is generally not possible, since a reverse curve configuration cannot be reliably produced and maintained (the latter because of a tendency of the catheter to soften when exposed to body temperature during prolonged use). In addition, these catheters have a thin-wall construction, which maximizes the inner diameter but decreases wall stiffness with corresponding increased susceptibility to kinking. We encountered the same problems with these catheters as we did with their predecessors when attempting to position them, by catheter exchange, over a long wire.

We have found that coronary guiding catheters, such as the Brite Tip (Cordis Endovascular systems, Miami Lakes, Fla) and Sherpa Peak Flow (Medtronic, Inc, Minneapolis, Minn), are useful for direct catheterization of the proximal brachiocephalic vessels when larger inner lumen diameters are need for the above-mentioned devices. These catheters consist of 100 cm of braided nylon or urethane with preformed curves and soft atraumatic radiopaque tips that range in size from 6F to 10F. These catheters provide an inner diameter of 0.062 in with a 6F catheter and up to 0.108 in with the 10F catheter. A variety of preformed curves are available, including variations of the Judkins left and right coronary technique (3, 4) (Fig 2).

The specific type of coronary guiding catheter is selected by taking into consideration both the inner lumen size required to deliver a neurointerventional device and the geometry of the vessel to be accessed. For example, PTA of the common and internal carotid arteries often can be performed with a low-profile 5F PTA catheter (eg, Sub-4, Meditech, Watertown, Mass, and Opta-5, Cordis

TABLE 2: Detachable and tied-on balloons

Device	Balloon No.	Deflated Balloon		Guiding Catheter
		Diameter, mm	Length, mm	Outer Diameter, F (Inner Diameter, in)
Debrun latex balloons (tied-on)* (11-14)	BC7	2.50	2.40	9.0
	BC9	1.75	6.60	8.0
	BC12	2.20	5.50	9.0
	BC15	0.88	2.50	7.0
	BC16	1.20	6.60	7.0
	BC17	1.45	2.75	7.0
	BC19	1.20	2.65	7.0
	BC26	2.00	7.00	9.0
DSB detachable silicon balloons† (15)	DSB8501	0.85	...	6.3 (0.060)
	DSB8502	0.85	...	6.3 (0.060)
	DSB1502	1.50	...	7.3 (0.070)
	DSB1503	1.50	...	7.3 (0.070)
	DSB1505	1.50	...	7.3 (0.070)
	DSB1509	1.50	7.3	7.3 (0.070)
	DSB1804	1.80	...	8.0 (0.082)
	DSB1807	1.80	...	8.0 (0.082)
	DSB1810	1.80	6.40	8.0 (0.082)
	DSB1815	1.80	...	8.0 (0.082)
	DSB2220	2.20	...	9.0 (0.090)
ASB detachable silicon balloon†	ASB2005	2.00	...	8.0 (0.082)
	ASB2008	2.00	...	8.0 (0.082)
	ASB2207	2.20	...	9.0 (0.090)
	ASB2210	2.20	...	9.0 (0.090)
	ASB2220	2.20	...	9.0 (0.090)
Goldvalve latex detachable balloons* (16-17)	GVB7	2.40	2.50	10.0
	GVB9	1.60	6.50	9.0
	GVB12	2.30	5.00	10.0
	GVB15	1.50	3.00	7.0
	GVB16	1.50	6.50	8.0
	GVB17	1.60	3.00	8.0
	GVB19	1.50	3.00	8.0
	GVB26	2.40	7.50	10.0
	SPGV7	2.40	2.50	10.0
	SPGV9	1.60	6.50	9.0
	SPGV12	2.30	5.00	10.0
	SPGV16	1.50	6.50	8.0
	Integrated valve detachable balloons (latex)*	IVB9	1.60	6.50
IVB12		2.30	5.00	10.0
IVB15		1.50	3.00	7.0
IVB16		1.50	6.50	8.0
IVB17		1.60	3.00	8.0

* Nycomed, Ingenor Medical Co, Paris, France.

† Interventional Therapeutics Corp, San Francisco, Calif.

Endovascular Systems, Miami Lakes, Fla), which requires coaxial delivery through a 7F or 8F guiding catheter (Fig 3) (Table 4). Alternatively, a 9F or 10F guiding catheter can be used when a distal protective balloon is desired for use in conjunction with the PTA catheter, as described by Theron et al (5).

Selection of the appropriate preformed curve is also important to facilitate access to the targeted brachiocephalic artery. Generally, the Judkins (3, 4) right coronary catheters (3.5 and 4.0 curves) are favored for selection of the innominate and both common carotid arteries

owing to their similar configuration to the Hincks headhunter catheters (6). However, in some patients with extreme dolichoectasia of the aortic arch, resulting in very acute angles of origin of the great vessels, a Judkins (3, 4) left coronary catheter (3.5 curve) can be used, since it mimics the reverse curve configuration of a Simmons catheter, thus facilitating direct selection of both right and left common carotid arteries (Fig 2).

Because of their inherent stiffness and torquability, these large-caliber coronary guiding catheters can be manipulated into the origin of the targeted brachiocephalic

TABLE 3: Coronary guiding catheters

Catheter	Outer Diameter, F (in, mm)	Inner Diameter, F (in, mm)	Length, cm	Shapes
Petite Brite Tip*	6.0 (0.079, 2.01)	4.7 (0.062, 1.57)	100	JL, JR, MP, HS, AL, AR
Brite Tip*	6.0 (0.079, 2.01)	4.7 (0.062, 1.57)	90	JL, JR
	7.0 (0.092, 2.34)	5.5 (0.072, 1.82)	100	JL, JR, MP, HS, AL, AR
	8.0 (0.104, 2.64)	6.0 (0.078, 1.98)	97	JL, JR, MP, HS, AL, AR
XL Brite Tip*	8.0 (0.104, 2.64)	6.4 (0.084, 2.11)	100	JL, JR, MP, HS, AL, AR
Vista Brite Tip*	8.0 (0.104, 2.64)	6.6 (0.086, 2.18)	90/100	JL, JR, MP, HS
	9.0 (0.117, 2.97)	7.5 (0.098, 2.49)	98	JL, JR, MP, HS
	10.0 (0.130, 3.30)	8.5 (0.110, 2.79)	95	JL, JR, MP, HS
Roubin LuMax†	7.0 (0.092, 2.34)	5.6 (0.073, 1.85)	100	JL, JR, MP, HS, AL, AR
	8.0 (0.104, 2.64)	6.6 (0.086, 2.18)	100	JL, JR, MP, HS, AL, AR
Sherpa‡	6.0 (0.078, 1.98)	4.4 (0.057, 1.45)	100	JL, JR, MP, HS, AL, AR
	7.0 (0.091, 2.28)	5.4 (0.070, 1.78)	100	JL, JR, MP, HS, AL, AR
	8.0 (0.104, 2.64)	6.1 (0.079, 2.00)	100	JL, JR, MP, HS, AL, AR
Sherpa Peak Flow‡	7.0 (0.091, 2.28)	5.5 (0.072, 1.83)	100	JL, JR, MP, HS, AL, AR
	8.0 (0.104, 2.64)	6.4 (0.083, 2.11)	100	JL, JR, MP, HS, AL, AR
	9.0 (0.117, 2.97)	7.0 (0.092, 2.34)	100	JL, JR, MP, HS, AL, AR
	10.0 (0.130, 3.30)	8.3 (0.108, 2.74)	95	JL, JR, MP, HS, AL, AR
Giant Lumen‡	7.0 (0.091, 2.31)	5.0 (0.066, 1.67)	100	JL, JR, MP, HS
	8.0 (0.104, 2.64)	6.1 (0.079, 2.00)	95	JL, JR, MP, HS
	9.0 (0.117, 2.96)	6.8 (0.088, 2.23)	95	JL, JR, MP, HS

Note.—JL indicates Judkins left; JR, Judkins right; MP, multipurpose; HS, hockey-stick; AL, Amplatz left; and AR, Amplatz right.

* Cordis Endovascular Systems, Inc, Miami Lakes, Fla.

† Cook Cardiology, Cook Inc, Bloomington, Ind.

‡ Medtronic Interventional Vascular, Medtronic, Danvers, Mass.

artery with standard torquing and the withdrawal maneuvers used in neuroangiography. Once the guiding catheter engages the origin of the vessel, it can be advanced a few centimeters over a guidewire into the desired position. The braided construction provides excellent stability of these catheters and prevents kinking once a vessel has been selected.

The position of the guiding catheter is determined by the anticipated level of the procedure to be performed. Ideally, the guiding catheter is placed so that direct access to the targeted vessel is achieved without requiring negotiation of a major branch point. When occlusion of the internal carotid artery (ICA) is desired (ie, distal parent artery occlusion for treatment of an intracranial aneurysm), the ideal position of the guiding catheter is in the proximal ICA, bypassing the bifurcation of the common carotid artery (CCA). In situations requiring composite occlusion of the CCA, the external carotid artery (ECA), and the ICA (eg, carotid blowout syndrome) (7, 8), a more proximal placement of the guiding catheter just beyond the origin of the CCA is preferred.

After these guiding catheters are placed, an infusion of a saline flush solution with 1 to 3 U/mL of heparin is continued throughout the procedure. This is accomplished by the use of a Y adapter with an adjustable diaphragm to allow coaxial delivery of the occlusive device while maintaining constant infusion. If there is no contraindication, all patients are given an anticoagulant (3000 to 5000 U of heparin intravenously) to prevent thromboembolic complications.

Discussion

The ideal guiding catheter for neuroendovascular therapeutic techniques should have certain characteristics that permit relatively easy and safe catheterization of the brachiocephalic arteries and provide stable and frictionless access for coaxial delivery of endovascular therapeutic devices. The former set of characteristics includes adequate stiffness and torque control, sufficient radiopacity, and favorable distal curvatures. The latter set of characteristics includes larger inner lumen diameter, sufficient wall stiffness to avoid kinking, and stability once positioned in a vessel. Until recently, many commonly used large-caliber guiding catheters for neuroendovascular use fell far short of providing all these ideal characteristics.

We have noted that the most striking deficiencies with these older guiding catheters are their lack of appropriate torque control, tractability, radiopacity, and wall stiffness. Despite attempts to modify the distal curve of these catheters and to coaxially insert a smaller diameter inner catheter (to enhance stiffness and tractability), it is not unusual to experience significant difficulty in selecting the brachiocephalic arteries by either direct or exchange

TABLE 4: Angioplasty catheters and balloon occlusion catheters

Device	Inflated Balloon Diameter, mm	Outer Diameter, F	Recommended Inner Diameter of Guiding Catheter Guidewire, in	Length, cm	
Angioplasty catheters (18–20)					
Sub-4 balloon dilatation catheter*	2.0	3.8	0.064/0.018	80/120	
	2.5	3.8	0.064/0.018	80/120	
	3.0	3.8	0.064/0.018	80/120	
	4.0	3.8	0.064/0.018	80/120	
	4.5	3.8	0.079/0.018	80/120	
	5.0	3.8	0.079/0.018	80/120	
	5.5	3.8	0.079/0.018	80/120	
	6.0	3.8	0.079/0.018	80/120	
Stealth balloon dilation systems†					
	2.0	3.2	0.043/0.014‡	150	
	2.5	3.2	0.045/0.014‡	150	
	3.0	3.2	0.048/0.014‡	150	
	3.5	3.2	0.052/0.014‡	150	
	4.0	3.2	0.059/0.014‡	150	
Ultra-thin balloon*					
	3.0	5.0	7F (0.072)/0.035	75/120/150	
	4.0	5.0	7F (0.072)/0.035	75/120/150	
	5.0	5.0	7F (0.072)/0.035	75/120/150	
	6.0	5.0	8F (0.084)/0.035	75/120/150	
	7.0	5.0	8F (0.084)/0.035	75/120/150	
	8.0	5.0	8F (0.084)/0.035	75/120/150	
	9.0	5.0	9F (0.098)/0.035	75/120/150	
Opta 5§	10.0	5.0	9F (0.098)/0.035	75/120/150	
	4.0	5.0	7F (0.072)/0.035	80/110/135	
	5.0	5.0	7F (0.072)/0.035	80/110/135	
	6.0	5.0	8F (0.084)/0.035	80/110/135	
	7.0	5.0	8F (0.084)/0.035	80/110	
	8.0	5.0	8F (0.084)/0.035	80/110	
Balloon Occlusion Catheters (21–23)	9.0	5.0	9F (0.098)/0.035	65/80	
	10.0	5.0	9F (0.098)/0.035	65/80	
	Standard balloon occlusion catheter*				
	8.5	5.0	8F/0.027	65/100	
	8.5	5.0	9F/0.035	65/100	
Berenstein balloon occlusion catheters (large lumen)*	11.5	5.0	.../0.038	65/100	
	13.0	7.0	.../0.056	80	
	11.5	6.0	.../0.041	25/80	

* Medi-tech, Boston Scientific Corp, Natick, Mass.

† Target Therapeutics, Fremont, Calif.

‡ 0.014-in Seeker Valve Wire or Stubbie Valve Wire.

§ Cordis Endovascular Systems, Inc, Miami Lakes, Fla.

catheterization techniques (particularly when sizes of 8F or greater are used). This difficulty increases substantially in procedures with older patients who have dolichoectasia of the aortic arch and great vessels.

Recently developed neuroendovascular guiding catheters currently offer some substantial improvements over their predecessors but have failed to satisfy completely all the needs of the neurointerventionalist. The smaller catheters such as the 5F and 6F Envoy, the 6F Fastguide, and the 4F to 6F Omniguide guiding catheters have certainly enhanced the operator's ability to attain safe and secure distal catheterization of

the internal carotid and vertebral arteries for coaxial intracranial navigation with many currently available neuroendovascular devices. However, despite the larger inner lumen diameters of some of these new catheters, they remain too small to permit coaxial delivery of the many larger detachable and nondetachable balloons, PTA catheters, and double-lumen temporary balloon occlusion catheters. Currently, only the Omniguide guiding catheters are available in larger sizes (7F to 10F) for use with these larger endovascular devices. Although these catheters have better torque control and rigidity, they remain inadequate for direct cath-

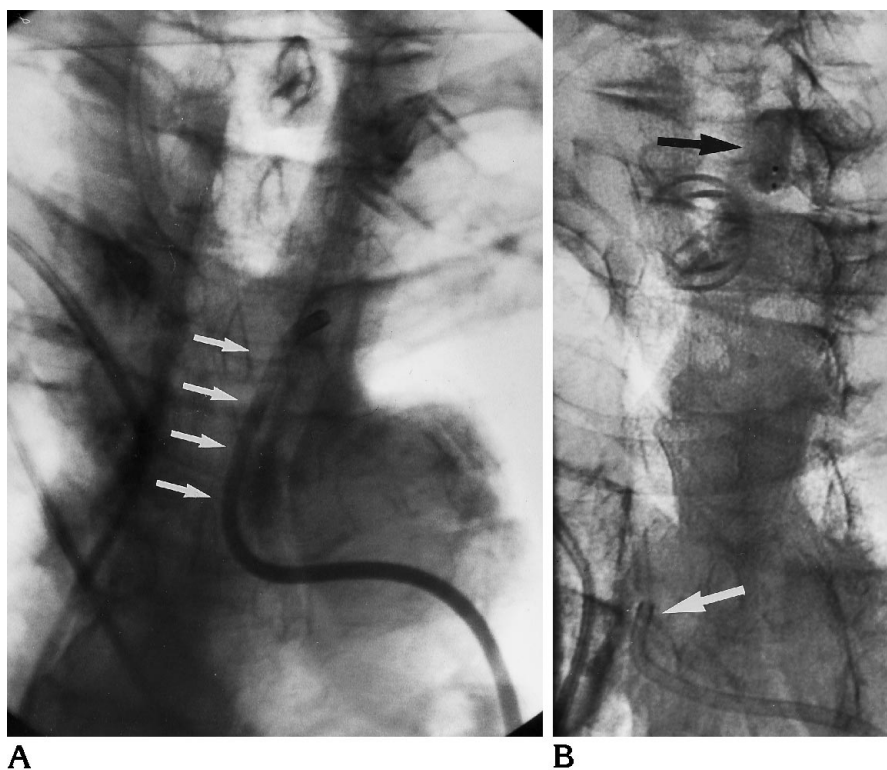


Fig 3. A 9F Judkins right 4.0 curve coronary guiding catheter used in a composite left carotid balloon occlusion in a patient with recurrent squamous cell carcinoma.

A, The catheter (*arrows*) was positioned in the left distal common carotid artery without requiring a long exchange over a wire.

B, After balloon occlusion of the internal and external carotid arteries, the catheter (*white arrow*) was repositioned in the orifice of the left common carotid artery. The GVB12 balloon (*black arrow*) was positioned in the distal left common carotid artery before detachment.

eterization of ectatic brachiocephalic vessels. Furthermore, in our experience, these catheters are often as difficult to position into ectatic vessels by catheter exchange over a long wire as the older types of guiding catheters.

We have found that large-caliber coronary guiding catheters in the size range of 7F to 10F, with either a Judkins right 3.5 or 4.0 curve permits surprisingly easy access to most proximal brachiocephalic vessels with the use of conventional direct catheterization techniques. In some cases in which direct selection can only be accomplished with a reverse curve configuration (9) (eg, acute angle of origin of the left common carotid artery), the Judkins left 3.5 curve catheter has worked well. The increased stiffness, excellent torquability, large inner lumen diameters, favorable preformed curves, and good radiopacity of these catheters make them extremely useful in patients with difficult anatomic configuration of the aortic arch and great vessels. Although these catheters are not officially approved for use in neurointerventional applications, we have used them in off-label applications where no officially approved device could meet the need.

There are several potential disadvantages of the use of large-caliber guiding catheters: (a) a

large arteriotomy may result in an increased rate of complications at the access site (10); (b) a larger, less supple catheter may cause greater trauma to the vasculature, resulting in increased risk of catheter-induced vasospasm or dissection; and (c) the larger surface area and greater size may cause an increased risk of thrombus formation with associated thromboembolic complications.

Additional precautions should be taken to minimize any risk to the patient from the guiding catheter. The smallest system that will enable the operator to accomplish the procedure should be selected. All patients should be given an anticoagulant after percutaneous transfemoral access to minimize possible thromboembolic complications. Removal of the vascular sheath should be done in a controlled setting after coagulation factors are maximized. Monitoring of the access site at frequent intervals also necessary. In our experience, the advantages of using a stable, large-diameter catheter to provide a direct coaxial pathway to the targeted vessel far outweigh the disadvantages of these devices.

In conclusion, large-caliber guiding catheters are required when relatively large diameter endovascular devices such as detachable

balloons and PTA catheters are used. We have found that in such situations, certain 7F to 10F coronary guiding catheters (particularly with a Judkins right coronary configuration) are extremely useful in providing proximal catheterization of the brachiocephalic arteries in patients with unfavorable anatomy resulting from dolioectasia.

References

- Dion JE. Principles and methodology. In: Vinuela F, Halbach VV, Dion JE, eds. *Interventional Neuroradiology: Endovascular Therapy of the Central Nervous System*. New York, NY: Raven Press; 1992; 1-13
- Chaloupka JC, Putman CM. Endovascular therapy of surgical disease of the cranial base. *Clin Plast Surg* 1995;22:417-450
- Judkins MP. Percutaneous transfemoral selective coronary arteriography. *Radiol Clin North Am* 1968;6:467-492
- Judkins MP. Selective coronary arteriography: a percutaneous transfemoral technique. *Radiology* 1967;89:815-824
- Theron J, Courtheoux P, Alachkar S, Bouvard G, Maiza D. New triple coaxial catheter system for carotid angioplasty with cerebral protection. *AJNR Am J Neuroradiol* 1990;11:869-874
- Hinck V, Tanabe C. Comprehensive selective angiography in cerebrovascular insufficiency. *Surg Gynecol Obstet* 1969;129:519-524
- Citardi MJ, Chaloupka JC, Son YH, Sasaki CT. Management of carotid artery rupture by monitored endovascular therapeutic occlusion (1988-1994). *Laryngoscope* 1995;10:1086-1092
- Chaloupka JC, Putman CM, Citardi MJ, Ross D, Sasaki CT. Endovascular therapy of carotid blowout syndrome in head and neck surgical patients: an evolving diagnostic and management paradigm. *AJNR Am J Neuroradiol* (in press)
- Simmons CR, Tsao EC, Thompson JR. Angiographic approach to the difficult aortic arch: a new technique for transfemoral cerebral angiography in the aged. *AJR Am J Roentgenol* 1973;119:605-610
- Muller WM, Shamir KJ, Ellis SG, Topol EJ. Peripheral vascular complications after conventional and complex percutaneous coronary interventional procedures. *Am J Cardiol* 1992;69:63-68
- Debrun G, Lacour P, Vinuela F, Fox A, Drake CG, Caron JP. Treatment of 54 traumatic carotid-cavernous fistulas. *J Neurosurg* 1981;55:678-692
- Debrun GM. Treatment of traumatic carotid-cavernous fistula using detachable balloon catheters. *AJNR Am J Neuroradiol* 1983; 4:355-356
- Debrun G, Lacour P, Caron JP, Hurth M, Comoy J, Keravel Y. Detachable balloon and calibrated-leak balloon techniques in the treatment of cerebral vascular lesions. *J Neurosurg* 1978;49:635-649
- Debrun G, Lacour P, Caron JP, Keravel Y, Comoy J, Loisanse D. Treatment of arterio-venous fistulas and aneurysms with an inflatable release balloon: experimental work—application in man. In: Salamon G, ed. *Advances in Cerebral Angiography*. Berlin: Springer-Verlag 1975: 198-204
- Higashida RT, Halbach VV, Dormandy B, Bell JD, Hieshima GB. Endovascular treatment of intracranial aneurysm therapy with a new silicone microballoon device: technical considerations and indications for therapy. *Radiology* 1990;174:687-691
- Burrows PE, Lasjunias P, TerBurge KG. A 4-F coaxial catheter system for pediatric vascular occlusion with detachable balloons. *Radiology* 1989;170:1091-1094
- Khangure MS, ApSimon HT, Hartley DE, Maddren L. Valved latex balloons and water-soluble contrast opacified polymer: a simple detachable balloon system. *Acta Radiol Suppl* 1986;369:627-630
- Eskridge JM, Newell DW, Pendleton GA. Transluminal angioplasty for the treatment of vasospasm. *Neurosurg Clin N Am* 1990;1:387-399
- Higashida RT, Tsai FY, Halbach VV, Branmwell SL, Dowd CF, Hieshima GB. Interventional neurovascular techniques in the treatment of stroke: state-of-the-art therapy. *J Int Med* 1995;237: 105-115
- Higashida RT, Halbach VV, Dowd CF, Dormandy B, Bell J, Hieshima GB. Intravascular balloon dilatation therapy for intracranial arterial vasospasm: patient selection, technique, and clinical results. *Neurosurg Rev* 1992;15:89-95
- Berenstein A, Kricheff II. Catheter and material selection for transarterial embolization: technical considerations. *Radiology* 1979;132:619-630
- Greenfield AJ, Athanasoulis CA, Waltman AC, LeMoire ER. Transcatheter embolization: prevention of embolic reflux using balloon catheters. *AJR Am J Roentgenol* 1978;131:651-655
- Wholey MH. The technology of balloon catheters in interventional angiography. *Radiology* 1977;125:671-676