
Extraaxial Ependymoma of the Posterior Fossa

Melanie B. Fukui, Jeffery P. Hogg, and A. Julio Martinez

Summary: We report an unusual case of an extraaxial ependymoma of the posterior fossa in an adult. MR imaging showed a heterogeneously enhancing extraaxial mass with a cystic component. Ependymoma should be included in the differential diagnosis of uncommon extraaxial masses of the posterior fossa.

Index terms: Ependymoma; Posterior fossa, neoplasms

Two to six percent of all primary brain tumors are ependymomas (1, 2). These tumors usually arise from the fourth ventricle (2, 3), and all are in, or are in proximity to, the fourth ventricle (4, 5). In one large series (3), the mean age at presentation for ependymomas of the posterior fossa was 19 years. We report an unusual case of an extraaxial ependymoma of the posterior fossa in an adult.

Case Report

A 66-year-old man had left-sided facial pain in the distribution of the first and second divisions of the trigeminal nerve. Initially, the pain was relieved by carbamazepine; but during the next 6 months, his symptoms progressed and began to awaken him at night. He had no history of vertigo, disequilibrium, hearing loss, or tinnitus. On neurologic examination, the only positive finding was some horizontal nystagmus on right lateral gaze. Magnetic resonance (MR) imaging of the brain showed an extraaxial, heterogeneously enhancing mass adjacent to the left cerebellar hemisphere and lateral tentorium (Fig 1A–C). The preoperative diagnosis was meningioma.

A left-sided retromastoid craniectomy was performed. At surgery, a 2.5 × 1.5-cm lobulated tan-gray mass with loculated areas containing yellowish fluid was found at the superolateral margin of the cerebellum. There was no attachment to the petrous bone, dura, or the seventh and eighth cranial nerve complex. The surgeons developed an arachnoid plane around the mass and removed it completely. A frozen section rendered a tentative diagnosis of glial neoplasm. After resection of the mass, a large loop of

the superior cerebellar artery was identified at the rostral and anterior aspect of the left fifth cranial nerve; microvascular decompression was performed.

Histologic examination revealed a papillary glial neoplasm (Fig 1D) with a moderate fibroconnective network and extensive areas of old and new hemorrhage. The neoplastic cells were ependymal with abundant eosinophilic cytoplasm. The nuclei were uniform and bland with minimal pleomorphism. True rosettes and perivascular rosettes were seen (Fig 1D). Thirty-five percent to 40% of the cells had a positive reaction for the glial fibrillary acidic protein. Ultrastructural studies showed neoplastic ependymal cells with elongated processes containing glial filaments and microvilli, confirming the diagnosis of ependymoma.

The patient underwent radiation therapy to the head. At the 2½-year follow-up, he was asymptomatic with no evidence of recurrence on a computed tomographic (CT) scan.

Discussion

The most common site for ependymomas is the fourth ventricle (2, 3). Posterior fossa ependymomas usually arise from the roof, floor, or lateral medullary velum of the fourth ventricle (2, 3). Plastic ependymomas, or those that extend beyond the fourth ventricle into the subarachnoid space through the foramina of Luschka and Magendie, have both intraaxial and extraaxial components (6).

An exclusively extraaxial ependymoma of the posterior fossa is rare. We are aware of one other reported case (7). Extraaxial ependymomas outside the posterior fossa are most frequent in the spine (8, 9); the most commonly reported spinal site is the sacrococcygeal region (9, 10). A few cases of supratentorial ependymomas completely outside the neuraxis have been reported: one described a case of an

Received August 1, 1996; accepted after revision November 15.

Supported in part by the Pathology Education and Research Foundation of the Department of Pathology, University of Pittsburgh (Pa) School of Medicine.

From the Departments of Radiology (M.B.F.) and Pathology (A.J.M.), University of Pittsburgh (Pa) Medical Center, and the Department of Radiology, West Virginia University, Morgantown (J.P.H.).

Address reprint requests to Melanie B. Fukui, MD, Division of Neuroradiology, Department of Radiology, Room D-132, Presbyterian University Hospital, 200 Lothrop St, Pittsburgh, PA 15213.

AJNR 18:1179–1181, Jun 1997 0195-6108/97/1806–1179 © American Society of Neuroradiology

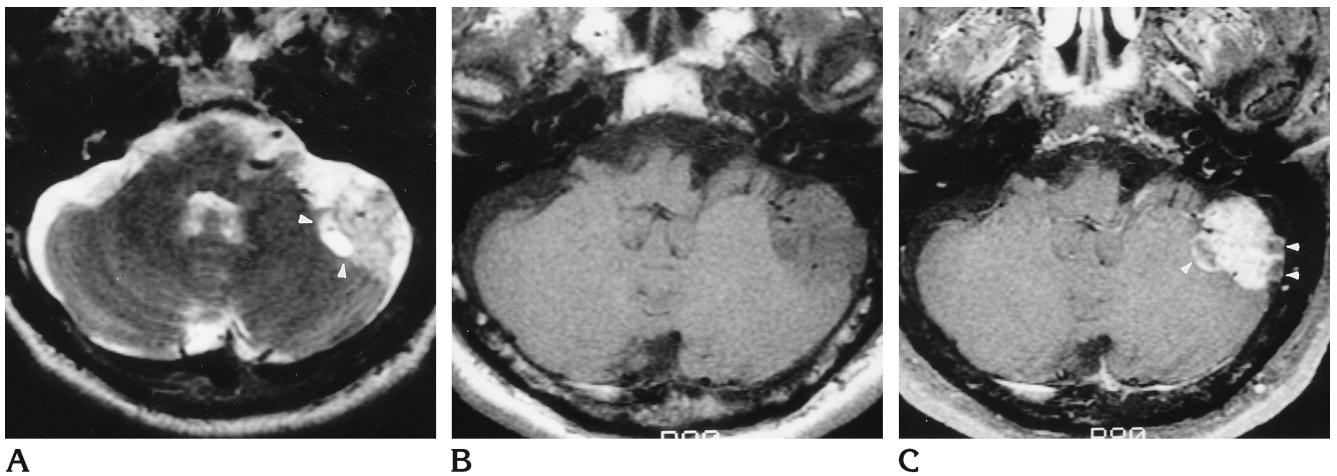


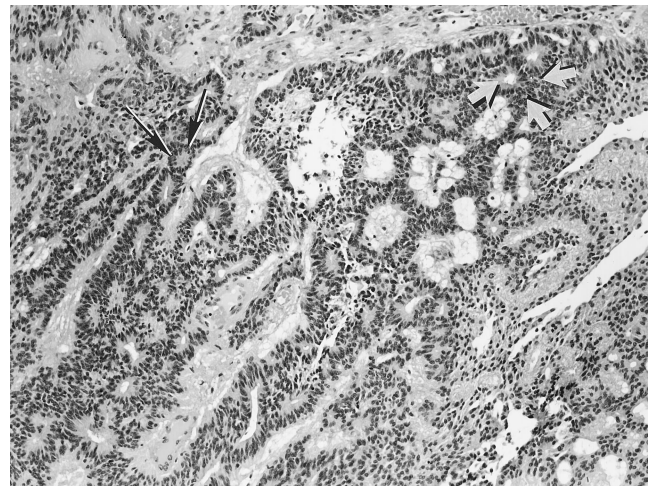
Fig 1. A 66-year-old man with extraaxial ependymoma of the posterior fossa.

A, Axial T2-weighted MR image (4000/119/1 [repetition time/echo time/excitations]) shows a lobulated extraaxial mass adjacent to the left cerebellar hemisphere, that is hyperintense with respect to gray matter and contains fluid-filled cavities (*arrowheads*).

B, Axial T1-weighted MR image (450/20/4) shows the mass to be heterogeneous and hypointense relative to gray matter. There is minimal distortion of the fourth ventricle.

C, Axial T1-weighted MR image (500/20/4) after contrast administration shows heterogeneous enhancement of the mass. *Arrowheads* indicate loculated fluid.

D, Histologic section shows that the neoplasm is composed of ependymal cells forming rosettes without (*thin arrows*) and with (*thick arrows*) lumina, characteristic of ependymoma (hematoxylin-eosin, original magnification $\times 100$).



D

interhemispheric ependymoma and another reported an ependymoma adjacent to the dura of the occipital and parietal lobes (11, 12).

In our case, MR imaging clearly established the extraaxial site of the tumor. Although no MR imaging features are pathognomonic of ependymoma (13), they often (in half the reported cases) show heterogeneous enhancement (13), as did this mass. This lack of imaging specificity most likely reflects the varied histology of these tumors (2).

Other types of extraaxial gliomas that have occasionally been reported include astrocytoma, oligodendroglioma, glioblastoma, and mixed glioma (14–18). Gliomas of the leptomeninges are believed to originate from heterotopic nests of glial tissue in the meninges and subarachnoid space (8, 19). In the current case, a clear plane was seen between the posterior fossa mass and the cerebellum at surgery. No connection was apparent between the mass and

the fourth ventricle. We propose that, in this case, the neoplasm most likely arose from glial rests in the subarachnoid space or meninges of the posterior fossa (8, 19) to produce an extraaxial mass. In conclusion, ependymoma should be considered among the uncommon causes of an extraaxial posterior fossa mass.

Acknowledgment

We thank Sabrina Jennings for assistance in preparing the manuscript.

References

1. McKernan R, Thomas D. The clinical study of gliomas. In: Thomas D, Graham D, ed. *Brain Tumors: Scientific Basis, Clinical Investigation and Current Therapy*. London, England: Butterworth; 1980:194–230
2. Russell D, Rubinstein L. *Pathology of Tumours of the Central Nervous System*. 5th ed. London, England: Edward Arnold; 1989: 192–206

3. Fokes E, Earle K. Ependymomas: clinical and pathological aspects. *J Neurosurg* 1969;30:585-594
4. Mork S, Loken A. Ependymoma: a follow-up study of 101 cases. *Cancer* 1977;40:907-915
5. West C, Bruce D, Duffner P. Ependymomas: factors in clinical and diagnostic staging. *Cancer* 1985;56:1812-1816
6. Courville C, Broussalian S. Plastic ependymomas of the lateral recess: report of eight verified cases. *J Neurosurg* 1961;18:792-799
7. Cosgrove G, Villemure J, Robitaille Y, Melanson D. Extraaxial ependymoma of the posterior fossa. *Surg Neurol* 1985;24:433-436
8. Cooper I, Craig W, Kernohan J. Tumors of the spinal cord: primary extramedullary gliomas. *Surg Gynecol Obstet* 1951;92:183-190
9. Wagle W, Jaufman B, Mincy J. Intradural extramedullary ependymoma: MR-pathologic correlation. *J Comput Assist Tomogr* 1988;12:705-707
10. Morantz R, Kepes J, Batnitsky S. Extraspinal ependymomas: report of three cases. *J Neurosurg* 1979;51:383-391
11. Hayashi K, Tamura M, Shimozuru T, et al. Extraaxial ependymoma. *Neurol Med Chir (Tokyo)* 1994;34:295-299
12. Hanchey R, Stears J, Lehman R, Norenberg M. Interhemispheric ependymoma mimicking falx meningioma. *J Neurosurg* 1976;45:108-112
13. Spoto G, Press G, Hesselink J, Solomon M. Intracranial ependymoma and subependymoma: MR manifestations. *AJNR Am J Neuroradiol* 1990;11:83-91
14. Bailey O. Relation of glioma of the leptomeninges to neuroglia nests. *Arch Pathol* 1936;21:584-600
15. Bailey P, Robitaille. Primary diffuse leptomeningeal gliomatosis. *Can J Neurol Sci* 1985;12:278-281
16. Ho K, Hoschner J, Wolfe D. Primary leptomeningeal gliomatosis: symptoms suggestive of meningitis. *Arch Neurol* 1981;38:662-666
17. Korein J, Feigin I, Shapiro M. Oligodendrogliomatosis with intracranial hypertension. *Neurology* 1957;7:589-594
18. Sceats D, Quisling R, Rhoton A, Ballinger W, Ryan P. Primary leptomeningeal glioma mimicking an acoustic neuroma: case report with review of the literature. *Neurosurgery* 1986;19:649-654
19. Wolbach S. Congenital rhabdomyoma of the heart: report of a case associated with multiple nests of neuroglial tissue in the meninges of the spinal cord. *J Med Res* 1907;16:495-519