

The Anterior Epitympanic Recess: CT Anatomy and Pathology

L. V. Petrus and W. W. M. Lo

PURPOSE: To describe the variation in size and shape of the anterior epitympanic recess and to discuss pathologic processes that affect this space. **METHODS:** Axial CT scans of the temporal bones of 31 adults and 19 children were reviewed retrospectively to ascertain the morphology and size of the anterior epitympanic recess. Selected confirmed disease processes involving this space were studied. **RESULTS:** The anterior epitympanic recess, which is consistently identified on axial CT scans, is either single or multicelled. In our study, it was made up of a solitary cell in 61 of 100 ears. Side-to-side symmetry in shape was present in 78 of 100 cases. The size of a solitary air cell ranged from 1.0 to 7.0 mm. **CONCLUSIONS:** The configuration of the anterior epitympanic recess is readily affected by a persistent stapedia artery, by facial nerve schwannomas, by hemangiomas of the facial nerve canal in the geniculate region, and by congenital and acquired cholesteatomas. Familiarity with the CT anatomy of this space facilitates recognition of these pathologic processes at an early stage.

Index terms: Temporal bone, computed tomography; Temporal bone, anatomy

AJNR Am J Neuroradiol 18:1109–1114, June 1997

The anterior epitympanic recess, also called the supratubal recess, is the small space in the epitympanum anterior to the malleus. It is partitioned from the epitympanum proper (attic) by a coronally oriented bony septum, the anterior attic bony plate or “cog,” which is suspended from the anterior petrosal tegmen (1, 2). It is bordered medially by the geniculate fossa and the anterior portion of the tympanic facial nerve canal, and laterally by the petrosquamosal suture (3). The anterior epitympanic recess is partitioned in varying degrees in some temporal bones from the protympanum by a horizontal mucosal fold at the level of the tensor tympani muscle, or in others from the epitympanic space proper by a vertical fold attached to the cog (3–5).

The anterior epitympanic recess has received scant attention in the radiologic literature (6–8). Recent advances in surgical techniques of the middle ear cleft has spawned renewed interest in the microanatomy of the middle ear (3, 4). The anterior epitympanic recess has also attracted the attention of ear surgeons because of its relationship to important surrounding structures and to its frequent involvement by cholesteatoma (1, 4, 9, 10). In this article, we describe the variations in size and shape that this space may adopt on axial computed tomographic (CT) scans, illustrate its radiologic anatomy, and describe the pathologic processes that may affect its appearance.

Materials and Methods

We retrospectively reviewed the axial CT scans of the temporal bone in 50 patients examined for vestibulocochlear symptoms. The patients ranged in age from 6 months to 80 years; 29 were female and 21 male. All patients were scanned on a GE (Milwaukee, Wis) 9800 CT scanner. The scanning protocol included 1.5-mm-thick sections at 1-mm intervals obtained at the +30° plane, with an edge-enhancement algorithm on an extended scale using a 512 × 512 matrix. Other scanning parameters included 120 kV with 170 mA for 3 seconds. The

Received October 7, 1996; accepted after revision January 21, 1997.
Presented at the annual meeting of the American Society of Head and Neck Radiology, Los Angeles, Calif, April 1996.

From the Department of Radiology, Olive View-UCLA Medical Center, Sylmar, Calif (L.V.P.), and the Department of Radiology, St Vincent's Medical Center, Los Angeles, Calif (W.W.M.L.).

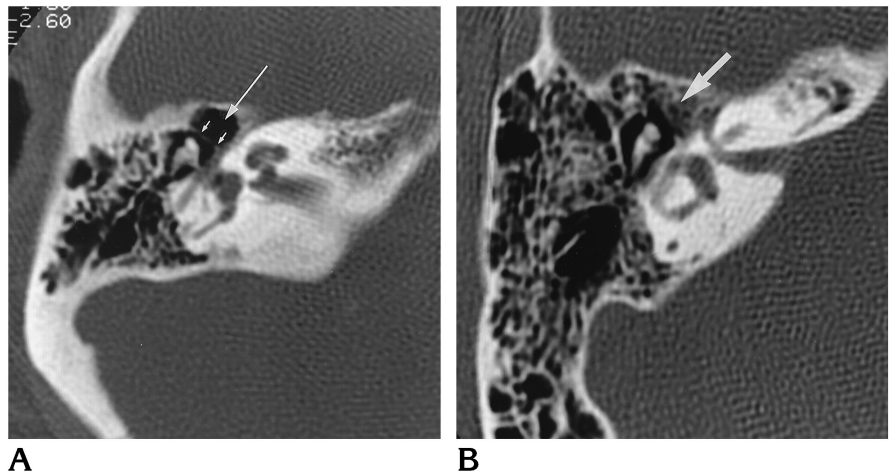
Address reprint requests to L. V. Petrus, MD, Department of Radiology, Olive View-UCLA Medical Center, 14445 Olive View Dr, #2D139, Sylmar, CA 91342.

AJNR 18:1109–1114, Jun 1997 0195-6108/97/1806–1109
© American Society of Neuroradiology

Fig 1. Variably shaped anterior epitympanic recesses.

A, Axial CT scan of the right temporal bone shows a single-celled anterior epitympanic recess (*long arrow*). The anterior attic bony plate, or cog (*short arrows*), separates the anterior epitympanic recess from the attic proper.

B, Axial CT scan of this well-pneumatized right temporal bone shows the anterior epitympanic recess to be made up of several small cells with no dominant cell (*arrow*).



images were displayed on a field of view of 9.6 cm with a window width of 4000 and level 925 Hounsfield units.

Within each temporal bone, note was made as to whether the anterior epitympanic recess consisted of a single cell or multiple small cells. If a single cell was identified, its anteroposterior and transverse dimensions were measured. The measurements were made with a magnifying glass that contained millimeter calibrations. We also reviewed a randomly selected collection of cases of various pathologic processes with involvement of the anterior epitympanic recess.

Results

Of the 100 temporal bones evaluated, 61 had a solitary cell making up the anterior epitympanic recess (Fig 1A) and 39 had several small cells (Fig 1B). In 25 pairs (50%), the anterior epitympanic recess was composed of a solitary cell bilaterally; 14 pairs (28%) had multiple cells bilaterally; and 11 pairs (22%) had a single cell on one side and multiple cells on the other.

The average measurement of the single-celled anterior epitympanic recess was 3.3 mm with a range of 1.0 to 5.5 mm in the anteroposterior dimension, and 3.4 mm with a range of 1.0 to 7.0 mm in the transverse dimension.

A wide variety of pathologic processes may affect the appearance of the anterior epitympanic recess. Those we encountered include a facial nerve schwannoma, hemangioma of the facial nerve canal, persistent stapedial artery, and congenital, acquired, and recurrent cholesteatoma formation. Diagnosis of persistent stapedial artery was based on the criteria described by Guinto et al (11). The diagnosis of the other lesions were verified by surgical and pathologic findings.

Discussion

Different names have been given to the air-filled anatomic structure anterior to the head of the malleus. Proctor (5), in his classic discussion of the development of the middle ear spaces in 1964, noted an anterior extension of the attic, which he called the *supratubal recess*. Wigand and Trillsch (12) regarded this space as the *sinus epitympani*. Terms like *supratubal recess* (1), *anterior epitympanic compartment* (13), *anterior attic recess* (14), *recessus protympanicum* (15), *anterior epitympanic recess* (2, 16), and *geniculate sinus* (17) have been used synonymously.

Between the third and seventh fetal months, the gelatinous tissue of the middle-ear cleft is gradually absorbed. At the same time, the primitive tympanic cavity develops by a growth into the cleft of an endothelium-lined fluid pouch extending from the eustachian tube (18). The middle ear spaces are formed from four such pouches or sacs (the saccus anticus, saccus medius, saccus superior, and saccus posticus) that bud out from the eustachian tube (18). The attic is formed from the saccus medius, which divides into three saccules, anterior, medial, and posterior. The anterior epitympanum may be formed by either the saccus anticus or more commonly from the anterior saccule of the saccus medius. The anterior saccule of the saccus medius meets the slower growing saccus anticus at the level of the semicanal of the tensor tympani, thus forming the horizontally lined tensor tympani fold. The space thus formed above the tensor fold and anterior to the tensor tendon is the anterior attic compartment (5). Alterna-

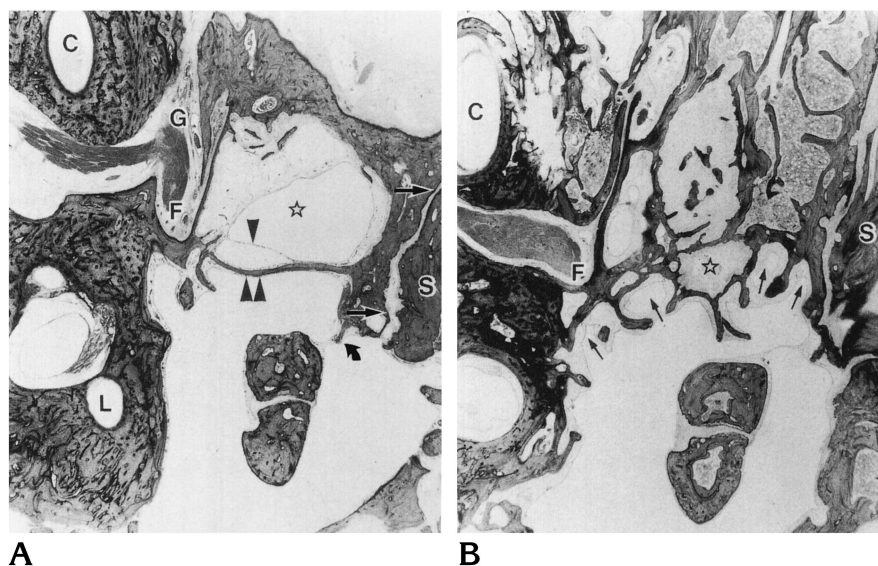


Fig 2. Sections of temporal bone from two 3-year-old children.

A, Dome-shaped supratubal recess (star). Straight arrows indicate the outermost plate of the petrosa; curved arrow, a spur projecting toward the malleolar head, to which is attached a mucosal fold associated with the anterior malleolar ligament; double arrowheads, the anterior attic bony plate; and single arrowhead, a mucosal fold that extends from the tensor tympani tendon and attaches to a part of the anterior attic bony plate.

B, Air cell-shaped supratubal recess (star) surrounded by petrosal air cells (arrows). C indicates the cochlea; G, geniculate fossa; S, squamosa; F, facial nerve; and L, lateral semicircular canal (from Tono et al [3]).

tively, the saccus anticus may occasionally extend upward to the tegmen and as far posteriorly as the superior malleolar fold. In this less common instance, the tensor tympani fold is absent and the anterior epitympanum is in direct continuity with the protympanum and eustachian tube and is termed more appropriately the *supratubal space* (5).

Tono et al (3), studying temporal bones in fetuses and children, found that upward expansion from the bony eustachian tube to form the anterior epitympanic recess begins at a late fetal stage and continues throughout childhood. By contrast, growth of the tympanic cavity, the attic, and the mastoid antrum is virtually complete by birth (2). They also found that the anterior epitympanic recess had already formed in 68% of temporal bones without pneumatization, suggesting that it develops independent of the air cell system.

Tono et al (3) noted two patterns of the anterior epitympanic recess, a single dome-shaped extension of the bony eustachian tube (Fig 2A) and an air cell-shaped anterior epitympanic recess (Fig 2B). The latter pattern, approximately one third as common as the former, is always associated with a well-pneumatized temporal bone and becomes more common with increasing age. The two corresponding patterns, single cell and multiple cell, occurred in a ratio of 3:2 in our predominately adult population. The study by Tono et al indicates that in the air cell-shaped pattern, petrosal cells surround the true anterior epitympanic recess (Fig 2B). CT is not capable of distin-

guishing the multiple small air cells that constitute the anterior epitympanic recess from the small adjacent mastoid air cells. These investigators found side-to-side asymmetry in patterns in only 7% of their cases (3) as compared to 22% in ours.

Hoshino (4) noted that in all of his dissected specimens, a thin bony plate, which he referred to as the anterior attic bony plate, marked the posterior boundary of the anterior epitympanic recess. In our study, we noted that when the anterior epitympanic recess was composed of a solitary air cell, a bony plate consistently separated the space from the attic proper (Fig 1A). House coined, and Sheehy (13) popularized, the term *cog* to refer to this bony ridge that suspends from the tegmen and ends superior to the cochleariform process and anterosuperior to the head of the malleus. The cog probably represents the separation of the anterior saccule of the saccus medius from the remaining saccus medius.

The horizontal tensor tympani fold extends laterally from the semicanal of the tensor tympani muscle to the lateral wall of the protympanum, and reaches anteriorly from the cochleariform process and tensor tympani tendon to the root of the zygoma to form the floor of the anterior epitympanic recess (1, 5). This mucosal fold is not visible on CT scans, but the semicanal of the tensor tympani demarcating its location is routinely seen (Fig 3A). The roof and the anterior wall of the anterior epitympanic recess is formed by the upwardly convex floor of the middle cranial fossa.

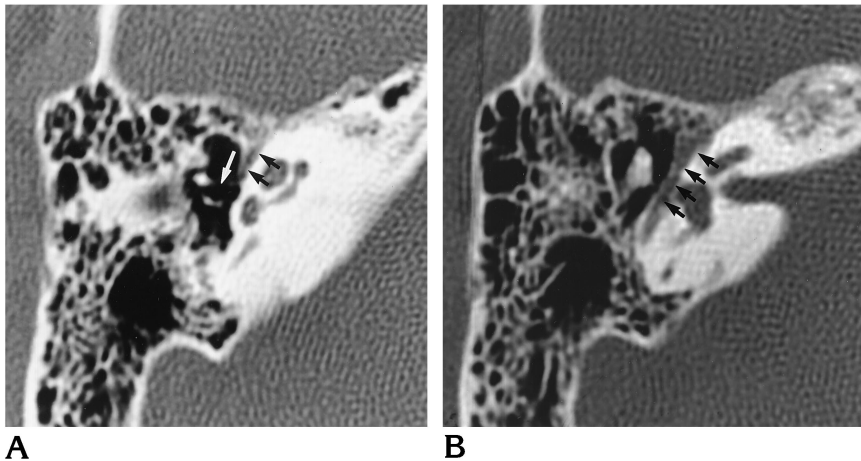


Fig 3. A, Tensor tympani muscle and tendon: axial CT scan shows the tensor tympani muscle (*black arrows*) within its canal. This muscle together with its tendon (*white arrow*) demarcates the floor of the anterior epitympanic recess.

B, Tympanic facial nerve canal: axial CT section 3-mm superior to A shows the tympanic portion of the facial nerve within its canal (*arrows*).

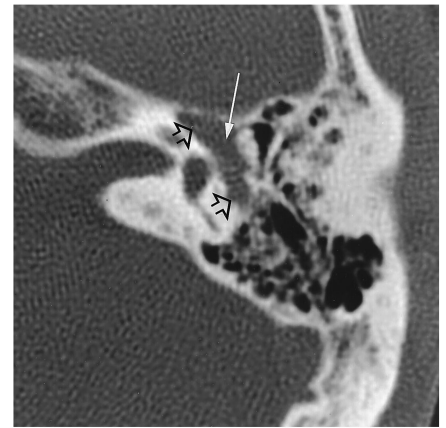


Fig 4. Facial nerve schwannoma: axial CT scan shows smooth enlargement of the tympanic portion of the facial nerve canal (*open arrows*). The tumor invades and fills the anterior epitympanic recess (*long arrow*).

While the carotid canal and the cochlea also lie close together medially, the most important anatomic structures related to the anterior epitympanic recess are the tympanic portion of the facial nerve canal and the geniculate fossa. This portion of the facial nerve canal lies in the medial wall of the anterior epitympanic recess superior to the semicanal of the tensor tympani, which is similarly tubular in appearance. On CT scans, they both are seen routinely (Fig 3A and B). Owing to its intimate relationship with the anterior epitympanic recess, even mild enlargement of the facial nerve canal may fill or deform the anterior epitympanic recess, as in a facial nerve schwannoma (Fig 4) or a small hemangioma of the facial nerve canal at the geniculum.

The persistent stapedial artery is a rare vascular anomaly. Embryologically, the primitive second aortic arch gives rise to the hyoid artery, which in turn gives rise to the stapedial artery. If the stapedial artery fails to involute, the artery courses from the infracochlear carotid through the stapedial obturator foramen and then enlarges the tympanic facial nerve canal en route to the middle fossa to terminate as the middle meningeal artery. Enlargement in the proximal tympanic segment of the facial nerve canal may encroach upon the adjacent anterior epitympanic recess. CT scans will, in addition, show absence of the ipsilateral foramen spinosum (11) (Fig 5).

Ear surgeons are particularly interested in the

anterior epitympanic recess because of its frequent involvement by cholesteatoma (1, 10). Diseases in the anterior epitympanic recess region may call for a middle fossa craniotomy approach to the middle ear rather than the more commonly used transmastoid approach (1). An atticochlear cholesteatoma may extend anteromedially into the anterior epitympanic recess eroding the cog in the process. (Fig 6). Chu and Jackler (9) reported five cases of facial palsy caused by attic cholesteatoma extending anteromedially to the head of the malleus and compressing the facial nerve in the region of the geniculate ganglion. A cholesteatoma found behind an intact tympanic membrane in a patient with no history of otitis media is presumed to be congenital (19, 20). The common sites of origin within the middle ear include the anterior epitympanic recess, the anterior mesotympanum, and the vicinity of the incudostapedial articulation (21). Those arising in the anterior epitympanic recess may erode the facial nerve canal. Besides congenital and acquired cholesteatomas, the anterior epitympanic recess may also be a site of recurrent cholesteatoma formation (Fig 7).

Our study shows that the anterior epitympanic recess is an anatomic structure that is consistently identified on high-resolution CT scans. It is more often single celled than multicelled, and is usually symmetric in appearance. The anterior epitympanic recess is readily deformed by pathologic processes in the anterior

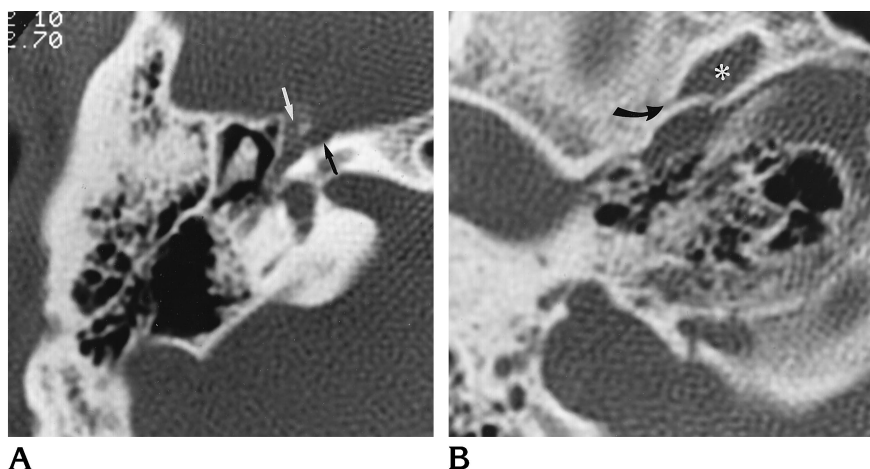


Fig 5. Persistent stapedial artery.
 A, Axial CT scan shows Y-shaped enlargement of the geniculate fossa and deformity of the anterior epitympanic recess by the persistent stapedial artery en route to the middle fossa to become the middle meningeal artery (*white arrow*). *Black arrow* demarcates the canal for the greater superficial petrosal nerve.
 B, Axial CT scan at a lower level reveals the absent foramen spinosum (*arrow*). *Asterisk* indicates the foramen ovale.

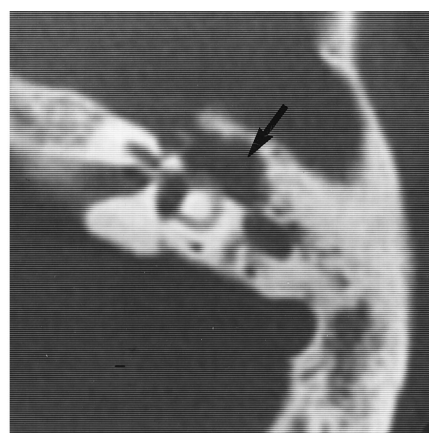


Fig 6. Acquired atticotympanic cholesteatoma. Axial CT scan shows a soft-tissue mass within the left attic extending anteriorly to involve the anterior epitympanic recess and eroding the cog and the ossicles (*arrow*).

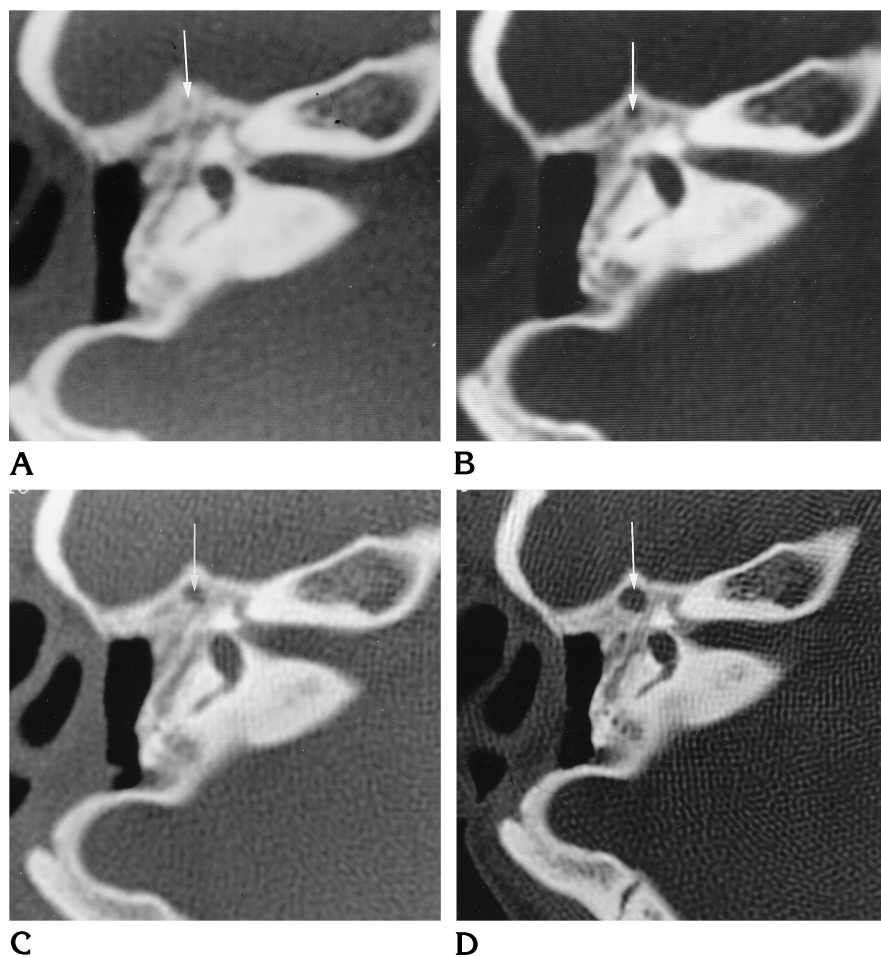


Fig 7. Recurrent cholesteatoma. High-resolution CT scans obtained over a 4-year period show progressive, smooth enlargement of the anterior epitympanic recess (*arrow*) in a patient with a prior radical mastoidectomy. *A*, One year after mastoidectomy; *B*, 2 years after mastoidectomy; *C*, 3 years after mastoidectomy; *D*, 4 years after mastoidectomy. Any of the images if viewed in isolation might suggest a fluid-filled anterior epitympanic recess rather than a mass lesion.

epitympanum or the geniculate region. Familiarity with the CT appearance of this space facilitates recognition of its early pathologic changes.

References

- Horn KL, Brackman DE, Luxford WM, Shea JJ III. The supratubal recess in cholesteatoma surgery. *Ann Otol Rhinol Laryngol* 1986; 95:12-15
- Schucknecht HF, Gulya AJ. *Anatomy of the Temporal Bone with Surgical Implications*. Philadelphia, Pa: Lea & Febiger; 1986:89-90
- Tono T, Schachern PA, Morizono T, Paparella MM, Morimitsu T. Developmental anatomy of the supratubal recess in temporal bones from fetuses and children. *Am J Otol* 1996;17:99-107
- Hoshino T. Surgical anatomy of the anterior epitympanic space. *Arch Otolaryngol Head Neck Surg* 1988;114:1143-1145
- Proctor B. The development of the middle ear spaces and their surgical significance. *J Laryngol Otol* 1964;78:631-648
- Valvassori GE, Buckingham RA. Serial CT sections of temporal bone anatomy In: Valvassori GE, Mafee MF, Carter BL, eds. *Imaging of the Head and Neck*. New York, NY: Thieme; 1995:4-30
- Swartz JD, Harnsberger HR. The middle ear and mastoid. In: Swartz JD, Harnsberger HR, eds. *Imaging of the Temporal Bone*. New York, NY: Thieme; 1994:48-62
- Veillon F, Block P, Vasquez B. Radio-anatomie de l'os temporal bone normal. In: Veillon F, ed. *Imagerie De L'oreille*. Paris, France: Flammarion Medicine-Sciences; 1991:21-59
- Chu FWK, Jackler RK. Anterior epitympanic cholesteatoma with facial paralysis: a characteristic growth pattern. *Laryngoscope* 1988;98:274-279
- Collins ME, Coker NJ, Igarashi M. Inflammatory disease of the anterior epitympanum. *Am J Otol* 1991;12:11-15
- Guinto FC Jr, Garrabrant EC, Radcliffe WB. Radiology of the persistent stapedial artery. *Radiology* 1972;105:365-369
- Wigand ME, Trillsch K. Surgical anatomy of the sinus epitympani. *Ann Otol Rhinol Laryngol* 1973;82:378-383
- Sheehy JL. The facial nerve in surgery of chronic otitis media. *Otolaryngol Clin North Am* 1974;7:483-503
- Hawke M, Farkashidy J, Jahn AF. Nonlamellar new bone formation in the anterior attic recess. *Arch Otolaryngol* 1975;101:117-119
- Wullstein SR. Osteoplastic epitympanotomy: tympanoplasty types I, II, III: a review of 15 years experience. *Am J Otol* 1985; 6:5-89
- Yamasoba T, Harada T, Nomura Y. Observations of the anterior epitympanic recess in the human temporal bone. *Arch Otolaryngol Head Neck Surg* 1990;116:566-570
- Proctor B. *Surgical Anatomy of the Ear and Temporal Bone*. New York, NY: Thieme; 1989, 46-49
- Hammar JA. Studien Uper Die Entwicklung Des Vorderdarms und Einiger Angrenzenden Organe. *Arch Mikroskop Anat* 1902;59: 471-628
- Cawthorne T. Congenital cholesteatoma. *Arch Otolaryngol* 1963; 78:248-252
- Peron DL, Shucknecht HF. Congenital cholesteatoma and other anomalies. *Arch Otolaryngol* 1975;101:498-505
- Ruedi L. Acquired cholesteatoma. *Arch Otolaryngol* 1963;78: 252-261