

Coexistence of Occult Vascular Malformations and Developmental Venous Anomalies in the Central Nervous System: MR Evaluation

Toshi Abe, Robert J. Singer, Michael P. Marks, Alexander M. Norbash, Rebecca S. Crowley, and Gary K. Steinberg

PURPOSE: We sought to determine the prevalence of coexistent occult vascular malformations (OVMs) and developmental venous anomalies (DVAs) and to investigate the relationship between them.

METHODS: One hundred two patients with OVMs were examined with precontrast and postcontrast T1-weighted MR imaging and with noncontrast T2-weighted MR imaging. Seventy-two patients had surgery, with subsequent pathologic confirmation of the final diagnosis.

RESULTS: Coexistent DVAs and OVMs were present in 23 (23%) of 102 patients. Seventy-nine patients had OVMs without DVAs, and in this population, multiple OVMs (from two to 10 or more) were seen in 13 patients (16%). In contrast, multiple OVMs were seen in 10 (43%) of 23 patients with coexisting OVMs and DVAs. Twenty-five (83%) of 30 OVMs coexisting with DVAs were infratentorial. In 72 patients with surgically resected OVMs, 49 (68%) had pathologically confirmed cavernous malformations. Among the patients with coexistent DVAs, seven (46%) had cavernous malformations, four (27%) had thrombosed arteriovenous malformations, and four (27%) had vascular malformations that were not classifiable.

CONCLUSION: Our study revealed a high prevalence of OVMs with coexistent DVAs, and a high percentage of these were in the posterior fossa. Contrast-enhanced MR imaging may increase the probability of finding these lesions, and therefore should be considered part of the preoperative evaluation, since the finding of unexpected coexistent lesions may affect surgical management.

Vascular malformations in the central nervous system have traditionally been classified into four categories: arteriovenous malformations (AVMs), capillary malformations (telangiectasia), venous malformations, and cavernous malformations (1, 2). However, this classification scheme does not always accommodate the histopathologic findings. A number of terms have been used to describe the histopathology of cavernous malformations; these entities are referred to chiefly as *cavernous angiomas*, *cavernous hemangiomas*, *cavernomas*, *angiographically occult*

vascular malformations, *occult cerebrovascular malformations*, and *occult vascular malformations (OVMs)*. Similarly, venous angiomas have been known by a variety of terms, including *venous malformations*, *medullary venous malformations*, and, more recently, *developmental venous anomalies (DVAs)* (3, 4). We use *OVM* and *DVA*, respectively, to describe these lesions. Recently, clinical and pathologic attention has been paid to the multiplicity and coexistence of the four described categories of vascular malformations of the brain (3-15), including the two entities evaluated in this study. We undertook this work to determine the prevalence of coexistent DVAs and OVMs, to investigate the relationship between them, and to document their magnetic resonance (MR) imaging features.

Methods

We retrospectively reviewed the medical records and diagnostic images of 184 patients with OVMs who were examined between 1985 and 1996. The patient database was obtained from two institutions. One hundred two patients (55 female and 47 male; 2 to 77 years old [mean age, 36 years] at the time of diagnosis) met the criterion of having complete MR studies

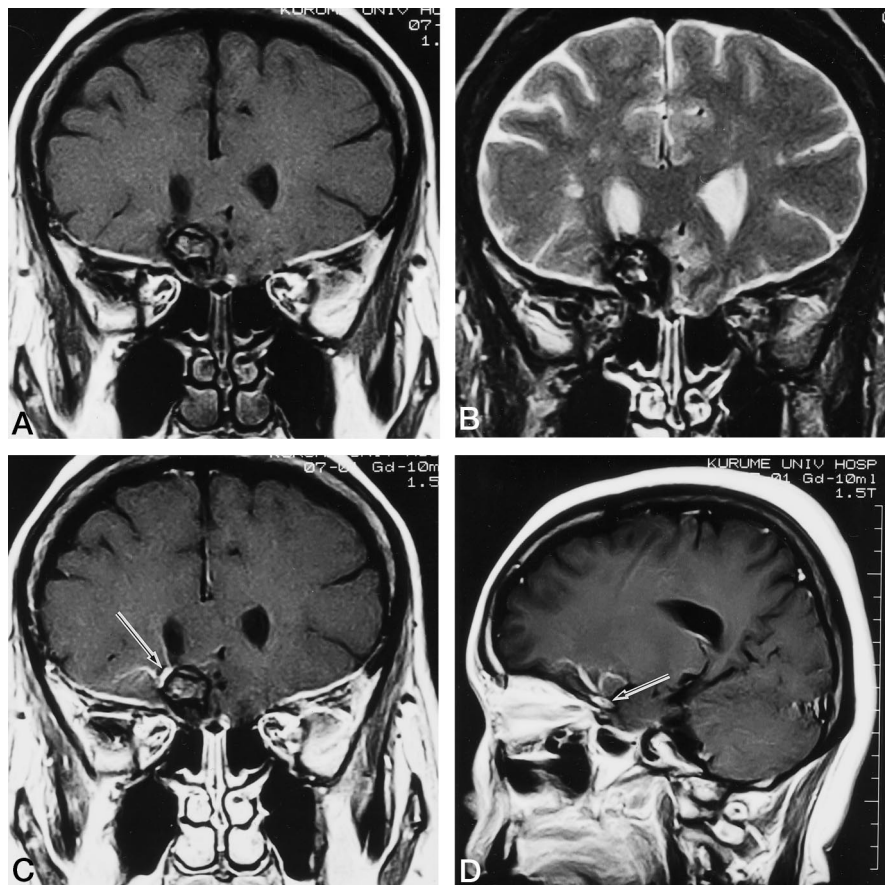
Received October 25, 1996; accepted after revision June 9, 1997.

Presented at the annual meeting of the American Society of Neuroradiology, Seattle, Wash, June 1996.

From the Department of Radiology, Kurume University School of Medicine, Fukuoka, Japan (T.A.), and the Departments of Radiology (T.A., R.J.S., M.P.M., A.M.N.), Pathology (R.S.C.), and Neurosurgery (G.K.S), Stanford University Medical Center, Palo Alto, Calif.

Address reprint requests to Toshi Abe, MD, Department of Radiology, Kurume University School of Medicine, 67 Asahimachi, Kurume, Fukuoka, 830, Japan.

FIG 1. Coronal T1-weighted (600/26/2 [repetition time/echo time/excitations]) (A) and T2-weighted (2500/90/1) (B) MR images show mixed signal intensity surrounded by a hypointense rim in the right frontal lobe. After administration of contrast material, adjoining linear enhancement is shown corresponding to dilated medullary and collecting veins (arrow) on coronal (C) and sagittal (D) images. In this particular example, the OVM is located in the territory of the DVA.



available, including noncontrast T1- and T2-weighted sequences and contrast-enhanced T1-weighted sequences. MR examinations were performed on 0.5-T (seven studies), 1.0-T (three studies), or 1.5-T (92 studies) units.

MR images were evaluated independently by three senior neuroradiologists and included determinations of lesion size, location, venous drainage pattern, and coexistence of associated lesions. Seventy-two patients in this series underwent surgery. In instances where relevant surgical specimens were available, they were reviewed for confirmation of the final diagnosis.

Results

A total of 126 OVMs were found in the 102 patients. OVMs were separated into three groups: group 1, OVM without DVA (89 lesions); group 2, OVM adjoining or in the vascular territory of a visible DVA (30 lesions) (Fig 1); and group 3, OVM distant from or outside the vascular territory of a visible DVA (seven lesions) (Fig 2). In all, 23 (23%) of 102 patients with OVMs had DVAs that were detected on contrast-enhanced T1-weighted images. In 11 of 23 patients with DVAs, these lesions were confirmed angiographically. Two of 23 patients had two DVAs in different vascular territories.

In the total patient population, 23 (23%) had multiple OVMs. In 23 patients (23%), OVMs were found coexisting with DVAs, and among these patients, 10 (43%) had multiple OVMs (Table 1). Table 2 summarizes the data regarding the location of all the OVMs. Overall, 79 (63%) of the OVMs were supra-

tentorial and 47 (37%) were infratentorial. Alternatively, in the population with coexisting DVAs and OVMs, 25 (83%) of the OVMs were located in the infratentorial compartment.

Surgically obtained specimens were available in 72 patients. Histopathologic analysis confirmed that the OVM was a cavernous malformation in 49 patients. A combined cavernous malformation and AVM were found in one patient, and thrombosed AVMs were found in five patients (Table 3). In seven (14%) of 49 patients with a cavernous malformation, an associated DVA was found, whereas four (80%) of five patients with a thrombosed AVM had an associated DVA. Seventeen patients had a vascular malformation that could not be classified either because of inadequate tissue sample size or surgical artifacts.

The group of 23 patients with coexisting OVMs and DVAs included 13 female and 10 male subjects with a mean age of 38 years. Fifteen (65%) had OVMs in the posterior fossa, and 10 had multiple OVMs. Two DVAs were noted in two patients.

The location of an OVM adjoining a DVA may be categorized on the basis of the OVM's position relative to the venous anatomy of the DVA. The DVA is formed from multiple smaller veins rapidly dearborizing from the classically described caput medusae to an abnormally enlarged collecting vein. For the purpose of our study, the relationship between OVMs and DVAs was categorized as follows: type 1, OVMs in the territory of dilated medullary veins; type 2,

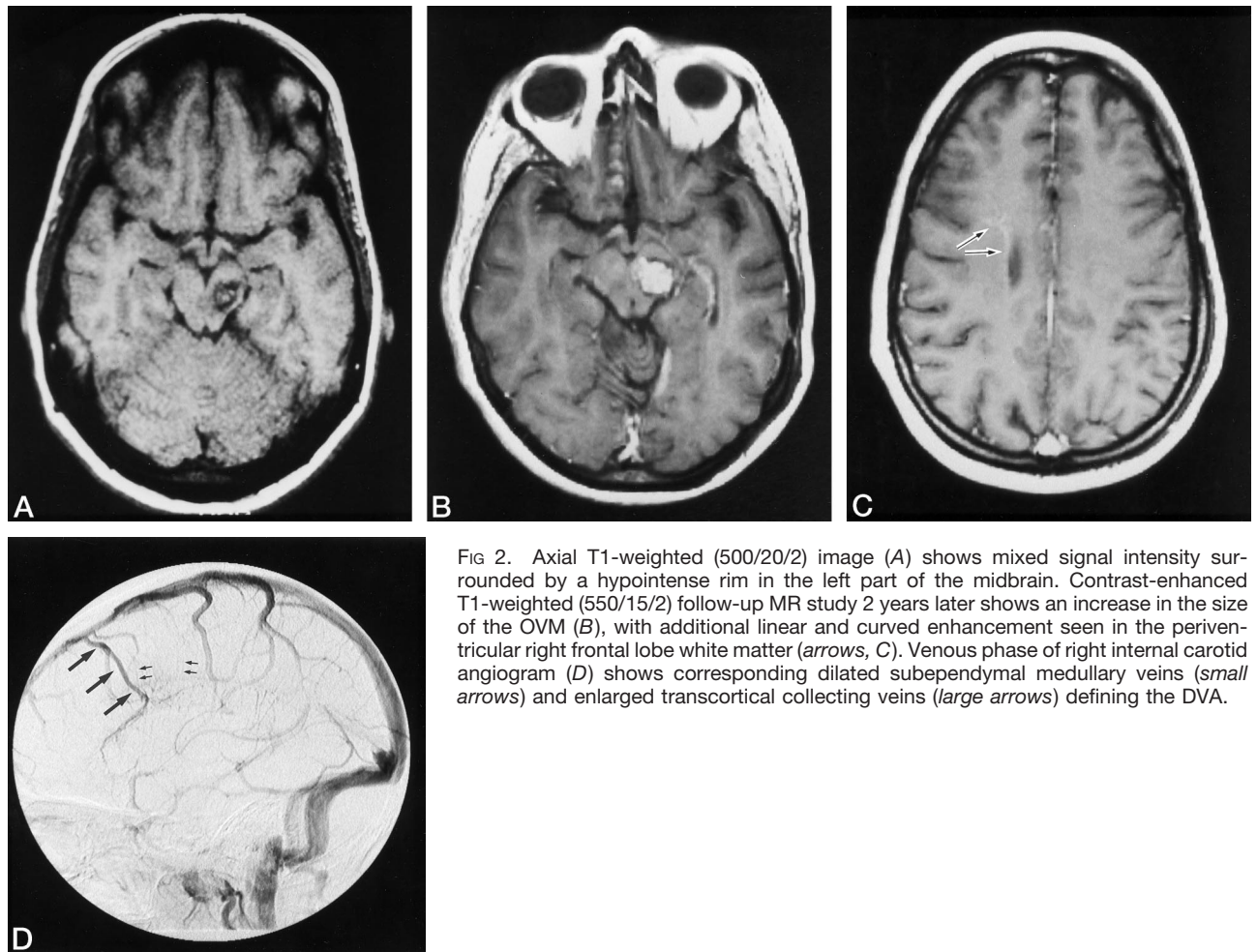


FIG 2. Axial T1-weighted (500/20/2) image (A) shows mixed signal intensity surrounded by a hypointense rim in the left part of the midbrain. Contrast-enhanced T1-weighted (550/15/2) follow-up MR study 2 years later shows an increase in the size of the OVM (B), with additional linear and curved enhancement seen in the periventricular right frontal lobe white matter (arrows, C). Venous phase of right internal carotid angiogram (D) shows corresponding dilated subependymal medullary veins (small arrows) and enlarged transcortical collecting veins (large arrows) defining the DVA.

TABLE 1: Multiplicity of OVMs (n = 102 patients)

No. of OVMs	OVM	OVM + DVA	Total
1	66 (84%)	13 (57%)	79 (77%)
2	6	6	12
3	1	4	5
4	1 (16%)	0 (43%)	1 (23%)
5	1	0	1
10 or more	4	0	4
Total	79 (100%)	23 (100%)	102 (100%)

Note.—OVM indicates occult vascular malformation; OVM + DVA, OVM coexistent with developmental venous anomaly.

OVMs adjacent to a collecting vein; type 3, OVMs in the junction between medullary and collecting veins; and type 4, no relation between the location of the OVM and that of the DVA or its direct drainage. Thirty OVMs in 18 patients existed in the vascular territory of a DVA. Twelve (33%) of the OVMs/DVAs had a type 1 relationship, six (16%) had a type 2 relationship, 12 (33%) had a type 3 relationship, and seven (22%) had a type 4 relationship.

Twenty-one of 25 DVAs had a single distribution of dilated medullary veins. Four patients, all with multiple OVMs, had medullary veins in the brain stem

TABLE 2: Location of OVMs (n = 126 lesions)

Location	OVM (Group 1)	OVM + DVA (Group 2)	OVM + DVA (Group 3)	Total
Frontal lobe	19	2	0	21
Temporal lobe	16	1	2	19
Parietal lobe	14	0	2	16
Occipital lobe	7	0	0	7
Basal ganglia	7	2	0	9
Thalamus	6	0	1	7
Brain stem	19	13	2	34
Cerebellum	1	12	0	13
Total	89 (100%)	30 (100%)	7 (100%)	126 (100%)

Note.—OVM indicates occult vascular malformation; OVM + DVA, OVM coexistent with developmental venous anomaly.

and cerebellum (Fig 3). In the 15 patients with DVAs in the posterior fossa (Fig 4), the collecting veins were as follows: lateral transpontine vein (n = 4, 27%); vein of the lateral recess of the fourth ventricle (n = 3, 20%); anterior transpontine vein (n = 3, 20%); and precentral cerebellar vein (n = 3, 20%).

Discussion

MR imaging is considered the most sensitive and specific method of detecting OVMs (9, 16–21). Typical MR findings of an OVM include well-demarcated areas of mixed signal intensities with a hypointense rim on T1- and T2-weighted studies (9, 16). Fol-

low-up MR studies of OVMs have shown temporal changes in size and signal characteristics (22). Ordinarily, it is not considered necessary to obtain a contrast-enhanced MR study to detect and diagnose OVMs, although DVAs are seen much more easily after contrast enhancement. DVAs can be missed on unenhanced MR images as a result of slow venous blood flow and the low volume of blood. Contrast material helps delineate the dilated medullary veins and the venous drainage pattern of these lesions (23–26). To maximize our sensitivity in diagnosing DVAs, we included in our study only patients in whom contrast-enhanced sequences had been obtained.

Previous reports have documented clinical and imaging characteristics of mixed vascular malformations. Barr et al (27) reported that eight of 12 telangiectatic vascular malformations in the pons had a visible vessel, and one of the 12 patients in the same series had a cavernous malformation. These authors concluded that enhancing pontine lesions with minimal or no signal abnormality on T2-weighted images

TABLE 3: Pathologic findings in OVMs (n = 72 patients)

Pathologic Diagnosis	OVM	OVM + DVA	Total
CM	42	7	49
VM	13	4	17
AVM	1	4	5
CM + AVM	1	0	1
Total	57	15	72

Note.—OVM indicates occult vascular malformation; OVM + DVA, OVM coexistent with developmental venous anomaly; CM = cavernous malformation; AVM, arteriovenous malformation; and VM, vascular malformation that could not be classified.

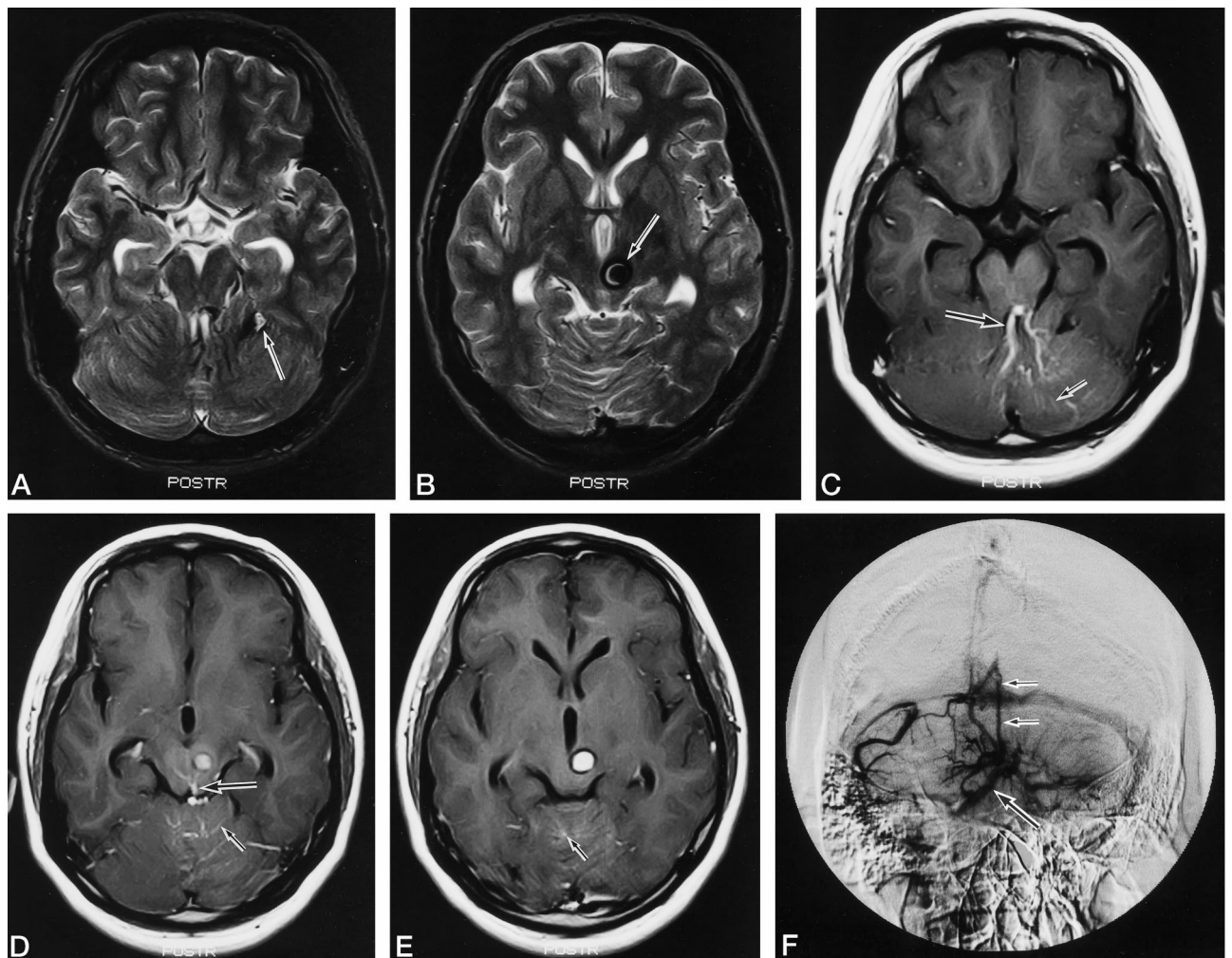


FIG 3. A and B, Axial T2-weighted images (4500/112/1) show OVMs in the left cerebellar hemisphere (arrow, A) and the midbrain (arrow, B). C–E, Contrast-enhanced T1-weighted images (550/15/2) show dilated medullary veins (small arrow) and collecting veins (large arrow) in the midbrain and both cerebellar hemispheres. F, Venous phase of left vertebral angiogram shows a paucity of cortical veins in the cerebellar hemisphere in addition to dilated medullary veins in the brain stem and both cerebellar hemispheres. One of the collecting veins is the contralateral lateral transpontine vein (large arrow), the other is the precentral cerebellar vein (small arrows).

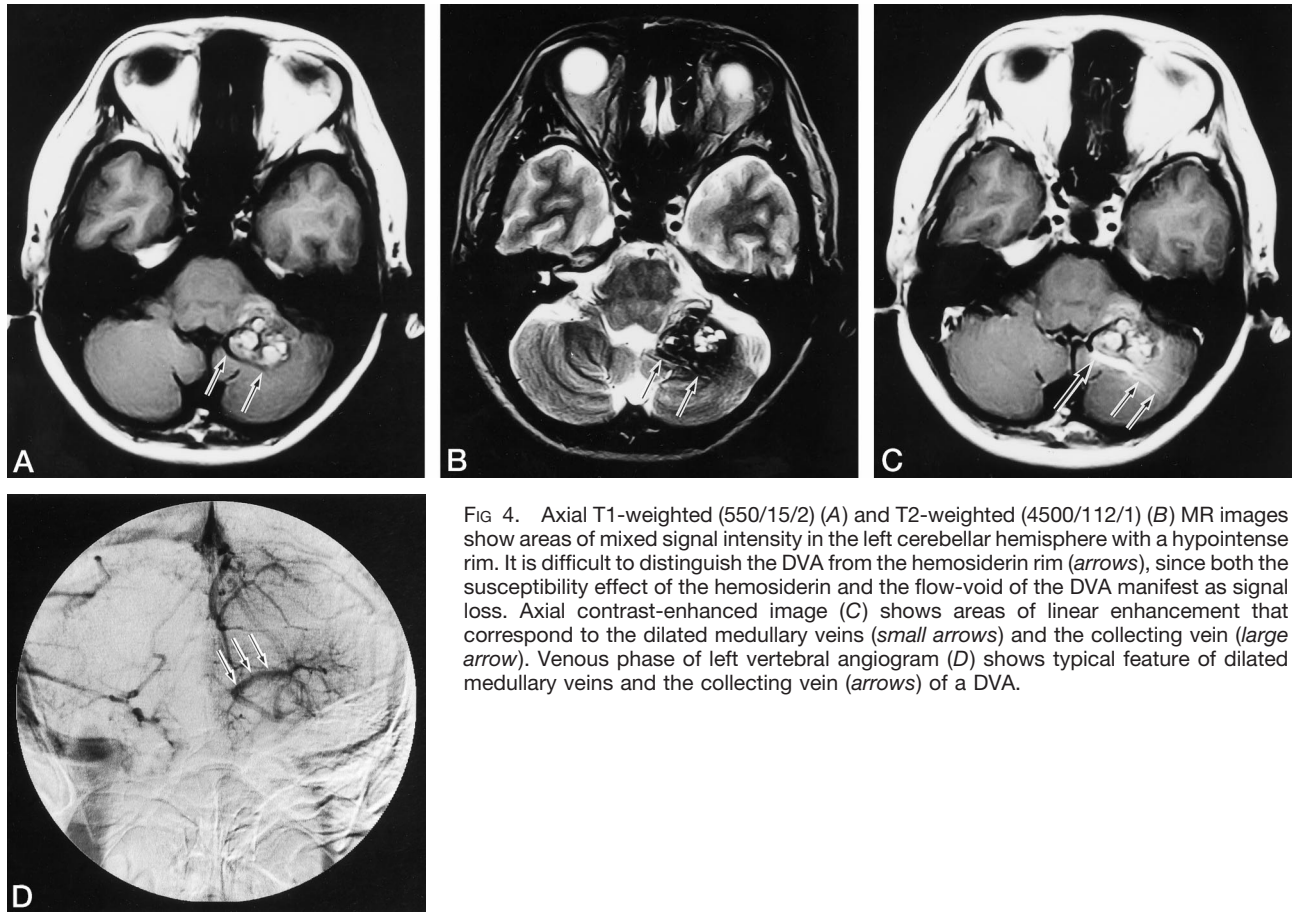


FIG 4. Axial T1-weighted (550/15/2) (A) and T2-weighted (4500/112/1) (B) MR images show areas of mixed signal intensity in the left cerebellar hemisphere with a hypointense rim. It is difficult to distinguish the DVA from the hemosiderin rim (arrows), since both the susceptibility effect of the hemosiderin and the flow-void of the DVA manifest as signal loss. Axial contrast-enhanced image (C) shows areas of linear enhancement that correspond to the dilated medullary veins (small arrows) and the collecting vein (large arrow). Venous phase of left vertebral angiogram (D) shows typical features of dilated medullary veins and the collecting vein (arrows) of a DVA.

are most consistent with capillary telangiectasias or transitional capillary-venous malformations. Rigamonti et al (12) reported finding capillary telangiectasias and transitional lesions at the periphery of cavernous malformations in autopsy series. McCormick et al (13) suggested that elevated venous pressure in DVAs leads to ectasia in an acquired telangiectasia that evolves toward a cavernous malformation. Tomlinson et al (14) reported that histologically cavernous malformations are the most common form of vascular anomaly, with most lesions showing a partially racemose architecture. Finally, MR findings of radiation-induced telangiectasia have been reported to be similar in appearance to OVMs (28). In our series, 17 of 72 resected OVMs were diagnosed as unclassified vascular malformations, reflecting previously reported and ongoing difficulties in diagnosing OVM subtypes (11, 13, 15).

The association of cavernous malformations or OVMs with DVAs, as based on radiologic and pathologic characteristics, has been reported previously (4–11, 23, 29–34). The reported frequency of this coexistence, ranging from 2% to 29%, varies with lesion location and imaging technique (4, 5, 8, 9, 17, 23, 31, 32, 35). We found a 23% rate of occurrence of coexistent lesions by using unenhanced and contrast-enhanced MR imaging, confirming the need to search closely for otherwise unsuspected coexistent lesions in patients with OVMs.

In our coexistent DVA/OVM population, the frequency of pathologically confirmed cavernous malformation was 16% (8/49). After excluding the five patients in whom an OVM was found in an unrelated location relative to the DVA, the frequency of pathologically confirmed cavernous malformations was 18%. In 14 of the 18 patients with coexistent DVA/OVM, the lesions were located in the posterior fossa. Eight (57%) of these 14 patients had multiple OVMs, all in the posterior fossa. Overall, 25 (83%) of 30 type 2 OVMs were located in the posterior fossa. Isolated DVAs have been shown elsewhere to have a 56% to 83% supratentorial predominance (7, 24–26, 36); similarly, supratentorial cavernous malformations without any coexisting vascular lesions have been shown to represent 64% to 86% of the total number (9, 16, 17, 37–41). Our series demonstrated a high relative prevalence of coexisting lesions in the posterior fossa.

Considerable controversy exists as to the relationship of DVAs and hemorrhage and the risk of bleeding from the DVA itself. It has been suggested that the majority of hemorrhagic changes found in DVA territories are attributed to associated OVMs (4, 8, 13, 35). Some reports separately attribute DVA-associated hemorrhage to thrombosis or stenosis of central venous drainage, leading to a transient increase in the pressure within the draining veins and thereby increasing the potential of venous hemorrhage (33,

42–44). Many unanswered questions remain concerning the hemorrhagic risk of isolated DVAs and the physiological basis and anatomic source of hemorrhage when it coexists with an OVM. Further clinical, neuroradiologic, and pathophysiological information will be necessary to clarify this issue.

It is currently agreed in the surgical literature that accessible symptomatic OVMs should be resected. The current established indications for surgical management are overt hemorrhage, focal neurologic symptoms, and/or medically intractable epilepsy (45). Alternatively, DVA resection is not considered a customary procedure. DVAs ordinarily, at least in part, drain normal brain tissue; therefore, resection of DVAs can lead to major neurologic complications if pathways of venous egress are removed (4, 17, 31, 36, 46, 47). Parenchymal evaluation with contrast-enhanced MR imaging has a high likelihood of identifying an associated DVA and is therefore indispensable in establishing a complete diagnosis before surgery. Seventy-nine percent of patients in our series had medullary or junctional venous drainage of DVAs directly associated with an OVM.

Conclusion

Our series disclosed a high prevalence of OVMs with coexistent DVAs. The association seems highest in the posterior fossa and with OVMs that prove pathologically to be either thrombosed AVMs or unclassified vascular malformations. Contrast-enhanced MR imaging greatly improves the evaluation of coexistent DVAs, and its use is recommended, particularly in preoperative examinations, since the detection of coexistent lesions may alter surgical decisions.

Acknowledgments

We are grateful Drs Kazuyuki Kojima, Norimitsu Tanaka, and Kiminori Fujimoto and Mary Marcellus for helpful advice and discussions. We thank Ann Hidalgo, Etsuko Kodama, and Satoko Kuribayashi for providing secretarial support.

References

- Russel D, Rubenstein L. **Tumors and hamartomas of the blood vessels.** In: *The Pathology of Tumors of Nervous System*. 4th ed. London, England: Edward Arnold; 1977:126–145
- McCormick WF, Boulter TR. **Vascular malformations (angiomas) of the dura matter.** *J Neurosurg* 1966;25:309–311
- Lasjaunias P, Burrows P, Planet C. **Developmental venous anomalies (DVA): the so-called venous angioma.** *Neurosurg Rev* 1986;9:233–244
- Goulao A, Alvarez H, Garcia Monaco R, Rruvost P, Lasjaunias P. **Venous anomalies and abnormalities of the posterior fossa.** *Neuroradiology* 1990;31:476–482
- Awad IA, Robinson JR, Mohanty S, Estes ML. **Mixed vascular malformations of the brain: clinical and pathogenetic considerations.** *Neurosurgery* 1993;33:179–188
- Sasaki O, Tanaka R, Koike T, Koide A, Koizumi T, Ogawa H. **Excision of cavernous angioma with preservation of coexisting venous angioma: case report.** *J Neurosurg* 1991;75:461–464
- Garner TB, Del Curling O, Kelly DL, Kaster DY. **The natural history of intracranial venous angioma.** *J Neurosurg* 1991;75:715–722
- Rigamonti D, Spetzler RF. **The association of venous and cavernous malformations: report of four cases and discussion of the pathophysiological, diagnostic and therapeutic implications.** *Acta Neurochir (Wien)* 1988;92:100–105
- Robinson JR, Awad IA, LITTLE JR. **Natural history of the cavernous angioma.** *J Neurosurg* 1991;75:709–714
- Ciricillo SF, Dillon WP, Fink ME, Edwards MS. **Progression of multiple cryptic vascular malformations associated with anomalous venous drainage.** *J Neurosurg* 1994;81:477–481
- Papacki TFX, Brantley MJ, Furlow TW, Geyer CA, Toro VE, George EG. **Heterogeneity of cerebral cavernous hemangiomas diagnosed by MR imaging.** *J Comput Assist Tomogr* 1990;14:18–25
- Rigamonti D, Johnson PC, Spetzler, Hadley MN, Drayer BP. **Cavernous malformations and capillary telangiectasia: a spectrum within a single pathological entity.** *Neurosurgery* 1991;28:60–64
- McCormick PW, Spetzler RF, Johnson PC, Drayer BP. **Cerebellar hemorrhage associated with capillary telangiectasia and venous angioma.** *Surg Neurol* 1993;34:792–799
- Tomlinson FH, Wayne Houser O, Scheithauer BW, Sundt TM, Okazaki H, Parisi JE. **Angiographically occult vascular malformations: a correlative study of features on magnetic resonance imaging and histological examination.** *Neurosurgery* 1994;34:792–799
- Robinson JR, Awad IA, Masaryk TJ, Estes M. **Pathological heterogeneity of angiographically occult vascular malformations of the brain.** *Neurosurgery* 1993;33:547–554
- Del Curling O, Kelly DL, Elster AD, Craven TE. **An analysis of the natural history of cavernous angiomas.** *J Neurosurg* 1982;75:702–708
- Bartalanffy H, Gilsbach JM, Eggert HR, Seeger W. **Microsurgery of deep-seated cavernous angiomas: report of 26 cases.** *Acta Neurochir (Wien)* 1991;108:91–99
- Gomori JM, Grossman RJ, Goldberg HI, et al. **Occult cerebral vascular malformations: high-field MR imaging.** *Radiology* 1986;158:707–713
- Lemme-Plaghos L, Kucharczyk W, Brant-Zawadzki M, et al. **MRI of angiographically occult vascular malformations.** *AJR Am J Roentgenol* 1986;146:1223–1228
- New PFJ, Ojemann RG, Davis KR, et al. **MR and CT of occult vascular malformations of the brain.** *AJNR Am J Neuroradiol* 1986;7:771–779
- Rigamonti D, Drayer BP, Johnson PC, Hadley MN, Zabramski J, Spetzler RF. **The MRI appearance of cavernous malformations (angioma).** *J Neurosurg* 1987;67:518–524
- Sigal R, Krief O, Houtteville JP, Halimi P, Doyon D, Pariente D. **Occult cerebrovascular malformations: follow-up with MR imaging.** *Radiology* 1990;176:815–819
- Crecco M, Flosis R, Vidiri A, et al. **Venous angioma: plain and contrast enhanced MRI and MR angiography.** *Neuroradiology* 1995;37:20–24
- Wilms G, Demaerel P, Marchal G, Albert M, Baert L, Plets C. **Gadolinium-enhanced MR imaging of cerebral venous angiomas with emphasis in their drainage.** *J Comput Assist Tomogr* 1991;15:199–206
- Wilms G, Marchal G, VanHecke P, Van Fraeyenhoven L, Decrop E, Baert AL. **Cerebral venous angiomas.** *Neuroradiology* 1990;32:81–85
- Lee C, Pennington A, Kenney CK. **MR evaluation of developmental venous anomalies: medullary venous anatomy of venous angiomas.** *AJNR Am J Neuroradiol* 1996;17:61–70
- Barr RM, Dillon WP, Wilson CB. **Slow-flow vascular malformations in the pons: capillary telangiectasias?** *AJNR Am J Neuroradiol* 1996;17:71–78
- Gaensler EH, Dillon WP, Edward MB, Larson DA, Rosenau W, Wilson CB. **Radiation-induced telangiectasia in the brain simulates cryptic vascular malformations at MR imaging.** *Radiology* 1994;193:629–636
- Roberson GM, Kase CS, Wolpow ER. **Telangiectases and cavernous angioma of the brainstem: "cryptic" vascular malformations: report of a case.** *Neuroradiology* 1974;8:83–89
- Diamond C, Torvik A, Amundsen P. **Angiographic diagnosis of telangiectases with cavernous angioma of the posterior fossa: report of a case.** *Neuroradiology* 1974;8:83–
- Zimmerman RS, Spetzler RF, Lee Stuart K, Zabramski JM, Hargraves RW. **Cavernous malformation of the brain stem.** *J Neurosurg* 1991;75:32–39
- Symon L, Jackowski A, Bills D. **Surgical treatment of pontomedullary cavernomas.** *Br J Neurosurg* 1991;5:339–347
- Lupret V, Negovetic L, Smiljanic D, Klanfar Z, Lambasa S. **Cerebral venous angiomas: surgery as a mode of treatment for selected cases.** *Acta Neurochir (Wien)* 1993;120:33–39
- Abe M, Asfora WT, DeSalles AF, Kjellberg RN. **Cerebellar venous angioma associated with angiographically occult brain stem vas-**

- cular malformation: report of two cases.** *Surg Neurol* 1990;33:400-403
35. Wilms G, Bleus E, Demaerel P, et al. **Simultaneous occurrence of developmental venous anomalies and cavernous angiomas.** *AJNR Am J Neuroradiol* 1994;15:1247-1254
 36. Huang YP, Robbins A, Patel SC, Chaudhary M. **Cerebral venous malformation.** In: Kapp JP, Schmidek HH, eds. *The Cerebral Venous System and Its Disorders*. New York, NY: Grune & Stratton; 1984:373-474
 37. Hsu F, Rigamonti D, Huhn SL. **Epidemiology of cavernous malformation.** In: Awad IA, Barrow DL, eds. *Cavernous Malformations*. Park Ridge, Ill: American Association of Neurological Surgeons; 1993;13-23
 38. Lonjon M, Roche JL, George B, et al. **Intracranial cavernoma: 30 cases [in French].** *Presse Med* 1993;22:990-994
 39. Sage MR, Brophy BP, Sweeney C, et al. **Cavernous haemangiomas (angiomas) of the brain: clinically significant lesions.** *Australas Radiol* 1993;37:147-155
 40. Giombini S, Morello G. **Cavernous angiomas of the brain: account of fourteen personal cases and review of the literature.** *Acta Neurochir (Wien)* 1978;40:61-82
 41. Lobato R, Perez C, Rivas J, Cordobes F. **Clinical, radiological, and pathological spectrum of angiographically occult intracranial vascular malformations.** *J Neurosurg* 1988;68:518-531
 42. Field LR, Russell E. **Spontaneous hemorrhage from a cerebral venous malformation related to thrombosis of the central draining vein: demonstration with angiography and serial MR.** *AJNR Am J Neuroradiol* 1995;16:1885-1888
 43. Truwit CL. **Venous angioma of the brain: history, significance, and imaging findings.** *AJR Am J Roentgenol* 1992;159:1299-1307
 44. Ostertum B, Solymosi L. **Magnetic resonance angiography of cerebral developmental venous anomalies: its role in differential diagnosis.** *Neuroradiology* 1993;35:97-104
 45. Nozipo Maraire J, Awad IA. **Intracranial cavernous malformations: lesion behavior and management strategies.** *Neurosurgery* 1995;37:591-605
 46. McCormick WF. **Pathology of vascular malformations of the brain.** In: Wilson CB, Stein BM, eds. *Intracranial Arteriovenous Malformations*. Baltimore, Md: Williams & Wilkins; 1984:44-63
 47. Senegor M, Dohrmann GJ, Wollman RL. **Venous angioma of the posterior fossa should be considered as anomalous venous drainage.** *Surg Neurol* 1983;19:26-32