

Hemispheric Language Dominance Studied with Functional MR: Preliminary Study in Healthy Volunteers and Patients with Epilepsy

Bas F. W. van der Kallen, George L. Morris, F. Zerrin Yetkin, Leon J. T. O. van Erning, Henk O. M. Thijssen, and Victor M. Haughton

PURPOSE: We used functional MR imaging to compare hemispheric language dominance in healthy volunteers and in patients with epilepsy.

METHODS: We retrospectively reviewed the functional MR images of 23 healthy volunteers and 16 patients with epilepsy obtained by using an echo-planar technique designed for whole-brain imaging. The activation paradigm used was a silent word generation task. Hemispheric language dominance was assessed as the percentage of activated pixels in the left hemisphere minus the percentage of activated pixels in the right hemisphere $\times 100$.

RESULTS: We found no significant difference in language lateralization between right-handed male and right-handed female volunteers. However, a statistically significant difference in language distribution was found between left- and right-handed female volunteers. The left-handed female volunteers showed a more bilateral hemispheric language lateralization. Language lateralization in right-handed male epilepsy patients with early age at seizure onset and seizure locus in the left temporal lobe was not significantly different from that of healthy right-handed male volunteers. Similarly, we found no difference in language lateralization between right-handed female volunteers and right-handed female epilepsy patients with late age at seizure onset and seizures in the left temporal lobe.

CONCLUSION: Handedness has a significant influence on hemispheric language dominance in healthy volunteers. Sex has no influence on hemispheric language dominance, regardless of the task used to assess such dominance, nor does age at seizure onset influence language lateralization in patients with left temporal lobe epilepsy. Therefore, hemispheric language dominance can be assessed and compared effectively with functional MR imaging.

Many investigators, using mainly Wada testing, have examined hemispheric language dominance (1-9). However, owing to the invasiveness of Wada testing, it is performed only in selected patients to evaluate the risk of damaging language areas during neurosurgical procedures. The advent of functional magnetic resonance (MR) imaging has made it possible to study healthy volunteers noninvasively (10-16). This imaging technique shows signal intensity changes as a result of changes in local deoxyhemoglobin concentration and blood flow (17-19). Functional

MR imaging has been used successfully to map motor, sensory, auditory, and cognitive brain systems (10-12, 17-29).

Differences in language lateralization related to handedness and sex have been reported in studies using Wada testing, functional MR imaging, and magnetoencephalography (4-7, 14-16). These studies found a greater occurrence of right hemispheric language dominance in left-handed subjects than in right-handed subjects. Yet, there have been contradictory results as to the role of gender in hemispheric language dominance. Furthermore, studies have indicated that, owing to neuronal plasticity, language organization in patients with epilepsy can be altered when neuronal damage takes place at an early age (2-7, 30). However, it is unclear whether language areas in the brain shift solely within hemispheres or also across hemispheres. Since, in previous studies, Wada test results were highly correlated with functional MR imaging of language tasks in patients with epilepsy (31, 32), we used functional MR imaging in a

Received February 25, 1997; accepted after revision May 20.

From the Department of Radiology, University Hospital Nijmegen (the Netherlands) (B.F.W.V.D.K., L.J.T.O.V.E., H.O.M.T.); and the Departments of Neurology (G.L.M.) and Radiology (F.Z.Y., V.M.H.), Medical College of Wisconsin, Milwaukee.

Address correspondence to Victor M. Haughton, MD, Department of Radiology, Medical College of Wisconsin, Froedtert Memorial Lutheran Hospital, 9200 W Wisconsin Ave, Milwaukee, WI 53226.

series of healthy volunteers and epilepsy patients in this preliminary study to assess the influence of handedness, sex, and age at seizure onset on hemispheric language dominance.

Methods

Functional MR imaging studies in 23 volunteers and in 16 patients with partial complex epilepsy were reviewed retrospectively. Subjects with a history of neurologic illness and/or head trauma were excluded; three volunteers and two patients were excluded owing to head motion or other imaging artifacts. The selected group of volunteers consisted of 10 women and 10 men between the ages of 20 and 50 years (mean age, 30 years). Five of the women were right-handed and five were left-handed; nine of the men were right-handed and one was left-handed. The patient group consisted of eight women and six men between the ages of 17 and 49 years (mean age, 36 years). Seven of the women were right-handed and one was left-handed; five of the men were right-handed and one was left-handed. All patients were selected from those with partial complex epilepsy documented by electroencephalographic (EEG) split-screen video monitoring. Patients with space-occupying lesions on MR images, computed tomographic scans, or other radiologic images were excluded from the study. Each subject gave written informed consent.

All subjects were examined using a 1.5-T MR unit equipped with a birdcage head coil and a three-axis gradient coil designed for whole-brain echo-planar imaging. Sponges were used in positioning the patients and volunteers to minimize motion, and all subjects were instructed not to move. A series of spin-echo localizer images were obtained in axial, coronal, and sagittal planes. The functional data were acquired with single-shot blipped echo-planar gradient-recalled images at 2-second intervals. With the multisection sequence, 12 to 14 sagittal sections covering the whole brain were acquired. During the acquisition of the echo-planar images, four rest periods were alternated with three periods of silent word generation. Each period had a duration of 20 seconds. The total imaging time was 2 minutes 20 seconds. Echo-planar imaging parameters were 2000/40/1 (repetition time/echo time/excitations), 642 matrix, 24-cm field of view, 10-mm section thickness, and 40-millisecond acquisition time. The acquired images were examined in cine mode to exclude any studies with head motion. The time course of the signal intensity of each pixel over the 70 images was plotted and compared with a reference function by means of a cross-correlation analysis (20, 25). The reference function had a square waveform. The first five images of each rest and task period were excluded from the cross-correlation calculation. Activation was assessed as the pixels that passed a cross-correlation threshold of 0.6 ($P < .0001$, with the number of time points actually used in the cross-correlation analysis). The activated pixels were projected upon the corresponding anatomic images.

For the silent word generation task (12), subjects were instructed to think of as many words as possible beginning with a letter given by the investigator. In each of the three task periods a different letter was given.

The volunteers were stratified by sex and handedness (Table 1). The patients with epilepsy were stratified by sex, handedness, age at seizure onset, and seizure location as determined with EEG (Table 2).

The degree of activation was tabulated as the number of activated pixels in each cortical hemisphere. Hemispheric language dominance is expressed as the lateralization index, which was calculated as the percentage of activated voxels in the left hemisphere minus the percentage of activated voxels in the right hemisphere:

$$1) \quad LI = [VI - Vr] / [VI + Vr] \times 100$$

where LI is lateralization index, VI is left hemisphere, and Vr is right hemisphere. The lateralization index ranges from -100% (strong right-hemisphere dominant) to 100% (strong left-hemisphere dominant). The results for the volunteers and the patients with partial complex epilepsy were tabulated (Tables 1 and 2).

To study the effect of sex on cerebral language distribution, we compared the right-handed male volunteers with the right-handed female volunteers. The relation between handedness and language lateralization was examined by comparing the left-handed with the right-handed female volunteers. The effect of early neuronal damage on language lateralization was studied by comparing the right-handed male volunteers with the right-handed male epilepsy patients with an early age at seizure onset (<5 years) and left temporal lobe seizure location. The right-handed female epilepsy patients with a late age at seizure onset (>11 years) and left temporal lobe seizure location were compared with the right-handed female volunteers. Comparisons of other groups—for example, right-handed with left-handed male volunteers—was not possible because of the limited number of subjects. Student's t test was used to determine significant differences in the average lateralization indexes among the different groups (Tables 3 and 4).

Results

The main areas of cortical activation with the silent word generation task were found in the inferior frontal gyrus and the middle and superior frontal gyri. Other areas with activation included the precentral and postcentral gyri; the supplementary motor area; the inferior, middle, and superior temporal gyri; the supramarginal gyrus; and the anterior cingulate (Fig 1). Activated pixels were also seen in the cerebellum and the thalamus. These latter two areas were not included in the tabulation because of their location outside the cortical hemispheres.

TABLE 1: Volunteer group demographics and lateralization index (LI)

Volunteer	Sex/Age, y	Handedness	LI, %
1	M/24	R	85
2	M/27	R	91
3	M/22	R	92
4	M/28	R	53
5	M/29	R	67
6	M/41	R	71
7	M/23	R	53
8	M/23	R	81
9	M/34	R	86
10	M/24	L	93
11	F/42	R	90
12	F/22	R	87
13	F/34	R	92
14	F/50	R	10
15	F/20	R	41
16	F/36	L	0
17	F/43	L	-29
18	F/22	L	42
19	F/38	L	15
20	F/22	L	29

TABLE 2: Patient demographics and lateralization index (LI)

Patient	Sex/Age, y	Handedness	Seizure Locus		Age at Seizure Onset, y	LI, %
			Hemisphere	Lobe		
1	M/33	R	L	Temporal	4	100
2	M/44	R	L	Temporal	<1	56
3	M/48	R	L	Temporal	2	100
4	M/17	R	L	Temporal	<1	55
5	M/35	R	L	Temporal	5	41
6	M/38	L	R	Temporal	21	56
7	F/49	R	L	Temporal	25	30
8	F/30	R	L	Temporal	11	46
9	F/43	R	L	Temporal	29	100
10	F/40	R	L	Temporal	23	100
11	F/47	R	L	Temporal	15	45
12	F/26	R	R	Temporal	10	53
13	F/20	R	L	Temporal	<1	14
14	F/40	L	L	Frontal	18	-60

TABLE 3: Sex and handedness differences in the volunteers

Volunteers	No. of Subjects	Lateralization Index (SD)	P
Sex			
Right-handed male	9	75 (15)	<.21
Right-handed female	5	64 (37)	
Handedness			
Right-handed female	5	64 (37)	<.02*
Left-handed female	5	11 (27)	

* Significant difference with an unpaired Student's *t* test ($P < .05$).

TABLE 4: Influence of age at seizure onset on the lateralization index (LI) in right-handed subjects

Subject Group	No. of Subjects	LI (SD)	P*
Male epilepsy patients with early seizure onset	5	70 (28)	.33
Male volunteers	9	75 (15)	
Female epilepsy patients with early seizure onset	5	57 (27)	.38
Female volunteers	5	64 (37)	

* Significance of LI differences assessed with Student's *t* test.

Language Dominance Assessed with Functional MR Imaging Using a Silent Word Generation Task

In the volunteer group, the lateralization index ranged from -28% to 93%. In the group of patients with epilepsy, the lateralization index ranged from -60% to 100%. There was no significant difference ($P < .29$) in language lateralization between the patient group (lateralization index, 50%) and the volunteer group (lateralization index, 57%).

In the volunteer group, no difference in language lateralization was found between the right-handed men and the right-handed women (Table 3). Both sexes had a left hemispheric language distribution (right-handed men [$n = 9$] lateralization index, 75%; right-handed women [$n = 5$] lateralization index,

64%; $P < .21$). A significant difference was found in language lateralization between right- and left-handed women. A more bilateral language distribution was found in the left-handed female volunteers (left-handed women [$n = 5$] lateralization index, 11%; right-handed women [$n = 5$] lateralization index, 64%; $P < .02$).

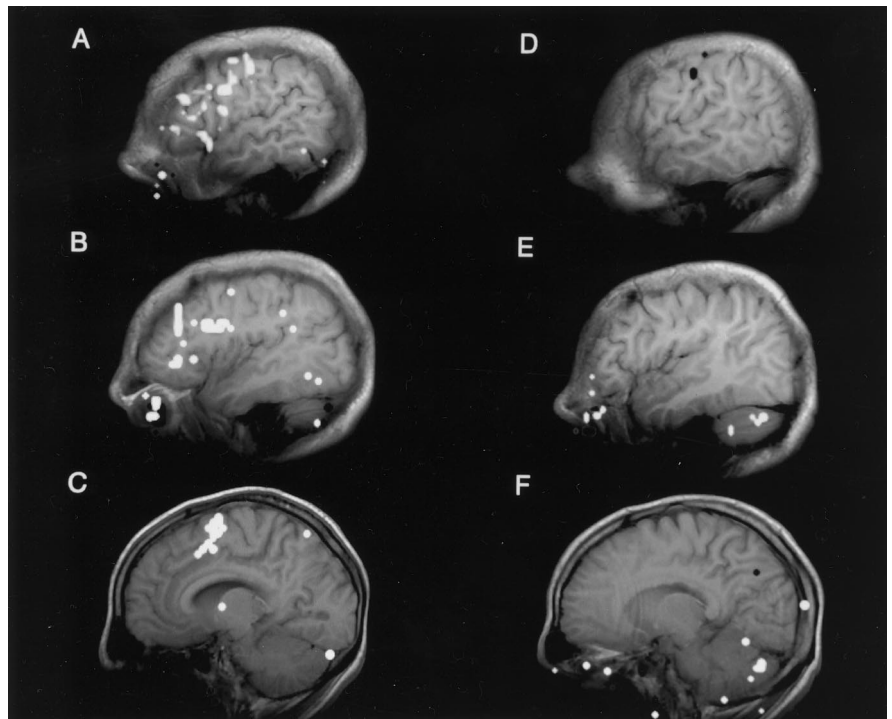
In the comparison of right-handed male epilepsy patients with left temporal lobe seizure locus and early age at seizure onset (< 5 years) (lateralization index, 70%) and right-handed male volunteers (lateralization index 75%), a similar degree of language lateralization was found ($P < .33$). In the comparison of right-handed female epilepsy patients with left temporal lobe seizure locus and late age at seizure onset (> 11 years) (lateralization index, 57%) and right-handed female volunteers (lateralization index 64%), no marked differences in language lateralization was found ($P < .38$) (Table 4).

Discussion

The feasibility of using functional MR imaging in the assessment of language activation has been demonstrated by several investigators (10-13). Our study shows the potential of using functional MR imaging for studying language organization in populations of healthy subjects and patients. In our functional MR imaging study of volunteers and of patients with partial complex epilepsy, functional activation for the language task was seen in regions of the cerebral cortex normally associated with language, and, to a lesser degree, in the sensorimotor cortex, auditory regions, and supplementary motor areas, as shown in previous studies (12). Functional MR imaging successfully showed activation in 14 of 16 patients with epilepsy and in 20 of 23 volunteers. Language mapping in the remaining subjects failed because of motion and susceptibility artifacts. Motion correction programs were not used in the study.

There are limitations to our preliminary study. The small number of subjects narrows the significance of our findings, yet our results are consistent with those

FIG 1. Functional activation maps of a representative volunteer (No. 3) show a strong left-hemisphere-dominant language lateralization. A–C are sagittal images at different levels in the left hemisphere; D–F are sagittal images at different levels in the right hemisphere. Cortical activation is seen in the inferior frontal gyrus, the middle and superior frontal gyri, the precentral and postcentral gyri, the temporal lobe, the supplementary motor area, and the anterior cingulate. Activation is also seen in the thalamus and cerebellum.



of earlier studies. We included only patients with no macroscopic abnormalities on MR images or other radiologic studies. The best paradigm by which to study language lateralization in functional MR imaging has not yet been established. We used the silent word generation task to minimize the chance of motion artifacts (12). Others have obtained similarly good results with semantic language tasks (13, 31, 32).

Our results indicate a relationship between handedness and hemispheric language dominance in healthy volunteers. A markedly stronger left hemispheric language dominance was found in right-handed subjects, which is in accord with earlier studies among clinical populations (2–7, 30). We found no marked sex-related difference in language lateralization. A recent functional MR imaging study showed that, in different language tasks, only a task focused on the phonological component of language (rhyming) produced sex-related differences (23). Therefore, the design of the functional MR imaging experiment plays an important role in the outcome of language dominance.

During the period of early development, an injury or seizure may alter the location or organization of language function (2–7, 30). Our results show that in patients with partial complex epilepsy with left temporal seizure location, a normal pattern of hemispheric language dominance is seen. With a larger sample, differences might have been found, but most likely not of large magnitude. These results are consistent with previous reports (2). Language lateralization is affected by epileptogenic foci in the left frontal and parietal cortex. In our one patient with left frontal lobe epilepsy, language was dominant in the right hemisphere. Seizure location in the temporal lobe

may cause a shift in the location of language areas in the left hemisphere (30, 33, 34).

Functional MR imaging can be used to evaluate language organization and lateralization (10–13, 16, 31, 32). This study shows that functional MR imaging can be successfully used to compare hemispheric language dominance in patients and healthy subjects in whom Wada testing would not be indicated.

References

1. Wada J, Rasmussen T. Intracarotid injection of sodium amytal for the lateralization of cerebral speech dominance. *J Neurosurg* 1960; 17:266–282
2. Rasmussen T, Milner B. The role of early left brain injury in determining lateralization of cerebral speech functions. *Ann N Y Acad Sci* 1977;299:355–369
3. Woods RP, Dodrill CB, Ojemann GA. Brain injury, handedness, and speech lateralization in a series of amobarbital studies. *Ann Neurol* 1988;23:510–518
4. Rausch R, Walsh OG. Right hemisphere language dominance in right-handed epileptic patients. *Arch Neurol* 1984;41:1077–1080
5. Rausch R, Boone K, Ary CM. Right-hemisphere language dominance in temporal lobe epilepsy: clinical and neuropsychological correlates. *J Clin Exp Neuropsychol* 1991;13:217–231
6. Strauss E, Wada J, Goldwater B. Sex differences in interhemispheric reorganization of speech. *Neuropsychologia* 1992; 30:353–359
7. Strauss E, Wada J, Hunter M. Sex-related differences in the cognitive consequences of early left-hemisphere lesions. *J Clin Exp Neuropsychol* 1992;14:738–748
8. Friberg L. Brain mapping in thinking and language function. *Acta Neurochir Suppl (Wien)* 1993;56:34–39
9. Larson B, Skin JE, Lassen NA. Variations in regional cortical blood flow in the right and left hemispheres during automated speech. *Brain* 1978;101:193–209
10. Hinke RM, Hu X, Stillmann AE, et al. Functional magnetic resonance imaging of Broca's area during internal speech. *Neuroreport* 1993;4:675–678
11. Cuenod CA, Bookheimer S, Hertz-Pannier L, Zeffiro TA, Theodore WH, LeBihan D. Functional MR during word generation, using conventional equipment: a potential tool for language local-

- ization in the clinical environment. *Neurology* 1995;45:1821-1827
12. Yetkin FZ, Hammeke TA, Swanson S, et al. A comparison of activation in functional MR activation patterns during silent and audible language tasks. *AJNR Am J Neuroradiol* 1995;16:1087-1092
 13. Binder JR, Rao SM, Hammeke TA, et al. Lateralized human brain language systems demonstrated by task subtraction functional magnetic resonance imaging. *Arch Neurol* 1995;52:593-601
 14. Reite M, Cullum CM, Stocker J, Teale P, Kozora E. Neuropsychological test performance and MEG-based brain lateralization: sex differences. *Brain Res Bull* 1993;32:325-328
 15. Steinmetz H, Volkman J, Jäncke L, Freund H-J. Anatomical left-right asymmetry of language-related temporal cortex is different in left- and right-handers. *Ann Neurol* 1991;29:315-319
 16. Shaywitz BA, Shaywitz SE, Pugh KE, et al. Sex differences in the functional organization of the brain for language. *Nature* 1995;373:607-609
 17. Ogawa S, Tank DW, Menon R, et al. Intrinsic signal changes accompanying sensory stimulation: functional brain mapping with magnetic resonance imaging. *Proc Natl Acad Sci U S A* 1992;89:5951-5955
 18. Ogawa S, Menon RS, Tank DW, et al. Functional brain mapping by blood oxygenation level-dependent contrast magnetic resonance imaging: a comparison of signal characteristics with a biophysical model. *Biophys J* 1993;64:803-812
 19. Belliveau JW, Kwong KK, Kennedy DN, et al. Magnetic resonance imaging mapping of brain function: human visual cortex. *Invest Radiol* 1992;27:S59-S65
 20. Bandettini PA, Wong EC, Hincks PS, Tikofsky RS, Hyde JS. Time course EPI of human brain function during task activation. *Magn Reson Med* 1992;25:390-397
 21. Rao SM, Binder JR, Bandettini PA, et al. Functional magnetic resonance imaging of complex human movements. *Neurology* 1993;43:2311-2318
 22. Kim S-G, Ashe J, Georgopoulos AP, et al. Functional imaging of human motor cortex at high magnetic field. *J Neurophysiol* 1993;69:297-302
 23. Frahm J, Bruhn H, Merboldt K, Hanicke WLF. Dynamic MR imaging of human brain oxygenation during rest and photic stimulation. *J Magn Reson Imaging* 1992;2:501-505
 24. Menon RS, Ogawa S, Kim S-G, et al. Functional brain mapping using magnetic resonance imaging: signal changes accompanying visual stimulation. *Invest Radiol* 1992;27:S47-S53
 25. DeYoe EA, Bandettini P, Neitz J, Miller D, Winans P. Functional magnetic resonance imaging (fMRI) of the human brain. *J Neurosci Methods* 1994;54:171-187
 26. Kwong KK, Belliveau JW, Chesler DA, et al. Dynamic magnetic resonance imaging of human brain activity during primary sensory stimulation. *Proc Natl Acad Sci U S A* 1992;89:5675-5679
 27. Hammeke TA, Yetkin FZ, Mueller WM, et al. Functional magnetic resonance imaging of somatosensory stimulation. *Neurosurgery* 1994;35:677-681
 28. Binder JR, Rao SM, Hammeke TA, et al. Functional magnetic resonance imaging of human auditory cortex. *Ann Neurol* 1994;35:662-672
 29. Binder JR, Rao SM, Hammeke TA, Frost JA, Bandettini PA, Hyde JS. Effects of stimulus rate on signal response during functional magnetic resonance imaging of auditory cortex. *Cog Brain Res* 1994;2:31-38
 30. Devinsky O, Perrine K, Llinas R, Luciano DJ, Dogali M. Anterior temporal language areas in patients with early onset of temporal lobe epilepsy. *Ann Neurol* 1993;34:727-732
 31. Binder JR, Swanson SJ, Hammeke TA, et al. Determination of language dominance using functional MRI: a comparison with the Wada test. *Neurology* 1996;46:978-984
 32. Desmond JE, Sum JM, Wagner AD, et al. Functional MRI measurement of language lateralization in Wada-tested patients. *Brain* 1995;118:1411-1419
 33. Ojemann GA. Individual variability in cortical localization of language. *J Neurosurg* 1979;50:164-169
 34. Ojemann G, Ojemann J, Lettich E, Berger M. Cortical language localization in left, dominant hemisphere. *J Neurosurg* 1989;71:316-326