

Lasting Cytotoxic Edema as an Indicator of Irreversible Brain Damage: A Case of Neonatal Stroke

Helmut Rumpel, Barbara Ferrini, and Ernst Martin

Summary: We describe a case of neonatal stroke in the territory of the left middle cerebral artery. Although the ischemic lesion appeared rather homogeneously hyperintense on T2-weighted MR images, corresponding diffusion-weighted images clearly delineated two separate zones of different cellular swelling and, thus, different prognoses. Lasting cytotoxic edema heralded infarction. We believe that the different rates of disintegration of neurons and glial cells may have caused the change from intracellular to interstitial volume fraction during the evolution of edema.

Brain disorders, such as neonatal hypoxia-ischemia, stroke, excitotoxic injury, and seizures, are known to be multifactorial diseases characterized by secondary brain damage following the initial destructive effect (1). Although the pathophysiological mechanisms are complex, a common characteristic is cellular swelling; that is, cytotoxic edema. Medical diagnosis and treatment depend on knowing to what extent such swelling occurs and what impact it has on cell and tissue survival.

We report the differentiation of ischemic lesions in the territory of the left middle cerebral artery (MCA) in a neonate, whom we examined on the sixth day of life and again after 3 months. The specificity in predicting the outcome of ischemic lesions by analyzing the accompanying edema is discussed.

Case Report

A 5-day-old boy was admitted because of right-sided seizures of the face, arm, and hand, beginning on the third day of life. Neurologic findings were normal, with symmetric movements of all extremities. Pregnancy and delivery had been uneventful. An MR study performed on the sixth postnatal day revealed a hyperintense ischemic lesion in the territory of the left MCA on T2-weighted images. The frontal part of the lesion included the medial and inferior frontal gyri; the temporal part, the superior temporal, angular, and supramarginal gyri as well as the postcentral gyrus with partial effacement of the temporooccipital cortex (Fig 1A). Using snapshot fast low-angle shot (FLASH) imaging combined with a diffusion-weighting preparation period (2), the apparent diffusion coefficient of water (ADC) map was calculated from six images of differing diffu-

sion weighting (b values 0–500 $\frac{\text{s}}{\text{mm}^2}$). Data were acquired on a Tomikon S200A 2T system; Bruker-Spectrospin, Switzerland. In the temporal part of the lesion, the ADC was $78 \pm 5\%$ of baseline, as compared with the contralateral hemisphere, whereas in the frontal zone it was apparently normal (Fig 1B).

At 3 months of age, the infant had asymmetric muscle tone and spontaneous movements, predominantly in the legs. T2-weighted images showed that the frontal part of the lesion had recovered partially, with atrophy of the cortex, subcortical white matter, and parts of the lenticular nucleus, whereas the temporal part had turned into a cystic infarction (Fig 1C).

Discussion

MR imaging is capable of showing the operative mechanisms underlying the formation of cytotoxic and vasogenic edema after stroke (3). This is because the physiological properties of tissue are important factors in controlling image contrast. First, diffusion-weighted imaging provides information about the cellular architecture, such as cellular size, membranes, and volume fraction (4). Moreover, intracellular ADC is about an order of magnitude smaller than extracellular ADC. A narrowing of the extracellular space caused by the swelling of cells may, therefore, cause at least part of the ADC reduction. Second, T2 signal intensity detected in ischemic lesions takes into account the various phases of the edematous process: edema (5) originates from increased vascular permeability, which is paralleled by an increase in water content in such areas (ie, proton density and T2 prolongation), and from cell lysis and cell shrinkage (eg, neuronal loss through apoptosis, which also results in an enlarged interstitial space).

Given this background, the image contrast of the ischemic lesion in this case may be interpreted as follows. In the frontal zone, the almost normal finding of ADC probably resulted from compensating effects on the extracellular (interstitial) space. Slight swelling of cells and increased vascular permeability will enlarge both the intracellular space and the interstitial space in such a way that their volume fraction is

Received August 11, 1997; accepted after revision January 21, 1998.

Funded by the Swiss National Science Foundation (SNF-Nr. 32–37811.93).

From the Division of Magnetic Resonance and Developmental Brain Research, University Children's Hospital Zurich, Steinwiesstrasse 75, CH-8032 Zurich, Switzerland. Address reprint requests to H. Rumpel, PhD.

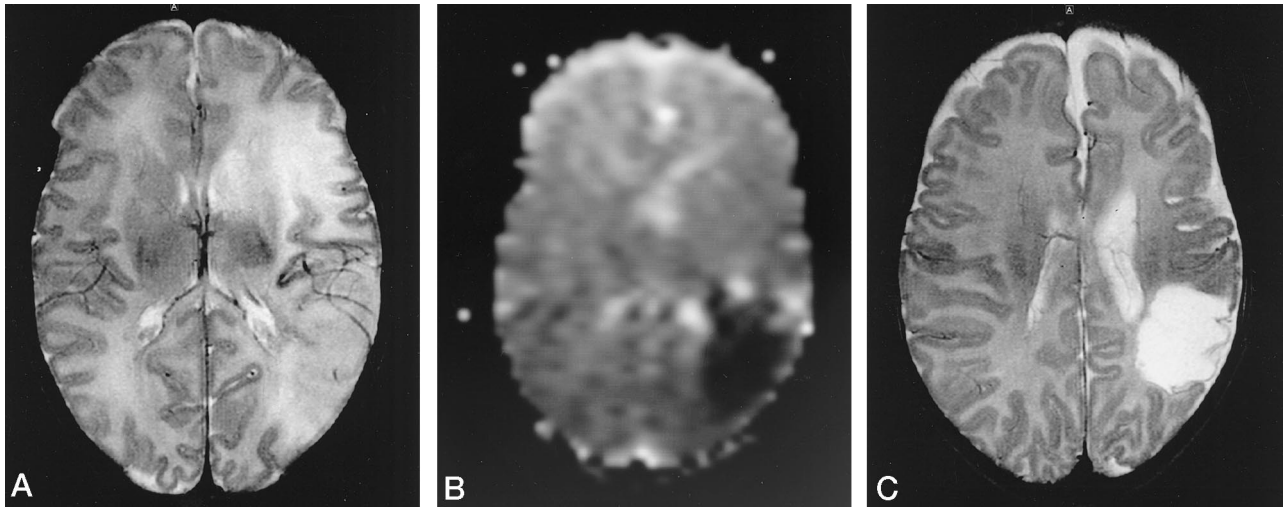


FIG 1. A and B, Axial T2-weighted image (A) and corresponding ADC (B) of a 6-day-old neonate obtained 3 days after onset of stroke symptoms. A shows the hyperintense ischemic lesion in the territory of the left MCA with partial effacement of the temporooccipital cortex. B shows low ADC values (dark area) in the temporal region, although the T2 hyperintensity appears homogeneous throughout the lesion.

C, Follow-up T2-weighted image at 3 months of age shows partial tissue survival in the frontal part of the lesion and cystic infarction in the temporal part.

apparently normal, resulting in presumably normal ADC but prolonged T2, as depicted schematically in Figure 2. With respect to the temporal part of the lesion, the persistent reduction of ADC reflected a more pronounced cellular swelling, although increased extracellular fluid resulting from already lysed cells was coexistent by reason of a low ADC together with a prolonged T2 (Fig 2). The following two findings were significant in support of this expla-

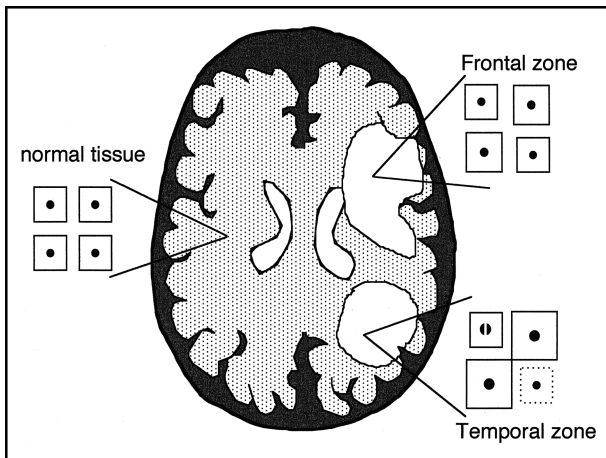


FIG 2. Schematic diagram of the extracellular to intracellular volume fraction based on four cells for normal tissue, the frontal zone, and the temporal zone. In the time scale of MR imaging, observation focuses on isotropic diffusion through both compartments. On the basis of image contrast of T2 hyperintensity and the apparently normal ADC of the frontal part of the lesion, one could judge the slight swelling of the cells and the enlargement of interstitial space in such a way that the volume fraction remains seemingly normal. In the temporal part of the lesion, the low ADC together with an elevated T2 suggests severe cellular swelling combined with cell lyses (dotted square) and/or apoptosis (divided dot), leading to a decreased extracellular volume of increased tortuosity, albeit partially compensated by an accumulation of free interstitial fluid.

nation: first, in the frontal part of the lesion, the gray-white interfaces were preserved to a greater extent, indicating more moderately affected brain tissue relative to the almost total effacement of the temporooccipital cortex; and, second, T2-weighted imaging at 3 months of age showed partially recovered tissue, suggesting that the early cellular dysfunction remained within recoverable limits, probably due to a transient or incomplete ischemia, while in the temporal region a cystic infarction had developed.

The clinical condition of patients often prohibits early examination after onset of ischemic stroke symptoms. Since both the T2-weighted signal and the diffusion-weighted signal change over time during recovery from an ischemic insult, one examination provides just a snapshot of these dynamic processes. However, our present knowledge about the evolution of ischemic brain damage may allow us to draw conclusions from such a single examination, based on both the clinical (6) and pathophysiological aspects in animal models (7). The mechanisms of temporal progression of ischemia to final irreversible brain damage have been expressed as a sequence of pathophysiological stages, beginning with perfusion deficit, followed by imbalance of the cerebral energy metabolism and cellular dysfunction, and finally leading to cell death. Because this early time point during ischemia is generally missed in clinical practice, as in the present case, emphasis is placed on the early phase of recovery with possible delayed brain damage. Cellular dysfunction is caused by inhibition of the cell energy metabolism leading to cell depolarization. This mechanism is known to induce cellular swelling, which greatly affects ADC. Upon reperfusion, different mechanisms triggered by a metabolic cascade of excitotoxicity (8) appear to prolong the cytotoxic, mostly glial, swelling. As demonstrated in a recent

study (9), early neuronal damage and lasting swelling of glial cells contribute to combined T2 and ADC contrast, proving that both mechanisms of edema formation, cytotoxic and vasogenic, take place simultaneously.

The presence of lasting cytotoxic edema over days, as in this case, allows the delineation of brain tissue with irreversible ischemic injury. Although its exact mechanism is still debated (6, 10), comparison with experimental studies (9) points toward a model of different rates of disintegration of the two cell types, neurons and glial cells, as one of the principal mechanisms initiating the lasting ADC effect in acute stroke, along with low regional blood flow, low regional temperature, and long duration of initial ischemia (6).

Conclusion

Although this is a simplified explanation for a complex phenomenon, animal studies are important for understanding the pathophysiological mechanisms in humans. A relationship between the stage of formation of cytotoxic and vasogenic edema during secondary brain damage, evaluated with single-point MR measurements, can be made with respect to both the temporal and spatial evolution in the animal model.

References

1. Johnston MV. **Cellular alterations associated with perinatal asphyxia.** *Clin Invest Med* 1993;16:122-132
2. Haase A. **Snapshot FLASH MRI: applications to T1, T2, and chemical-shift imaging.** *Magn Reson Med* 1990;13:77-89
3. Moseley ME, Cohen Y, Mintorovich J, et al. **Early detection of regional cerebral ischemia in cats: comparison of diffusion- and T2-weighted MRI and spectroscopy.** *Magn Reson Med* 1990;14:330-346
4. Norris DG, Niendorf T, Leibfritz D. **Healthy and infarcted brain tissues studied at short diffusion times: the origins of apparent restriction and the reduction in apparent diffusion coefficient.** *NMR Biomed* 1994;7:304-310
5. Klatzo I. **Evolution of brain edema concepts.** *Acta Neurochir (Suppl)* 1994;60:3-6
6. Moseley ME, Butts K, Yenari MA, Marks M, de Crespigny A. **Clinical aspects of DWI.** *NMR Biomed* 1995;8:387-396
7. Vannucci RC, Christensen MA, Yager JY. **Nature, time-course, and extent of cerebral edema in perinatal hypoxic-ischemic brain damage.** *Pediatr Neurol* 1993;9:29-34
8. Kempfski O, Staub F, Schneider G-H, Weigt H, Baethmann A. **Swelling of C6 glioma cells and glial cells from glutamate, high K⁺ concentrations or acidosis.** *Prog Brain Res* 1992;94:69-76
9. Rumpel H, Nedelcu J, Aguzzi A, Martin E. **Late glial swelling after acute cerebral hypoxia-ischemia in the neonatal rat: a combined magnetic resonance and histochemical study.** *Pediatr Res* 1997;42:54-59
10. Cowan FM, Pennock JM, Hanrahan JD, Manji KP, Edwards AD. **Early detection of cerebral infarction and hypoxic ischemic encephalopathy in neonates using diffusion weighted magnetic resonance imaging.** *Neuropediatrics* 1994;25:196-224