

# Neuroimaging Findings in Late Infantile GM1 Gangliosidosis

Cheng-Yu Chen, Robert A. Zimmerman, Chueng-Chen Lee, Fu-Hwa Chen, Yeong-Seng Yuh, and Hai-Sung Hsiao

**Summary:** Late infantile GM1 gangliosidosis is an extremely rare metabolic disorder with clinical features of seizure and progressive motor and mental retardation without facial dysmorphism or visceral organomegaly. We report the CT and MR imaging findings in one infant, which included abnormalities of the cerebral cortex, white matter, and deep nuclei.

GM1 gangliosidosis is a rare lysosomal storage disease characterized by a deficiency in the activity of lysosomal  $\beta$ -galactosidase, which results in increased accumulation of GM1 ganglioside and asialo-GA1 in the brain and of oligosaccharide in the visceral organs (1, 2). Patients with infantile GM1 gangliosidosis usually have dysmorphic facial features, motor and mental retardation, seizures, and hepatosplenomegaly (2). The late infantile form of this disorder is extremely rare and has no clinical features of facial dysmorphism or visceral organomegaly (1).

## Case Report

An 11-month-old girl, the product of an uncomplicated full-term pregnancy, presented with complex febrile convulsion during an episode of upper respiratory infection. Physical examination at first admission showed a hypotonic infant with macrocephaly (>97 percentile), normal facial features, and psychomotor retardation. Hyperactive reflexes and augmented startle response to noise were present. The abdomen was soft without hepatosplenomegaly. Examination of the eyes revealed a normal clear lens, dilatation of the pupil without light reflex in the right eye, and mild dilatation of the pupil with sluggish light reflex in the left eye. Fundoscopy showed no cherry-red spots at the maculae. Deficient  $\beta$ -galactosidase activity and normal hexosaminidase, and glucosidase activity on lysosomal enzyme assay in cultured skin fibroblasts were documented at the patient's second admission 3 months later for clonic-tonic seizures during another episode of acute upper respiratory infection.

Radiologic investigation included chest radiography (also covering the abdomen), CT, and MR imaging, all of which were done on initial admission and again at follow-up. A bone survey was not performed owing to unremarkable somatic manifestations. A CT scan of the brain at age 11 months showed increased attenuation of the bilateral thalami (Fig 1A). MR

examinations at 11 and 14 months of age showed hyperintensity of the thalami on T1-weighted images (Fig 1B) whereas, on T2-weighted images, the signal intensity of the thalami was decreased (Fig 1C). The white matter myelination was markedly delayed, with only the splenium of the corpus callosum being myelinated and no interval improvement in myelination noted at the second MR study (Fig 1D).

## Discussion

GM1 gangliosidosis is a rare inborn error of metabolism caused by a deficiency of  $\beta$ -galactosidase activity resulting in failure of catalyzing cleavage of terminal  $\beta$ -link galactose from substrates, such as GM1 ganglioside, asialo-GM1, lactosylceramide, galactose-containing oligosaccharides, and mucopolysaccharides. The abnormally accumulated substances in the lysosomes of the affected cells in the CNS are mainly GM1 ganglioside and its asialo derivative GA1 as well as other minor glycolipids and glycopeptides. Visceral storage with oligosaccharides is variable and may cause organomegaly.

Three types of GM1 gangliosidosis, classified by age of onset, have been reported (1, 3, 4). Infantile GM1 gangliosidosis (type 1) is the most common and severe form, with clinical features of hypotonia, failure to thrive in the neonatal period, and clonic-tonic seizure activity. Coarse facial features, frontal bossing, dysostosis multiplex, hepatosplenomegaly, and hazy cornea may be present or become apparent in the first year of life (2). The late infantile or juvenile form (type 2) begins with progressive mental and motor retardation between 1 and 5 years of age. Seizures are common, and spastic tetraplegia develops, with cerebellar and extrapyramidal signs. Decerebrate rigidity follows, and death occurs between 3 and 10 years of age, usually precipitated by recurrent bronchopneumonia. Dysmorphic facial features, hepatosplenomegaly, corneal changes, and bony abnormalities are usually lacking, and, when present, are due to a mild degree or absence of oligosaccharide accumulation. Cerebral GM1 ganglioside storage is also less severe in type 2 than in type 1 disease (1, 2).

Received September 9, 1997; accepted after revision December 18.

From the Departments of Radiology (C-Y.C., C-C.L., F-H.C., H-S.H.) and Pediatrics (Y-S.Y.), Tri-Service General Hospital and National Defense Medical Center, Taipei, Taiwan; and the Department of Radiology, The Children's Hospital of Philadelphia (R.A.Z.).

Address reprint requests to Cheng-Yu Chen, MD, Department of Radiology, Tri-Service General Hospital and National Defense Medical Center, 8, Sec. 3, Ting-Chou Rd, Taipei, Taiwan, Republic of China.

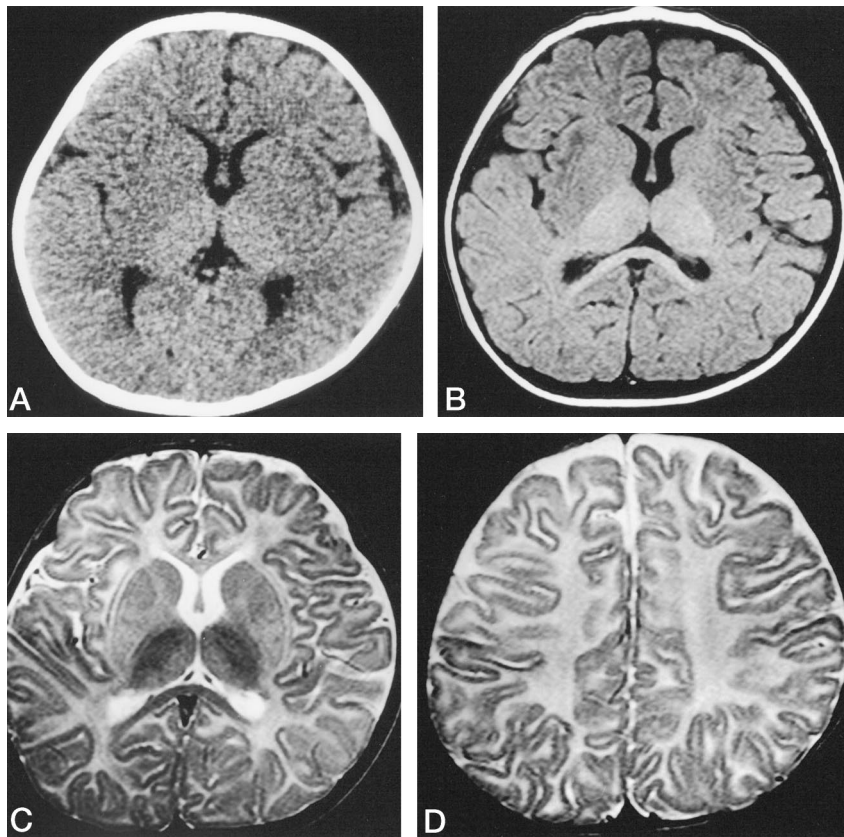


FIG 1. Infant with GM1 gangliosidosis.

A, Cranial CT scan at age 11 months shows increased attenuation of the thalamus and decreased attenuation of the basal ganglia, which were isointense with adjacent white matter.

B, T1-weighted axial MR image (600/20/2 [TR/TE/excitations]) obtained at the same time shows increased signal intensity of the thalamus. The white matter myelination was markedly delayed. Note that only the splenium of the corpus callosum is myelinated.

C, Corresponding axial T2-weighted MR image (2800/90/1) reveals hypodensity of the thalamus and normal signal intensity of the basal ganglia. The cerebrum showed almost no myelination of the white matter except the splenium of the corpus callosum.

D, Follow-up T2-weighted MR image at 14 months of age shows persistent delayed myelination of the white matter. Note that no cortical atrophy is seen at this stage.

Children or adults with chronic, or type 3, GM1 gangliosidosis may have a slowly progressive disorder in which dystonia, dysarthria, ataxia, myoclonus gait disorders, and extrapyramidal signs occur (4). Bony changes are minimal. Cherry-red spots at the maculae, which are found in about half the patients with type 1 GM1 gangliosidosis, are not seen in patients with type 2 and type 3 disease.

The disorder can be diagnosed in several ways, including lysosomal enzyme assay of low  $\beta$ -galactosidase activity in peripheral leukocytes or cultured skin fibroblasts, detection of abnormal urinary oligosaccharide excretion, and rectal biopsy (2). Prenatal diagnosis by measurement of enzyme activity in amniotic fluid and cultivated amniotic fluid cells has also been established (5).

Neuropathologic reports on GM1 gangliosidosis have shown diffuse neuronal storage with ballooning of neuronal cytoplasm in the cerebral and cerebellar cortex, basal ganglia, brain stem, spinal cord, and dorsal root ganglion in type 1 and type 2 forms, and a tendency for selective storage in the basal ganglia with neuronal loss and gliosis in type 3 disease (6, 7). The cerebral white matter is gliotic and there is loss of myelin in type 1 but not in types 2 and 3 GM1 gangliosidosis.

Neuroimaging findings in patients with type 1 GM1 gangliosidosis have been reported only in a few cases. In one case, initial thalamic hyperdensity was found on CT scans and hypointense signal of the thalami was seen on T2-weighted MR images at a later stage (3). Persistent delay in white matter myelination on

serial MR studies has been described in another case (8). In type 3 GM1 gangliosidosis, the symmetrical abnormal signal intensities were more selectively seen in the caudate nucleus and putamen on T2-weighted MR images (9). To our knowledge, neuroimaging findings in type 2 GM1 gangliosidosis have not been reported previously.

The CT and MR findings in our case are identical to those reported in patients with Tay-Sachs disease (GM2 gangliosidosis). This may be understood because the structure of gangliosides GM1 and GM2 differs only in the terminal *N*-acetylgalactosamine, and they are stored together with cholesterol and phospholipid; the neuronal staining reactions and ultrastructure are identical (7). The thalamic hyperdensity seen on CT scans in Tay-Sachs and Krabbe lysosomal storage disorders has been presumed to be due to calcification. Calcium deposition in the thalamus can also explain the hyperintense T1 signal and hypointense T2 signal on MR images, although frank calcium deposition has not been reported pathologically (10). Other investigators have suggested that secondary lipofuscinosis, resulting in deposits of pigmented degradation products, occurs in the thalami and cause this appearance in GM2 gangliosidosis (11, 12). In our case, the CT study showed not only thalamic hyperdensity but also hypointensity of the basal ganglia, which were almost isointense with adjacent white matter (Fig 1A). The MR study verified the CT findings of abnormal thalamic attenuation but not the hypointensity of the basal ganglia. MR is the only imaging technique that is capable of demonstrating

the arrested myelination of the cerebral white matter in serial examinations (Fig 1C and D).

### Conclusion

Although the neuroimaging findings of GM1 gangliosidoses are unique in our case, these findings could also be identified in GM2 gangliosidoses and, to some extent, in late-stage Canavan disease. Patients with late-stage Canavan disease may have dense thalami on T1-weighted images, as well as white matter necrosis, resulting in cavitation, and brain stem and cerebellar atrophy, which are not observed in GM1. Other neurometabolic diseases that often manifest with macrocephaly include mucopolysaccharidosis and Alexander disease. These disorders have distinct neuroimaging features and they should be distinguished from GM1. A definite diagnosis of this rare disorder can only be made by obtaining lysosomal enzyme assay results of deficient  $\beta$ -galactosidase and normal hexosaminidase.

### References

1. Gascon GG, Ozand PT, Erwin RE. **GM1 gangliosidosis type 2 in two siblings.** *J Child Neurol* 1992;7:S41-S50
2. Suzuke Y, Sakuraba H, Oshima A. **Beta-galactosidase deficiency (beta-galactosidosis): GM1 gangliosidosis and Morquio B disease.** In: Scriver CR, Beaudet AL, Sly WS, et al, eds. *The Metabolic and Molecular Bases of Inherited Disease*. New York: McGraw-Hill; 1995:2785-2823
3. Kobayashi O, Takashima S. **Thalamic hyperdensity on CT in infantile GM1-gangliosidosis.** *Brain Dev* 1994;16:472-474
4. Tanaka R, Momoi T, Yoshida A, et al. **Type 3 GM1 gangliosidosis: clinical and neuroradiological findings in an 11-year-old girl.** *J Neurol* 1995;242:299-303
5. Tasso MJ, Martinez-Gutierrez A, Carrascosa C, et al. **GM1-gangliosidosis presenting as nonimmune hydrops fetalis: a case report.** *J Perinatal Med* 1996;24:445-449
6. Bieber FR, Mortimer G, Kolodny EH, et al. **Pathologic findings in fetal GM1 gangliosidosis.** *Arch Neurol* 1986;43:736-738
7. Lake B. **Lysosomal and peroxisomal disorders.** In: Graham DI, Lantos PL, eds. *Greenfield's Neuropathology*. 6th ed. London: Arnold; 1997
8. Kaye EM, Alroy J, Raghavan SS, et al. **Dysmyelinogenesis in an animal model of GM1 gangliosidosis.** *Pediatr Neurol* 1992;8:255-261
9. Uyama E, Terasaki T, Watanabe S, et al. **Type 3 GM1 gangliosidosis: characteristic MRI findings correlated with dystonia.** *Acta Neurol Scand* 1992;86:609-615
10. Brismar J, Brismar G, Coates R, et al. **Increased density of the thalamus on CT scans in patients with GM2 gangliosidoses.** *AJNR Am J Neuroradiol* 1990;11:125-130
11. Lowden JA, Callahan JW, Gravel RA, et al. **Type 2 GM gangliosidosis with neuronal ceroid lipofuscinosis.** *Neurology* 1981;31:719-724
12. Stalker HP, Jan BK. **Thalamic hyperdensity: a previously unreported sign of Sandhoff disease.** *AJNR Am J Neuroradiol* 1989;10: S82