

White Matter Changes Associated with Deletions of the Long Arm of Chromosome 18 (18q- Syndrome): A Demyelinating Disorder?

Laurie A. Loevner, Raymond M. Shapiro, Robert I. Grossman, Joan Overhauser, and John Kamholz

PURPOSE: To evaluate the MR findings in the central nervous systems of patients with deletions of the long arm of chromosome 18 (18q- syndrome). **METHODS:** Sixteen patients with 18q- syndrome ranging in age from 3 to 46 years (mean, 17 years) were studied with high-field-strength MR imaging. Images were analyzed for abnormal T2 hyperintensity in the white matter, abnormal T2 hypointensity in the deep gray matter, and atrophy. **RESULTS:** Ten of 16 patients had abnormal white matter. Diffuse, bilaterally symmetric deep white matter T2 hyperintensity, most pronounced in the periventricular regions, was most common, noted in eight cases. Focal deep white matter lesions and/or abnormalities involving the subcortical white matter were also noted in four cases. The cerebellum, brain stem, and corpus callosum were spared. Ventriculomegally associated with volume loss, and abnormal T2 hypointensity in the basal ganglia and/or thalami were each present in 11 patients. **CONCLUSION:** The 18q- syndrome is associated with white matter disease and abnormal T2 hypointensity in the deep gray matter. The basis for the white matter abnormalities is unknown, but may be related to one of the two genes for myelin basic protein included in the deleted segment of chromosome 18.

Index terms: Brain, magnetic resonance; Chromosomes; Demyelinating disease; White matter, abnormalities and anomalies

AJNR Am J Neuroradiol 17:1843-1848, November 1996

The 18q- syndrome is an increasingly recognized chromosomal abnormality in which there is partial deletion of the distal long arm of chromosome 18 (18q). De Grouchy et al (1) reported a case in 1964. In 1966, Lejeune et al (2) described the clinical syndrome associated with this chromosomal abnormality. While there is a wide range of phenotypic variation, relatively constant manifestations include mental retardation and developmental delay, growth

deficiency, craniofacial dysmorphism (midface hypoplasia, frontal bossing, carplike mouth), limb anomalies, eye movement disorders, genital hypoplasia, and a spectrum of less frequently identified neurologic abnormalities (2-5). The characterization of central nervous system (CNS) abnormalities has lagged behind the delineation of clinical features owing to the scarcity of autopsy material. In addition, few of these patients have been examined with computed tomography or magnetic resonance (MR) imaging.

In 1987, Felding et al (6) identified reduced cerebral white matter with delayed CNS myelination at autopsy in a 2¹/₂-year-old girl with 18q- syndrome. With the exception of a handful of reports, little has been described in the literature regarding the CNS imaging findings in patients with 18q- syndrome. In 1990, Miller et al (3) described abnormal high signal intensity on T2-weighted MR images in the central white matter consistent with immature myelination in a 25-year-old woman and a 16-month-old boy with 18q- syndrome. These investigators hy-

Received December 22, 1995; accepted after revision June 5, 1996.

Presented in part at the annual meeting of the Radiological Society of North America, Chicago, Ill, November 1994.

Supported in part by grant R01 NS2 9029-01A1 from the National Institutes of Neurological Disorders and Stroke, National Institutes of Health.

From the Departments of Radiology (L.A.L., R.I.G.) and Psychiatry (R.M.S.), Hospital of the University of Pennsylvania, Philadelphia; the Department of Biochemistry and Molecular Biology, Thomas Jefferson University, Philadelphia, Pa (J.O.); and the Department of Neurology, Wayne State University, Detroit, Mich (J.K.).

Address reprint requests to Laurie A. Loevner, MD, Hospital of the University of Pennsylvania, 3400 Spruce St, Philadelphia, PA 19104.

AJNR 17:1843-1848, Nov 1996 0195-6108/96/1710-1843

© American Society of Neuroradiology

pothesized that these changes might be due to deletion of one of the myelin basic protein genes located on the long arm of chromosome 18 and almost invariably included in the deleted segment in this chromosomal abnormality. Similar MR findings in a patient with 18q- syndrome were reported by Weiss et al (7). Subsequently, Kline et al in 1993 (8) reported abnormal white matter and poor gray-white matter differentiation on MR studies in three patients with this entity. In 1994, Ono et al (9) described delayed myelination on serial MR studies in a patient with this chromosomal deletion. These case reports suggest that dysmyelination and perhaps demyelination may be a common feature of 18q- syndrome.

MR imaging is very sensitive in detecting both focal and diffuse white matter abnormalities. Because of its ability to delineate the extent of white matter abnormality, it has enhanced our understanding of several white matter diseases, including the demyelinating and dysmyelinating disorders (10-12). In this study we evaluated the CNS MR findings in 16 patients with 18q- syndrome. In particular, we wanted to determine whether white matter abnormalities are a common finding in these patients and, if so, to determine whether there is a characteristic pattern of disease.

Materials and Methods

We analyzed the MR studies of 16 patients (10 male, six female) with 18q- syndrome who were referred to our institution for clinical and genetic examination. Ten of the patients were studied prospectively, and in six cases MR images were evaluated retrospectively. The ages of the patients at the time of their MR studies ranged from 3 to 46 years (average, 17 years). Deletions of the long arm of chromosome 18 (18q) were confirmed in all patients by trypsin-Giemsa banding and fluorescent in situ hybridization techniques (13).

Thirteen patients had MR studies performed at our institution on a 1.5-T system with a quadrature head coil. Each patient's head was secured between sponge wedges and taped to prevent motion during and between the acquisition of images. The remaining three patients had MR studies at outside institutions, also on 1.5-T systems. Conventional spin-echo sagittal T1-weighted images, 600-700/17-28/1 (repetition time/echo time/excitations), were obtained in all patients. Axial fast spin-echo T2-weighted (2700/17-30,85-90/1) and conventional spin-echo T2-weighted (2000-3000/30,80/1) images were obtained in nine and seven of the 16 cases, respectively. Contrast-enhanced axial T1-weighted images with parameters similar to the unenhanced images were obtained in

five of 16 patients (0.1 mL/kg gadopentetate dimeglumine). Other imaging parameters included a section thickness of 5 mm, a 22-cm field of view, and a 256 × 192 matrix.

MR images were reviewed by two neuroradiologists, and a consensus interpretation was obtained. The white matter was evaluated in a systematic fashion for abnormal T2 hyperintensity and included the corona radiata, the centrum semiovale, the internal and external capsules, and the subcortical white matter. The white matter in the brain stem and cerebellum was also evaluated. In the five patients also studied with intravenous contrast material, images were analyzed for abnormal enhancement. The presence of cerebral atrophy, especially white matter volume loss with secondary ventriculomegaly, was determined. Finally, the deep gray matter structures, including the caudate nucleus, putamen, globus pallidus, thalamus, red nucleus, and substantia nigra, were analyzed for the presence of hypointensity on the second echo of the T2-weighted images. Any deep gray nuclei that showed lower signal intensity than the adjacent white matter on visual inspection were noted.

The medical records of all patients were reviewed. Clinical severity of the syndrome marked both by physical findings and neuropsychiatric testing, including social adaptive functioning determined by the Vineland Adaptive Behavior Scale as well as intellectual level assessed by IQ, were reviewed.

Results

Fifteen of 16 patients had abnormal MR findings, including white matter disease, volume loss, and/or T2 hypointensity in the deep gray matter (Table). One patient had a completely normal MR study. White matter abnormalities were present on T2-weighted images in 10 patients (62.5%) and were characterized by diffuse, bilateral high signal intensity in the periventricular and deep white matter, including the corona radiata and centrum semiovale. In all cases these changes were more pronounced posteriorly in the parietooccipital areas, especially in the peritrigonal regions (Fig 1). In eight of 10 patients these findings were symmetric. Abnormal T2 hyperintensity was also noted in the posterior limbs of the internal capsules as well as the external capsules in eight and four of the patients, respectively. In addition to diffuse white matter changes, four patients also had focal, demarcated deep white matter lesions most notable in the centrum semiovale and corona radiata (Fig 2). We also noted poor differentiation of the gray and white matter in four patients, suggesting subcortical white matter involvement (Fig 2). In one patient there was

MR imaging findings in 18q- syndrome

	Case (Sex/Age, y)															
	1 (M/16)	2 (M/16)	3 (M/46)	4 (F/29)	5 (F/14)	6 (F/29)	7 (M/16)	8 (M/3)	9 (F/12)	10 (F/18)	11 (M/15)	12 (M/10)	13 (M/8)	14 (F/18)	15 (M/15)	16 (M/5)
White matter disease																
Deep (centrum semiovale, periventricular, corona radiata)	B	B	B	B	B	B	-	B	B	-	B	A	-	-	-	-
Posterior limb internal capsule	B	B	-	B	B	B	-	B	-	-	-	+	-	-	+	-
External capsule	L	-	-	-	-	-	-	B	B	-	L	+	-	-	B	-
Subcortical	-	-	-	-	-	-	-	+	-	-	+	-	-	-	-	-
Focal lesions	+	-	-	-	-	-	-	+	+	-	-	+	-	-	-	-
Ventriculomegally	-	-	-	+	+	+	-	+	+	+	+	+	-	+	+	+
Hypointensity																
Basal ganglia	+	+	+	+	+	+	-	-	-	+	+	+	-	+	+	-
Thalami	+	-	-	+	-	-	-	-	-	+	+	-	-	+	-	-
Substantia nigra	-	-	+	-	+	-	-	-	-	-	-	-	-	-	-	-

Note.—B indicates bilateral, symmetric; A, asymmetric; +, present; and -, absent.

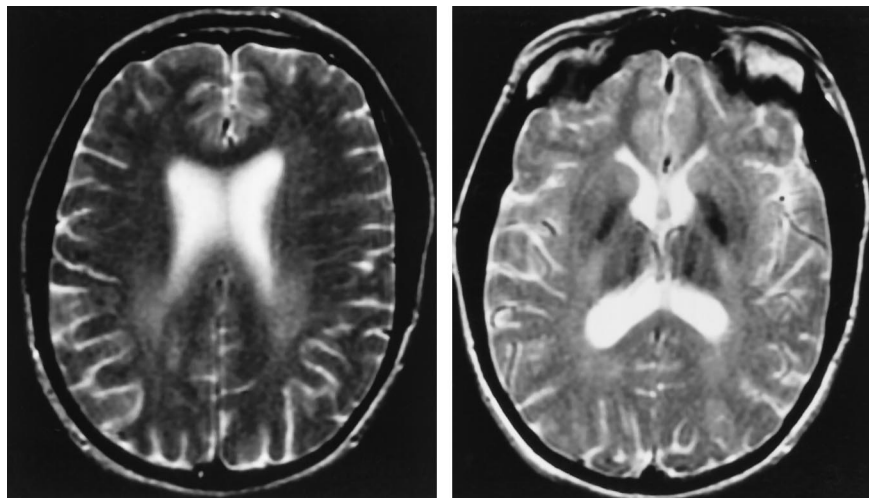


Fig 1. A 25-year-old woman with 18q- syndrome.

A, Axial fast spin-echo T2-weighted MR image (2700/90), section thickness of 5 mm, shows abnormal hyperintensity in the periventricular white matter, especially in the parietal regions. Note that the changes are bilaterally symmetric.

B, Axial image through the deep gray matter shows abnormal T2 hypointensity in the globus pallidus and thalami. Also note the abnormal signal intensity in the internal capsules.

A

B

diffuse T2 hyperintensity in the subcortical white matter in addition to extensive deep white matter involvement (Fig 3). The cerebellum, brain stem, and corpus callosum were normal in all cases. In the five patients also studied after administration of intravenous contrast material, no pathologic enhancement was identified.

Abnormal hypointensity was seen on T2-weighted images in the globus pallidus (11 cases), putamen (two cases), thalamus (five cases), substantia nigra (two cases), and/or the red nuclei (two cases) (Fig 1). Enlargement of the lateral ventricles caused by cerebral volume loss was noted in 11 (69%) of the 16 cases.

Clinical examination of these patients re-

vealed a spectrum of abnormalities; however, all patients had several of the manifestations associated with this chromosomal abnormality. Developmental delay was present in all cases. Intellectual level assessed by full-scale IQ testing was abnormal in all patients, ranging from 44 to 73 (mean, 62). Behavioral and social adaptive functioning as determined by the Vineland Adaptive Behavior Scale, which is graded on an individual basis determined by gender and age, was also abnormal in all patients. Physical examination revealed growth delay in 75% of cases, extremity findings in 50%, and conductive hearing loss, hypoplastic genitalia, and/or ophthalmologic findings in 40% of cases.

Fig 2. A 12-year-old girl with partial deletion of the distal long arm of chromosome 18. Axial fast spin-echo T2-weighted MR images (2700/85), section thickness of 5 mm, show diffuse white matter abnormality with superimposed focal white matter lesions (arrows). Poor gray-white matter differentiation, suggesting subcortical white matter involvement and delayed myelination, is noted.

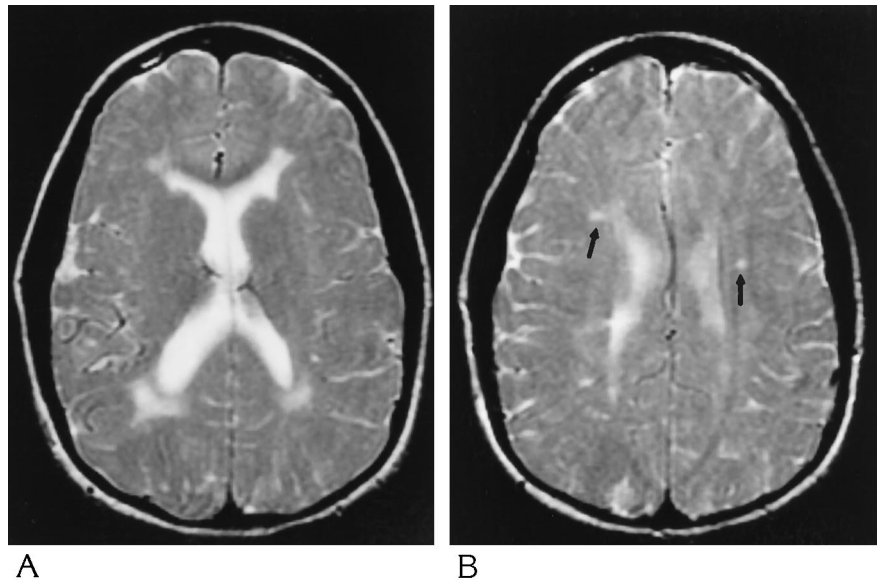
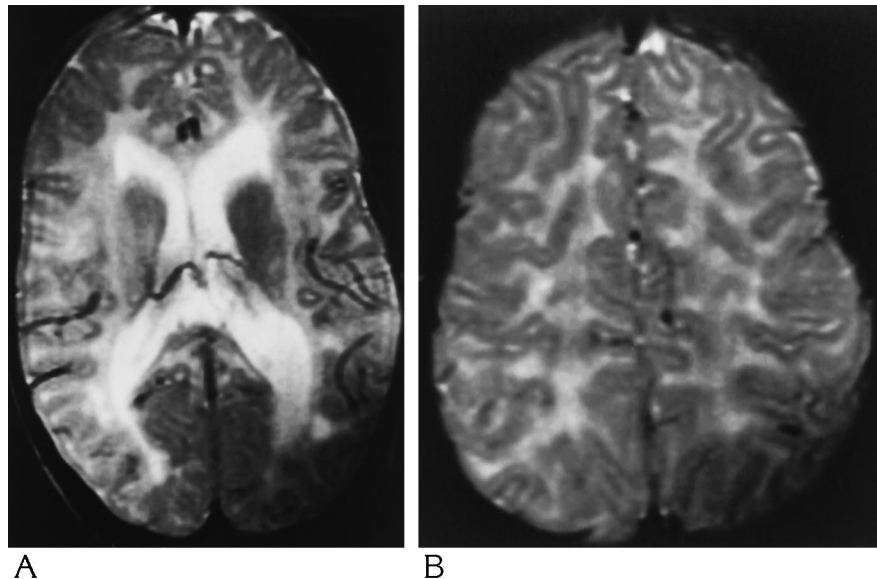


Fig 3. Extensive deep and subcortical white matter involvement in a 3-year-old boy with 18q- syndrome. Axial spin-echo T2-weighted MR images (2000/80), section thickness of 5 mm, show diffuse hyperintensity in the deep white matter. In addition, there is extensive involvement of the subcortical arcuate fibers. Except for deletion of the distal long arm of chromosome 18, the remainder of the patient's genetic work-up was unremarkable.



Discussion

The leukodystrophies are a heterogeneous group of disorders that affect the central and sometimes the peripheral nervous systems, and that predominantly involve the white matter (14-17). They are characterized by abnormal formation and/or maintenance of normally formed myelin (15). While destruction of normally formed myelin is typically considered in the classification of demyelinating diseases, this may also be seen in the leukodystrophies, especially the later onset juvenile and adult forms. Histologic postmortem examination of brains in

these patients in general has revealed a spectrum of findings, including astrocytic gliosis, loss of myelin, and axonal loss (15, 18).

Postmortem evaluation of myelination in the CNS shows that it typically occurs in a relatively ordered pattern (from central to peripheral, inferior to superior, and posterior to anterior) beginning in utero and continuing throughout infancy (19, 20). Analysis of myelination patterns on MR images has correlated in general with pathologic studies (21-23). On MR images obtained at birth, myelination should be apparent in the posterior limb of the internal capsule, the

cerebellar peduncle, and the corona radiata (23). Myelination then progresses in an orderly fashion, and, usually by 2 years of age, the pattern of myelination is similar to that of an adult.

Since its description in 1964, 18q- syndrome has become a well-recognized chromosomal abnormality (1). In the majority of cases the deletion occurs *de novo*; however, in 10% of patients the deletion results from an inversion (24) or a translocation (25, 26). While there is significant phenotypic variation, several physical features are relatively constant. These include craniofacial dysmorphism, limb anomalies (clubfoot, syndactyl, short thumbs, abnormal implantation/overriding toes), and genital hypoplasia (3, 4, 6, 8, 25, 27, 28). Other associated anomalies include congenital heart disease (atrial or septal defect) and skin manifestations (dimpling and excessive whorls on fingertips).

Although neurologic manifestations—including infantile hypotonia, developmental delay, mental retardation, seizures, ocular abnormalities (strabismus, nystagmus), autism, and behavioral problems—are common features of 18q- syndrome, little is known about their underlying cause (3, 5, 6, 8, 28). To begin to identify the structural basis for these neurologic manifestations, we used MR imaging to examine 16 patients with this syndrome.

We found marked white matter abnormalities in 10 of the 16 patients with 18q- syndrome. Similar to a few previously reported cases, diffuse, bilaterally symmetric deep white matter T2 hyperintensity, most pronounced in the posterior periventricular regions, was the most common pattern (3, 7) (Fig 1). Subcortical white matter involvement, manifest as poor gray-white matter differentiation or abnormal T2 hyperintensity, was noted in four of our patients (Figs 2 and 3), and was also described in three patients reported by Kline et al (8). Unlike other studies, we found, in addition to diffuse disease, superimposed focal deep white matter lesions in 25% of cases (Fig 2). The brain stem and cerebellum were spared in all our patients; however, Miller et al (3) reported involvement of the white matter tracts in these areas. As in other reports (3), the corpus callosum was spared in our patients.

We noted abnormal T2 hypointensity in the deep gray matter in 69% of patients, probably on the basis of abnormal iron deposition (Fig 1).

Examination of pathologic specimens with Perls's staining suggests that areas of T2 hypointensity in the basal ganglia and thalami correspond to ferric iron deposition (29). In a study of healthy volunteers ranging in age from 20 to 79 years, Milton et al (30) made several observations, including that middle-aged and elderly adults showed increasing hypointensity in the globus pallidus, that putaminal hypointensity was not present before the age of 60, and that hypointensity in the thalamus and caudate was not seen in any age group. Regions of accelerated hypointensity in the deep gray matter structures on high-field-strength MR images have been noted by several investigators in patients with underlying neurodegenerative diseases (29, 31). Abnormal patterns of T2 hypointensity in the deep gray matter seen on long-repetition-time/long-echo-time images should raise the question of underlying CNS disease.

The extent of the chromosomal deletion is heterogeneous so that the number of genes encoded by the deleted segment may be 10 or more. Which gene or combination of genes may be responsible for the formation of abnormal myelin, however, is not yet understood. An attractive candidate whose deletion may participate in producing abnormal myelination is the myelin basic protein (MBP) gene. MBP is expressed specifically in oligodendrocytes, the myelinating cells of the CNS. The MBP gene is located on the distal long arm of chromosome 18, and was included in the deleted segment in all of the patients in our series. Loss of both MBP genes, such as occurs in the homozygous shiverer mice, is accompanied histologically by marked abnormalities in myelin formation. Shiverer heterozygotes, however, in which only one of the two MBP genes is deleted, are clinically normal and have ultrastructurally normal myelin (32-34). However, in contrast to shiverer mice, deletion of one of the two MBP genes in patients with 18q- syndrome is different in that they are clinically abnormal, with numerous neurologic manifestations. In 18q- syndrome, loss of one of the MBP genes could lead to abnormal myelin formation, since one or more of the other genes included in the deleted segment might interact with MBP. Furthermore, expression of the nondeleted MBP gene may be diminished by a number of epigenetic factors, such as imprinting, which could contribute to dysmyelination. Further molecular character-

ization of the common chromosomal region deleted in patients with 18q- syndrome will be necessary to understand better the basis of abnormal myelin in this syndrome.

In conclusion, long-arm deletions of chromosome 18 are associated with diffuse and focal white matter abnormalities; however, there is no constant pattern of findings. Abnormal mineral deposition in the deep gray matter as well as atrophy are often present. Examination with MR imaging in infancy as well as serial studies extending into adulthood are necessary to understand better the character and the natural progression of white matter disease in these patients.

References

1. de Grouchy J, Royer P, Salmon C, Lamy M. Dé lé tion partielle des bras longs du chromosome 18. *Pathol Biol* 1964;12:579-582
2. Lejeune J, Berger R, Lafourcade J, Rethore MO. La dé lé tion du bras long du chromosome 18. Individualisation d'un nouvel é tat morbide. *Ann Genet* 1966;9:32-38
3. Miller G, Mowrey PN, Hopper KD, Frankel CA, Ladda RL. Neurologic manifestations in 18q- syndrome. *Am J Med Genet* 1990;37:128-132
4. Lewkonja RM, Lin CC, Haslam RHA. Selective IgA deficiency with 18q+ and 18q- karyotypic anomalies. *J Med Genet* 1980;17:453-456
5. Fraccaro M, Hulsten M, Ivemark BI, Lindsten J, Tiepolo L, Zetterqvist P. Structural abnormalities of chromosome 18: a case of 18q-, with autopsy findings. *Ann Genet* 1971;14:275-280
6. Felding I, Kristofferson U, Sjö ström, Noré n O. Contribution to the 18q-syndrome: a patient with del (18) (q22.3qter). *Clin Genet* 1987;31:206-210
7. Weiss BJ, Kamholz J, Ritter A, et al. Segmental spinal muscular atrophy and dermatological findings in a patient with chromosome 18q deletion. *Ann Neurol* 1991;30:419-423
8. Kline AD, White ME, Wapner R, et al. Molecular analysis of the 18q- syndrome and correlation with phenotype. *Am J Hum Genet* 1993;52:895-906
9. Ono J, Harada K, Yamamoto T, Onoe S, Okada S. Delayed myelination in a patient with 18q- syndrome. *Pediatr Neurol* 1994;11:64-67
10. Grossman RI, Gonzalez-Scarano F, Atlas SW, Galetta S, Silberberg DH. Multiple sclerosis: gadolinium enhancement in MR imaging. *Radiology* 1986;161:721-725
11. Paty DW. Magnetic resonance imaging in demyelination. In: Kim SU, ed. *Myelination and Demyelination: Implications for Multiple Sclerosis*. New York, NY: Plenum; 1987:259-272
12. Jackson JA, Leake DR, Schneiders NJ, et al. Magnetic resonance imaging in multiple sclerosis: results in 32 cases. *AJNR Am J Neuroradiol* 1985;6:171-176
13. Strathee G, Zackai EH, Shapiro R, Kamholz, Overhauser J. Analysis of the clinical variation seen in patients with 18q- terminal deletions. *Am J Med Genet* 1995;59:476-483
14. Brismar J, Brismar G, Gascon G, Oznan P. Canavan disease: CT and MR imaging of the brain. *AJNR Am J Neuroradiol* 1990;11:805-810
15. Becker LE. Lysosomes, peroxisomes, and mitochondria: function and disorder. *AJNR Am J Neuroradiol* 1992;13:621-653
16. Van der Knaap MS, Valk J. MR of adrenoleukodystrophy: histopathologic correlations. *AJNR Am J Neuroradiol* 1989;10:512-514
17. Van der Knaap, Valk J, deNeeling N, Nauta JJP. Pattern recognition in magnetic resonance imaging of white matter disorders in children and young infants. *Neuroradiology* 1991;33:478-493
18. Kendall BE. Disorders of lysosomes, peroxisomes, and mitochondria. *AJNR Am J Neuroradiol* 1992;13:621-653
19. Brody BA, Kinney HC, Kloman AS, Gilles FH. Sequence of central nervous system myelination in human infancy, I: an autopsy study of myelination. *J Neuropathol Exp Neurol* 1987;46:283-301
20. Kinney HC, Brody BA, Kloman AS, Gilles GH. Sequence of central nervous system myelination in human infancy, II: patterns of myelination in autopsy infants. *J Neuropathol Exp Neurol* 1988;47:217-234
21. Ballesteros MC, Hansen PE, Solia K. MR imaging of the developing human brain. *Radiographics* 1993;13:611-622
22. Barkovich AJ, Lyon G, Evrard P. Formation, maturation and disorders of white matter. *AJNR Am J Neuroradiol* 1992;13:447-461
23. Bird CR, Hedberg M, Drayer BP, et al. MR assessment of myelination in infants and children: usefulness of marker sites. *AJNR Am J Neuroradiol* 1989;10:731-740
24. Wertenleick W, Gerald PS. Clinical and chromosomal studies of the 18q- syndrome. *J Pediatr* 1971;78:44-52
25. Wilson MG, Towner JW, Forsman I, Siris E. Syndromes associated with deletion of the long arm of chromosome 18[del(18q)]. *Am J Med Genet* 1979;3:155-174
26. Fryns JP, Logghe N, Van Eygin M, Van den Berghe H. 18q- syndrome in mother and daughter. *Eur J Pediatr* 1979;130:189-192
27. Vogel H, Urich H, Horoupian DS, Wertenleick W. The brain in the 18q- syndrome. *Dev Med Child Neurol* 1990;32:725-742
28. Insley J. Syndrome associated with a deficiency of part of the long arm of chromosome no. 18. *Arch Dis Child* 1967;42:140-146
29. Rutledge JN, Hilal SK, Silver AJ, Defendini R, Fahn S. Study of movement disorders and brain iron by MR. *AJNR Am J Neuroradiol* 1987;8:397-411
30. Milton WJ, Atlas SW, Lexa FJ, Mozley PD, Gur RE. Deep gray matter hypointensity patterns with aging in healthy adults: MR imaging at 1.5 T. *Radiology* 1991;181:715-719
31. Drayer BP, Burger P, Hurwitz B, Dawson D, Cain J. Reduced signal intensity on MR images of thalamus and putamen in multiple sclerosis: increased iron content? *AJNR Am J Neuroradiol* 1987;8:413-419
32. Shine HD, Readhead C, Popko B, Hood L, Sidman RL. Morphometric analysis of normal, mutant, and transgenic central nervous system: correlation of myelin basic protein expression to myelinogenesis. *J Neurochem* 1992;58:342-349
33. Shine HD, Readhead C, Popko B, Hood L, Sidman RL. Myelin basic protein and myelinogenesis: morphometric analysis of normal, mutant, and transgenic central nervous system. *Prog Clin Biol Res* 1990;336:81-92
34. Rosenbluth J. Central myelin in the mouse mutant shiverer. *J Comp Neurol* 1980;194:639-648