

Proton MR Spectroscopy in Patients with Neurofibromatosis Type 1: Evaluation of Hamartomas and Clinical Correlation

Mauricio Castillo, Cynthia Green, Lester Kwock, Keith Smith, Douglas Wilson, Sharon Schiro, and Robert Greenwood

PURPOSE: To use proton MR spectroscopy in patients with neurofibromatosis type 1 to determine: (a) the spectroscopic characteristics of hamartomas and compare them with that of gliomas; (b) whether differences exist between patients with and without learning disabilities; and (c) spectroscopic patterns in normal-appearing brain (by MR imaging) in patients with and without focal lesions. **METHODS:** Seventeen proton MR spectroscopy volumes were obtained in 10 patients with neurofibromatosis type 1 (including hamartomas, N = 7; normal-appearing brain, N = 10). Seven patients had learning disorders, and 3 were mentally normal. Ten healthy volunteers and 10 patients with pathologically proved gliomas (all grades) were also examined. *N*-Acetyl aspartate/creatine, creatine/choline, and *N*-acetyl aspartate/choline ratios were calculated for all samples. **RESULTS:** (a) Hamartomas showed higher *N*-acetyl aspartate/creatine, creatine/choline, and *N*-acetyl aspartate/choline ratios than gliomas. Hamartomas showed *N*-acetyl aspartate/creatine, creatine/choline, and *N*-acetyl aspartate/choline ratios similar to those of healthy volunteers. (b) No significant differences in *N*-acetyl aspartate/creatine, creatine/choline, and *N*-acetyl aspartate/choline ratios were found in patients who had neurofibromatosis type 1 with and without learning disabilities. (c) *N*-acetyl aspartate/creatine, creatine/choline, and *N*-acetyl aspartate/choline ratios were similar for patients who had neurofibromatosis type 1 with and without focal hamartomas and in healthy volunteers. **CONCLUSIONS:** (a) Hamartomas have a proton MR spectroscopy pattern different from that of glioma and similar to that of normal brain. (b) As performed in this study, proton MR spectroscopy did not show significant differences in patients who had neurofibromatosis type 1 with and without learning disabilities. (c) Patients who have neurofibromatosis type 1 with and without hamartomas seem to have normal intervening brain by proton MR spectroscopy when compared with healthy volunteers.

Index terms: Neurofibromatosis; Hamartoma; Magnetic resonance, spectroscopy

AJNR Am J Neuroradiol 16:141-147, January 1995

Neurofibromatosis type 1 is the most common phakomatosis. It is inherited by a gene located in chromosome 17 (1). Within the central nervous system, the most commonly encountered lesions include optic pathway and cerebral astrocytomas, neurofibromas, neurofibrosarcomas, and nonneoplastic "hamartomas."

The presence of the so-called hamartomas of the brain in patients with neurofibromatosis

type 1 was unknown before routine magnetic resonance (MR) imaging became available (1). These focal abnormalities are usually seen as areas of high signal intensity on proton-density and T2-weighted images in as many as to 43% of patients with neurofibromatosis type 1 (1). They are generally found in the cerebellar peduncles, basal ganglia, brain stem, and optic radiations. Although they have no mass effect, edema, or contrast enhancement, they may occasionally be difficult to differentiate from low-grade gliomas that occur in the neurofibromatosis type 1 population. Also, as many as 70% of patients with neurofibromatosis type 1 will have some degree of mental disability (2). The presence or severity of this impediment does not correlate with the type or number of brain lesions seen by MR imaging in these cases (3).

Received January 13, 1994; accepted after revision May 5.

From the Departments of Radiology (M.C., C.G., L.K., K.S., D.W., S.S.) and Neurology (R.G.), University of North Carolina School of Medicine, Chapel Hill.

Address reprint requests to: Mauricio Castillo, Radiology, CB 7510, University of North Carolina at Chapel Hill, Chapel Hill, NC 27599-7510.

AJNR 16:141-147, Jan 1995 0195-6108/95/1601-0141

© American Society of Neuroradiology

Our purpose was to establish proton MR spectroscopy characteristics of brain hamartomas in patients with neurofibromatosis type 1 and compare them with those seen in glial cell-line tumors and normal brain.

Materials and Methods

Ten patients (age range, 5 to 49 years; six female, four male, seven with mental disabilities, and three mentally normal) with the unequivocal clinical diagnosis of neurofibromatosis type 1 were studied using proton MR spectroscopy. Consent as dictated by our institutional review board was obtained from all patients and healthy volunteers. Hamartomas, found in seven patients (age range, 4 to 15 years), were considered as such only if they were unchanged in size and configuration over a 3-year period by MR imaging, were of high signal intensity on proton-density and T2-weighted sequences, showed no contrast enhancement, and had no edema or mass effect. Pathologic proof that these were indeed hamartomas was not obtained. Hamartomas were found in the middle cerebellar peduncles (bilateral, N = 4; left side, N = 3; right side, N = 1), the left globus pallidus (N = 2), or the left thalamus (N = 1), and all measured between 1.4 and 2.5 cm in their greatest dimension. Spectroscopy using single voxels measuring $2 \times 2 \times 2$ cm (the minimum possible in our 1.5-T unit) to $3 \times 3 \times 3$ cm were used (Fig 1). Our intention was to use a voxel in which each lesion was at least 40% of the total size of that voxel to be able to establish with confidence minimal differences in metabolite concentrations. This was based on a 20% SD for the volumes sampled in healthy volunteers. We believe that




Fig 1. Axial T2-weighted image shows placement of a $2 \times 2 \times 2$ -cm voxel encompassing a hamartoma in the left thalamus with little surrounding normal-appearing tissue.

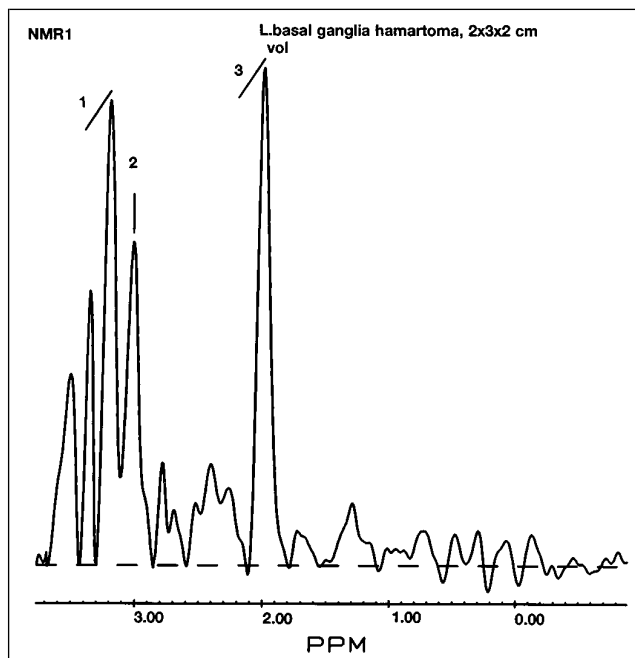


Fig 2. Proton MR spectra obtained from a basal ganglia hamartoma. 1 indicates choline; 2, creatine; and 3, *N*-acetyl aspartate.

differences of more than 1 SD in metabolite concentration and relaxation are needed to detect spectroscopic abnormalities confidently. Proton MR spectroscopy was obtained in a 1.5-T unit using point resolved spectroscopy spin-echo location, and water was suppressed using the water elimination Fourier transformation inversion-recovery sequence with spectra obtained at 2000/272/128–256 (repetition time/echo time/excitations) using for all subjects. Three patients did not have any focal hamartomas, and an area of the brain that encompassed the basal ganglia was sampled (voxel size, $3 \times 3 \times 3$ cm). In the seven patients with basal ganglia hamartomas (N = 3; Fig 2), the contralateral basal ganglia, which were normal by MR imaging, were sampled using a voxel size of $3 \times 3 \times 3$ cm. In patients with cerebellar hamartomas (N = 4; Fig 3), the ipsilateral but normal-appearing (by MR imaging) basal ganglia were studied also using a voxel size of $3 \times 3 \times 3$ cm. Medical records were reviewed of all patients with neurofibromatosis type 1 to try to determine whether any mental disabilities were present. When pertinent, the authorities at the schools the children attended were contacted to try to determine whether a specific learning disability had been observed.

Ten patients with pathologically proved astrocytomas were also studied (pilocytic, N = 1; low-grade, N = 3; anaplastic, N = 2; and glioblastoma multiforme, N = 4) using the same parameters as above, with exception of the voxel size, which in these patients ranged between $3 \times 3 \times 3$ and $5 \times 5 \times 5$ cm and was positioned at the epicenter of the mass and tailored to its size (Fig 4). All tumors were located in the cerebral hemispheres except for the one

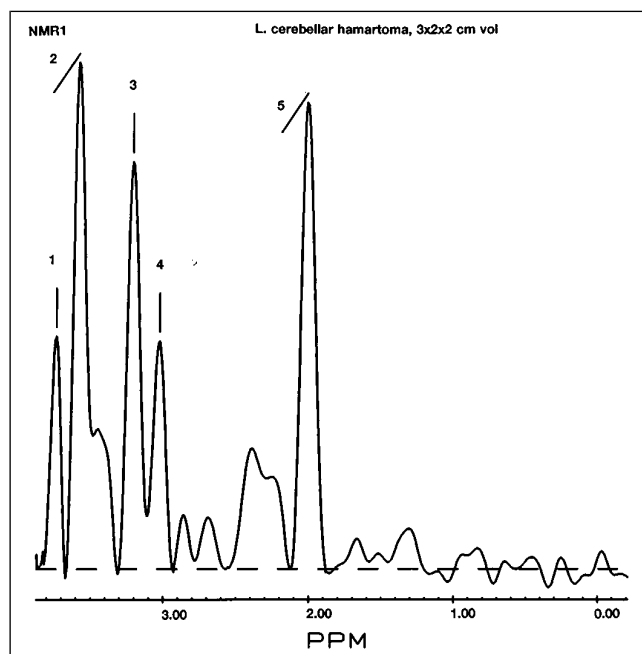


Fig 3. Proton MR spectra obtained from a cerebellar hamartoma. 1 and 2 indicate possible alcoholic sugars; 3, choline; 4, creatine; and 5, *N*-acetyl-aspartate.

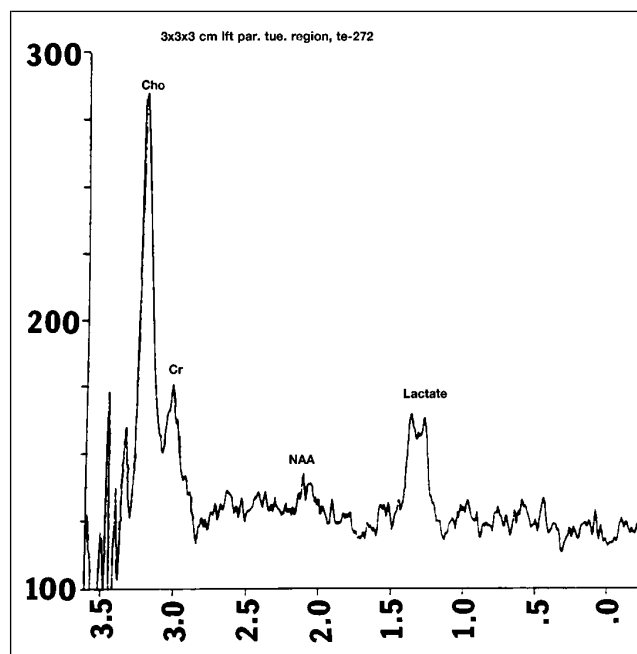


Fig 4. Proton MR spectroscopy of a proved glioblastoma multiforme shows markedly elevated choline (*Cho*), decreased *N*-acetyl-aspartate (*NAA*), and increased lactate. Note the difference between these spectra and ones obtained in hamartomas (Figs 2 and 3).

pilocytic astrocytoma, which arose in the optic chiasm. None of these patients had neurofibromatosis.

Ten nonmatched healthy volunteers were studied. (Age matching was not possible, because scanning of healthy children was not allowed by our institutional review board.) In five of these subjects, proton MR spectroscopy using a voxel size of $2 \times 2 \times 2$ cm was performed centered at the level of the middle cerebellar peduncle, and in the other five volunteers $3 \times 3 \times 3$ -cm voxels centered at the globus pallidus were examined (Fig 5).

Using the maximum peak intensities, *N*-acetyl aspartate/creatine, creatine/choline, and *N*-acetyl aspartate/choline ratios were calculated for all volumes obtained and correlated with findings on conventional contrast-enhanced MR imaging studies and clinical status for patients with neurofibromatosis.

Mean metabolite ratios for each group of patients were compared using one-way analysis of variance. When a statistically significant difference among means was detected, posthoc stepwise comparison of group means was performed using Bonferroni testing. Statistical significance was set at $P > .05$. Data analysis was performed using SYSTAT for the Macintosh (SYSTAT, Evanston, Ill).

Results

Hamartomas had lower *N*-acetyl aspartate/creatine ratios (1.26 ± 0.14) than the brain of healthy volunteers (1.71 ± 0.12) but higher ratios than astrocytomas (0.75 ± 0.12) (Fig

6A). Hamartomas had higher creatine/choline ratios (0.74 ± 0.13) when compared with astrocytomas (0.34 ± 0.05) but similar to those of healthy volunteers (0.72 ± 0.05) (Fig 6B). Hamartomas had *N*-acetyl aspartate/choline ratios (0.97 ± 0.08) similar to those of brain of volunteers (1.19 ± 0.07) but higher than those found in astrocytomas (0.27 ± 0.07) (Fig 6C). Therefore, our results suggest that hamartomas of the brain in patients with neurofibromatosis type 1 have different proton MR spectra than those seen in astrocytomas but similar to those of the brain in healthy volunteers. Visual inspection of the spectra did not demonstrate lactate in any case of hamartoma, but lactate was present in all four glioblastoma multiforme (Fig 4). Despite the diverse histologic grades of the astrocytomas evaluated, we observed no qualitative differences between low- and high-grade tumors based on their spectroscopic signatures. Specifically, there was no definite overlap of metabolite ratios between one pilocytic glioma, three low-grade astrocytomas, and hamartomas.

N-acetyl aspartate/creatine ratios were 1.83 ± 0.14 and 1.63 ± 0.2 for patients who had

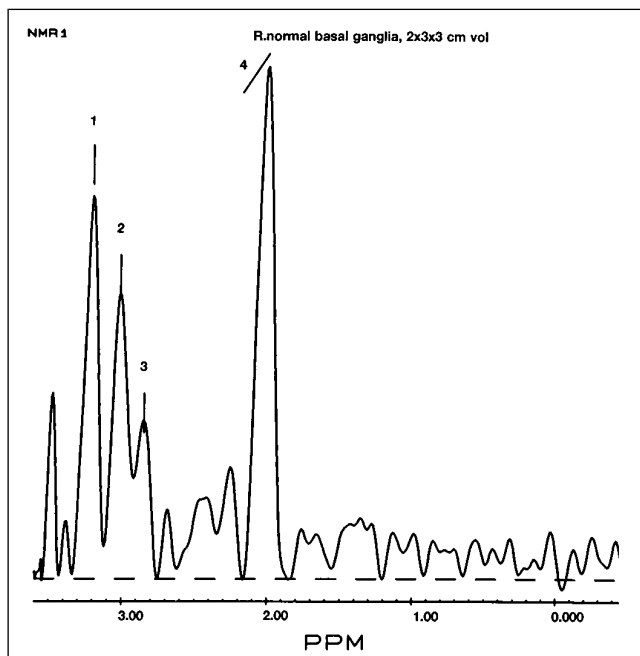


Fig 5. Proton MR spectra obtained from the basal ganglia of a healthy volunteer. Note similarities with spectra obtained from hamartomas (Figs 2 and 3). 1 indicates taurine; 2, choline; 3, creatine; and 4, *N*-acetyl-aspartate.

neurofibromatosis type 1 with and without learning disabilities, respectively (Fig 7A). Creatine/choline ratios were 0.7 ± 0.07 and 0.81 ± 0.09 for patients with and without learning disabilities, respectively (Fig 7B). *N*-acetyl aspartate/choline ratios were 1.25 ± 0.1 and 1.33 ± 0.13 for patients with and without learning disabilities, respectively (Fig 7C). Also, there was no significant difference in metabolite ratios between these two groups of patients with neuro-

fibromatosis type 1 and the healthy volunteers. Three patients were grossly mentally retarded; three patients had significant learning disabilities in mathematics; and one patient had a gross delay in language acquisition. Two patients were considered totally functional and mentally normal; one child was considered gifted and was attending an institution for such students. Our results indicate that proton MR spectroscopy, as used in this study, does not show any significant differences between patients who have neurofibromatosis type 1 with and without learning disabilities when compared with healthy volunteers.

Proton MR spectroscopy of the normal-appearing brain (by MR imaging) in patients who had neurofibromatosis type 1 with and without hamartomas showed that there were no significant differences in the *N*-acetyl aspartate/creatine ratios (with hamartomas, 1.9 ± 0.15 ; without hamartomas, 1.60 ± 0.17) of patients with neurofibromatosis type 1 versus volunteers (1.71 ± 0.12) (Fig 8A). Creatine/choline ratios in patients who had neurofibromatosis type 1 with focal hamartomas were 0.64 ± 0.07 , 0.86 ± 0.08 in patients who had neurofibromatosis type 1 with no focal hamartomas, and 0.72 ± 0.06 in volunteers (Fig 8B). Also, *N*-acetyl aspartate/choline ratios were 1.20 ± 0.11 in patients who had neurofibromatosis type 1 with focal hamartomas versus 1.38 ± 0.12 in patients who had neurofibromatosis type 1 with no hamartomas versus 1.19 ± 0.09 in volunteers (Fig 8C). Therefore, it seems that by proton MR spectroscopy, patients who have neurofibroma-




Fig 6. A, Scatter plot showing absolute scores for *N*-acetyl aspartate/creatine ratios in patients who had neurofibromatosis type 1 with hamartomas ($N = 7$), healthy volunteers ($N = 10$), and gliomas ($N = 10$).

B, Scatter plot showing ratios for creatine/choline in the same population.

C, Scatter plot showing ratios for *N*-acetyl aspartate/choline in the same population. (Note that some patients overlap.)




Fig 7. A, Scatter plot showing ratios of *N*-acetyl aspartate/creatine in neurofibromatosis type 1 with (*With LD*) and without learning disabilities (*Without LD*) compared with healthy subjects (*Normal*).

B, Scatter plot showing ratios for creatine/choline in neurofibromatosis patients who had type 1 with and without learning disabilities compared with healthy subjects.

C, Scatter plot showing ratios for *N*-acetyl aspartate/choline for patients who had neurofibromatosis type 1 with and without learning disabilities compared with healthy volunteers. (Note that some patients overlap.)




Fig 8. A, Scatter plot showing ratios for *N*-acetyl aspartate/creatine obtained in normal-appearing brain regions by MR imaging in patients who had neurofibromatosis type 1 with (*With Ham.*) and without (*Without Ham.*) focal lesions and compared with healthy volunteers (*Normal*).

B, Scatter plot showing ratios for creatine/choline obtained in normal-appearing brain regions by MR imaging in patients who had neurofibromatosis type 1 with and without focal lesions and compared with healthy volunteers.

C, Scatter plot showing ratios for *N*-acetyl aspartate/choline obtained in normal-appearing brain regions by MR imaging in patients who had neurofibromatosis type 1 with and without focal lesions and compared with healthy volunteers. (Note that some patients overlap.)

osis type 1 with and without focal hamartomas have normal intervening brain.

Discussion

Hamartomas

Areas of high signal intensity on proton-density or T2-weighted images seen in patients with neurofibromatosis type 1 are generally called

hamartomas (1). Traditionally, it has been assumed that these MR imaging abnormalities represent normal cells in atypical locations. Alternative explanations for them include heterotopias, areas of delayed or disordered myelination, areas of gliosis, and low-grade astrocytomas (4). Pathologic correlation was performed in two patients with neurofibromatosis type 1 and showed that these hamartomas

were composed of atypical glial infiltrates, foci of microcalcifications, perivascular gliosis, and spongy changes in the periphery of the lesions (Zimmerman RA et al, "Pathology of Findings of Cerebral High Signal Intensity in Two Patients with Type 1 Neurofibromatosis," presented at the 78th Annual Meeting of the Radiological Society of North America, Chicago, Ill, November 29–December 4, 1992). The term *hamartoma* has been adopted for these abnormalities because they generally show little or no growth, are devoid of surrounding edema, and almost invariably show no contrast enhancement. Although as many as 43% of patients with neurofibromatosis type 1 will show hamartomas by MR imaging, fewer than 10% of lesions will show growth on serial examinations (5). If growth occurs after 10 years of age, careful follow-up or even a biopsy should be done to exclude the possibility of tumor (5). Hamartomas occurring in the globus pallidus tend to be slightly larger than those found elsewhere, may have slight mass effect, and be mildly bright on precontrast T1-weighted images (5). Because there seems to be no correlation between the number and location of these lesions with the clinical status of the patients, their importance lies in distinguishing them from low-grade astrocytomas, which are known to occur in patients with neurofibromatosis type 1. Obviously, early detection of astrocytomas is desirable.

For purposes of our study we selected, from our Neurofibromatosis Clinic, seven patients with neurofibromatosis type 1 who have lesions that fit the criteria previously described for the diagnosis of hamartoma. Although none of our patients underwent a biopsy to prove that these lesions were indeed benign, their locations and apparent lack of change over a minimum 3-year follow-up period suggested their benign nature. By MR spectroscopy, these hamartomas showed *N*-acetyl aspartate/choline and creatine/choline ratios that were clearly different from those seen in our patients with glioma but similar to those seen in healthy volunteers (Figs 6A–C). Admittedly, partial volume averaging of normal surrounding brain in the areas sampled could play a part in our results. However, in all patients the hamartomas occupied at least 40% of the voxel (Fig 1). We believe this is sufficient to detect minimum changes in metabolites within the lesions. Also, the size of a lesion within a voxel may not necessarily be related to the change in metabolites reflected by proton MR spectroscopy. That is, a small lesion within

a large voxel may have enough changes in metabolite concentrations to produce alterations in the spectra within the given voxel. *N*-Acetyl aspartate is a neuronal marker that is diminished (supposedly because of axonal loss from a breakdown of myelin) in gliomas (6). Our hamartomas showed *N*-acetyl aspartate/creatine and *N*-acetyl aspartate/choline ratios slightly lower than in normal brain but higher than that seen in gliomas (Figs 6A and C). This seems to suggest that there is some neuronal cell loss or deficient neuronal formation in hamartomas. Creatine is a marker of intracellular energetics, and in our study hamartomas had creatine/choline ratios similar to those in healthy volunteers but higher than those seen in gliomas (Fig 6B). This finding could reflect the fact that hamartomas and normal brain have similar metabolism of high-energy compounds, which is decreased in gliomas. Choline is believed to reflect membrane constituents (6). Higher creatine/choline ratios in hamartomas when compared with gliomas indicate an abnormality in choline-containing compounds that could reflect altered cell membrane metabolism in gliomas. Similar creatine/choline ratios between hamartomas and the brain of healthy volunteers suggest similar cell membrane metabolism in these two groups.

Another possible caveat is that, although the majority of astrocytomas that occur in patients with neurofibromatosis type 1 are known to be low grade, our tumor population included astrocytomas of all grades. Again, we believe that our overall results are not affected by this, because it has been shown that proton MR spectroscopy differences between different histologic grades of gliomas are not sufficient to allow identification of increasing grades of malignancy (6). Therefore, proton MR spectroscopy is sensitive enough to suggest the diagnosis of glioma but may not be used to provide grading of a given tumor. Moreover, lactate, which is known to be present in high-grade gliomas (6), was not identified in any of our hamartomas. We believe that the fact that our control subjects were not age matched (all were adults) is not a problem, because the youngest patient with neurofibromatosis type 1 was 4 years of age, and in our experience, children 1 year of age and older show proton MR spectra that are similar to those of adults. The point resolved spectroscopy method was used to locate the spectra; however, the stimulated echo acquisition mode (which was not available in

our equipment at the time of this study) may reveal subtle changes in metabolites that have short decay times. These were not evaluated in our study and could form the focus for further evaluation of hamartomas in the neurofibromatosis type 1 population.

In summary, we believe that proton MR spectroscopy may be helpful in identifying brain lesions in patients with neurofibromatosis type 1 that are hamartomas and may be used to distinguish them from gliomas.

Learning Disabilities

As many as 70% of children with neurofibromatosis type 1 will have learning disabilities (2). A marker with which to identify this group of patients is desirable (but not available) to help institute early special treatment. The number of hamartomas or other brain lesions generally does not correlate with the presence or degree of a learning disability (3). In our study, seven patients had learning disabilities. We elected to perform proton MR spectroscopy in these patients by sampling a volume (9 to 12 cm³ centered at the globus pallidus) that encompassed both large areas of gray (basal ganglia) and white matter (corona radiata and centrum semiovale). We did not find any significant differences between patients who had neurofibromatosis type 1 with and without learning disabilities and healthy volunteers (Figs 7A–C). Our results, however, do not imply that proton MR spectroscopy may not be used in this regard. Perhaps sampling of regions of the brain involved in higher learning (cortex) will eventually reveal proton MR spectroscopy abnormalities in mentally disabled patients with neurofibromatosis. At this time, sampling of the cortex is hindered by magnetic susceptibility effects arising from the nearby skull and by the requirement to sample subcentimeter volumes, which we are unable to perform.

In summary, proton MR spectroscopy, as used in our patient population, did not show any significant differences between patients who had neurofibromatosis type 1 with and without learning disabilities and healthy volunteers.

Regions of Brain That Appear Normal by MR Imaging

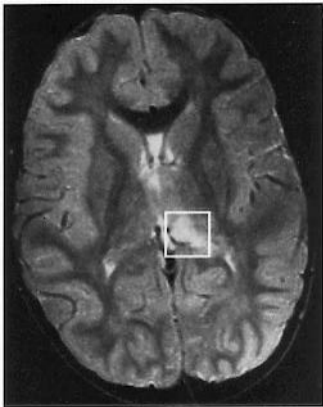
The last part of our study involved proton MR spectroscopy sampling of regions of the brain that appeared normal by MR imaging. Patients

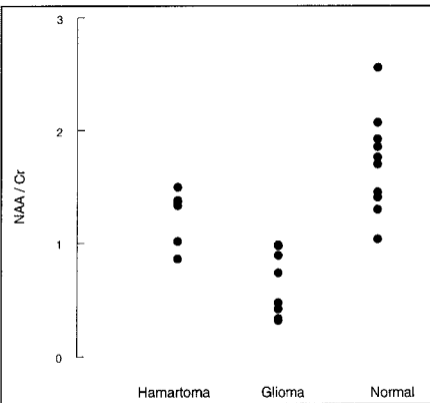
who have neurofibromatosis type 1 with no identifiable brain abnormalities, but who clinically have learning disabilities, are well known to exist. In our study, of the seven patients who had learning disabilities, two had normal MR brain findings. This observation suggests that despite the normal MR findings, some intrinsic brain abnormalities do occur in these patients. Our objective was to use proton MR spectroscopy to detect whether a diffuse parenchymal abnormality was present that could explain neurologic deficits in patients with neurofibromatosis type 1.

N-Acetyl aspartate/creatine ratios obtained in regions of normal-appearing brain in patients who had neurofibromatosis type 1 with other focal hamartomas were similar to the results obtained in healthy volunteers (Fig 8A). *N*-Acetyl aspartate/creatine ratios of normal-appearing brain regions in patients who had neurofibromatosis type 1 with no other focal abnormalities were also similar to those seen in healthy volunteers. Creatine/choline ratios were similar in the regions of normal-appearing brain in the patients who had neurofibromatosis type 1 with hamartomas and in the volunteers (Fig 8B). Again, creatine/choline ratios in patients who had neurofibromatosis type 1 with no focal brain abnormalities were similar to those of volunteers. No significant differences in the *N*-acetyl aspartate/choline ratios were found in the three groups of patients (Fig 8C). These results indicate that, despite clinically detectable neurologic abnormalities, there are no differences in metabolites in the normal-appearing brain of patients who have neurofibromatosis type 1 with and without other focal brain lesions when compared with healthy volunteers.

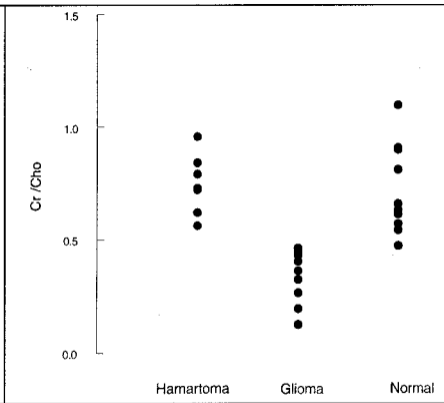
References

1. Pont MS, Elster AD. Lesions of skin and brain: modern imaging of the neurocutaneous syndromes. *AJR Am J Roentgenol* 1992;158:1193–1203
2. Roos KL, Dunn DW. Neurofibromatosis. *CA* 1992;42:241–254
3. Dunn DW, Roos KL. Magnetic resonance imaging evaluation of learning difficulties and coordination in neurofibromatosis. *Neurofibromatosis* 1989;2:1–5
4. Aoki S, Barkovich AJ, Nishimura K, et al. Neurofibromatosis types 1 and 2: cranial MR findings. *Radiology* 1989;172:527–534
5. Sevick RJ, Barkovich AJ, Edwards MSB, et al. Evolution of white matter lesions in neurofibromatosis type 1: MR findings. *AJR Am J Roentgenol* 1992;159:171–175
6. Fulham MJ, Bizzi A, Dietz MJ, et al. Mapping of brain tumor metabolites with proton MR spectroscopic imaging: clinical relevance. *Radiology* 1992;185:675–686

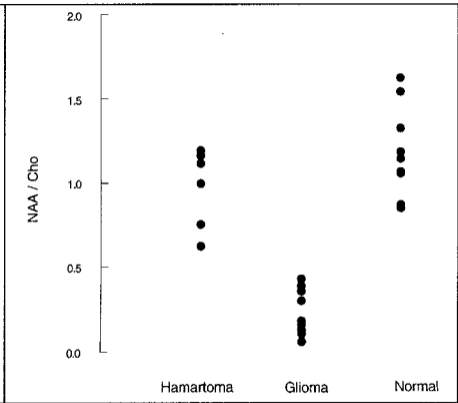




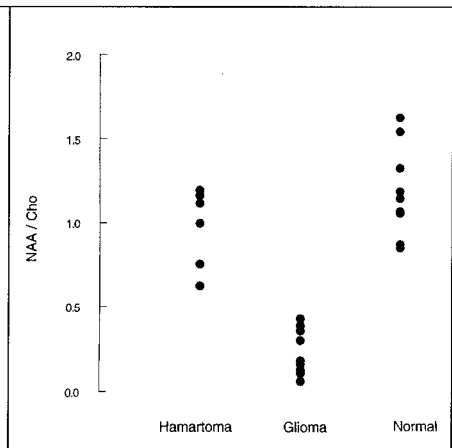
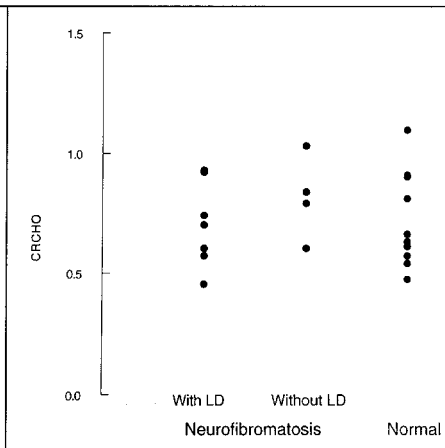
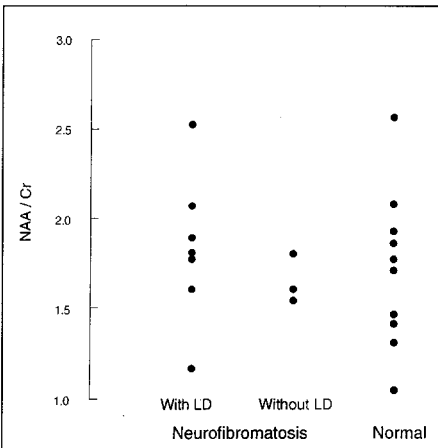
A



B



C



A

B

C

