

Preliminary Experience with MR-Guided Thermal Ablation of Brain Tumors

Yoshimi Anzai, Robert Lufkin, Antonio DeSalles, D. Rex Hamilton, Keyvan Farahani, and Keith L. Black

PURPOSE: To evaluate the feasibility of a technique of MR-guided stereotactic radio frequency ablation, which was developed as a minimally invasive treatment for brain tumors, and to determine MR characteristics and sequential evolution of radio frequency lesions created to ablate brain tumors. **METHODS:** Fourteen lesions in 12 patients with primary and metastatic brain tumors were treated with this technique and followed for up to 10 months. The stereotactic coordinates of the tumor and the angle of the radio frequency probe were calculated on MR imaging. The radio frequency lesion was generated in the awake patient by increasing the temperature to 80°C within the tumor for 1 minute. This was repeated until the entire tumor volume was destroyed. MR imaging was performed before, during, and immediately after the radio frequency procedure, and sequential MR was obtained during clinical follow-up. **RESULTS:** MR imaging clearly showed well-defined radio frequency lesions and provided feedback for treatment planning. The radio frequency lesion boundary was well identified as a dark signal rim on T2-weighted images and showed ring enhancement on contrast-enhanced T1-weighted images. The sequential MR imaging showed the radio frequency lesions decreased in volume in all cases, suggesting focal control. **CONCLUSION:** Stereotactic MR-guided radio frequency brain tumor ablation is a feasible and promising technique that can be an attractive brain tumor treatment alternative. MR provided not only accurate tumor location but also visualization of feedback of thermal tissue changes that reflected therapeutic effect.

Index terms: Interventional neuroradiology; Brain neoplasms, therapeutic radiology; Brain neoplasms, magnetic resonance

AJNR Am J Neuroradiol 16:39–48, January 1995

Radio frequency energy has been used successfully over 3 decades in the neurosurgical field and proved to be a safe, well-controlled, and reproducible energy source (1–5). Radio frequency has been applied for treatment of functional disorders such as Parkinson disease, essential tremor, intractable cancer pain, and trigeminal neuralgia (5–13). Probes have been placed in well-defined lesions of the brain and

spinal cord under fluoroscopy or ventriculography guidance and recently computed tomography (CT) and magnetic resonance (MR) control (1, 7, 8, 10). Because delivery of radio frequency energy during the treatment of functional disorders is controlled by observing changes in patient symptoms, such as tremor or dyskinesia or pain, the main role of imaging is locating the lesion, rather than monitoring treatment effect.

MR imaging has excellent soft-tissue contrast resolution. Small brain tumors that cannot be found on CT often can be easily detected with MR, and appropriate treatment can be performed. Because a mass lesion seen on MR does not necessarily indicate neoplasm, stereotactic biopsy is required in the majority of cases. With the development of MR-compatible stereotactic frames, MR-guided stereotactic biopsy has become a standard procedure at many institutions (8, 10, 14). Once the biopsy

Received February 9, 1994; accepted after revision July 21.

Presented at the 1994 annual meeting of the ASNR, Nashville, Tenn.

From the Departments of Radiological Sciences (Y.A., R.L., D.R.H., K.F.) and Surgery, Division of Neurosurgery (K.L.B., A.A.D.), University of California, Los Angeles, Medical Center.

Address reprint requests to Yoshimi Anzai, MD, Department of Radiological Sciences, UCLA Medical Center, CHS B-3-2275, 10833 LeConte Ave, Los Angeles, CA 90024-1721

AJNR 16:39–48, Jan 1995 0195-6108/95/1601-0039

© American Society of Neuroradiology

needle has reached the lesion, the possibility of providing focal treatment at the same setting can be explored.

We have developed a technique of MR-guided stereotactic radio frequency ablation of brain tumors, based on the combination of three modern techniques: stereotactic neurosurgery for precise placement of devices, radio frequency energy for creating focal thermal coagulation, and MR imaging for locating tumor and monitoring the therapeutic effect. This is a minimally invasive interventional procedure that allows brain tumor ablation under local anesthesia in the MR suite while the patient is awake.

The main objectives of this initial clinical study were to evaluate the feasibility of this technique, and to determine the MR characteristics and sequential evolution of the appearance of radio frequency lesions created within brain tumors.

Materials and Methods

Clinical Study

Patients with a solitary or multiple metastatic tumor, or high-grade primary brain tumor, less than 3 cm in maximal diameter, were considered for this study. Twelve patients with primary or metastatic brain tumors were enrolled in this study. The ages ranged from 20 to 80 years (mean, 57 years). Ten patients had metastatic brain tumor (5 patients with adenocarcinoma, 4 with melanoma, 1 with osteosarcoma) and 2 patients had primary brain tumor (1 patient with oligodendroglioma and the other with glioblastoma multiforme). A total of 14 lesions were treated with stereotactic MR-guided radio frequency ablation. Two patients had two metastatic lesions treated at the same time. The follow-up period ranged from 2 weeks to 10 months.

All patients received a full explanation of their treatment options including surgical resection, stereotactic radiosurgery, conventional radiation, and/or chemotherapy alone. Patients were allowed to volunteer for this study. This protocol was approved by the Human Subject Protection Committee at UCLA. Written informed consent was obtained from all patients. Patients without prior histologic confirmation of their tumor had stereotactic biopsy of the lesion for frozen-section diagnosis in the first part of the thermoablative procedure. Only patients with tumor confirmed with histologic section underwent thermoablation of the lesion.

Surgical Procedure

All patients were premedicated with dexamethasone (Decadron) and anticonvulsants at least 48 hours before the procedure. In the MR suite, an intravenous line was started for antibiotics and light sedation. An MR-compati-

ble Leksell stereotactic frame (Elekta Instruments, Atlanta, Ga) was placed using clean technique. With the frame attached to the patient's head, the patient was placed in the MR scanner where MR images were obtained without gadolinium. All patients had had previous gadolinium-enhanced MR that allowed identification of tumor borders. The stereotactic coordinates of the tumor for placement of the biopsy needle and the radio frequency coagulative lesion were determined in the axial scan. The angles of entrance for the trajectory of the electrode to the tumor were planned on the sagittal (anteroposterior angle) and coronal (right-left angle) scans.

After the pre-radio frequency MR, the patient was withdrawn from the scanner. Local anesthesia was administered at the location of the electrode entrance. A 5-mm skin incision allowed the placement of a small twist drill hole. Biopsy specimens were obtained from the lesion if necessary. After histopathologic diagnosis was confirmed by frozen section, the biopsy needle was removed. The MR-compatible radio frequency probe then was introduced through the same opening, and radio frequency impedance monitoring was performed as the electrode was advanced. The neurologic status was monitored in the awake patient throughout the procedure.

Radio Frequency Ablation

A modified MR-compatible radio frequency lesion generator system (Radionics Inc, Burlington, Mass), which generated 480 KHz sine wave signals, was used in this study. The radio frequency lesion was generated by increasing the temperature to 80°C and maintaining this for 1 minute. This is an accepted technique, well described in the literature, that results in a local area of coagulation necrosis of the tissue (1-4). This 1-minute treatment fraction at different locations in the tumor was repeated until the entire tumor volume was treated. The endpoint was determined by a combination of known probe position, tumor shape and volume, temperature, duration, and MR appearance. Patients were treated using a single insertion of either a 5- or 10-mm exposed-tip straight electrode or a side-advance spring that describes a 10-mm diameter semicircle from the tip of the electrode to create a three-dimensional treatment volume. The goal of the treatment was to cover the entire tumor seen on the pretreatment image plus a small rim of normal surrounding tissue. The probe was removed and the incision was closed using 1 to 2 nylon sutures and covered with a bandage. MR imaging was used to monitor the lesion and confirm its extent before and after treatment in all patients and later during treatment in 3 patients in the series. Patients were observed for 24 hours before discharge.

MR Imaging

In this study, a modified 1.5-T, superconducting MR unit was used. Specific modifications include additional life-support monitoring system, MR-compatible television camera observation for the patient within the magnet, MR-




Fig 1. A, T2-weighted fast spin-echo image of a patient with radio frequency electrode in place confirms the location of the electrode within the tumor (*arrow*).

B, Radio frequency T2-weighted fast spin-echo image obtained immediately after beginning ablation before the appearance of the radio frequency lesion. Slight increased noise is seen because of radio frequency energy delivery inside MR unit; however, the image quality remains acceptable.

compatible computer display for use in MR room, slight enlargement of magnet bore for improved patient access, and integration of compatible radio frequency ablation under MR so that either device would not interfere with the other. Image section thickness of 3 mm with interleaving was used to define tumor location, to determine anatomic relationships with surrounding vital structures, and to measure tumor volume. T2-weighted fast spin-echo imaging (2000–2800/80–90/2 [repetition time/echo time/excitations]) was obtained in axial, coronal, and sagittal planes, providing location of the tumor as well as determination of radio frequency–probe trajectory. Additional T1-weighted spin-echo images (500–650/16–20/2) were obtained. The standard head coil in which a Leksell stereotactic frame could be fitted was used. MR imaging before the procedure was performed with a 28-cm field of view, which is large enough to cover the fiducials to calculate the stereotactic coordinates and angle of trajectory. The remainder of the MR examination was performed with a 22-cm field of view. A 256×192 matrix was used for both T1- and T2-weighted images. The administration of gadolinium was not performed before the radio frequency ablation except in one case, in which tumor was too small and close to the sulcus to be well seen on the noncontrast study. In addition, MR angiography with two-dimensional time of flight (45/8/2) using 60 degree flip angle and 1.5-mm section thickness was obtained in later patients, locating vascular structures at the entry point of the radio frequency probe and along its planned trajectory into the brain.

MR imaging was performed before, during (Figs 1A and B), immediately after, and 1 day, 1 week, 1 month, 3 months, and 6 months after radio frequency ablation. The images were reviewed by two neuroradiologists in conjunction with a review of the clinical data.

Volume Measurement

Three-dimensional reconstruction of the initial brain tumor and the radio frequency lesion was obtained in each

imaging time point using a thresholding technique. The radio frequency lesion was segmented and reconstructed to calculate sequential volumes.

The radio frequency lesion volumes were calculated based on three-dimensional reconstruction of images in all patients. The sequential radio frequency lesion volume was plotted as a function of time after treatment in 6 patients who had more than 3 months follow-up with MR imaging. The volume of the acute radio frequency lesion also was plotted as a function of the time-temperature dose of radio frequency energy delivered.

Results

Clinical Outcome

A summary of the 12 patients and 14 lesions treated by stereotactic MR-guided radio frequency ablation is shown in the Table.

Two patients who had had previous whole-brain radiation and one patient who had had open craniotomy and radiation therapy presented with recurrent tumor, which was treated with radio frequency ablation. One patient had received systemic chemotherapy for osteosarcoma before radio frequency treatment. One patient received whole-brain radiation after stereotactic radio frequency ablation, and 3 months after radiation therapy was completed, she presented with another two lesions that also were treated with stereotactic MR-guided radio frequency ablation. The seven remaining patients had not received any treatment before radio frequency ablation. Six of these patients were over 65 years old.

The radio frequency lesion was large enough to cover the initial tumor volume in all cases. Although the follow-up period was limited, focal

Brain tumors treated by stereotactic MR-guided radio frequency ablation

Patient	Age, y/sex	Histology	Location/ Size, cm	Previous Treatment	Bx?	Radio Frequency Dose, minutes	Follow- up, months
1	44/M	Melanoma	RF/1.2	None	Yes	45	10
2	65/F	Adenocarcinoma	RP/1.0	None	Yes	4	9
3	56/M	Melanoma	LP/0.8	None	Yes	3	8
4	71/F	Adenocarcinoma	LF/1.5	None	Yes	9	6
5	70/F	Glioblastoma multiforme	LF/2.8	None	Yes	9	5
6	75/F	Adenocarcinoma	LF/2.6	None	Yes	16	5
7	45/F	Oligodendroglioma	LF/2.5	Surgery and radiation	Yes	9	4
8	69/M	Melanoma	LF/1.3	None	Yes	3	3
9	20/F	Osteosarcoma	RF/1.0	Chemotherapy	No	10	2
10	40/F	Melanoma	RF/1.0	None	No	4	1.5
			RT/1.0	None	No	3	1.5
11	70/F	Adenocarcinoma	RP/1.2	Whole-brain radiation	No	2	1
			LO/0.8	Whole-brain radiation	No	1	1
12	80/F	Adenocarcinoma	RF/0.8	None	No	1	0.5

Note.—Bx indicates biopsy immediately before radio frequency therapy; F, frontal; P, parietal, T, temporal; and O, occipital.

control was obtained in all lesions treated by radio frequency ablation. Two patients who had active primary cancers (one had melanoma, the other had lung cancer) presented with other metastatic brain tumors after radio frequency ablation. However, no lesion treated by radio frequency ablation showed any disease progression.

Broca aphasia developed in two patients who had tumors adjacent to the left motor cortex; one was transient and completely resolved, the other patient still has mild speech difficulty at 10 weeks after treatment. These symptoms had their onset approximately 10 minutes after completion of the procedure, rather than during or immediately after radio frequency ablation. No other serious adverse events were noted.

MR Findings

The MR appearance of the acute radio frequency lesion consisted of four concentric zones, A–D. Zone A, an innermost central area of high signal intensity on T1-weighted images, was seen in patients who underwent biopsy immediately before radio frequency ablation (Fig 2). This high-signal appearance was not seen in patients who did not undergo biopsy immediately before treatment (Fig 3). Zone B was a second concentric zone isointense to gray matter on T1-weighted images and of low signal intensity on T2-weighted images. Zone C was

the outermost low-signal rim on both T1- and T2-weighted sequences. Zone D corresponded to a perilesional high-signal area suggestive of edema on T2-weighted images without significant mass effect. On postgadolinium images, peripheral enhancement outside the low signal rim (zone C) was seen. Some small tumors (less than 1 cm in diameter) that required a limited radio frequency exposure did not develop a zone D after treatment at all, and central enhancement after gadolinium administration was noted (Fig 4).

Sequential changes of the radio frequency lesion on MR images were studied and several patterns emerged: (a) the central high signal on T1-weighted image persisted 1 to 3 months after procedure and then gradually resolved (Fig 2); (b) the peripheral low-signal rim became well-demarcated and more prominent with time (Fig 4); (c) the perilesional high-signal area was the maximum in size at 1 day to 1 week after therapy, then gradually reduced; however, in some cases it was still seen 6 months after radio frequency ablation; (d) the overall size of the radio frequency lesions gradually reduced with time (Figs 2 and 4); (e) peripheral enhancement was seen up to 6 months after radio frequency ablation. A small radio frequency lesion created for ablation of a metastatic melanoma has greatly decreased in size 6 months after treatment (Fig 4).




Fig 2. Case 1. A 44-year-old man with a history of melanoma presented with a metastatic melanoma in the right frontal lobe.

A, T1-weighted sagittal image before radio frequency treatment shows the large area of edema without evidence of hemorrhage within the tumor.

B, Unenhanced T1-weighted image immediately after radio frequency ablation shows high signal foci in the central portion of the radio frequency lesion (*arrow head*). This is often seen in patients who had biopsy immediately before thermal ablation and is presumably related to heat-induced methemoglobin formation.

C, Gadolinium-enhanced axial image immediately after thermoablation shows well-defined ring enhancement of the radio frequency lesion (*arrow*). Multiple high-signal foci seen outside the head represent fiducials in an MR-compatible stereotactic frame (*small arrow*).

Contrast-enhanced MR images taken 1 month (*D*), 3 months (*E*), and 6 months (*F*) after radio frequency ablation show that radio frequency lesions gradually decrease in size. There is no evidence of tumor progression observed for this 10-month follow-up period.




Fig 3. Case 10. A 40-year-old woman with known history of melanoma presented with four brain tumors. No biopsy was performed immediately before the radio frequency ablation.

A, T1-weighted sagittal image shows a small tumor surrounded by extensive edema (*arrow*).

B, After radio frequency ablation, very little increased signal is present. This is unlike the high signal foci often seen in patients who were treated immediately after biopsy (compare with Figure 2B and 4B).




Fig 4. Case 3. A 56-year-old man with melanoma presented with two metastatic tumors.

A, A small tumor in the left parietal lobe (*small arrow*) was treated with radio frequency ablation, and the other large tumor (*arrow head*) in the right parietal lobe was removed by open craniotomy after thermal ablation of the tumor on the left. Biopsy from this small lesion revealed metastatic melanoma.

B, T2-weighted image immediately after radio frequency ablation shows low-signal rim at the boundary (*arrow*).

C, Gadolinium-enhanced axial image immediately after radio frequency ablation shows enhancement of the radio frequency lesion, representing the area of blood-brain-barrier disruption (*arrow*).

Sequential T2-weighted images obtained 1 month (*D*), 3 months (*E*), and 6 months (*F*) after radio frequency ablation show significant volume reduction of the radio frequency lesion. The peripheral dark rim becomes well demarcated and more prominent 1 month after treatment (*arrowhead*), and the overall lesion size gradually reduces and is barely seen in the image taken 6 months after the radio frequency ablation (*F*).

Volume Measurement

The sequential radio frequency lesion volumes were calculated based on gadolinium-enhanced 3-D reconstruction images in six patients who had more than 3 months follow-up with MR. The outermost enhancing portion was segmented at the lesion margin. The sequential radio frequency lesion volumes were plotted as function of time after treatment in each patient.

A gradually decreasing volume was observed in all patients in follow-up studies (Fig 5). This volume-curve analysis was consistent with the clinical impression that focal control was ob-

tained in all radio frequency-treated lesions. It is hypothesized that a sudden increase in volume could represent progression or recurrence of tumor.

Radio Frequency Lesion Volume versus Radio Frequency Dose

Lesion volumes calculated on gadolinium-enhanced MR images were plotted as function of the radio frequency dose (time in minutes at 80°C), which reflects tissue heating at the electrode tip (Fig 6). The lesion volume did not correlate well with radio frequency dose. Fur-

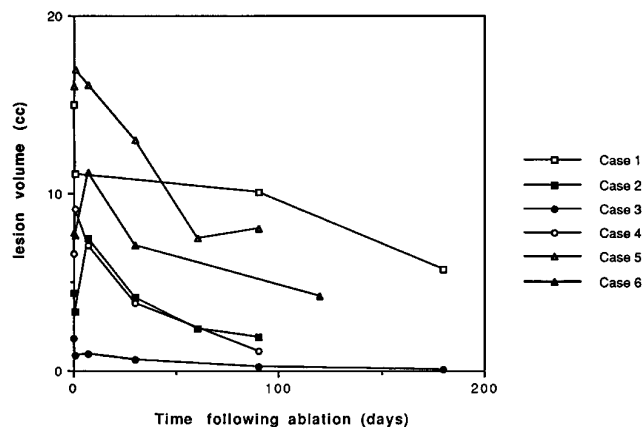


Fig 5. The sequential volume change in radio frequency lesions in patients who had more than 3 months follow-up with MR. The radio frequency lesion volume was plotted as function of time after treatment in six patients. The lesion volume slightly increases up to 7 days after radio frequency therapy and gradually decreases in all patients.

thermore, the lesion size did not increase over a certain volume despite increased radio frequency lesion energy delivery. For example, the volume of the lesion treated for 45 minutes was similar to that treated for 7 minutes. The volume of the radio frequency lesion depends not only on the energy delivered but also on the volume over which the energy is applied. Thus, a large radio frequency lesion could be created, by advancing and/or retracting the radio frequency probe and by using the side arm rather than by merely increasing the dose in the same position. The thermal capability of the tissue also varies depending on whether there are large vessels (acting as heat sinks)

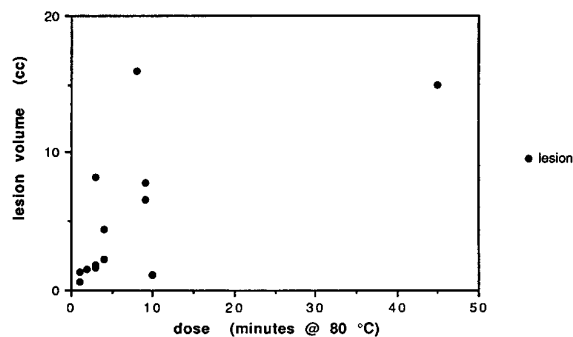


Fig 6. Radio frequency lesion volume versus radio frequency dose.

The acute radio frequency lesion volume calculated on the gadolinium-enhanced MR image was plotted as function of the radio frequency dose (cumulative times in minutes that the tissue was maintained at 80°C). The graph shows that lesion size did not increase over a certain volume despite repeated radio frequency energy delivery.

nearby, which can distort the uniform delivery of a radio frequency dose.

Prediction of radio frequency lesion size is helpful for treatment planning. However, all these factors made accurate preoperative dosimetry planning of limited predictive value for lesion volume and underscore the need for imaging feedback during treatment.

Discussion

The MR appearance of radio frequency lesions in the brain and interpretation of their signal characteristics has been reported (8, 15) in two papers describing radio frequency thalamotomy. It has been reported that the signal intensity change of the radio frequency lesion has been closely related to the MR appearance of intracranial hemorrhage (8).

In our patients the signal intensity changes were consistent with previous animal experiments and previous reports investigating histologic changes after radio frequency ablation in the brain. The innermost high signal on T1-weighted images most likely represents heat-induced methemoglobin conversion from deoxyhemoglobin (Farahani K et al, *Radiology*, 1993; 189(P): 167), which normally takes more than 72 hours in cerebral hematoma without heat induction (16, 17). These high signal foci were seen only in patients for whom biopsy was performed immediately before radio frequency ablation, which presumably caused a small amount of local bleeding. High-signal foci were not observed in three patients who had treatment of five lesions for which biopsy was not necessary. The contribution of a high protein content fluid collection to the high signal foci on the acute radio frequency lesions, however, can not be entirely excluded.

The second zone of low signal intensity corresponded to the area of coagulative necrosis, with resulting loss of tissue water seen in the histologic studies. This phenomenon has been noted in other examples of interstitial thermal tissue injury caused by Nd:YAG laser and represented irreversible tissue damage (18, 19).

The third zone consisting of the low-signal rim was well seen especially in relatively large radio frequency ablations that required multiple radio frequency applications in different locations within the tumor. This most likely represents deoxyhemoglobin in the acute sit-

uation and hemosiderin deposition in later follow-up studies.

The outermost zone of peripheral high signal most likely represents edema in the acute lesion and gliosis in the chronic stage.

The hemoglobin products are a potential, intrinsic marker to help define resolving radio frequency lesions on follow-up MR imaging. In small radio frequency lesions, this ring of hemosiderin was not as visible as in the larger lesions. In these cases, gadolinium enhancement may help to delineate the radio frequency lesion, because peripheral ring enhancement is invariably seen at the boundary of the radio frequency lesion, which presumably corresponds to heat-induced blood-brain-barrier disruption.

One of the clinical issues to be addressed is how to differentiate recurrent tumor adjacent to or inside the radio frequency lesion from resolving radio frequency thermal tissue effects on MR imaging. In this study, sequential volume measurement was helpful for showing no tumor progression. Although we had no treatment failures, we anticipate from experience elsewhere that recurrent tumor could appear as an increasing volume. Increased edema around 1 week after thermal treatment was expected based on previous reports in the animal model (19) as well as with radio frequency thalamotomy in the human (8, 15). This high-signal edema did not show as much mass effect as that often seen with recurrent brain tumors. Therefore, the new onset of mass effect might be one of the MR findings suggesting progression of tumor. We are also beginning protocols using thallium scanning and MR spectroscopy to help in this area.

MR imaging has high soft-tissue contrast, which allows not only precise location of the brain tumor but also visualization of the immediate thermal injury caused by the radio frequency energy. The application of MR angiography allows large cortical vessels to be seen easily without additional contrast agents and avoided during instrumentation. MR image information defines the angle of electrode trajectory as well as how much additional treatment is necessary to cover the entire tumor. Although the physical access of conventional diagnostic MR units is limited, we are installing a new open 0.2-T interventional MR system, which will help overcome this limitation of currently available devices. The rela-

tively large susceptibility artifacts from even MR-compatible electrodes tend to obscure smaller lesions with our current high-field scanner. The use of new lower-field interventional MR units will reduce the susceptibility artifact from instruments.

Interventional MR may be criticized as an expensive technology. However, when compared with more costly inpatient surgical procedures and considering patient morbidity, hospitalization costs, and lost time from work for open surgical procedures, closed MR-guided interventions may potentially lower the ultimate cost of medical care.

Although the number of patients studied was limited, this study demonstrates that stereotactic MR-guided radio frequency ablation of brain tumors is feasible and a promising brain tumor treatment alternative. The advantages of this technique are multiple. First, the procedure is minimally invasive, performed under local anesthesia while patients are awake and communicating with the physician. Neurologic symptoms can be monitored during the entire procedure, whereas many neurologic deficits can not be clearly identified until a patient is awake from general anesthesia often necessary for an open craniotomy. Second, MR-guided stereotactic localization provides accurate targeting of the lesion to minimize damage to surrounding structures. In addition, by the use of low-energy stimulation of the area to be treated before lethal energy delivery, undesired damage to normal functioning brain can be further avoided (1).

Third, radio frequency heat lesions can be clearly identified on MR imaging performed immediately after the procedure, allowing feedback during the procedure. This approach is more analogous to a conventional surgical procedure than to radiation therapy in which there is no immediate imaging feedback of the effects of treatment. Because radio frequency energy creates focal tissue coagulation, this technique can be used in previously fully radiated patients and can be applied and reapplied to multiple lesions.

The entire procedure takes approximately 3 hours including pretreatment and posttreatment MR examinations. With interventional MR scanners, it is anticipated that this would decrease further. This technique requires minimum observation (usually 24 hours after the procedure) and after more experience the

treatment probably can be done entirely on an outpatient basis. This technique has the potential to improve the quality of life of patients and is appealing if this approach could provide therapeutic benefit similar to other treatments.

The limited lesion size created by the radio frequency electrode is one possible limitation of this technique. Several factors influence the radio frequency lesion size, including current intensity, temperature of tip, duration of radio frequency application, size of the exposed electrode (length and diameter), and the properties of the tissue to be treated (4, 20, 21). Increased lesion size can be obtained by repositioning the radio frequency probe, using a probe with a side arm or a probe with larger diameter or length. Once coagulation necrosis takes place, current conductivity will drop off, resulting in the limited lesion size in one location even with long exposure (4). Therefore, the duration of application does not increase the radio frequency lesion size after a certain point. The temperature setting is also one of the factors that influence lesion size. Most radio frequency lesions in the brain are made at electrode-tip temperatures between 60 and 80°C and a duration of 30 to 90 seconds. Tissue vascularity also affects the lesion size and shape. For a given set of parameters, a lesion extends more into areas of white matter than gray matter because of the lower electrical resistance and the greater vascularity of gray matter. Based on theoretical limitation, we currently limit the size of tumors we treat to 3 cm because of swelling after ablation; however, with more experience it may be possible to treat larger lesions.

The risk of hitting major intracranial vessels during instrumentation is not high but still exists, which might cause a significant intracranial hematoma. Careful planning of needle trajectory with MR angiography helps avoid major injuries.

Most patients in this initial clinical study were elderly and had systemic disease, such as hypertension, diabetic mellitus, asthma, or previous lower lobectomy of the lung or systemic chemotherapy. Open craniotomy could have resulted in a very long recovery period, loss of quality of remaining life, and would for many reasons not be desirable for these patients. Stereotactic MR-guided radio frequency ablation is suitable for those patients who have a systemic illness, previous full course of radiation, or mul-

iple small tumors, and those who refuse the other alternatives. Because the maximum follow-up period at the time of this writing was 10 months, the ultimate prognosis for patients treated with this technique remains to be determined. We are now moving into the next phase of evaluation and have begun a randomized clinical trial, comparing patient treatment response with MR-guided stereotactic radio frequency ablation and stereotactic radiosurgery at our institution.

Finally, because the technique is simple, minimally invasive, and effective for focal disease, possible uses of MR-guided radio frequency ablation of tumors elsewhere in the body, such as soft-tissue tumors in the breast, head and neck, abdomen, prostate, and metastatic bone tumors should be explored.

Acknowledgments

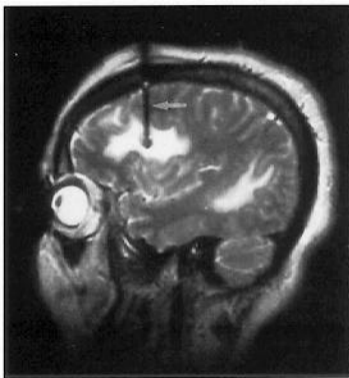
We thank Marco Favilli, RT, for his assistance in 3-D segmentation of tumors and radio frequency lesions, and Eric Behnke, MS, and Gillian Nelson, PA-C, for technical assistance.

References

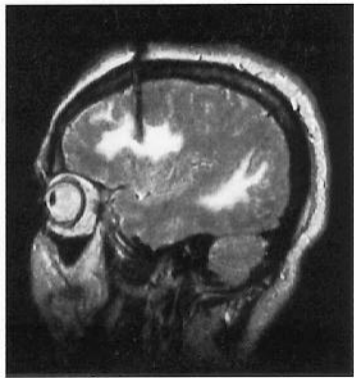
1. Sweet WH, Mark VH, Hamlin H. Radiofrequency lesions in the central nervous system of man and cat, including case reports of eight bulbar pain-tract interruptions. *J Neurosurg* 1960;17: 213-225
2. Aronow S. The use of radiofrequency power in making lesions in the brain. *J Neurosurg* 1960;17:431-438
3. Zervas NT, Kuwayama A. Pathological characteristics of experimental thermal lesions: comparison of induction heating and radiofrequency electrocoagulation. *J Neurosurg* 1972;37(4): 418-422
4. Organ LW. Electrophysiologic principles of radiofrequency lesion making. *Appl Neurophysiol* 1976;39:69-76
5. Kelly PL, Gillingham FJ. The long term results of stereotaxic surgery and L-dopa therapy in patients with Parkinson's disease: a 10-year follow-up study. *J Neurosurg* 1980;53(3):322-337
6. Matsumoto K, Shichijo F, Fukami T. Long term follow-up review of cases of Parkinson's disease after unilateral or bilateral thalamotomy. *J Neurosurg* 1984;60(5):1033-1044
7. Laitinen LV, Harriz M, Bergenheim T. Leksell's posteroventral pallidotomy in the treatment of Parkinson's disease. *J Neurosurg* 1992;76(1):53-61
8. Tomlison FH, Jack CR, Kelly PJ. Sequential magnetic resonance imaging following stereotactic radiofrequency ventralis lateralis thalamotomy. *J Neurosurg* 1991;74:579-584
9. Blond S, Caparros-Lefebvre D, Parker F, et al. Control of tremor and involuntary movement disorders by chronic stereotactic stimulation of the ventral intermediate thalamic nucleus. *J Neurosurg* 1992;77:62-68
10. Hassenbusch SJ, Pillary PK, Barnett GH. Radiofrequency cingulotomy for intractable cancer pain using stereotactic guided by magnetic resonance imaging. *Neurosurgery* 1990;27:220-223

11. Siegfried J. 500 percutaneous thermocoagulation of the gasserian ganglion for trigeminal pain. *Surg Neurol* 1977;8(2):126-131
12. Rosomoff HL, Brown CJ, Sheptak P. Percutaneous radiofrequency cervical cordotomy: technique. *J Neurosurg* 1965;23(5):639-644
13. Nashold BS Jr, Bullitt E. Dorsal root entry zone lesions to control central pain in paraplegics. *J Neurosurg* 1981;55(3):414-419
14. Kondziolka D, Dempsey PK, Lunsford LD, et al. A comparison between magnetic resonance imaging and computed tomography for stereotactic coordinate determination. *Neurosurgery* 1992;30(3):402-407
15. Matsumoto S, Shima F, Hasuo K, et al. MR imaging of stereotactic thalamotomy using radiofrequency methods. *Nippon Acta Radiologica* 1992;52(11):1559-1564
16. Gomori JM, Grossman RI, Yu-lp C, et al. NMR relaxation times and cell integrity. *J Comput Assist Tomogr* 1987;11:684-690
17. Gomori JM, Grossman RI, Goldberg HI, et al. Intracranial hematomas: imaging by high-field MR. *Radiology* 1985;157:87-93
18. Anzai Y, Lufkin RB, Castro D, et al. MR imaging guided interstitial Nd:YAG laser phototherapy: dosimetry study of acute tissue damage in an in vivo model. *J Magn Reson Imaging* 1991;1:553-559
19. Anzai Y, Lufkin RB, Hirshowitz S, Farahani K, Castro DJ. MR imaging: histopathologic correlation of thermal injuries induced with interstitial Nd:YAG laser irradiation in the chronic model. *J Magn Reson Imaging* 1992;2:671-678
20. Alberts WW, Wright EW, Feinstein B, von Bonin G. Experimental radiofrequency brain lesion size as a function of physical parameters. *J Neurosurg* 1966;25:421-423
21. Dieckman G, Gabriel E, Hassler R. Size, form, and structural peculiarities of experimental brain lesions obtained by thermo-controlled radiofrequency. *Confinia Neurol* 1965;26:134-142

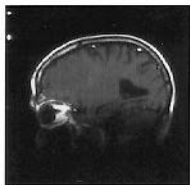
Please see the commentary on page 49 in this issue.



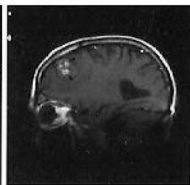
A



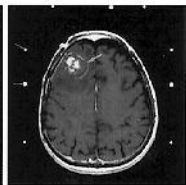
B



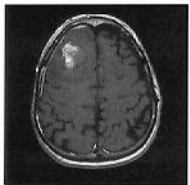
A



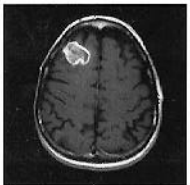B



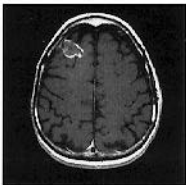C



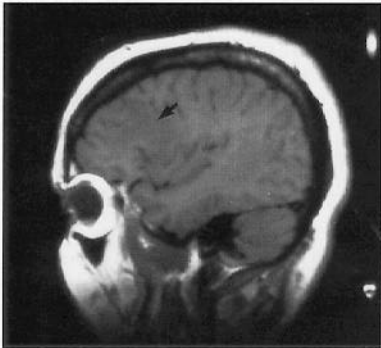
D



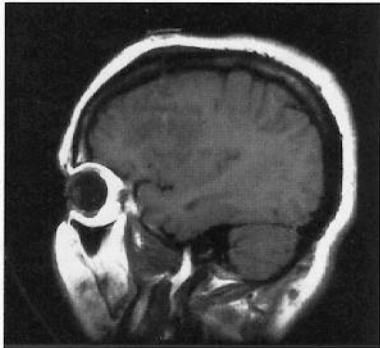
E



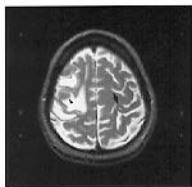
F



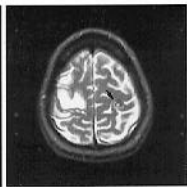
A



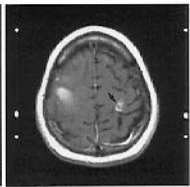
B



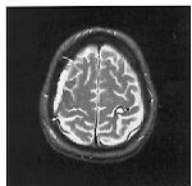
A



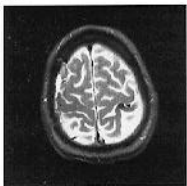B



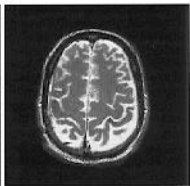C



D



E



F