

# Subarachnoid Hemorrhage due to Late Recurrence of a Previously Unruptured Aneurysm after Complete Endovascular Occlusion

Timothy J. Hodgson, Thomas Carroll, and David A. Jellinek

**Summary:** We present a case of subarachnoid hemorrhage attributed to rupture of an aneurysm 18 months after endovascular occlusion. The aneurysm was diagnosed after the patient had a seizure; however, there was no evidence of subarachnoid hemorrhage. Angiography at 6 months revealed a totally occluded aneurysm. This case illustrates that the long-term results of endovascular occlusion remain uncertain.

Embolization of intracranial aneurysms using Guglielmi detachable coils (GDCs) (Target Therapeutics, Fremont, CA) was described in 1991 (1). Since the initial description, several large series have detailed the efficacy of this treatment (2, 3). While the short-term results have been encouraging, the long-term effects of endovascular treatment require further evaluation. This report describes a case in which a previously unruptured aneurysm was occluded using GDCs and remained occluded at the 6-month follow-up; at 18 months, the patient presented with subarachnoid hemorrhage and a large recurrent aneurysm.

## Case Report

A 55-year-old normotensive woman presented in 1995 with a seizure. A cranial CT scan revealed a probable aneurysm in the region of the left middle cerebral artery bifurcation. At cerebral angiography, an 8-mm aneurysm occurring at the M1-M2 bifurcation was confirmed (Fig 1A) and endovascular embolization was undertaken. With the patient under a general anesthetic, 56 cm of 0.18 GDCs were deployed, including an 8 mm × 30-cm coil, a 4 mm × 10-cm coil, a 4 mm × 10-cm coil, and a 4 mm × 6-cm coil. Occlusion was considered to be greater than 90% (Fig 1B). Follow-up angiography at 6 months showed the aneurysm to be totally occluded (Fig 1C). Further angiography was planned at 2 years.

Eighteen months after the initial embolization, the patient presented with a subarachnoid hemorrhage, with blood localized to the left sylvian fissure. Angiography revealed a large recurrent aneurysm with the coil ball pushed anteromedially (Fig 1D). Further embolization was considered technically possible, but craniotomy and surgical clipping were undertaken to achieve a more permanent occlusion. Because of the position

of the coil mass, clip closure across the aneurysmal neck proved impossible. Temporary middle cerebral artery occlusion was necessary to open the aneurysmal sac and remove the coil mass. It was apparent on opening the aneurysmal sac that the anteromedial part of the aneurysm contained coils firmly embedded in organized thrombus. The posterolateral part of the aneurysm contained uncoagulated blood in free communication with the interior of the middle cerebral artery bifurcation. Postoperatively, the patient was noted to have a right hemiplegia, which has not improved.

## Discussion

Embolization of intracranial aneurysms using GDCs has been shown to be effective in reducing the risk of subarachnoid hemorrhage (2). GDC embolization is particularly suited to aneurysms 4 to 10 mm in diameter with a small neck (less than or equal to 4 mm); it becomes less favorable in aneurysms with wide necks (greater than 4 mm). Complete occlusion of the aneurysm, as demonstrated by cerebral angiography, is thought to prevent subarachnoid hemorrhage in both the short and intermediate term (3). The long-term outcome remains to be determined. Incomplete occlusion reduces the risk of subarachnoid hemorrhage but partial treatment cannot be considered totally protective (2).

Various theories have been postulated to explain the mechanism of action of the GDC system. Electrothrombosis occurring at the time of the procedure followed by subsequent organization of the thrombus has been suggested (4). Animal models with venous pouches surgically anastomosed to carotid arteries have suggested that neoendothelialization takes place as early as 2 weeks after GDC embolization (5). Formation of a medialike structure separating the aneurysm from the lumen of the artery has been shown at 3 months (6, 7). However, other studies have suggested that the initial electrothrombosis and subsequent neoendothelialization with formation of a medialike structure may not occur to any significant extent (7-10).

Molyneux et al (7) reported two patients who died

Received October 16, 1997; accepted after revision March 9, 1998.

From the Departments of Neuroradiology (T.J.H.) and Neurosurgery (T.C., D.A.J.), Royal Hallamshire Hospital, Sheffield, U.K.

Address reprint requests to Dr. T. J. Hodgson, Department of Neuroradiology, Royal Hallamshire Hospital, Glossop Rd, Sheffield S10 2JF, U.K.

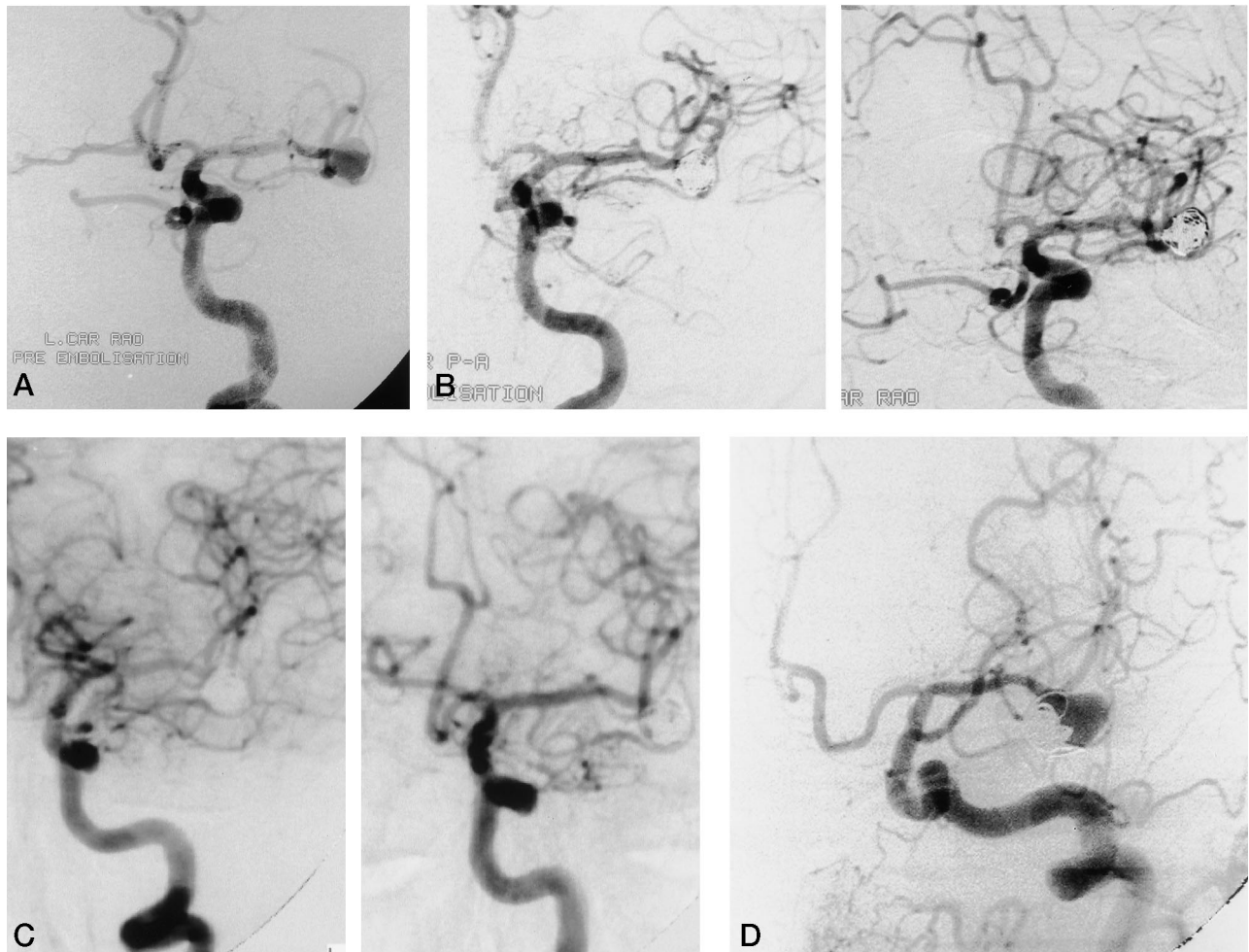


FIG 1. 55-year-old woman with CT findings of a probable aneurysm in the region of the left middle cerebral artery bifurcation.

- A, Left carotid angiogram before embolization shows an 8-mm aneurysm at the left middle cerebral artery bifurcation.  
 B, Left carotid angiogram, posteroanterior (*left*) and right anterior oblique (*right*) projections, immediately after embolization show a greater than 90% occlusion.  
 C, Left carotid angiogram, posteroanterior (*left*) and right anterior oblique (*right*) projections, at 6 months show a totally occluded aneurysm.  
 D, Left carotid angiogram 18 months after embolization reveals large recurrent aneurysm with the coil ball lying medially.

of causes unrelated to previous GDC treatment. Death occurred 2 and 6 months, respectively, after the procedure. Histologic examination revealed a lack of organization of blood clot within the aneurysm, but these authors suggest this may not be important in long-term occlusion, as the position of the coils remained unchanged between the final angiogram and death. Our case calls into question the validity of this statement, as the coils were firmly embedded in organized thrombus.

Factors that are thought to contribute to successful aneurysmal obliteration include small size, well-defined neck, tight coil compaction, and parent vessel flow directed away from the coil mass. The initial tightness of the coil packing has been shown to be an important factor in recurrence and rebleeding. A recent study has shown that in a 6-month follow-up of incompletely embolized aneurysms after subarachnoid hemorrhage, the rate of rehemorrhage was 2.2% (2). The position of the aneurysm in relation to parent vessel flow has also been postulated as a factor in

aneurysmal recurrence and regrowth. In one study, follow-up of a group of 55 patients treated with GDCs suggested that completely occluded aneurysms occurring remote from bifurcation points (and therefore not subject to the direct force of blood flow) were unlikely to recanalize (Borchers DJ, paper presented at the annual meeting of the American Association of Neurosurgeons, Minnesota, 1996). Aneurysms occurring at the carotid and basilar bifurcations are at particular risk of this hemodynamic effect, with aneurysms of the middle cerebral artery bifurcation less so.

Our case illustrates that despite the angiographic presence of "total" occlusion at 6 months, regrowth and rupture occurred 12 months later. It is interesting to speculate whether regrowth had occurred over a period of months or developed acutely with subsequent rupture. One could further speculate whether the regrowth was from the original coiled aneurysm or from the development of a second, new, daughter aneurysm adjacent to the original. Our case

is made more unusual in that the aneurysm was initially unruptured.

### Conclusion

The short and intermediate results of GDC embolization are extremely promising, but the long-term results remain to be established. The length and frequency of angiographic follow-up to detect recurrence also remain an unresolved question, particularly if the recurrence developed over a short period of time before rupture.

### References

1. Guglielmi G, Viñuela F, Dion J, Duckwiler G. **Electrothrombosis of saccular aneurysms via endovascular approach, 2: preliminary clinical experience.** *J Neurosurg* 1991;75:8–14
2. Viñuela F, Duckwiler G, Mawad M. **Guglielmi detachable coil embolization of acute intracranial aneurysm: perioperative anatomical and clinical outcome in 403 patients.** *J Neurosurg* 1997;86:475–482
3. Malisch TW, Guglielmi G, Viñuela F, et al. **Intracranial aneurysms treated with Guglielmi detachable coil: midterm clinical results in a consecutive series of 100 patients.** *J Neurosurg* 1997;87:176–183
4. Guglielmi G, Viñuela F, Septka I, Macellari V. **Electrothrombosis of saccular aneurysms via endovascular approach, 1: electrochemical basis, technique and experimental results.** *J Neurosurg* 1991;75:1–7
5. Tenjin H, Fushiki S, Nakahara Y, et al. **Effect of Guglielmi detachable coils on experimental carotid artery aneurysms in primates.** *Stroke* 1995;20:2075–2080
6. Mawad M, Mawad JK, Cartwright J, Gokasian Z. **Long-term histopathologic changes in canine aneurysms embolized with Guglielmi detachable coils.** *AJNR Am J Neuroradiol* 1995;16:7–13
7. Molyneux AJ, Ellison DW, Morris J, Byrne JV. **Histological findings in giant aneurysms treated with Guglielmi detachable coils.** *J Neurosurg* 1995;83:129–132
8. Horowitz M, Samson D, Purdy P. **Does electrothrombosis occur immediately after embolization of an aneurysm with Guglielmi detachable coils?** *AJNR Am J Neuroradiol* 1997;18:510–513
9. Mizoi K, Yoshimoto T, Takahashi A, Nagamine Y. **A pitfall in the surgery of a recurrent aneurysm after coil embolization and its histological observation clinical case report.** *Neurosurgery* 1996;39:165–168
10. Reul J, Weis J, Spetzger U, Konert T, Fricke C, Thron A. **Long-term angiographic and histopathological findings in experimental aneurysms of the carotid bifurcation embolized with platinum and tungsten coils.** *AJNR Am J Neuroradiol* 1997;18:35–42

Please see the Editorial on page 1809 in this issue.