
Bone Erosion Caused by Sinonasal Cavernous Hemangioma: CT Findings in Two Patients

Hyung-Jin Kim, Jung Hee Kim, Jae Hyoung Kim, and Eui Gee Hwang

Summary: We report two cases of cavernous hemangioma originating in the sinonasal cavity. Although CT showed some enhancing areas within both tumors, the substantial bone destruction caused by these tumors made it difficult to differentiate them from the more common malignant epithelial tumors. Angiography was performed in one patient and showed characteristic pooling of contrast material.

Index terms: Hemangioma; Paranasal sinuses, neoplasms; Bones

Although soft-tissue hemangiomas are relatively common in the head and neck, they occur infrequently in the sinonasal cavity (1–5). Sometimes, they can produce destruction of the adjacent bones, making it difficult to differentiate them from the more common malignant epithelial tumors on the basis of the imaging findings (4, 6). We report two cases of sinonasal cavernous hemangioma, both of which showed rather significant bone erosion on computed tomography (CT).

Case Reports

Case 1

A 37-year-old man was referred to our hospital because of the suspicion of nasal cancer. He had had nasal obstruction on the right side and intermittent epistaxis for 1 year. On inspection, the nasal cavity on the right side was obstructed by a large necrotic mass that bled easily when touched lightly. CT scans after intravenous administration of contrast material showed a large, inhomogeneously enhancing soft-tissue mass in the right maxillary sinus and nasal cavity (Fig 1A and B). The nasal turbinates and the medial wall of the maxillary sinus were destroyed by the mass, and the nasal septum was apparently displaced but considered to be intact. A small defect in the posterior wall of the maxillary sinus was shown also. The mass apparently invaded the ethmoidal sinus and the orbit through the

maxilloethmoidal plate and floor of the orbit, respectively. There was erosion of the bony margin of the nasolacrimal duct. Because of the impression of sinonasal cancer, biopsy was done from the nasal cavity; histology was reported as cavernous hemangioma.

For the preoperative evaluation, carotid angiography was performed, which revealed dense poolings of contrast material within the tumor (Fig 1C). Except for persistent faint tumor staining, there was no significant tumor vascularity or arteriovenous shunting. The sphenopalatine and greater palatine arteries were only mildly dilated; both were embolized with gelatin pledgets (Gelfoam; Upjohn, Kalamazoo, Mich).

Medial maxillectomy was performed the next day. The surgical findings correlated well with the CT findings. The nasal septum was found to be intact at surgery. The mass was excised in toto. There was no significant hemorrhage during surgery. Histologic examination of the resected specimen proved it to be cavernous hemangioma. No cytologic or histologic features suggesting malignancy were seen in any sections of the lesion.

Case 2

A 53-year-old woman had frequent epistaxis and stuffiness in the left nostril that had persisted for 4 years. Physical examination showed a large, friable, and easily bleeding mass in the nasal cavity on the left side.

CT scans after intravenous administration of contrast material showed a large, heterogeneous mass in the nasal cavity and maxillary sinus on the left side (Fig 2). Although there were some enhancing portions, larger areas of the tumor did not enhance. There was widespread erosion of adjacent bones, including the nasal turbinates, medial wall of the maxillary sinus, maxilloethmoidal plate, and inferomedial wall of the orbit. The mass extended to the posterior nasopharynx on the left side. Biopsies attempted twice during the hospital stay, one in the nasal cavity and another in the maxillary sinus, revealed only blood clots and chronic necrotizing inflammation.

Received November 3, 1993; accepted after revision February 23, 1994.

From the Departments of Diagnostic Radiology (H-J.K., Ju.H.K., Ja.H.K) and Otorhinolaryngology (E.G.H.), Gyeongsang National University Hospital, Chinju, Korea.

Address reprint requests to Hyung-Jin Kim, MD, Department of Diagnostic Radiology, Gyeongsang National University Hospital, 92 Chilam-dong, Chinju 660-702, Korea.

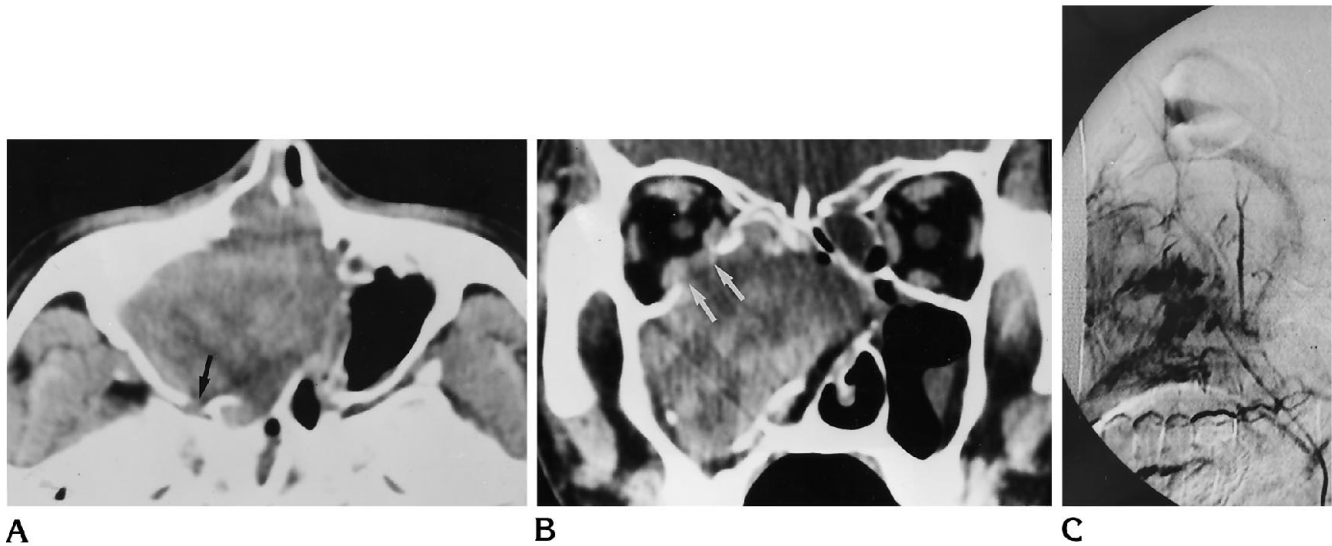


Fig 1. Case 1.

A, Axial and B, coronal CT scans show a large, inhomogeneously enhancing soft-tissue mass in the nasal cavity and maxillary sinus on the right side. The nasal turbinates and the medial wall of the maxillary sinus are widely eroded by the mass. The mass directly invades the ethmoidal sinus and the orbit. Note the focal destruction of the posterior wall of the right maxillary sinus (*black arrow*) and the inferomedial wall of the right orbit (*white arrows*). Also note the eroded right nasolacrimal duct in A.

C, Lateral view of intraarterial digital subtraction angiogram shows dense pooling of contrast material within the sinonasal tumor characteristic of hemangioma.

Surgical findings confirmed the bony erosion shown on CT. Incidentally, there was a separate mass in the ethmoidal sinus that could not be distinguished from the antro-nasal mass on CT. No significant hemorrhage occurred during surgery. Histologic examination proved both the antro-nasal and ethmoidal tumors were benign cavernous hemangiomas.

Discussion

Although controversies exist as to the pathogenesis of hemangiomas, histologically they are divided into two types, capillary and cavernous, depending on the dominant vessel size at

microscopy (5). The sinonasal cavity is an uncommon site of hemangiomas of the head and neck. Most nasal hemangiomas arise from the nasal septum or vestibule and are of capillary type. Only a few arise from the lateral wall of the nose, and these usually are cavernous (7). In the paranasal sinuses, hemangiomas are even rarer. Nonosseous hemangiomas of paranasal sinus origin have been reported in five cases (1-4, 6). In our cases, it is difficult to determine the precise site of origin. They might originate either from the lateral wall of the nasal cavity or from the medial wall of the maxillary sinus.

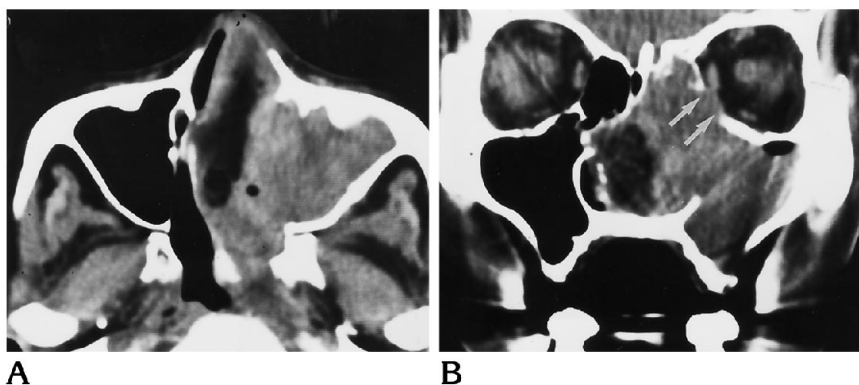


Fig 2. Case 2.

A, Axial and B, coronal CT scans show a large, inhomogeneously enhancing soft-tissue mass in the nasal cavity and maxillary sinus on the left side that is very similar to the mass in Figure 1. In addition, the mass extends to the nasopharynx posteriorly. Note the focal erosion of the inferomedial wall of the left orbit (*arrows*). Also note bone erosion around the left nasolacrimal duct in A and the inferolateral wall of the nasal cavity in B. The bony defect in the inferior wall of the left maxillary sinus resulted from the Caldwell-Luc operation, and the very low density between the tumor and the nasal septum is caused by packing from the previous biopsy.

However, the intact nasal septum and overlying maxilla and nasal bone clearly exclude these sites as the origin of the tumors.

Regardless of the site of origin, the tumors in our cases had several common clinical and radiologic characteristics: the patients' chief symptoms were persistent epistaxis and nasal obstruction, the tumor size was large enough to cause significant bone erosion, and the enhancement pattern on CT was inhomogeneous.

Hemangiomas of the sinonasal cavity are reported to cause changes in adjacent bone. Typically, bone changes appear benign on imaging studies. According to Dillon et al (5), three of six cases of capillary hemangioma of the nasal vault were accompanied by changes in adjacent bone. They reported that all three had benign-appearing bone changes consisting of expansion or remodeling of a long-standing nature (5). However, there have been cases of extensive bone destruction caused by hemangiomas of the paranasal sinus. Hayden et al (6) reported two cases of cavernous hemangioma of the sphenoidal sinus that caused extensive destruction of the skull base. Likewise, both of the tumors we describe caused significant erosion of adjacent bones. The nasal turbinates, medial wall of the maxillary sinus, maxilloethmoidal plate, and walls of the bony orbit were eroded either partially or completely. Although some enhancing portions were noted on CT scans, CT gave no additional information about the nature of the tumor, because even larger areas did not enhance because of necrosis and hemorrhage within the tumor. Furthermore, phleboliths, which are characteristic of cavernous hemangioma, were not contained in either of the tumors. These nonspecific CT features, in conjunction with the associated bone erosion, made the CT diagnosis quite difficult.

Angiography and transarterial embolization for the management of hemangiomas are valuable because biopsy or surgical intervention can lead to sudden loss of large quantities of blood. The fear of this mishap is more with cavernous hemangiomas than with capillary types (8). At angiography, foci of pooling of contrast material within the lesion, as was

shown in one of our cases, confirm the diagnosis of hemangioma. Fortunately, both of our patients underwent biopsies and operation without substantial bleeding. This may reflect no or only minimal arterial circulation in the tumors in our cases, as was shown on angiography in one patient.

Our experience suggests that benign cavernous hemangiomas of the sinonasal cavity can cause rather substantial bone erosion, the appearance of which on CT can mislead the radiologist to the false diagnosis of a malignant tumor. This kind of bone erosion can also occur with other benign lesions such as inverted papillomas or sinonasal polyps. The radiologist should not presume that a lesion is malignant simply because a defect in the bone is visualized on imaging studies. The long duration of frequent epistaxis and nasal obstruction can aid in differential diagnosis. Angiography is always warranted if there is any suspicion about the nature of these vascular tumors, not only because it can enable the correct diagnosis but also because, with the aid of transarterial embolization, undue hemorrhage during surgical intervention can be avoided.

References

1. Most DS. Hemangioma of the maxillary sinus. *Oral Surg Oral Med Oral Pathol* 1985;60:485-486.
2. Yasuoka T, Okumura Y, Okuda T, Oka N. Hemangioma and malignant hemangioendothelioma of the maxillary sinus: case reports and clinical consideration. *J Oral Maxillofac Surg* 1990;48:877-881.
3. Fu Y-S, Perzin KH. Non-epithelial tumors of the nasal cavity, paranasal sinuses, and nasopharynx: a clinicopathological study, I: general features and vascular tumors. *Cancer* 1974;33:1275-1288.
4. Mahindra SM, Malik GB, Bais AS, Logani KB. Vascular hamartoma of the paranasal sinuses. *Acta Otolaryngol (Stockh)* 1981;92:379-382.
5. Dillon WP, Som PM, Rosenau W. Hemangioma of the nasal vault: MR and CT features. *Radiology* 1991;180:761-765.
6. Hayden RE, Luna M, Goepfert H. Hemangiomas of the sphenoid sinus. *Otolaryngol Head Neck Surg* 1980;88:136-138.
7. Som PM. Sinonasal cavity. In: Som PM, Bergeron RT, eds. *Head and Neck Imaging*. St Louis: Mosby-Year Book, 1991:51-276
8. Afshin H, Sharmin R. Hemangioma involving the maxillary sinus. *Oral Surg Oral Med Oral Pathol* 1974;38:204-208.