
Masticator Muscle Enhancement in Subacute Denervation Atrophy

Steven B. Davis, Vincent P. Mathews, and Daniel W. Williams III

Summary: Six months after pontine hemorrhage, a 28-year-old woman exhibited masticator muscle enhancement on MR after gadolinium administration, attributable to denervation atrophy.

Index terms: Muscles, degeneration; Mouth, magnetic resonance

Atrophy of the muscles of mastication is a well known indirect sign of damage to the mandibular division of the trigeminal nerve (V3). Because V3 motor palsy is difficult to diagnose clinically, computed tomography (CT) or magnetic resonance (MR) imaging of the head and neck often provide the only evidence of masticator space muscle atrophy (1). This finding, in turn, should alert the physician to the possibility of head and neck neoplasm or brain stem abnormality. The imaging characteristics of denervation atrophy have been well described previously (1-3). We present a case of enhancement of atrophic muscles of mastication in a patient with a history of pontine hemorrhage.

Case Report

A 28-year-old white woman with a long-standing history of uncontrolled hypertension presented to the emergency room with sudden onset of headache, blurred vision, slurred speech, and left-sided weakness and numbness. A head CT scan at that time showed hemorrhage in the right posterior pons and midbrain. Neurologic examination revealed numbness on the left side of the body and several cranial nerve palsies, including right cranial nerves V, VI, and VII. The patient made a slow recovery and was discharged after 6 weeks, with residual cranial nerve palsies. The cause of her brain stem hemorrhage was not definitely identified, but was believed to be either hypertension or a small vascular malformation in the brain stem.

A follow-up MR study approximately 6 months after her event showed residual blood products (hemosiderin) in the right posterior pons (Fig 1A). Moderate atrophy of the right muscles of mastication was also noted (Fig 1B). On the

precontrast T1-weighted images slightly increased signal was noted in the affected muscles, indicating partial fatty replacement. They also demonstrated abnormal hyperintensity on T2-weighted images (Fig 1C). In addition, after the intravenous administration of gadolinium, diffuse enhancement of the involved muscles was noted on T1-weighted images (Fig 1D). Minimal enhancement in the region of the previous pontine hemorrhage also was noted. At the time of this follow-up MR study, the patient was afebrile, experienced no face or jaw pain, and had a normal white blood cell count, excluding an inflammatory process as the cause of the muscle enhancement.

Discussion

Denervation of skeletal muscle results in typical histologic, ultrastructural, enzymatic, and metabolic changes, which are observed in conjunction with atrophy of the muscle fibers (4-6). In chronically denervated muscle, fatty infiltration eventually develops, a change that is easily detected with either CT or MR imaging (7, 8).

Several studies have shown that blood flow to denervated muscle is increased relative to normal muscle (9, 10). Animal studies have shown that in denervated, atrophic skeletal muscle, the total number of capillaries supplying the muscle is unchanged, but the concentration, or number of capillaries per unit area or volume of muscle, increases as atrophy progresses (11). Functionally, this vascular arrangement results in "luxury perfusion" to the denervated muscle. Carpenter and Karpati showed similar increase in the number of capillaries per transverse muscle fiber area in chronic human denervation atrophy. Additionally, however, these investigators observed necrosis of capillaries in atrophic muscle. Their conclusions were that the capillary necrosis develops in response to the mus-

Received April 19, 1994; accepted after revision June 28.

From the Department of Radiology, Bowman Gray School of Medicine, Winston-Salem, NC.

Address reprint requests to Daniel W. Williams III, MD, Department of Radiology, Bowman Gray School of Medicine, Medical Center Boulevard, Winston-Salem, NC 27157.

AJNR 16:1292-1294, Jun 1995 0195-6108/95/1606-1292 © American Society of Neuroradiology

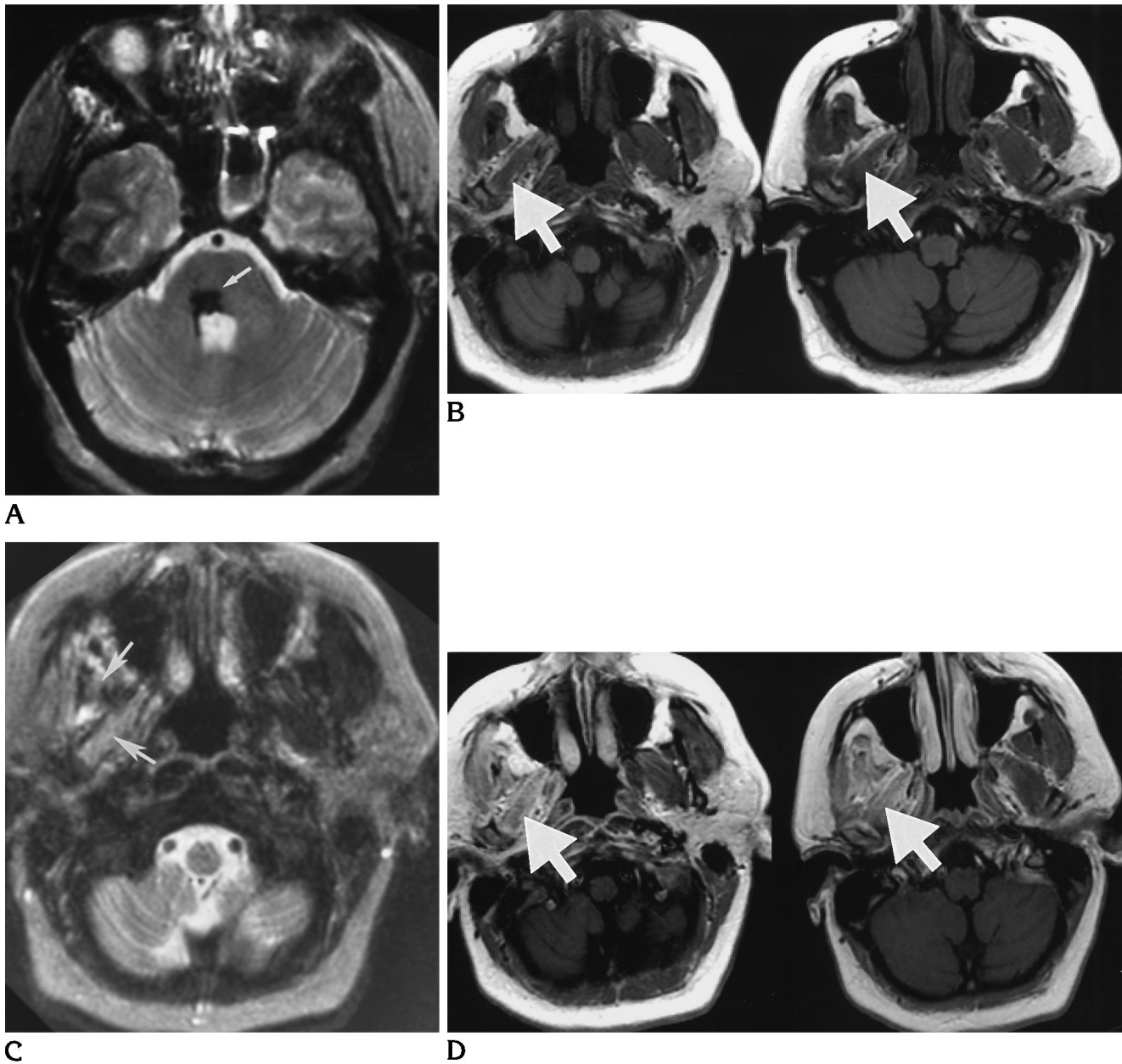


Fig 1. MR study of a 28-year-old woman performed 6 months after pontine hemorrhage.
 A, Axial T2-weighted (3000/90/1) image showing residual blood products (hemosiderin) in the right posterior pons (*white arrow*).
 B, Axial T1-weighted (600/15/1) image showing atrophy of right muscles of mastication (*white arrow*). Compare with normal muscles on left.
 C, Axial T2-weighted (3000/90/1) image showing increased signal in right muscles of mastication (*white arrows*).
 D, Axial T1-weighted gadolinium-enhanced images show enhancement in right muscles of mastication (*white arrow*).

cle being relatively overvascularized as an attempt to decrease unnecessary perfusion (12).

Fleckenstein et al described nonenhanced MR imaging findings in denervated skeletal muscles (3). In addition to the bright T1 signal in chronically denervated, fatty-replaced muscle, they observed increased T2 signal in "sub-acute" muscle denervation. They attributed this

phenomenon to relatively increased tissue water; that is, the extracellular, extravascular space increases in atrophying muscle.

Normal skeletal muscle is known to enhance mildly with gadolinium (13). Injected gadolinium is present both in the intravascular and extracellular/interstitial space in most tissues. In particular, the extraocular muscles normally

exhibit more prominent MR contrast enhancement than other skeletal muscles. This has been attributed to the rich vascularity and prominent extravascular/extracellular space unique to these muscles (14).

In the case presented, the atrophic masticator muscles both enhanced significantly with gadolinium and demonstrated increased signal on T2-weighted images. The signal characteristics on T2-weighted images are likely a result of increased tissue water in subacutely denervated muscle relative to normal nonatrophic muscle (ie, enlarging extracellular space). The enhancement in the atrophic masticator muscles has two possible explanations. First, relative blood flow to denervated muscle is increased, which results in more intense enhancement compared with normal muscle. Second, given that gadolinium accumulates in the extracellular space and that the extracellular space is more prominent in atrophying muscle, relative enhancement would be expected to be increased over normal muscle.

In conclusion, we have described MR contrast enhancement in denervation muscle atrophy and its possible explanations based on previous experimental work. The importance of this observation is to recognize it as an expected finding in some cases of subacute denervation atrophy and to avoid confusing it with an inflammatory or neoplastic process. Further investigation could determine the frequency of gadolinium enhancement in denervation atrophy and its temporal relationship to the initial insult and the development of fatty replacement of muscle.

References

1. Harnsberger HR, Dillon WP. Major atrophic patterns in the face and neck: CT evaluation. *Radiology* 1985;155:665-670
2. Shellhas KP. MR imaging of muscles of mastication. *AJR Am J Roentgenol* 1989;153:847-855
3. Fleckenstein JL, Watumull D, Conner KE, et al. Denervated human skeletal muscle: MR imaging evaluation. *Radiology* 1993;187:213-218
4. Romanul FC, Hogan EL. Enzymatic changes in denervated muscle. *Arch Neurol* 1965;13:263-282
5. Stonnington HH, Engel AG. Normal and denervated muscle: a morphometric study of bone structure. *Neurology* 1973;23:714-724
6. Bass A. Energy metabolism in denervated muscle. In: Gutman E, ed. *The Denervated Muscle*. Prague: Czechoslovak Academy of Sciences, 1962:203-272
7. Termote JL, Baert A, Crolla D, et al. Computed tomography of the normal and pathologic muscular system. *Radiology* 1980;137:439-444
8. Shabas D, Gerard G, Rossi D. Magnetic resonance imaging examination of denervated muscle. *Comput Radiol* 1987;11:9-13
9. Hudlická O. Blood flow and oxygen consumption in muscles after section of ventral roots. *Circ Res* 1967;20:570-577
10. Bondy SC, Purdy JL, Carroll JE, Kaiser KK, et al. The rate of nutrient supply to normal and denervated slow and fast muscle, and its relation to muscle blood flow. *Exp Neurol* 1976;51:678-683
11. Hassler O. The angioarchitecture of normal and denervated skeletal muscle. *Neurology* 1970;20:1161-1164
12. Carpenter S, Karpati G. Necrosis of capillaries in denervation atrophy of human skeletal muscle. *Muscle Nerve* 1982;5:250-254
13. Elster AD, Jackels SC, Allen NS, Marrache RC. Europium-DTPA: a gadolinium analogue traceable by fluorescence microscopy. *AJNR Am J Neuroradiol* 1989;10:1137-1144
14. Kaissar G, Kim JH, Bravo S, Sze G. Histologic basis for increased extraocular muscle enhancement in gadolinium enhanced MR imaging. *Radiology* 1991;179:541-542