
Basal Ganglia Hemorrhage Related to Lightning Strike

Bertan Ozgun and Mauricio Castillo

Summary: We describe a case of bilateral basal ganglia hemorrhage after a lightning strike to the head documented by a CT scan. Review of the literature shows this to be the most common brain imaging finding that can be attributed to a lightning strike. Several mechanistic theories are discussed, with the most plausible one being related to preferential conduction pathways through the brain.

Index terms: Basal ganglia, hemorrhage; Brain, injuries

Lightning strikes are the leading cause of weather-related fatalities in the United States. It is estimated that approximately 300 people are struck by lightning each year, with roughly one third of these cases being fatal (1). Immediate neurologic effects range from transient deficits such as loss of consciousness, weakness, amnesia, and paresthesias to devastating long-term deficits (2). A delayed myelopathy is also well documented (3). We report the case of basal ganglia hemorrhage after a lightning strike.

Case Report

A 32-year-old man was working on a metal dredge boat when he was struck by lightning in the head. A witness immediately began cardiopulmonary resuscitation. The victim resumed spontaneous breathing within 30 seconds.

Physical examination revealed a pulse rate of 135 with atrial fibrillation and a blood pressure of 140/90. There were 10% total body surface area burns on his neck beneath a metal necklace, his torso beneath a metal belt buckle, his penis beneath his pants zipper, and his thighs in a "ferning" pattern. His left tympanic membrane was perforated, and he has bilateral mixed sensorineural and conductive deafness. The patient was lethargic but able to follow commands. Cranial nerves were otherwise intact. Strength was preserved in all four extremities, but there were bilateral extensor plantar responses and ataxic gait. Sensory examination was normal. A computed tomographic scan of the head showed bilateral basal ganglia hemorrhages (Fig 1).

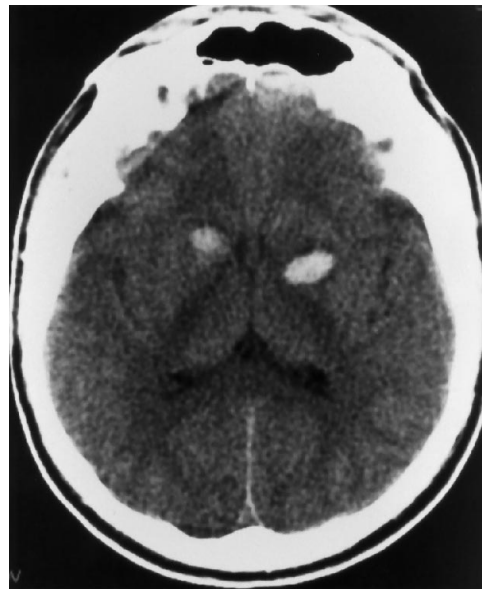


Fig 1. Noncontrast computed tomographic section shows bilateral hemorrhages (*left* greater than *right*) in the lentiform nuclei.

The patient spontaneously converted to sinus rhythm, and his sensorium gradually cleared. He remained ataxic and deaf at discharge 5 days after the lightning strike. Eight months after the incident he has recovered neurologically but remains profoundly deaf.

Discussion

In four cases of post-lightning strike basal ganglia hemorrhage, computed tomographic findings were initially normal in two and showed the hemorrhage in two patients (3–6). The magnetic resonance findings in four patients included one normal study, one with evidence of severe hypoxic encephalopathy, one with a right posterior parietal infarction, and one showing atrophy of the superior cerebellum (7, 8).

Received January 27, 1994; accepted after revision April 13.

From the Department of Radiology, University of North Carolina School of Medicine, Chapel Hill.

Address reprint requests to Mauricio Castillo, MD, Department of Radiology, Campus Box 7510, University of North Carolina at Chapel Hill, Chapel Hill, NC 27599-7510.

AJNR 16:1370–1371, Jun 1995 0195-6108/95/1606–1370 © American Society of Neuroradiology

The pathophysiology of basal ganglia hemorrhage after a lightning strike remains unclear, but the following mechanisms have been proposed: a direct heating effect of the current; a direct electrolytic effect of the electrical charge; the actual mechanical trauma of the lightning strike; and intense peripheral vasoconstriction resulting in acute hypertension (5). The latter explanation is considered unlikely, because hemorrhage in acute hypertension does not seem to have a specific predilection for the basal ganglia as in chronic hypertension. Similarly, intracranial hemorrhages related to blunt trauma do not tend to occur in the basal ganglia, and therefore mechanical trauma is also a less-likely explanation. It is more likely that intracranial hemorrhage is caused directly by electrical current passing through the brain. It has been shown experimentally that limb-to-limb electrical discharges will create no current in the brain, so for direct brain injury to occur, lightning must strike the head (9). Electricity deposited will naturally take the path of least resistance, which in the erect victim will be through the body and legs to the ground. Electrical conductivity is highest in the cerebrospinal fluid. Indeed, heating of the cerebrospinal fluid to 145°F has been recorded after legal electrocution (10). Blood vessels and neural tissue have been found to carry more current per unit area than other tissues and to become

damaged before surrounding tissues in an animal model (9). We believe preferential conduction along Virchow-Robin spaces in the anterior perforated substance plays a major role in the production of basal ganglia injury after a lightning strike.

References

1. Langley RL, Dunn KA, Esinhart JD. Lightning fatalities in North Carolina: 1972-1988. *NC Med J* 1991;52:281-284
2. Andrew JA, Darveniza M, Mackerras D. Lightning injury: a review of clinical aspects, pathophysiology, and treatment. *Adv Trauma* 1989;4:241-288
3. Davidson GS, Deck JH. Delayed myelopathy following lightning strike: a demyelinating process. *Acta Neuropathol (Berl)* 1988;77:104-108
4. Mann H, Kopic Z, Boulos M. CT of lightning injury. *AJNR Am J Neuroradiol* 1983;4:976-977
5. Stanley LD, Suss RA. Intracerebral hematoma secondary to lightning stroke: case report and review of the literature. *Neurosurgery* 1985;16:686-688
6. Wakasugi C, Masui M. Secondary brain hemorrhages associated with lightning stroke: report of a case. *Nippon Hoigaku Zasshi* 1986;40:42-46
7. Cherington M, Yernell P, Lammereste D. Lightning strikes: nature of neurological damage in patients evaluated in hospital emergency departments. *Ann Emerg Med* 1992;21:575-578
8. Cherington M, Yernell P, Hallmark D. MRI in lightning encephalopathy. *Neurology* 1993;43:1437-1438
9. Sances A, Myklebust JB, Szablya JF, et al. Current pathways in high voltage injuries. *IEEE Trans Biomed Eng* 1983;30:118-123
10. Blake-Pritchard EA. Changes in the central nervous system due to electrocution. *Lancet* 1934;1:1163-1167