

MR of Cerebral Abnormalities Concomitant with Primary Intracerebral Hematomas

Hans Offenbacher, Franz Fazekas, Reinhold Schmidt, Michael Koch, Gudrun Fazekas, and Peter Kapeller

PURPOSE: To determine whether arteriolar vessel wall degeneration in primary intracerebral hematomas might be associated with ischemic brain lesions and clinically silent (apparently intracerebral) previous hemorrhages. **METHODS:** The MR images of 120 consecutive patients (mean age, 60 years; age range, 22 to 84 years) with their first stroke caused by a primary intracerebral hematoma were reviewed retrospectively for coexisting ischemic damage and previous bleeds. **RESULTS:** Early confluent to confluent white matter hyperintensities, lacunes, or infarction were present in 83 (69%) of the patients, and 39 (33%) had had previous hemorrhages consisting of microbleeds or old hematomas. Extensive white matter hyperintensities and lacunes were most frequent in patients with thalamic primary intracerebral hematomas. There was no relationship between the frequency of old hemorrhages and the location of subsequent primary intracerebral hematomas. **CONCLUSION:** Clinically silent ischemic lesions and previous hemorrhages are a common finding on MR images of patients with primary intracerebral hematoma. They may therefore serve as evidence of diffuse microangiopathy with a possible increased risk for cerebral hemorrhage.

Index terms: Brain, magnetic resonance; Cerebral hematoma; Cerebral hemorrhage

AJNR Am J Neuroradiol 17:573-578, March 1996

Spontaneous bleeding into the brain parenchyma without a sizable vascular malformation or neoplasm constitutes the most frequent mechanism of nontraumatic intracerebral hemorrhage in the adult. Rupture of small arteries after damage from chronically increased blood pressure has been traditionally considered the most common cause of this primary intracerebral hematoma (PICH) (1). However, the absence of hypertension in more than 50% of the patients with PICH (2, 3) also implies other causes, like amyloid angiopathy (4, 5). Therefore, the development of vessel wall changes that predispose patients to PICH may not be suspected before the hematoma occurs.

Cerebral magnetic resonance (MR) imaging has revealed clinically silent white matter abnormalities, with most of these occurring in elderly patients and in patients with cerebrovascular risk factors (6, 7). Small punctate hyperintensities result primarily from a perivascular reduction in myelin caused by reduced vessel wall permeability (8, 9) and seem to be a frequent phenomenon of normal aging (7). Larger and confluent areas of signal abnormality, however, have been repeatedly linked to microangiopathy. Reported tissue changes range from incomplete infarctions to frank tissue necrosis in the center of areas of widespread high signal intensity (10-13). The sensitivity of MR imaging for hemosiderin also provides the unique opportunity to identify old hemorrhages (14, 15). In a setting of diffusely increased vascular fragility, small hemorrhages could occur when they are not clinically apparent (16), but they should be detectable by MR imaging, even in retrospect.

We therefore hypothesized that MR imaging of patients with PICH would frequently show extensive microangiopathy-related cerebral

Received May 12, 1995; accepted after revision September 11.

From the MR Institute (H.O., F.F., R.S., P.K.) and the Department of Neurology (H.O., F.F., R.S., M.K., G.F., P.K.), Karl-Franzens University, Graz, Austria.

Address reprint requests to Franz Fazekas, MD, Department of Neurology, Karl-Franzens University, Auenbruggerplatz 22, A-8036, Graz, Austria.

AJNR 17:573-578, Mar 1996 0195-6108/96/1703-0573

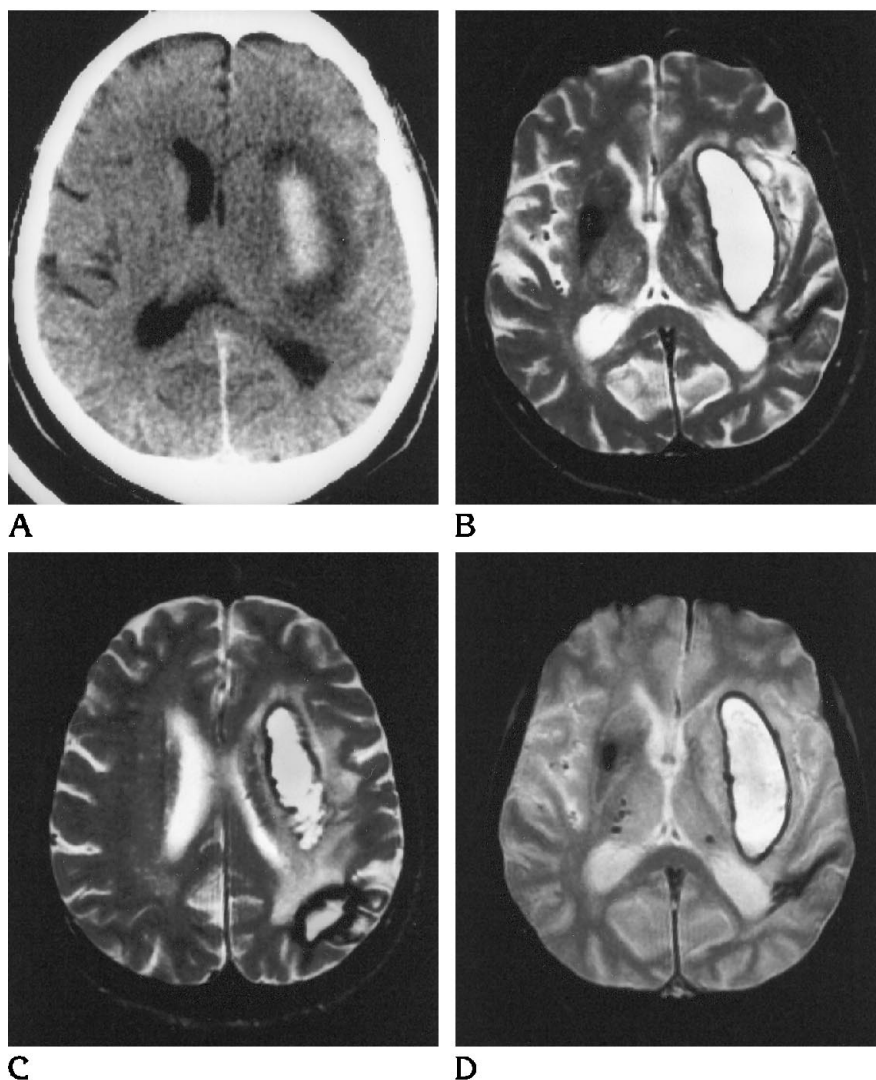
© American Society of Neuroradiology

Fig 1. Patient 74 years of age with a putaminal PICH.

A, CT scan shows an acute hematoma without any other parenchymal abnormalities.

B and C, T2-weighted spin-echo MR images (2500/90/2) 3 weeks later reveal another clinically silent, old hematoma in the left parietooccipital region.

D, T2*-weighted gradient-echo MR image (660/17/2; flip angle, 20°) corresponding to A and C shows many additional microbleeds.



ischemic damage and a high rate of small previous hemorrhages.

Materials and Methods

The patient population consisted of all those patients who were referred for MR imaging from the Department of Neurology during a period of 7 years and who had first-time stroke symptoms and final diagnoses of PICH. There were 68 men and 52 women (mean age, 60 years; age range, 22 to 84 years). In 67 (56%) of the patients, hypertension was present, defined either by a history of increased blood pressure or by repeated blood pressure recordings above 160/95 mm Hg beyond the second week after the stroke occurred. In 22 (18%) of the patients, diabetes mellitus was diagnosed either by a fasting blood sugar above 140 mg/dL or by previous or intercurrent treatment.

MR images of the brain were obtained on 1.5-T scanners within the first 4 weeks of the hemorrhage. Conven-

tional T1-weighted (550–720/15–30/1–2 [repetition time/echo time/excitations]), proton density-weighted, and T2-weighted (2300–2800/20–30,80–90/1–2) spin-echo sequences were performed in all patients. Gradient-echo T2*-weighted images (500–720/15–20/1–2; flip angle, 20–25°) were available on 38 patients.

Retrospectively, an experienced investigator (who was unaware of the patients' clinical data) reviewed all images and recorded the size and location of the clinically symptomatic hematoma, as well as the presence of additional parenchymal abnormalities. The locations of PICH were classified as lobar, basal ganglionic, thalamic, brain stem, or cerebellum. White matter hyperintensities were defined as focal areas of increased signal intensity on proton density-weighted and T2-weighted images if there was no corresponding signal alteration on T1-weighted images. The severity of a white matter hyperintensity was graded as punctate (grade 1), early confluent (grade 2), or confluent (grade 3) (17). Areas of ischemic parenchymal destruction (ie, lesions whose signal was isointense with

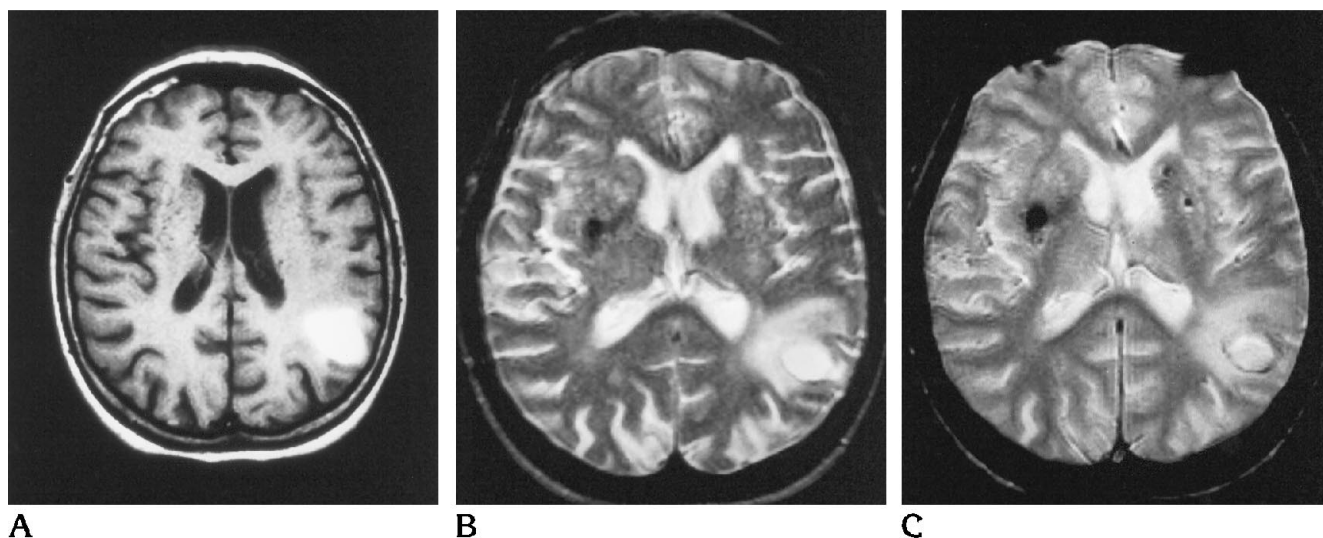


Fig 2. Patient 68 years of age with a left parietal subcortical PICH of 9 days' duration.

A, T1-weighted spin-echo MR image (587/15/2) shows the hematoma and numerous punctate lacunes throughout the basal ganglia of both sides.

B, T2-weighted spin-echo MR image (2500/90/1) one section lower shows a relatively large focal hypointensity in the right putamen.

C, T2*-weighted gradient-echo MR image (680/20/2; flip angle, 20°) shows two more focal hemosiderin deposits (microbleeds) in the left basal ganglia.

cerebrospinal fluid in their center) were categorized as lacunes (<10 mm in diameter) or infarcts. Focal areas within the brain parenchyma that showed signal loss on T2-weighted images were considered to indicate hemosiderin deposits, except for the symmetric hypointensity of the globus pallidus, which probably represents calcification. The majority of focal areas of signal loss consisted of homogeneous, rounded lesions with diameters of 2 to 5 mm; we called these *microbleeds* (Figs 1–3). Lesions with the typical appearance of an old hematoma were recorded separately. The χ^2 test was used for comparing the frequency distribution of concomitant MR lesions among different PICH locations (18).

Results

Basal ganglionic (Fig 1) and lobar (Fig 2) PICHs were each noted in 42 (35%) of the patients. Twenty-six (22%) of the patients had hemorrhages originating from the thalamus (Fig 3), the brain stem was involved in 4 (3%) of the patients, and the cerebellum was involved in 6 (5%) of the patients. The Table shows the frequency of concomitant MR findings for four specific locations of the symptomatic PICH and for the total group. Evidence of ischemic damage was present in 83 (69%) of the patients; evidence included pronounced (grades 2 and 3) white matter hyperintensities (Fig 3), lacunes (Fig 2), or infarction. Focal hemosiderin deposits from either microbleeds or old hematomas were seen in 39 (33%) of the patients. All types

of ischemic lesions were most frequent with PICH originating from the thalamus. The frequency of grades 2 and 3 white matter hyperintensities was significantly higher for thalamic PICH than for basal ganglionic PICH ($P < .05$). Ischemic lacunes were significantly more frequent in patients with thalamic ($P < .01$) and basal ganglionic PICH ($P < .05$) than in those with lobar PICH (see Table). There was no significant difference in the rates of microbleeds and old hematomas between hemorrhages in a basal ganglionic location and those in a lobar location (Figs 1–3).

Discussion

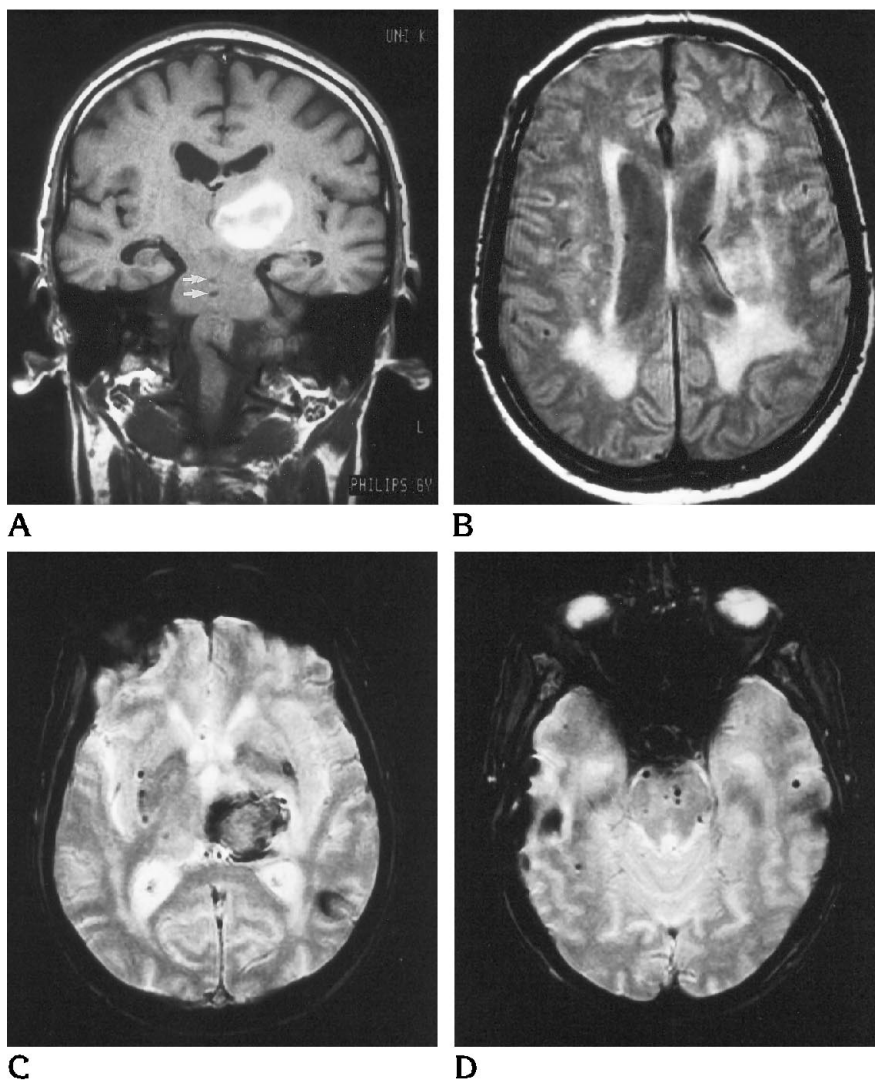
The relationship between incidental parenchymal damage and nontraumatic intracerebral hemorrhage has received little attention in previous radiologic studies. Selekler and Erzen (19) reported on 33 consecutive patients with periventricular white matter lucency on computed tomography (CT) of the brain (19). They found intracerebral hematomas in five patients; the hematoma was located in the thalamus in four patients and in the parietotemporal area in one patient. All five patients were hypertensive. Subsequently, Inzitari et al (20) compared the prevalence of diffuse white matter hypodensity (termed *leukoaraiosis*) on CT scans of 116 patients with intracerebral hemorrhage and 155

Fig 3. Patient 66 years of age with spontaneous intracerebral bleeding.

A, Coronal T1-weighted spin-echo MR image (720/18/2) shows a 1-week-old hematoma in the left thalamus and two small hypointense foci in the pons (arrows).

B, Axial proton density-weighted MR image (2500/20/2) reveals concomitant confluent white matter hyperintensities, which are more pronounced on the left side.

C and D, T2*-weighted gradient-echo MR images (660/17/2; flip angle, 20°) show multiple punctate hemosiderin deposits (microbleeds) in the subcortical gray matter and throughout the brain stem. Patchy subcortical hemosiderin deposition is also noted in the left temporooccipital region.



control subjects (20). They observed white matter rarefaction in 18% of hematoma patients, a rate significantly greater than the 8% rate for control subjects. Leukoaraiosis occurred more frequently in patients with basal ganglionic hemorrhages than in those with lobar hemorrhages (20).

In our 120 patients with PICH, we found many ischemia-related parenchymal changes, including white matter hyperintensities in 81% (with 50% of those being early confluent to confluent, ie, grades 2 and 3), lacunes in 51%, and territorial infarction in 8%. The rates in our study are higher than those in the study by Inzitari et al (20); this difference can be easily explained by the higher sensitivity of MR imaging. The observed extent of concomitant vascular damage also clearly exceeds that of "incidental" findings in the healthy elderly population. In a cohort of

101 randomly selected asymptomatic individuals, Fazekas et al (7) found white matter hyperintensities in up to 71% of subjects older than 70 years. However, only 6% of them had grades 2 and 3 white matter hyperintensities on a scoring scheme identical to that used in this study (7). Lacunar or territorial infarcts were not seen in the study by Fazekas et al (7). In a group of 133 patients with ischemic stroke, Schmidt et al (21) found white matter hyperintensities in only 44%; the rate of grades 2 and 3 hyperintensities was 20%. The mean age of the population in the study by Schmidt et al (21) was 5 years less than the mean age of our PICH patients; however, that alone cannot account for the striking difference in white matter damage.

All types of ischemic lesions were seen most often with thalamic PICH. This is probably because of the simultaneous negative effects of

Frequency of concomitant MR findings in 120 patients with primary intracerebral hematoma

Finding	Lobar (n = 42)	Basal ganglionic (n = 42)	Thalamic (n = 26)	Infratentorial (n = 10)	Total (n = 120)
White matter hyperintensities					
Grade 1	10 (24)	20 (48)	9 (35)	4 (40)	43 (36)
Grades 2 and 3	20 (48)	15 (36)	16 (62)*	3 (30)	54 (45)
All grades	30 (72)	35 (84)	25 (97)	7 (70)	97 (81)
Lacunae	15 (36)	25 (60)†	18 (69)‡	3 (30)	61 (51)
Infarcts	3 (7)	3 (7)	3 (12)	0 (0)	9 (8)
Microbleedings	8 (19)	8 (19)	10 (38)	1 (10)	27 (23)
Old hematomas	10 (24)	7 (17)	9 (35)	2 (20)	28 (23)

Note.—Numbers in parentheses in body of table indicate percentages. The χ^2 test was used to determine *P* values. Grade 1 white matter hyperintensities were punctate; grade 2 white matter hyperintensities were early confluent; and grade 3 white matter hyperintensities were confluent.

* Thalamic vs basal ganglionic, *P* < .05.

† Basal ganglionic vs lobar, *P* < .05.

‡ Thalamic vs lobar, *P* < .01.

hypertension. Hypertension-induced *lipohyalinosis* (consisting of subintimal deposition of lipid-rich hyaline material with disruption of muscle and elastic elements) has been preferentially linked to hematomas in the deep gray matter (22). In parallel, abnormally high blood pressure is associated with increased occurrence of lacunes (23) and favors the development of more extensive white matter hyperintensities (6).

The observation of previous hemorrhages in almost one third of patients with PICH is striking. The lack of corresponding abnormalities on CT scans excludes calcification as a cause of signal loss on T2-weighted images (Fig 1). The association of old hemorrhages with acute spontaneous hematomas has already been reported in pathologic studies, but in vivo investigation of this association was not possible before the advent of MR imaging. In an autopsy study of patients with lobar cerebral hemorrhage caused by amyloid angiopathy, Ishii et al (24) observed additional small foci of perivascular hemorrhages consisting of hemosiderin-laden macrophages or old hematomas in five of seven brains. Only two of those patients had been hypertensive. A histopathologic analysis of hypertensive brains (23) revealed hemosiderin-bearing macrophages at the periphery of lacunar lesions; Cole and Yates (23) speculated that these macrophages might represent residues of small hemorrhages. Therefore, the presence of focal hemosiderin deposits may be a general indicator of an increased fragility of blood vessels, regardless of the cause. This assumption is supported by the observation of similar rates of old hemorrhages in patients with

PICH in different locations. Evidence of previous hemorrhages manifested by focal hemosiderin deposition in a patient with an intracerebral hematoma may also serve a diagnostic purpose. Such an MR finding certainly favors an angiopathic cause for the bleeding and thus may obviate more invasive diagnostic procedures.

In conclusion, this study suggests that symptomatic PICH is frequently preceded by microangiopathy-related ischemic damage and silent hemorrhage. Such abnormalities shown on MR images may therefore indicate a higher risk of cerebral hematoma.

References

1. Caplan LR. Intracerebral hemorrhage. In: Tyler HR, Dawson D, eds. *Current Neurology*. Boston, Mass: Houghton-Mifflin, 1979;2: 185-205
2. Brott T, Thalinger K, Hertzberg V. Hypertension as a risk factor for spontaneous intracerebral hemorrhage. *Stroke* 1986;17: 1078-1083
3. Bahemuka M. Primary intracerebral hemorrhage and heart weight: a clinicopathologic case-control review of 218 patients. *Stroke* 1987;18:531-536
4. Wagle WA, Smith TW, Weiner M. Intracerebral hemorrhage caused by cerebral amyloid angiopathy: radiographic-pathologic correlation. *AJNR Am J Neuroradiol* 1984;5:171-176
5. Vinters HA. Cerebral amyloid angiopathy: a critical review. *Stroke* 1987;2:311-324
6. Awad IA, Spetzler RF, Hodak JA, Awad CA, Carey R. Incidental subcortical lesions identified on magnetic resonance imaging in the elderly, I: correlation with age and cerebrovascular risk factors. *Stroke* 1988;17:1084-1089
7. Fazekas F, Schmidt R, Offenbacher H, et al. Prevalence of white matter and periventricular magnetic resonance hyperintensities in asymptomatic volunteers. *J Neuroimag* 1991;1:27-30
8. Kirkpatrick JB, Hayman LA. White-matter lesions in MR imaging of clinically healthy brains of elderly subjects: possible pathologic basis. *Radiology* 1987;162:509-511

9. Fazekas F, Kleinert R, Offenbacher H, et al. The morphologic correlate of incidental white matter hyperintensities on MR images. *AJNR Am J Neuroradiol* 1991;12:915-921
10. Braffman BH, Zimmerman RA, Trojanowski JQ, Gonatas NK, Hickey WF, Schlaepfer WW. Brain MR: pathologic correlation with gross and histopathology, 2: hyperintense white-matter foci in the elderly. *AJNR Am J Neuroradiol* 1988;9:629-636
11. Leifer D, Buonanno FS, Richardson EP Jr. Clinicopathologic correlations of cranial magnetic resonance imaging of periventricular white matter. *Neurology* 1990;40:911-918
12. Fazekas F, Kleinert R, Offenbacher H, et al. Pathologic correlates of incidental MRI white matter signal hyperintensities. *Neurology* 1993;43:1683-1689
13. Van Swieten JC, Van den Hout JHW, Van Ketel BA, Hijdra A, Wokke JHJ, Van Gijn J. Periventricular lesions in the white matter on magnetic resonance imaging in the elderly: a morphometric correlation with arteriolosclerosis and dilated perivascular spaces. *Brain* 1991;114:761-774
14. Gomori JM, Grossman RI, Goldberg HI, Zimmerman RA, Bilaniuk LT. Intracranial hematomas: imaging by high-field MR. *Radiology* 1985;157:87-95
15. Offenbacher H, Fazekas F, Reisecker F, Schmidt R, Payer F, Lechner H. Superficial siderosis of the spinal cord: a rare cause of myelopathy diagnosed by MRI. *Neurology* 1991;41:1987-1989
16. Vonsattel JPG, Myers RH, Hedley-Whyte ET, Ropper AH, Bird ED, Richardson EP Jr. Cerebral amyloid angiopathy without and with cerebral hemorrhages: a comparative histological study. *Ann Neurol* 1991;30:637-649
17. Fazekas F, Chawluk JB, Alavi A, Hurtig HI, Zimmerman RA. MR signal abnormalities at 1.5T in Alzheimer's dementia and normal aging. *AJNR Am J Neuroradiol* 1987;8:421-426
18. Norusis MJ. *SPSS/PC + Advanced Statistics V2.0 for the IBM PC/XT/AT and PS/2*. Chicago, Ill: SPSS Inc, 1988
19. Selekler K, Erzen C. Leukoaraiosis and intracerebral hematoma. *Stroke* 1989;20:1016-1020
20. Inzitari D, Giordano GP, Ancona AL, Pracucci G, Mascalchi M, Amaducci L. Leukoaraiosis, intracerebral hemorrhage, and arterial hypertension. *Stroke* 1990;21:1419-1423
21. Schmidt R, Fazekas F, Kleinert G, et al. Magnetic resonance imaging signal hyperintensities in the deep and subcortical white matter: a comparative study between stroke patients and normal volunteers. *Arch Neurol* 1992;49:825-827
22. Fisher CM. Pathological observations in hypertensive cerebral hemorrhage. *J Neuropathol Exp Neurol* 1971;30:536-550
23. Cole FM, Yates PO. Comparative incidence of cerebrovascular lesions in normotensive and hypertensive patients. *Neurology* 1968;18:255-259
24. Ishii N, Nishihara Y, Horie A. Amyloid angiopathy and and lobar cerebral hemorrhage. *J Neurol Neurosurg Psychiatry* 1984;47:1203-1210
25. Schmidt R, Lechner H, Fazekas F, et al. Assessment of cerebrovascular risk profiles in healthy persons: definition of research goals and the Austrian Stroke Prevention Study. *Neuroepidemiology* 1994;13:308-313