

# A Proposed Model of Cerebrospinal Fluid Circulation: Observations with Radionuclide Cisternography

Dan Greitz and Jan Hannerz

**PURPOSE:** To determine the mechanisms of the tracer distribution at radionuclide cisternography (RC). **METHODS:** Ten patients with venous vasculitis were studied with RC. Flow phantom studies were performed mimicking cerebrospinal fluid (CSF) circulation with and without a main outlet comparable to the pacchionian granulations. **RESULTS:** Nine of the 10 patients had normal findings on RC images, including a maximum uptake over the vertex at 24 hours. In all patients, a second maximum occurred in the lumbosacral area. The flow phantom studies showed no tracer accumulation at an open outlet corresponding to the pacchionian granulations. On the contrary, a maximum arose without such an outlet. A maximum always arose at the closed dead ends of the phantom, including the lumbosacral area. **CONCLUSION:** The commonly accepted flow model for CSF circulation needs to be revised. The pattern of the normal RC cannot be explained by a bulk flow transport of the tracer to an outlet at the pacchionian granulations but rather by a primary mixing caused by pulsatile flow with a secondary dilution by newly formed CSF from the ventricular system. We suggest that the main absorption of the CSF is through the central nervous system to the blood.

**Index terms:** Cerebrospinal fluid, flow dynamics; Cerebrospinal fluid, radionuclide studies; Cisternography

*AJNR Am J Neuroradiol* 17:431-438, March 1996

In 1964 Di Chiro (1) published a now classic paper in *Nature*, in which he introduced radionuclide cisternography (RC) and showed the existence of an active cerebrospinal fluid (CSF) circulation. Since then, much information has been published about CSF tracer distribution after injections into the subarachnoid spaces, including the spinal canal (2-7). CSF radionuclide scanning is the method of choice for studying the normal physiological pattern and any derangement in the CSF flow (2).

Di Chiro (2) found a rapid migration of tracer from the lumbar region to the convexity and concluded that there was an active cranially directed CSF circulation, at least from the for-

men magnum and upward. He obviously regarded the cranial transport of the tracer to be a result of CSF bulk flow. In monkeys, he found a fast descent (3) into the spinal canal after the tracer was injected into the lateral ventricles. In his opinion, this finding gave only partial support for the hypothesis of a two-directional flow in the spinal canal, downwardly directed in the posterior compartment and upwardly directed in the anterior compartment (2). In 1976 Schossberger and Touya (7) questioned the interpretation of the cisternographic findings based on the concept of a bulk flow.

The present investigation was designed to examine whether bulk flows can be detected in the subarachnoid spaces by using radionuclide scanning. We studied a group of patients who had higher-than-normal intracranial pressure and who had been referred to the Department of Neuroradiology for RC. For better understanding of the results, we used a flow phantom to represent the subarachnoid spaces in a supplementary study.

---

Received June 30, 1994; accepted after revision May 22, 1995.

From the Department of Neuroradiology and Karolinska MR Research Center (D.G.) and the Department of Neurology (J.H.), Karolinska Hospital, Stockholm, Sweden.

Address reprint requests to Dan Greitz, MD, Karolinska MR Research Center, Karolinska Hospital, S-171 76 Stockholm, Sweden.

*AJNR* 17:431-438, March 1996 0195-6108/96/1703-0431

© American Society of Neuroradiology

## Subjects and Methods

### *Patient Studies*

RC was performed in 10 women with venous vasculitis (8) (mean age, 43 years; age range, 22 to 63 years). In each patient, high intracranial pressure had been recorded at least once before the examination. The reason for the cisternographic examination was to rule out pathologic CSF circulation, because CSF absorption disturbances have previously been associated with high intracranial pressure (9). Lumbar puncture was made at the L-4 to L-5 level, and 0.5 mL of 100 MBq of technetium-99m-diethylenetriamine pentaacetic acid was injected. In 4 patients, the radionuclide was mixed with contrast material (2 to 8 mL iohexol at 300 mg/mL) and tilted up to the level of the conus. The entire spine was scanned after 15 to 30 minutes and after 1, 1.5, 3, 6, and 24 hours. The head was scanned after 3, 6, and 24 hours; RC tomography was performed at 6 hours. In addition to the RC, computed tomographic (CT) cisternography was performed. CT scans were obtained at every fifth centimeter of the spine and head and at approximately 0.5, 3, and 6 hours after the injection.

### *Flow Phantom Studies*

A flow phantom containing water with pulsatile flow in a plastic tube representing the intracranial as well as the spinal subarachnoid spaces was used as a model of CSF circulation. Another plastic tube was placed inside the first one to mimic the effect of the spinal cord on CSF flow. A blue water-soluble dye (methylthionine chloride) was used as a tracer. The pulsatile flow was produced by a pump. The pulse amplitude was 15 mm, and the pulse rate was 30 pulses per minute. The outer tube had an inner diameter of 19 mm, and the inner tube had an outer diameter of 12 mm. To minimize the influence of the blue dye on the study, we adjusted its specific weight to be just above that of water, representing the CSF. The small difference was necessary to keep the dye in the lower end of the tube in the first part of the experiment and to prevent it from forming an upper maximum simply by floating up in the second part of the experiment.

In the first part of the flow phantom study, the upward distribution of the blue tracer was examined after it had been injected into the lower part of a water-filled U-shaped tube (Fig 1). There were three different experimental setups: one to study mere diffusion without a cord and two to examine the influence of pulsatile flow either with or without an artificial cord.

In the second part, inflow and outflow into the tube of artificial noncolored CSF (ie, plain water) was studied by adding water to the pulsating blue dye (Fig 2). The tube contained 150 mL of fluid. The water's inflow rate was equal to the outflow (10 mL/min). Two experiments were performed: one experiment with an inflow of water at the level corresponding to the "foramen magnum" and an outflow at the "convexity," which should imply a net flow,

and the other experiment with inflow and outflow placed opposite each other at the foramen magnum, which should be consistent with no longitudinal net flow in the main tube.

## Results

### *Patient Studies*

Nine of the 10 patients selected for the study had normal CSF circulation as judged by the commonly accepted diagnostic criteria used in RC. In these 9 patients, RC showed a more or less well-defined convexity maximum and no transient or permanent filling of the lateral ventricles. The tenth patient had a persistent uptake in the lateral ventricles and reduced activity over the upper convexity at 24 hours.

The highest concentration of the tracer was stationary at the site of deposition in the lumbar or the conus region and did not move toward the convexity. This means that no sweeping phenomenon, indicating a bolus transport, could be observed. The radioisotope-contrast medium solution deposited at the conus region reached the foramen magnum very quickly (about 15 minutes), but it did not reach the sacral end of the thecal sac until after 3 to 6 hours in 4 of 4 patients, as was also shown by CT cisternography. The cranial distribution was normal in all 10 patients, and the basal cisterns were reached after 15 to 60 minutes. The longer delays were observed after lumbar injection. The convexity was reached after about 5 to 7 hours in 9 of the 10 patients.

In all patients, there was a relative decrease of the activity after 24 hours in the area corresponding to the basal cistern and the cisterna magna, as well as in the cervical and thoracic areas; the activity remaining after 24 hours in this area corresponded mainly to brain tissue and cord, not to CSF spaces (Fig 3). This could be said to represent a craniocervical minimum. In comparison with the early scans, this minimum was more easily and reliably observed than the convexity maximum. In the lumbosacral area, however, the activity remained or became high at 24 hours and created a lumbar maximum in all 10 patients, including the patient who had pathologic CSF circulation (Fig 4). CT cisternography confirmed the findings of RC. The contrast material deposited in the lower thoracic region did not move as a bolus but remained at a maximum during the time of observation. Despite an observable layering at the

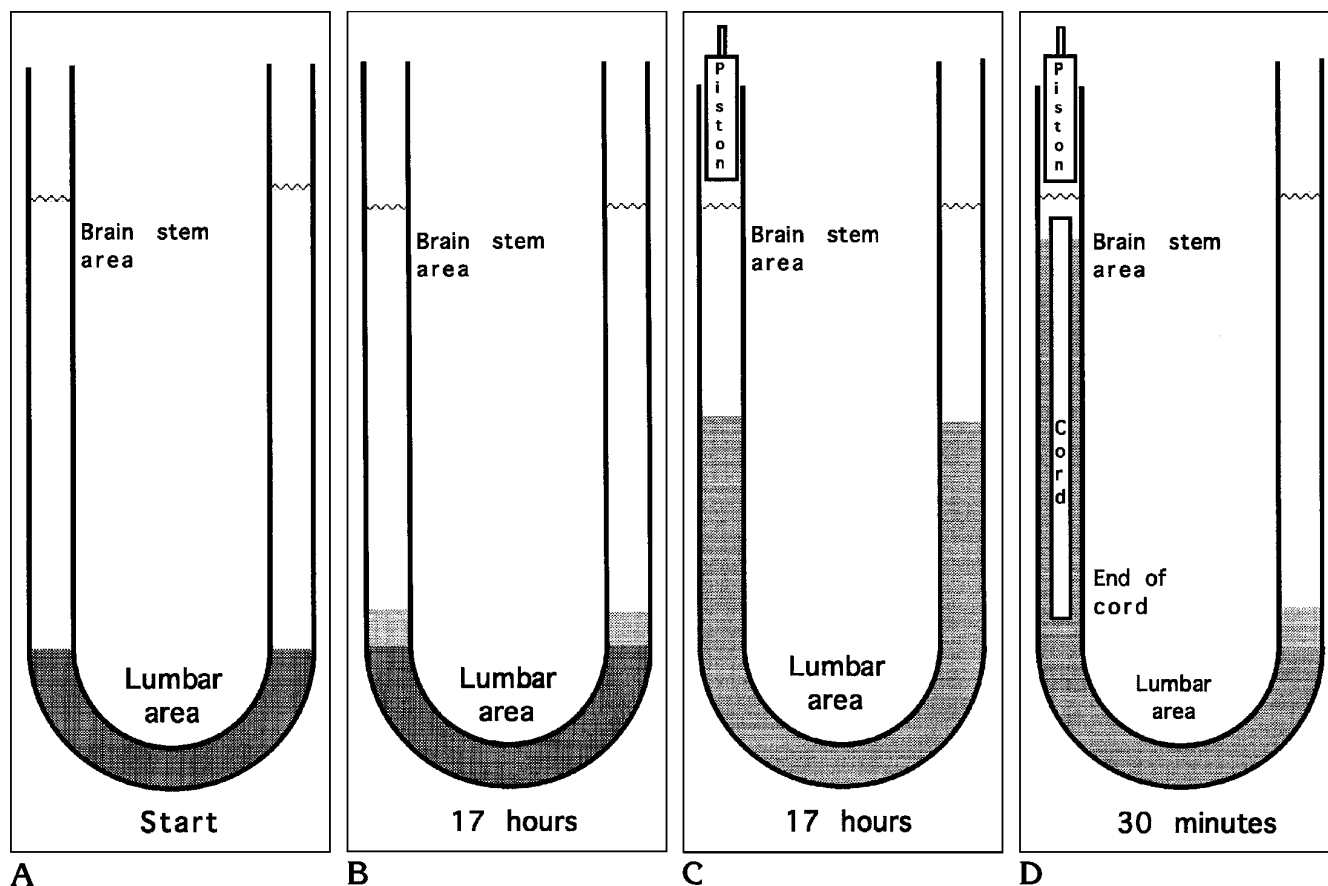


Fig 1. A, The phantom used for the first part of the experimental flow studies consisted of a plastic tube representing the spinal subarachnoid space. At the start, water and blue dye were added to the outer tube to represent cerebrospinal fluid and tracer, respectively. Pulsatile flow was produced by a pump (C and D). Another plastic tube with closed ends (D) could be inserted to simulate the cord.

B, The blue dye moved about 5 cm in 17 hours without pulsatile flow in the tube (simple diffusion).

C, The blue dye moved 50 cm in 17 hours with pulsatile flow.

D, The blue dye moved 80 cm in 30 minutes when the cord was put into the tube.

site of the deposition, a complete and even distribution of contrast material and CSF was noted in the cervical and upper thoracic area after 30 minutes; this distribution indicates that the contrast material did not have a significant detrimental influence on the RC results.

#### Flow Phantom Studies

When mere diffusion and pulsatile flow with and without an artificial cord (ie, with and without the inner tube) (Fig 1) were compared, the tracer moved about 5 cm in 17 hours with simple diffusion and 50 cm in 17 hours with pulsations of 4 mL per beat. When the cord was put

into the tube, the tracer moved 80 cm in 30 minutes with pulsations of the same magnitude (ie, about 50 times faster).

When the inflow was at the foramen magnum and the outflow was at the convexity (at A in Fig 2A), a dilution of the blue color was found between these two points (ie, in the area of net flow). There was a washout at the convexity and no convexity maximum was observed (Fig 2C). On the other hand, a lumbar maximum soon arose (15 to 30 minutes) after the washout at the convexity, despite the absence of net flow in the lumbar region. A maximum at the convexity and a maximum in the lumbar region were observed in the other setup (at B in Fig 2A), in

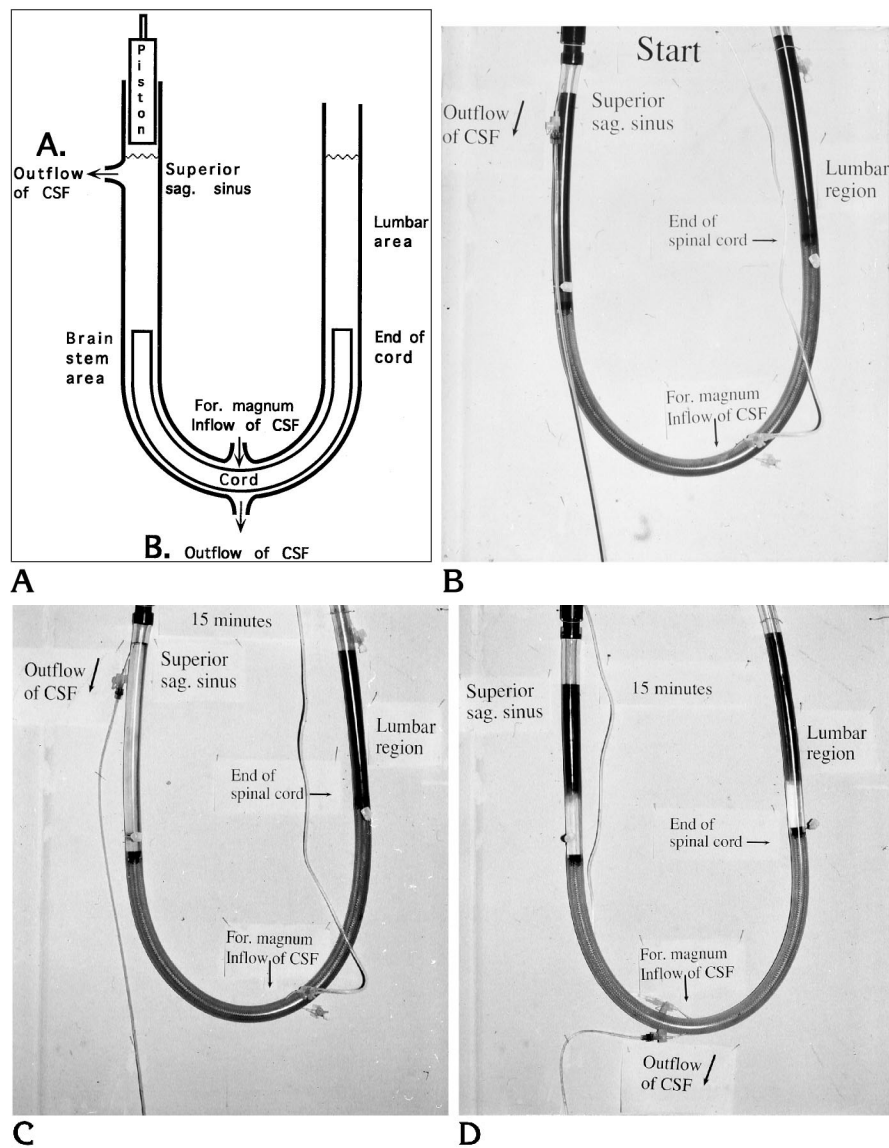


Fig 2. A, The second part of the experiment was designed to study the dilution of the tracer by newly formed cerebrospinal fluid (CSF). The phantom was similar to that used in the first part (Fig 1); the tube filled with blue dye represented the intracranial as well as the spinal subarachnoid space. Another plastic tube with closed ends was inserted to simulate the cord. The CSF (plain water) inflow was always at the midpoint of the tube during the experiment. The outflow could be varied either at one end (A.) corresponding to the superior sagittal sinus, which would imply net flow, or at the midpoint (B.), consistent with no net flow.

B, At the start of the experiments shown in C and D, the blue dye was evenly distributed through the entire tube.

C, The outflow occurs at the superior sagittal sinus, producing a net flow in the left part of the tube with no maximum at the outlet.

D, Outflow opposite to the inflow at the foramen magnum with no net flow in the main tube. A maximum arises at the superior sagittal sinus and in the lumbar area.

Sag. indicates sagittal; for., foramen.

which both the inflow and outflow of water into the colored CSF were located at the level of the foramen magnum (Fig 2D). This means that the two maxima at the ends of the plastic tube occur as a result of the dilution of the dye at the foramen magnum without a net flow being present.

## Discussion

In recent years, the introduction of gated magnetic resonance (MR) imaging has enabled researchers to quantify rapid CSF flow more precisely (10–15) than was possible when only cisternography with radioactive tracer or water-soluble contrast material was available (16). In

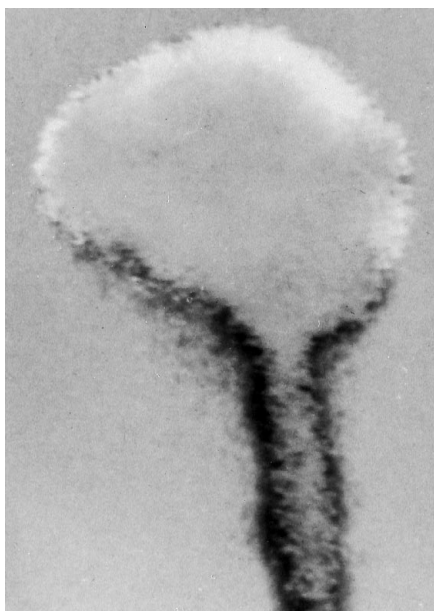


Fig 3. Radionuclide cisternography with normal cerebrospinal fluid circulation. Image obtained at 24 hours subtracted from the image obtained at 6 hours, which was used as a mask after being reversed. Areas with the same intensity are gray, those with relatively more activity at 6 hours are black, and those with more activity at 24 hours are white. At 24 hours, the activity recorded below the foramen magnum is almost exclusively in the cord and not in the spinal subarachnoid space. The white area corresponds to the convexity maximum caused by late washout from the frontoparietal cortex and the surrounding subarachnoid space.

previous MR studies by our group (12, 13), no net flow larger than the error of the method was found in the posterior or anterior part of the cervical canal. Complex flows are certainly underestimated with phase-contrast MR studies, but such flows might significantly contribute to an increased mixing of CSF rather than to an increased bulk flow. The rapid distribution of tracers in the spinal CSF spaces could be explained fully by the mixing caused by large pulsatile flows. Hence, we need not assume the existence of a bulk circulation to explain the distribution of the tracer. The present study was undertaken to elucidate this phenomenon.

A group of patients with venous vasculitis and higher-than-normal intracranial pressure were examined by RC after injections of the tracers into the spinal subarachnoid spaces. Because no definite signs of intracranial or spinal disease were found in the patients (apart from the high intracranial pressure) and because 9 of the 10 had normal results on cisternographic studies, we did not expect that the flow characteristics in these patients would differ from those of healthy control subjects.

RC scanning and CT cisternography of an injected tracer are probably more suitable than MR imaging for investigating the presence of a net CSF bulk flow. The error in bulk flow deter-

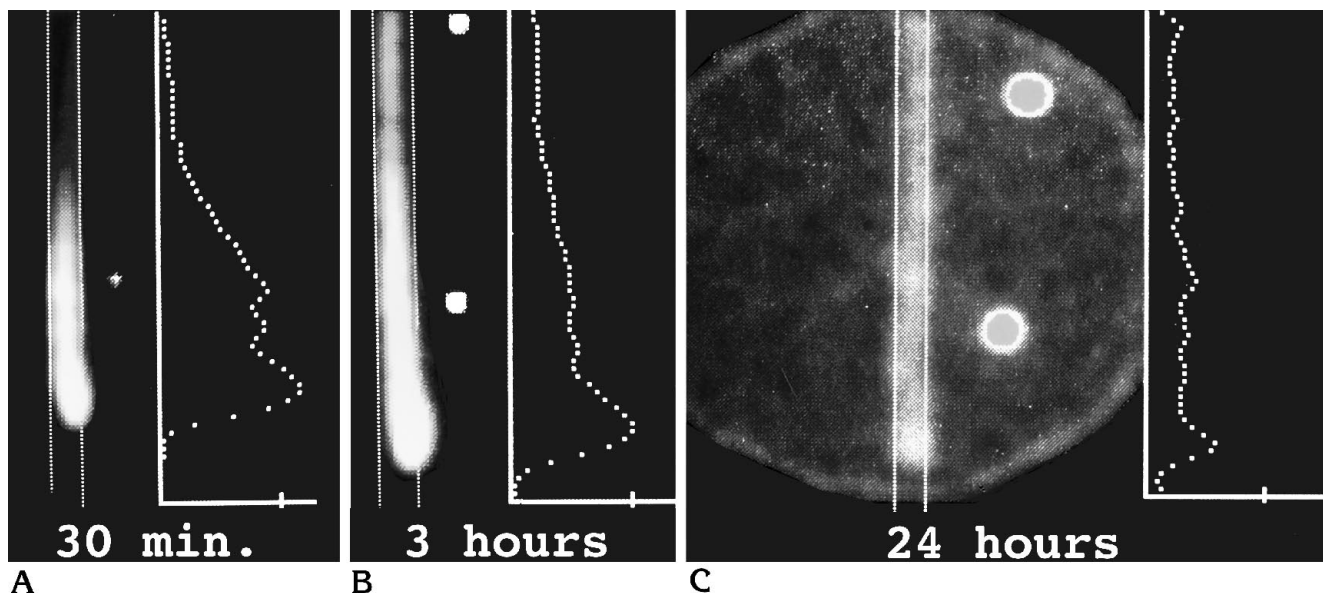


Fig 4. Tracer distribution in the lumbar and lower thoracic area at radionuclide cisternography in subjects with normal cerebrospinal fluid circulation. The lower of the two indicators was placed at the iliac crest (ie, at L-4 to L-5).

A, The activity profile shows high intensity in the entire lumbar area at 30 minutes.

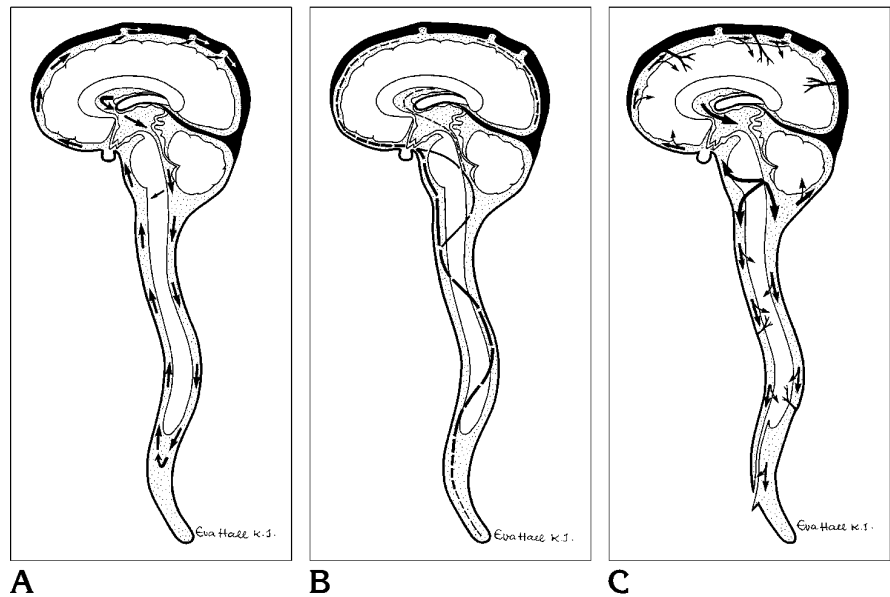
B, A fast upward transport occurs at 3 hours, except in the lumbosacral area where a maximum is building up.

C, This maximum remains at the sacral end of the thecal sac after 24 hours.

Fig 5. Diagram showing the commonly accepted bulk flow model (A) and the two types of cerebrospinal fluid circulation related to the proposed concept of the circulation (B and C). The dominant pulsatile flow shown in B is responsible for the rapid spread of tracers within the extraventricular cerebrospinal fluid spaces, and the comparatively small, almost minute, bulk flow (C) explains the appearance of the cisternogram in normal cases causing washout of tracer in the ventricular system and the basal cisterns.

B. There is a dominant pulsatile flow with a fast-velocity compartment in the brain stem–cord area and slow velocities at the upper and lower ends of the subarachnoid spaces. The amplitude and velocity are indicated by the length of the segments of the *dashed line*. The systolic and diastolic flows in the spinal canal follow one main channel, which is located toward the convexities showing a meandering S-shaped route caused by centrifugal forces and lower resistance in wider subarachnoid spaces.

C. The minute bulk flows are exaggerated for clearer illustration. The thickness of the *arrows* is related to the magnitude of the bulk flow, which decreases in both directions from the foramen magnum. The cerebrospinal fluid is resorbed everywhere in the central nervous system by the circulating blood. The spinal nerves, including the cauda equina, are represented solely by one caudal root in this schematic drawing.



mined by gated MR imaging is about 10% of the pulsatile flow. As shown in an earlier study (13), the measured CSF net flows are all within the error of the method (<10%), with the exception of the aqueductal bulk flow, which amounts to 35% of pulsatile flow (14). In RC, the maximum activity recorded for the tracer introduced into the CSF serves as the indicator of the flow processes. If a bulk flow exists, the maximum activity at the site of the deposition will follow the flow direction. If only diffusion or a mixing occurs in the fluid, the maximum will not move, as noted by H. Alfredsson (written communication, May 1992). The flow phantom experiments verified these phenomena when a color tracer was put into plain water and when a colored fluid was locally diluted. In the latter case, an area of minimum concentration of the colored tracer arose, and the diluted fluid behaved like a negative tracer; the minimum was stationary and corresponded to the foramen magnum area.

The flow phantom experiments also showed that the mixing is much more effective in the presence of the cord. This is because of the smaller area of the pulsating CSF space; the mixing is inversely dependent on the fifth power of the radius of a tubing (12). As has been shown in a previous work using gated MR im-

aging (13), the pulsations in the lumbosacral canal are much smaller than those in the thoracic and cervical part of the spinal canal, and the cross-sectional area of the CSF space is larger than that in the thoracic and cervical part of the spinal canal. Also, the pulsations are much smaller in the pontine cistern (0.3 mL) than at the foramen magnum (1.0 mL). The pulsations are even smaller in the sylvian fissure, and they were not detectable at the convexity. The tracer distribution may be said to reflect the division of the subarachnoid spaces into five compartments (Fig 5B) with different velocities: a fast-velocity compartment consisting of the posterior fossa and the cervicothoracic region, including the conus (the brain stem–cord compartment); two intermediate-velocity compartments, one consisting of the sylvian fissures and the lower half of the interhemispheric fissure and one consisting of the lumbar CSF space above L-5; and two slow-velocity compartments, the vertex area and the lumbosacral region. The rapid mixing that occurs in the fast compartment of the spinal canal easily gives the impression of two-way traffic. The model proposed here also explains why a larger volume of tracer injected in the lumbar area increases the speed of distribution (2); part

of the tracer then reaches the fast brain stem-cord compartment at the time of the injection.

Thus, many observations suggest that the rapid transport of the tracer in RC is caused by fast mixing occurring in the subarachnoid spaces. In RC, the radioisotope is usually injected in the lumbar area, where its maximum will be located. The brain stem-cord compartment is first filled rapidly because of the fast transport. Later, after about 6 to 12 hours, the tracer concentration is equalized throughout the entire subarachnoid spaces. At the outlets of the fourth ventricle, fresh CSF is poured out continuously into the subarachnoid spaces at the level of the foramen magnum. This slow dilution produces an area of decreasing concentration that is rapidly distributed in the brain stem-cord compartment, and it leaves a zone of tracer remaining at the dead ends of the CSF circulation (ie, over the convexity and at the end of the thecal sac in the lumbosacral area). This explains the convexity maximum shown by RC in the majority of healthy subjects and the lumbosacral maximum found in this study. These findings are also in accordance with the observation of low isotope concentration in the cervical and upper thoracic area of the subarachnoid spaces at 16 hours after ventricular injection of radio-nuclide (4).

The results of the flow phantom experiments presented here and the interpretation of the RC studies in healthy subjects differ from the most commonly accepted concept that the pacchionian granulations (17, 18) are the main pathway of the CSF outflow. This latter assumption is consistent neither with the presence of a convexity maximum in RC of normal subjects that is concomitant with another maximum in the lumbosacral area nor with a local dilution of the tracer at the level of the foramen magnum.

If the CSF is not exclusively drained through the pacchionian granulations, which structure is the best candidate for an alternative outflow pathway? The extracellular spaces of the brain are in open contact with the subarachnoid spaces, as evidenced, for example, by the presence of transmitter metabolites in the CSF and by the penetrance of various tracers (19), including radiographic contrast material (16, 20, 21) from the CSF to the brain. The extracellular fluid spaces are in communication with the brain capillaries, which provides apparent possibilities for the CSF to be resorbed in significant quantities into the flowing blood, as proposed

by Mott in 1910 (22). The lower isotope concentration at the basal parts of the head at 24 hours is a sign of washout through the brain and, in our opinion, strong evidence of brain capillary absorption via the extracellular fluid. Nothing contradicts the assumption that the capillaries have the potential to absorb all constituents of CSF. Water is freely diffusible and most solutes such as mineral ions pass over the blood-brain barrier (23, 24). Furthermore, even larger molecules can pass through the brain-blood barrier; this has been shown for horseradish peroxidase (25), sucrose, inulin (19), and even albumin, as evident from the experiments of Cserr et al (26, 27). Wagner et al (25) found a retrograde transport of horseradish peroxidase from the brain to the blood stream and concluded: "It does not seem to be warranted to treat the blood-brain and the brain-blood barrier as equal phenomena."

The resorption through the central nervous system implies a small bulk flow of a magnitude corresponding to the aqueductal net flow (0.4 mL/min) at the foramen magnum and decreasing toward zero at both ends of the subarachnoid spaces (Fig 5C). The model for the resorption mechanism suggested here could better explain the intimate relationship between CSF flow disturbances as observed in hydrocephalus and cerebral blood flow. The blood flow is decreased in patients with communicating hydrocephalus (28, 29). But this is the cause rather than the result of the reduced CSF absorption, implying that hydrocephalus is of primary vascular origin (30, 31).

## References

1. Di Chiro G. Movement of cerebrospinal fluid in human beings. *Nature* 1964;204:290-291
2. Di Chiro G. Observations on the circulation of the cerebrospinal fluid. *Acta Radiol* 1966;5:988-1002
3. Di Chiro G, Larsson SM, Harrington T, Johnston GS, Green MV, Swann SJ. Descent of cerebrospinal fluid to spinal subarachnoid space. *Acta Radiol* 1973;14:464-470
4. Di Chiro G, Hammock M, Bleyer W. Spinal descent of cerebrospinal fluid in man. *Neurology* 1976;26:1-8
5. Lying-Tunell U, Söderborg B. Quantitative scintigraphic method of estimating the circulation of cerebrospinal fluid. *Acta Radiol* 1972;13:554-569
6. Henriksson L, Voight K. Age-dependent differences of distribution and clearance pattern in normal RIHSA cisternograms. *Neurology* 1976;12:103-107
7. Schossberger PF, Touya JJ. Dynamic cisternography in normal dogs and in human beings. *Neurology* 1976;26:254-260

8. Hannerz J, Greitz D, Ericson K. Periorbital venous vasculitis, intracranial hypertension and empty sella. *Headache* 1994;34:95-98
9. Janny P, Chasel J, Colnet G. Benign intracranial hypertension and disorders of CSF absorption. *Surg Neurol* 1981;15:168-174
10. Bergstrand G, Bergström M, Nordell B, et al. Cardiac gated MR imaging of cerebrospinal fluid flow. *J Comput Assist Tomogr* 1985;9:1003-1006
11. Enzmann DR, Pelc NJ. Normal flow patterns of intracranial and spinal cerebrospinal fluid defined with phase-contrast cine MR imaging. *Radiology* 1991;178:467-474
12. Greitz D, Nordell B, Ericsson A, Ståhlberg F, Thomsen C. Notes on the driving forces of the CSF circulation with special emphasis on the piston action of the brain. *Neuroradiology* 1991;33(suppl):178-181
13. Greitz D, Franck A, Nordell B. On the pulsatile nature of the intracranial and spinal CSF-circulation demonstrated by MR imaging. *Acta Radiol* 1993;34:321-328
14. Nilsson C, Ståhlberg F, Thomsen C, Henriksen O, Herning M, Owman C. Circadian variation in human cerebrospinal fluid production measured by magnetic resonance imaging. *Am J Physiol* 1992;262:R20-R24
15. Nitz WR, Bradley WG Jr, Watanabe AS, et al. Flow dynamics of cerebrospinal fluid: assessment with phase-contrast velocity MR imaging performed with retrospective cardiac gating. *Radiology* 1992;183:395-405
16. Hindmarsh T. Computer cisternography for evaluation of CSF dynamics. Further experiences. *Acta Radiol* 1977;355(suppl):269-279
17. Milhorat TH. The third circulation revisited. *J Neurosurg* 1975;42:628-645
18. Weed LH. Studies on the cerebrospinal fluid, III: the pathways of escape from the subarachnoid spaces with particular reference to the arachnoid villi. *J Med Res* 1914;26:51-92
19. Reed DJ, Woodbury DM. Kinetics of iodide, sucrose, inulin and radio-iodinated serum albumin in the central nervous system and cerebrospinal fluid of the rat. *J Physiol* 1963;169:816-850
20. Drayer BP, Rosenbaum AE. Metrizamide brain penetrance. *Acta Radiol* 1977;supp 355:280-293
21. Jinkins JR, Bashir R, Al-Kawi MZ, Siquiera E. The parenchymal CT myelogram: in vivo imaging of the gray matter of the spinal cord. *AJNR Am J Neuroradiol* 1987;8:979-982
22. Mott FW. The Oliver-Sharpey lectures on cerebrospinal fluid, lecture I: the physiology of cerebrospinal fluid. *Lancet* 1910;2:1-8
23. Sweet WH, Selverstone B, Soloway S, Stetten D. Studies of formation, flow and absorption of cerebrospinal fluid, II: studies with heavy water in normal man. *Surgical Forum: Clinical Congress of American College of Surgeons*. Philadelphia, Pa: WB Saunders Company, 1951:376-381
24. Sweet W, Brownell G, Scholl J, Bowsher D, Benda P, Stickley E. The formation, flow and absorption of CSF: newer concepts based on studies with isotopes. *Res Publ Assoc Nerv Ment Dis* 1954;34:101-159
25. Wagner HJ, Pilgrim CH, Brandl J. Penetration and removal of horseradish peroxidase injected in the cerebrospinal fluid: role of cerebral perivascular spaces, endothelium and microglia. *Acta Neuropathol (Berl)* 1974;27:299-315
26. Cserr HF, Cooper DN, Milhorat TH. Flow of cerebral interstitial fluid as indicated by the removal of extracellular markers from rat caudate nucleus. *Exp Eye Res* 1977;25(suppl):461-473
27. Cserr HF, Cooper DN, Suri PK, Patlak CS. Efflux of radiolabeled polyethylene glycols and albumin from rat brain. *Am J Physiol* 1981;240:F319-F328
28. Greitz T. Cerebral blood flow in occult hydrocephalus studied with angiography and the <sup>133</sup>Xenon clearance method. *Acta Radiol* 1969;8:376-384
29. Greitz T, Grepe A, Kalmer M, Lopes J. Pre- and postoperative evaluation of cerebral blood flow in low-pressure hydrocephalus. *J Neurosurg* 1969;31:644-651
30. Greitz D. Cerebrospinal fluid circulation and associated intracranial dynamics: a radiologic investigation using MR imaging and radionuclide cisternography (thesis). *Acta Radiol* 1993;34(suppl 386):1-23
31. Greitz D, Hannerz J, Rahn T, Bolander H, Ericsson A. MR imaging of cerebrospinal fluid dynamics in health and disease: on the vascular pathogenesis of communicating hydrocephalus and benign intracranial hypertension. *Acta Radiol* 1994;35:204-211