

Endovascular Treatment of Ophthalmic Segment Aneurysms with Guglielmi Detachable Coils

Daniel Roy, Jean Raymond, Alain Bouthillier, Michel W. Bojanowski, Robert Moumdjian, and Georges L'Espérance

PURPOSE: To evaluate the safety and efficacy of endovascular treatment of ophthalmic segment aneurysms with Guglielmi detachable coils (GDCs), as well as the primary indications for such treatment. **METHODS:** We conducted a prospective study of 26 patients with 28 aneurysms of the ophthalmic segment in whom treatment with GDCs was attempted. Anatomic results were measured by statistical analysis of variance for such factors as age, sex, presence of subarachnoid hemorrhage, anatomic type (ophthalmic or superior hypophyseal), size of aneurysmal sac, and width of aneurysmal neck. Clinical evaluation and control angiography were performed at 6 and 18 months. **RESULTS:** Overall, complete occlusion was obtained in 14 aneurysms (50%) and small residual necks were left in 11 aneurysms (39%). Three treatment attempts failed (11%). Complete occlusion was obtained in 76% of small-necked aneurysms as opposed to 9% of aneurysms with a large neck. The best predictor of anatomic result was the size of the aneurysmal neck. Complete occlusion was obtained in 85% of superior hypophyseal aneurysms of the paraclinoid variant. One permanent complication was related to treatment. **CONCLUSION:** Endovascular treatment with GDCs appears to be a safe and efficient alternative approach for ophthalmic segment aneurysms, especially for paraclinoid variants of superior hypophyseal aneurysms, which tend to have a small neck.

Index terms: Aneurysm, embolization; Interventional instruments, coils

AJNR Am J Neuroradiol 18:1207-1215, August 1997

Ophthalmic segment aneurysms present a true surgical challenge owing to their proximity to the optic apparatus as well as to a partial intracavernous extension in some cases. The difficult proximal control and the narrow space to work with lead to a higher frequency of failed clipping procedures as well as to a higher surgical morbidity and mortality (1-12). These aneurysms are frequently referred for endovascular treatment and they are the second most common lesions treated with Guglielmi detachable coils (GDCs) in our institution, after basilar

bifurcation aneurysms. The goal of this study was to evaluate the safety and efficacy of endovascular treatment with GDCs for ophthalmic segment aneurysms and to determine which lesion characteristics correlate with the best anatomic results.

Materials and Methods

This prospective study includes 28 aneurysms in 26 patients referred for GDC treatment between August 1992 and February 1996. Patients were enrolled in a study protocol approved by the US Food and Drug Administration and by the Canadian Health Protection Branch. Four patients were referred for GDC embolization after failed surgical attempts. Other indications for GDC treatment were anticipated surgical difficulties or poor clinical condition.

Patients

The study included 23 women and three men ranging in age from 29 to 70 years (mean, 51 years). Thirteen patients had multiple aneurysms and five had bilateral ophthalmic segment aneurysms.

Received September 9, 1996; accepted after revision January 23, 1997.

From the Departments of Radiology (D.R., J.R.) and Neurosurgery (A.B., M.W.B., R.M.), CHUM, Pavillon Notre-Dame, and the Department of Neurosurgery, Hôpital Sacré-Coeur, (G.L.), Montreal, Quebec, Canada.

Address reprint requests to Daniel Roy, MD, Department de Radiologie, CHUM, Pavillon Notre-Dame, 1560 Sherbrooke St E, Montreal, Quebec, Canada H2L 4M1.

AJNR 18:1207-1215, Aug 1997 0195-6108/97/1807-1207

© American Society of Neuroradiology

Aneurysms

Aneurysms were considered small when less than 11 mm in greatest diameter (15 aneurysms), large when between 11 and 25 mm (11 aneurysms), and giant when more than 25 mm (two aneurysms). Aneurysmal neck size was considered small when equal to 4 mm or less (17 aneurysms) or wide when more than 4 mm (11 aneurysms). Aneurysms were divided into three anatomic subtypes according to criteria established by Day (3): ophthalmic aneurysms (14 aneurysms) and superior hypophyseal aneurysms, consisting of two variants, paraclinoid (13 aneurysms) and suprasellar (one aneurysm) (Fig 1). Two superior hypophyseal aneurysms and nine ophthalmic aneurysms had wide necks.

Clinical Presentation

Patients were divided into two subgroups on the basis of whether the aneurysms had ruptured or not. Eighteen patients with a total of 20 aneurysms were in the nonruptured group. One of these patients suffered optic neuropathy from mass effect by a giant partially thrombosed aneurysm. Subarachnoid hemorrhage due to rupture of another

aneurysm was the presenting symptom in six patients. Other associated anomalies were unrelated stroke (in two patients) and symptomatic contralateral cavernous aneurysm, associated brain arteriovenous malformation, vertebral arteriovenous fistula, unexplained frontal hematoma, and family history of aneurysms (in one patient each). Eight patients were in the ruptured group, in which two were categorized as grade I, one as grade II, three as grade III, and two as grade IV according to the Hunt and Hess classification (13). Four of the 14 ophthalmic aneurysms, three of the 13 paraclinoid aneurysms, and the single suprasellar aneurysm were accompanied by hemorrhage.

Treatment, Anatomic Results, and Follow-up

Treatment was performed according to the technique described previously (14–16). Anatomic results include those seen immediately after treatment, at 6 months, and at 18 months, when applicable. These results were divided into complete occlusion, “dog ear” (corresponding to a unilateral residual neck), residual neck, aneurysmal filling, or failure (Fig 2). Initial anatomic results were considered satisfactory when no opacification of the aneurysmal sac was seen at the end of embolization, even if a small residual neck was present. Treatment complications, clinical outcome, and date of follow-up were recorded. The Glasgow Outcome Scale (GOS) was used to classify clinical outcome.

Statistical Analysis

The Fisher's Exact Test was used to compare nominal variables and the Mann-Whitney test was used to compare continuous variables. Analysis of variance (ANOVA) was used to compare the effect of multiple independent nominal variables over the dependent variable anatomic result. The software Statview 2.02 (Abacus Concepts Inc, Berkeley, Calif) was used to compute statistics.

Results

Patients' age, sex, clinical presentation, aneurysm subtype, size of the aneurysm and the neck, anatomic results, clinical outcome, and interval to follow-up are summarized in Table 1. Clinical examples are illustrated in Figures 3 through 6.

Anatomic Results

Anatomic results were considered satisfactory in 25 (89%) of the 28 aneurysms. There were 14 complete occlusions, 10 residual necks, and one dog ear. Three treatment attempts failed. Two of these patients were treated by open surgery and one patient is being followed up. No aneurysmal filling occurred after treatment. Anatomic results were not signif-

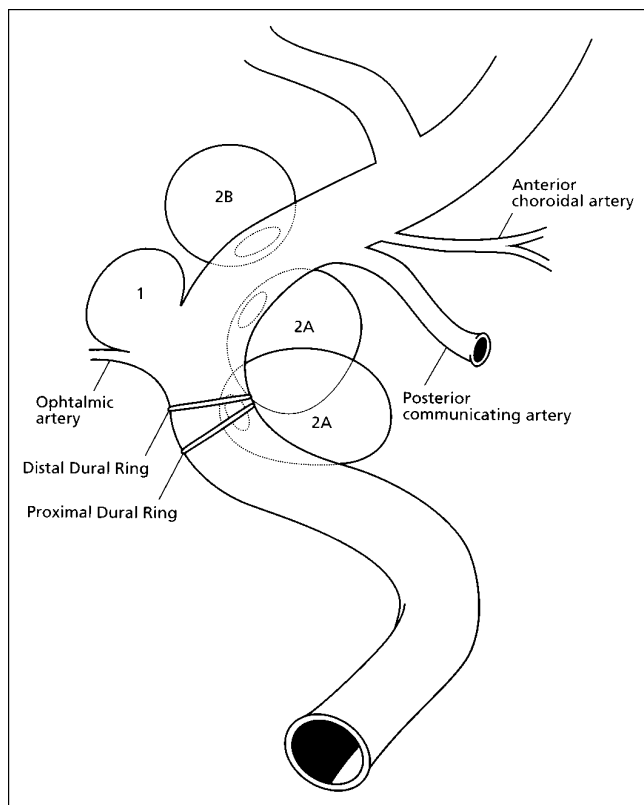


Fig 1. Schematic representation of the classification of ophthalmic segment aneurysms. 1 indicates ophthalmic aneurysm; upper 2A, paraclinoid variant of superior hypophyseal aneurysm; lower 2A, carotid cave aneurysm of Kobayashi (11); and 2B, suprasellar variant of superior hypophyseal aneurysm (adapted from Day [3] and Bouthillier et al [22]).

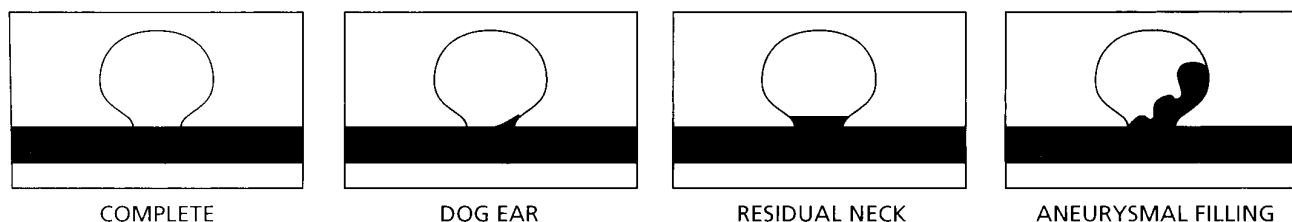


Fig 2. Schematic representation of the classification of anatomic results.

TABLE 1: Findings in 26 patients with ophthalmic segment aneurysms treated with Guglielmi detachable coils

Patient	Sex/Age, y	Clinical Presentation	Subtype	Size	Neck Size	Result	Outcome	Angiographic Follow-up, mo	Clinical Follow-up, mo
1	F/49	Incidental	Ophthalmic	Small	Small	Residual neck	Good	24	50
2	F/68	SAH III	Ophthalmic	Giant	Large	Failure (surgery)	Dead	0	0
3	F/45	Incidental	L ophthalmic, R paraclinoid	Large Small	Small Small	Dog ear	Good	18	34
4	F/49	SAH I	Paraclinoid	Small	Small	Complete	Good	24	35
5	F/62	Incidental	Ophthalmic	Large	Large	Complete	Good	22	37
6	M/44	Incidental	Ophthalmic	Small	Small	Residual neck	Good	27	35
7	F/70	SAH IV	Ophthalmic	Large	Large	Residual neck	Dead	0	0
8	F/38	Incidental	Paraclinoid	Large	Small	Complete	Good	15	27
9	F/44	Incidental	Paraclinoid	Small	Small	Complete	Good	18	34
10	F/29	SAH II	Paraclinoid	Large	Small	Complete	Good	18	33
11	F/65	Incidental	Ophthalmic	Large	Small	Complete	Good	8	20
12	F/39	Mass effect	Ophthalmic	Giant	Large	Failure (surgery)	Good	0	6
13	F/58	Incidental	R ophthalmic, L ophthalmic	Large Small	Large Large	Residual neck	Good	8	25
14	M/45	SAH I	Paraclinoid	Small	Small	Complete	Good	20	20
15	F/49	SAH III	Ophthalmic	Large	Large	Residual neck	Good	18	25
16	F/46	Incidental	Ophthalmic	Small	Small	Complete	Good	24	24
17	F/61	Incidental	Paraclinoid	Small	Small	Residual neck	Good	18	25
18	M/57	Incidental	Paraclinoid	Small	Small	Complete	Good	18	25
19	F/41	Incidental	Paraclinoid	Small	Small	Complete	Good	12	12
20	F/55	SAH III	Suprasellar	Large	Large	Residual neck	Good	3	13
21	F/38	Incidental	Paraclinoid	Small	Small	Complete	Good	6	15
22	F/63	Incidental	Ophthalmic	Large	Large	Residual neck	Minor stroke	11	14
23	F/67	Incidental	Paraclinoid	Small	Large	Residual neck	Good	6	6
24	F/62	SAH III	Ophthalmic	Large	Large	Residual neck	Dead	0	0
25	F/35	Incidental	Paraclinoid	Small	Small	Complete	Good	6	12
26	F/50	Incidental	Paraclinoid	Small	Small	Complete	Good	6	6

icantly influenced by the patient's sex or by the presentation (subarachnoid hemorrhage or not) ($P > .05$). However, patients with complete occlusion were significantly younger: 46 years versus 56 years ($P = .02$). Sixty-seven percent of small aneurysms were completely occluded as opposed to 36% of large aneurysms. Treatment failed in both cases of giant aneurysm. The influence of aneurysmal size on anatomic results did not reach statistical significance ($P = .1$). Seventy-six percent of small-necked aneurysms were completely occluded as compared with 9% of wide-necked aneurysms ($P = .0007$). All three failures occurred in wide-necked aneurysms. Complete occlusion was achieved in 79% of superior hypophyseal aneu-

TABLE 2: Statistical analysis

	Complete Occlusion	Incomplete Occlusion	<i>P</i>
Mean age, y	46	56	0.02 (MWT)*
Female	12	13	0.6 (FET)
Male	2	1	
No SAH	11	9	0.4 (FET)
SAH	3	5	
Ophthalmic	3	11	0.007 (FET)*
Superior hypophyseal	11	3	
Small aneurysms	10	5	0.1 (FET)
Large or giant aneurysms	4	9	
Small neck	13	4	0.0007 (FET)*
Large neck	1	10	

Note.—MWT indicates Mann-Whitney test; FET, Fisher's Exact Test; and SAH, subarachnoid hemorrhage.

* Significant.

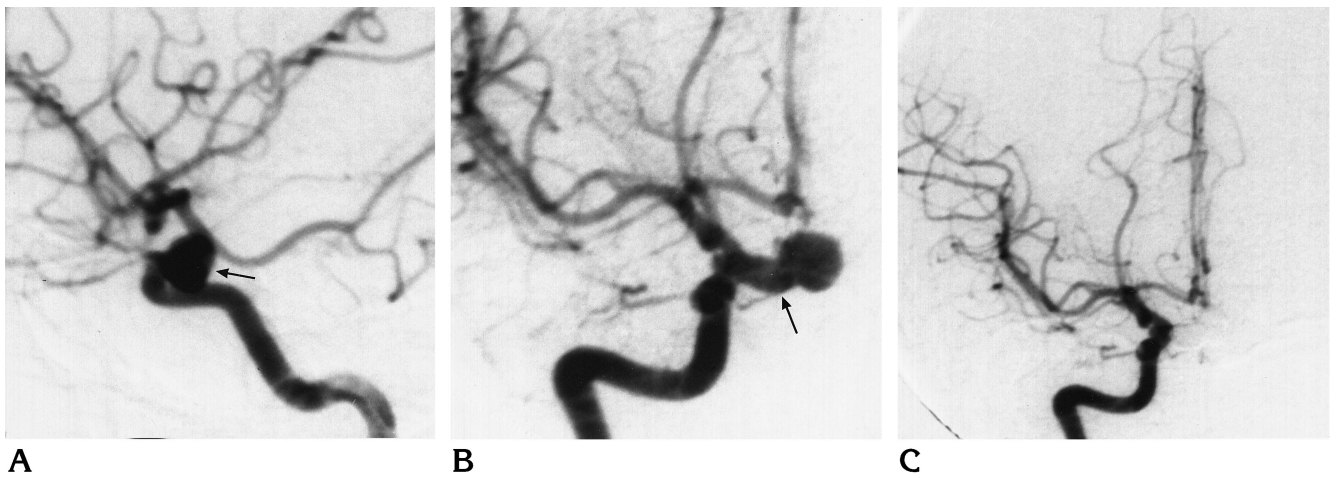
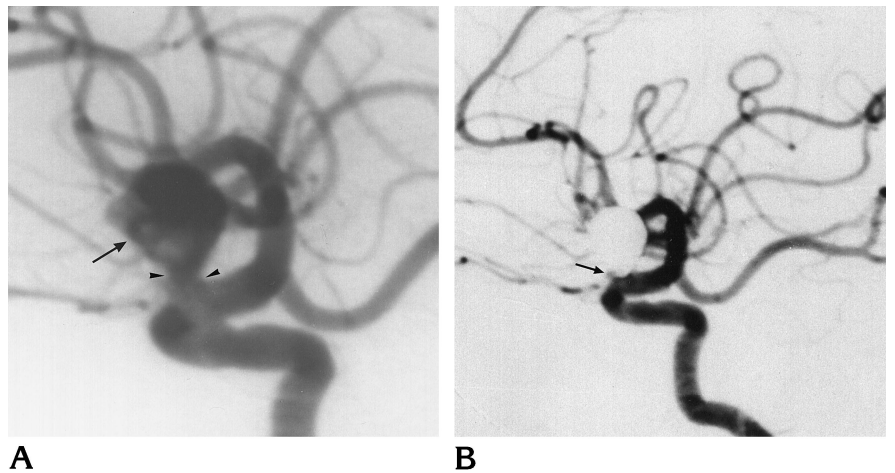


Fig 3. Case 10.
A and B, Right internal carotid artery angiograms (lateral and anteroposterior views, respectively) show paraclinoid variant of superior hypophyseal aneurysm (*arrow*). The dome projects on the cavernous segment of the carotid artery on the lateral view.
C, Right internal carotid artery angiogram (anteroposterior view) after embolization shows complete obliteration.
D, Postembolization CT scan shows the intrasellar position of the aneurysm (*arrow*).

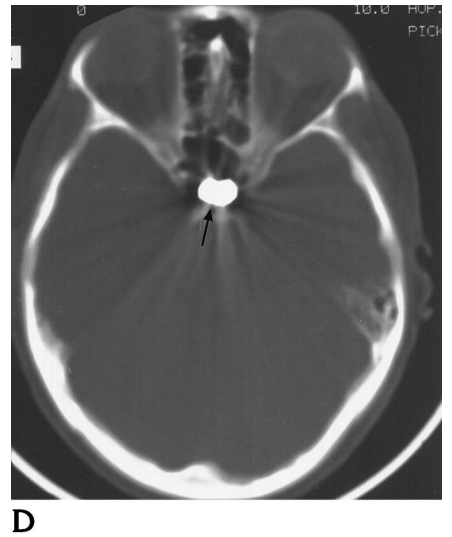

Fig 4. Case 11.
A, Left internal carotid artery angiogram (lateral view) shows ophthalmic aneurysm (*arrow*) with a small neck (*arrowheads*).
B, Left internal carotid artery angiogram (lateral view) 6 months after embolization shows complete obliteration of the aneurysm. *Arrow* points to the origin of the ophthalmic artery.



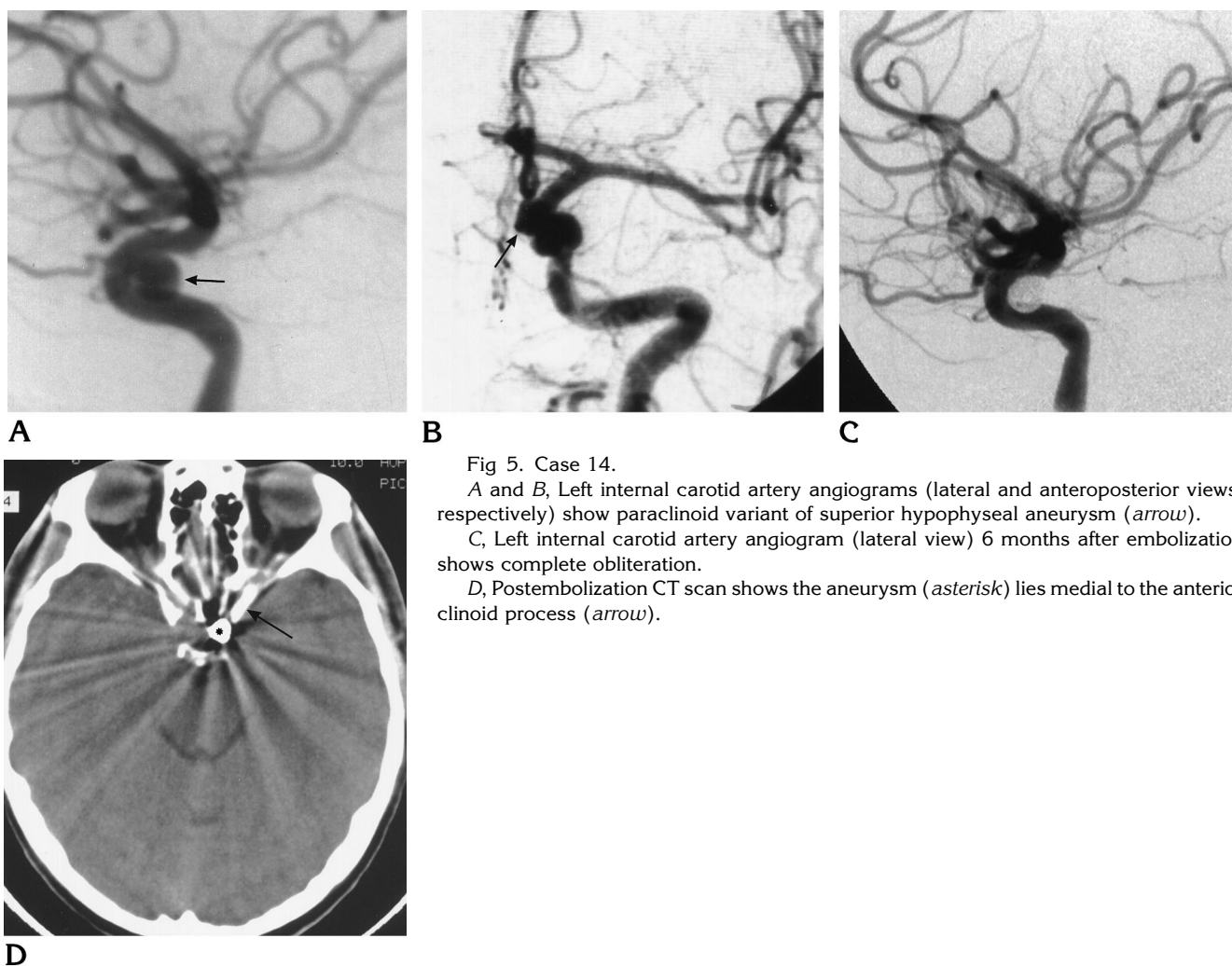


Fig 5. Case 14.

A and B, Left internal carotid artery angiograms (lateral and anteroposterior views, respectively) show paraclinoid variant of superior hypophyseal aneurysm (*arrow*).

C, Left internal carotid artery angiogram (lateral view) 6 months after embolization shows complete obliteration.

D, Postembolization CT scan shows the aneurysm (*asterisk*) lies medial to the anterior clinoid process (*arrow*).

rysms as opposed to 21% of ophthalmic aneurysms ($P = .007$). In the paraclinoid variant of superior hypophyseal aneurysms, 85% of complete occlusion was obtained. Youth and superior hypophyseal type were significantly associated with a small neck ($P = .002$ and $P = .01$, respectively). By ANOVA test, only neck size was a predictor of anatomic result ($F = 16.0$, $P = .0005$). Anatomic results and statistical analyses are summarized in Table 2.

Angiographic control studies 3 to 27 months after treatment were available in 22 patients (mean angiographic follow-up, 15 months). All complete occlusions persisted (mean angiographic follow-up, 14 months). Residual necks were slightly larger in two of nine patients at the 6-month angiographic follow-up. In one of these patients, retreatment was attempted but the residual neck was too small for deposition of a

coil. In the seven other patients, control angiography showed a stable appearance.

Clinical Outcome

In the group of nonruptured aneurysms, all 17 patients had good outcomes. No patient bled after treatment (mean clinical follow-up, 23.5 months). In the ruptured group, five patients had good outcomes (GOS I). Three patients died of complications of their initial hemorrhage and one patient died as a result of surgical complications. There was no rebleeding among the five surviving patients (mean clinical follow-up, 25 months).

Complications

In two patients, a middle cerebral artery embolus occurred during treatment; both patients were treated with local injection of urokinase,

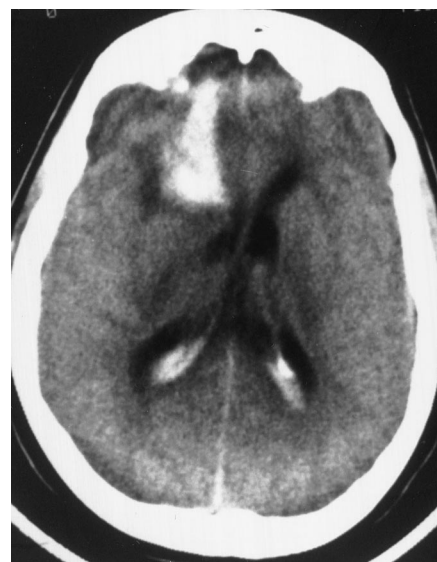Fig 6. Case 15.

A, CT scan shows right frontal hematoma with intraventricular blood.

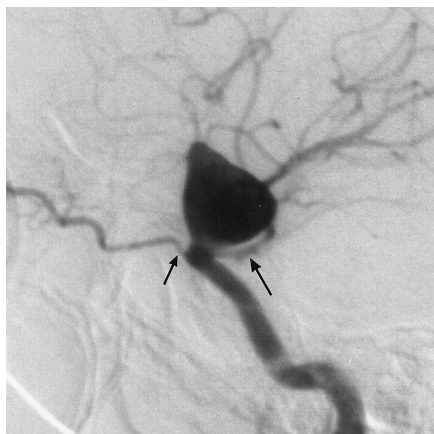
B, Right internal carotid artery angiogram (lateral view) shows large ophthalmic aneurysm with large neck. *Long arrow* points to the spastic supraophthalmic internal carotid artery, *short arrow* points to the low origin of the ophthalmic artery.

C, Right internal carotid artery angiogram (lateral view) immediately after embolization shows a small residual neck (*arrow*).

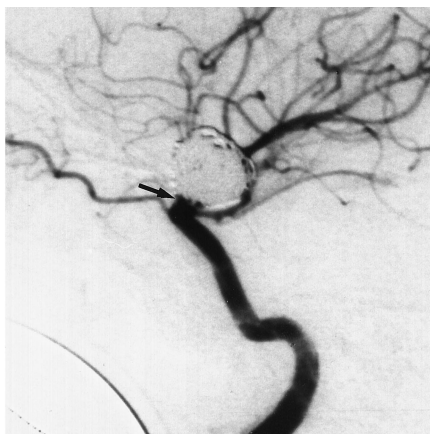
D, Right internal carotid artery angiogram (lateral view) at 6 months shows the spasm is relieved (*long arrow*); the residual neck (*short arrow*) appears larger.



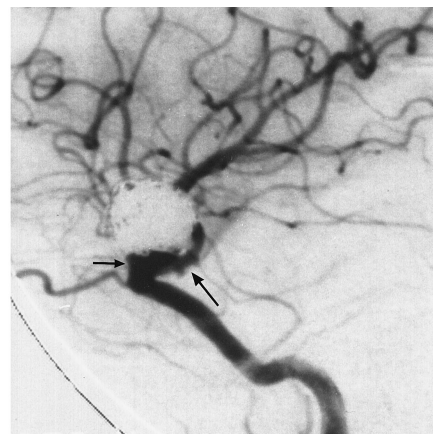
A



B



C



D

which resulted in complete recovery with no detectable deficits. One permanent complication related to treatment occurred 24 hours after embolization when one patient became suddenly hemiparetic and aphasic. Immediate control angiography showed that a loop of coil had moved out of the aneurysm into the lumen of the internal carotid artery (ICA). It was associated with a nonocclusive clot and distal emboli. Urokinase was infused locally into the ICA and the patient was treated with heparin for 5 days, followed by aspirin. She made a good recovery but still has a residual paresis of the right hand. No aneurysmal perforations occurred during any of the procedures.

Discussion

Ophthalmic segment aneurysms account for approximately 5% of all intracranial aneu-

rysms. They share a striking female predominance as well as a higher association with multiple aneurysms in most series (2-6, 8-10, 17-20). Aneurysms originating at any point on the ICA between the ophthalmic artery and the posterior communicating artery have been referred to as carotid-ophthalmic aneurysms (17). Many types of lesions are included in this definition. Some are clearly related to the origin of the ophthalmic artery while others appear to be located more distal or proximal on the ICA. The latter ones may sometimes be confused with cavernous aneurysms. The surgical approaches and challenges associated with these different subtypes of ophthalmic segment aneurysms differ (1, 9, 11, 12, 21). In order to define the lesions that may have the most favorable response to treatment with GDCs, it is useful to review the anatomy and

classification of ophthalmic segment aneurysms.

Anatomy

The risk of hemorrhage differs significantly between intradural and extradural aneurysms (19). The absence of a reliable radiologic landmark for the entry of the ICA into the subarachnoid space contributes to the confusion between intradural and extradural lesions. In the recently published classification by Bouthillier et al (22), the C5, or clinoid, segment refers to a small wedge-shaped segment lying between the proximal and distal dural ring of the ICA. Strictly, this segment is extradural even though supracavernous. Anatomic dissections show that on the medial side of this segment, the dura is loosely adherent to the ICA and that a dural evagination, called the carotid cave, may often be seen (11, 22–24). This carotid cave is part of the ophthalmic (C6) segment, an intradural section that lies between the distal dural ring and the origin of the posterior communicating artery (22, 25). Practically, an aneurysm originating from the wall of the ICA opposite the ophthalmic artery and projecting medially on an angiogram may be regarded as having at least an intradural component, even if the dome extends lower at the level of the cavernous sinus on lateral projections. Such aneurysms have been well documented (11, 12) and referred to as carotid-cave aneurysms by Kobayashi et al (11). These aneurysms have been proved to rupture into the subarachnoid space (2, 3, 11, 12).

Classification

Paraclinoid (2, 9, 12, 18), proximal internal carotid (19), and paraophthalmic (26) aneurysms are different terms used for ophthalmic segment aneurysms in the literature. We retained the classification proposed by Day (3), who divided the ophthalmic segment aneurysms into ophthalmic aneurysms and superior hypophyseal aneurysms. The interest in this classification lies in the fact that most surgical series have displayed a difference in the technical challenge and morbidity associated with the treatment of these two groups of aneurysms (1, 9, 11, 12, 21). The first group represents the true carotid-ophthalmic aneurysms; that is, those sitting at the junction between the ICA and

the origin of the ophthalmic artery. Aneurysms originating on the posterior or posteromedial side of the ICA at the level of the origin of the ophthalmic artery or slightly higher are referred to as *superior hypophyseal aneurysms* (3, 25). This group is divided into two variants: the paraclinoid and the suprasellar (3) (Fig 1). The paraclinoid variant is of special interest, as it often has an intracavernous proximal neck and fundus with only the distal neck lying in the subarachnoid space. We included in the paraclinoid variant what Kobayashi et al (11) called *carotid cave aneurysms*, because both involve the proximal and medial parts of the ophthalmic segment and there is no reliable angiographic landmarks to differentiate them. Paraclinoid and carotid cave aneurysms share many similarities in terms of intradural neck location, possible extension of their domes into the cavernous sinus, and the occasional need to open the cavernous sinus to clip them (27).

Surgery

The surgical challenge with ophthalmic segment aneurysms relates to the proximity of the anterior clinoid process, the optic nerve, and the cavernous sinus. Proximal control on the ICA often requires exposure of the carotid artery at the neck (2, 3, 7, 9, 11, 18, 21). Exposure of the aneurysm itself requires drilling the anterior clinoid process (2, 3, 6, 9, 11, 17, 18, 20, 21, 23, 24). Especially in cases of paraclinoid aneurysms, opening the cavernous sinus may also be required (9, 11, 17, 18, 27). Even with improved surgical techniques, a great deal of experience and mastery in this anatomic region is necessary in order to obtain satisfactory results (2–5, 9, 17). It is difficult to evaluate the true impact of this anatomic site in terms of surgical morbidity or mortality in large series, since they are often mixed together with all the other internal carotid aneurysms (28–32). Specific studies concerning the surgical treatment of ophthalmic segment aneurysms report a number of failed clippings, ischemic complications, and optic nerve injuries (1–6, 9, 11, 12, 18), especially for the paraclinoid variant of superior hypophyseal aneurysms (9, 11, 12, 21). Fox (9), in a series of eight patients with this type of aneurysm, had one patient who was operated on twice and another who underwent four operations; one aneurysm could not be clipped and was wrapped; two patients had visual compli-

cations; and one had an ischemic complication. In a series of seven patients, Kobayashi et al (11), dealing also with this subtype of aneurysm, reported two failed clippings, two visual complications, and one case of rhinorrhea. In a series described by Nutik (12), none of five aneurysms could be clipped completely and four patients died.

Comparison of the anatomic results obtained with surgery and with GDC treatment is difficult, since most surgical series do not mention the findings at control angiography (1-3, 5-7, 16, 19, 24). In the series reported by Fox (9), control angiograms obtained after surgery showed residual aneurysm that necessitated reoperation in two of the seven patients in whom a clip was applied.

GDC Embolization

A review of a multicentric GDC study revealed the proportion of ophthalmic segment aneurysms to be higher than their actual prevalence would suggest (F. Viñuela, unpublished data, April 1995). These lesions include over 20% of the aneurysms in our own series. This finding may be an indicator of how difficult many surgeons consider some of these aneurysms. Early results with GDC treatment show that protection against rebleeding in acutely treated aneurysms is excellent (33). The anatomic results, however, seem to be less satisfactory than with surgery. We consider an anatomic result to be satisfactory despite the presence of a small residual neck provided that complete obliteration of the sac is obtained. In our experience, as well as that described for the multicentric study, this kind of result is not associated with early rebleeding in cases of ruptured aneurysms. The most successful aneurysmal occlusions are obtained in small aneurysms with small necks (34). In the present series, the most successful occlusions were obtained with the paraclinoid variant of superior hypophyseal aneurysms, and statistical analysis showed that this was attributed to the small size of the neck. The width of the neck reflects the size of the wall defect. A smaller defect has theoretically a greater chance of being completely covered by the coils. Also, a small neck allows tighter packing of the aneurysm.

Most of the superior hypophyseal aneurysms had a small neck as compared with the ophthalmic aneurysms. This pattern may be biased by

the fact that most patients with the former aneurysms were referred for endovascular treatment while those with small-necked ophthalmic aneurysms were referred for surgery. No statistically significant difference was found between small and large aneurysms in terms of anatomic results, although there was a strong trend for more favorable outcomes with smaller aneurysms. The difference of anatomic results in relation to patient age could be theoretically explained by the presence of more tortuous vessels with more difficult access to the aneurysm in elderly patients. However, statistical analysis showed a higher percentage of wide-necked aneurysms in older patients.

The high prevalence of incomplete obliteration with endovascular treatment is a matter of concern for long-term evolution. Until more data concerning the consequences of a residual neck after GDC embolization are available, yearly control angiograms are indicated for incompletely occluded aneurysms. Retreatment is an option when the size of the recurrence permits placement of additional coils.

Failures and Complications of GDC Treatment

Wide-necked aneurysms may be impossible to treat with GDC embolization. In our three failed attempts, we did not use the balloon technique in front of the neck to avoid coil protrusion. The issue of this technique in terms of results and complications remains to be resolved. Two of our failures were in giant aneurysms. GDC embolization of giant aneurysms also produced unsatisfactory results in the multicentric study (F. Viñuela, unpublished data, April 1995). These aneurysms are also associated with the poorest surgical results (2, 18). The giant aneurysms in our series were not treated by GDC embolization because we could not avoid coil protrusion during deposition of the first coil. The management of giant ophthalmic segment aneurysms remains a challenge.

The three complications related to treatment in our series were thromboembolic events. Two of these occurred during treatment and were managed immediately without any sequelae. The third complication, a stroke, occurred the day after embolization with documented late displacement of a loop of coil, a rare event. Anticoagulation for a few days may be considered as a way to prevent delayed thromboembolic complications.

Indications for GDC Treatment

Endovascular treatment with GDCs is now our first option for the paraclinoid variant of superior hypophyseal aneurysms. Even if modern surgical techniques allow improved access to the anterior part of the cavernous sinus (17, 23, 24), the excellent anatomic and clinical results achieved with GDC treatment in our series support this therapeutic option. GDC embolization is also a valid alternative for ophthalmic aneurysms with a small neck. Further experience and technical improvements are needed to ameliorate the results in large-necked aneurysms. We would consider GDC embolization in elderly patients, in whom a neck remnant may be regarded with less concern, or in patients with a poor clinical grade.

Conclusion

Endovascular treatment with GDCs proved to be a safe and efficient alternative approach in a selected group of patients with ophthalmic segment aneurysms. The size of the neck was the most important determinant of satisfactory anatomic results. The best anatomic results were obtained in the paraclinoid variant of superior hypophyseal aneurysms.

References

- Almeida GM, Shibata MK, Bianco E. Carotid-ophthalmic aneurysms. *Surg Neurol* 1976;5:41-45
- Batjer HH, Kopitnik TA, Giller CA, Samson DS. Surgery of paraclinoid carotid artery aneurysms. *J Neurosurg* 1994;80:650-658
- Day AL. Aneurysms of the ophthalmic segment: a clinical and anatomical analysis. *J Neurosurg* 1990;72:677-691
- Drake CG, Vanderlinden RG, Amacher AL. Carotid-ophthalmic aneurysms. *J Neurosurg* 1968;29:24-36
- Ferguson GG, Drake CG. Carotid-ophthalmic aneurysms: visual abnormalities in 32 patients and the results of treatment. *Surg Neurol* 1981;16:1-8
- Guidetti B, La Torre E. Management of carotid-ophthalmic aneurysms. *J Neurosurg* 1975;42:438-442
- Sengupta RP, Gryspeerdt GL, Hankinson J. Carotid-ophthalmic aneurysms. *J Neurol Neurosurg Psychiatry* 1976;39:837-853
- Thurel C, Rey A, Thiébaud JB, et al. Anévrysmes carotido-ophthalmiques. *Neurochirurgie* 1974;20:25-39
- Fox JL. Microsurgical treatment of ventral (paraclinoid) internal carotid artery aneurysms. *Neurosurgery* 1988;22:32-39
- Kothandaram P, Dawson BH, Krut R. Carotid-ophthalmic aneurysms: a study of 19 patients. *J Neurosurg* 1971;34:544-548
- Kobayashi S, Kyoshima K, Gibo H, et al. Carotid cave aneurysms of the internal carotid artery. *J Neurosurg* 1989;70:216-221
- Nutik S. Carotid paraclinoid aneurysms with intradural origin and intracavernous location. *J Neurosurg* 1978;48:526-533
- Hunt WE, Hess RM. Surgical risk as related to time of intervention in the repair of intracranial aneurysms. *J Neurosurg* 1968;28:14-19
- Guglielmi G, Vinuela F, Sepetka I, Macellari V. Electrothrombosis of saccular aneurysms via endovascular approach. Part 1: Electrochemical basis, technique, and experimental results. *J Neurosurg* 1991;75:1-7
- Guglielmi G, Vinuela F, Dion J, Duckwiler G. Electrothrombosis of saccular aneurysms via endovascular approach. Part 2: Preliminary clinical experience. *J Neurosurg* 1991;75:8-14
- Guglielmi G, Vinuela F, Duckwiler G, et al. Endovascular treatment of posterior circulation aneurysms by electrothrombosis using electrically detachable coils. *J Neurosurg* 1992;77:515-524
- Dolenc VV. A combined epi- and subdural direct approach to carotid-ophthalmic artery aneurysms. *J Neurosurg* 1985;62:667-672
- Heros RC, Nelson PB, Ojemann RG, et al. Large and giant paraclinoid aneurysms: surgical techniques, complications, and results. *Neurosurgery* 1983;12:153-163
- Punt J. Some observations on aneurysms of the proximal internal carotid artery. *J Neurosurg* 1979;51:151-154
- Yasargil MG, Gasser JC, Hodosh RM, Rankin TV. Carotid-ophthalmic aneurysms: direct microsurgical approach. *Surg Neurol* 1977;8:155-165
- Yasargil MG. *Microneurosurgery, II: Clinical Considerations, Surgery of the Intracranial Aneurysms and Results*. Georg Thieme; New York, NY: 1984:43-70
- Bouthillier A, Van Loveren HR, Keller JT. Segments of the internal carotid artery: a new classification. *Neurosurgery* 1996;38:425-432
- Knosp E, Muller G, Perneczky A. The paraclinoid carotid artery: anatomical aspects of a microneurosurgical approach. *Neurosurgery* 1988;22:896-901
- Perneczky A, Knosp E, Vorkapic P, Czech Th. Direct surgical approach to infraclinoid aneurysms. *Acta Neurochir* 1985;76:36-44
- Gibo H, Lenkey C, Rhoton AL Jr. Microsurgical anatomy of the supraclinoid portion of the internal carotid artery. *J Neurosurg* 1981;55:560-574
- Pia HW. Classification of aneurysms of the internal carotid system. *Acta Neurochir* 1978;40:5-31
- Al-Rodhan NRF, Piepgras DG, Sundt TM Jr. Transitional cavernous aneurysms of the internal carotid artery. *Neurosurgery* 1993;33:993-996
- Kassel NF, Torner JC, Clarke Haley E Jr, et al. The international cooperative study on timing of aneurysm surgery. Part 1: Overall management results. *J Neurosurg* 1990;73:18-36
- Kassel NF, Torner JC, Jane J. The international cooperative study on the timing of aneurysm surgery. Part 2: Surgical results. *J Neurosurg* 1990;73:37-47
- Sundt TM Jr, Whisnant JP. Subarachnoid hemorrhage from intracranial aneurysms: surgical management and natural history of disease. *N Engl J Med* 1978;299:116-122
- Sundt TM, Kobayashi S, Fode NC, Whisnant JP. Results and complications of surgical management of 809 intracranial aneurysms in 722 cases: related and unrelated to grade of patient, type of aneurysm, and timing of surgery. *J Neurosurg* 1982;56:753-765
- Yoshimoto T, Uchida K, Kaneko U, et al. An analysis of follow-up results of 1000 intracranial saccular aneurysms with definitive surgical treatment. *J Neurosurg* 1979;50:152-157
- Graves VB, Strother CM, Duff TA, Perl J II. Early treatment of ruptured aneurysms with Guglielmi detachable coils: effect on subsequent bleeding. *Neurosurgery* 1995;37:640-647
- Zubillaga AF, Guglielmi G, Vinuela F, Duckwiler GR. Endovascular occlusion of intracranial aneurysms with electrically detachable coils: correlation of aneurysm neck size and treatment results. *AJNR Am J Neuroradiol* 1994;15:815-820