
Preoperative Embolization of Anastomoses of the Jugular Bulb: An Adjuvant in Jugular Foramen Surgery

David A. Carrier, Moises A. Arriaga, Michael J. Gorum, Richard T. Dahlen, and Stephen P. Johnson

Summary: We describe the technique of preoperative embolization of the inferior petrosal sinus/anterior condylar vein complex and the posterior condylar vein in three patients undergoing skull base surgery that required opening of the jugular bulb. Contrary to the usual situation, essentially no blood was lost during the operation, resulting in decreased surgical time and reduced risk to the lower cranial nerves.

Index terms: Interventional neuroradiology; Skull, base; Veins, jugular

In skull base surgeries involving the region of the jugular foramen, the jugular bulb is frequently opened after the sigmoid sinus and the proximal internal jugular vein have been ligated. As a result, significant back bleeding occurs from other tributaries to the jugular bulb, such as the inferior petrosal sinus/anterior condylar vein complex, the posterior condylar vein, and, occasionally, from other unnamed anastomoses. Bleeding is controlled by packing with absorbable hemostatic material (eg, Surgicel [Johnson and Johnson, Arlington, Tex]). Besides the significant loss of blood and increased surgical time, this procedure carries the risk of compression injury to cranial nerves IX, X, and XI from overpacking. Since these anastomoses to the jugular bulb have been occluded during surgery for the last 25 years without reports of complications, we believe they can be embolized before surgery with very little risk.

Case Reports

Case 1

A 36-year-old man had a 2-year history of hoarseness and weakness in the left shoulder. Physical examination confirmed left-sided palatal weakness, left vocal cord pa-

ralysis, left-sided neck and shoulder weakness, and normal tongue function. A magnetic resonance (MR) image showed a heterogeneously enhancing well-circumscribed mass in the left jugular foramen that extended slightly into the upper part of the neck (Fig 1). The right transverse and sigmoid sinuses were patent. Via a right common femoral vein puncture, a 5F vertebral catheter was advanced into the left jugular bulb and digital subtraction venography was performed. There was reflux of contrast material into the sigmoid sinus and a moderately sized anteromedial vein (probably the anterior condylar vein), which anastomosed with a large vein of the vertebral venous plexus. The inferior petrosal sinus did not fill and could not be located, despite a dedicated effort. Since the vertebral catheter could not be advanced into the anastomosing vein, a microcatheter was advanced coaxially through the vertebral catheter into the anastomosing vein to deploy four 3×8 -, two 5×14 -, two 2×20 -, two 2×10 -, and one 5×15 -mm microcoils. The vein continued to fill after embolization, but the flow was sluggish and we thought that complete thrombosis would develop in time. At surgery, when the jugular bulb was opened, no back bleeding occurred, confirming thrombosis of the anterior condylar vein and absence of a separate inferior petrosal sinus. At pathologic examination, the mass was confirmed to be a meningioma. No improvement of the preoperative ninth, 10th, and 11th nerve palsies was noted after surgical resection of the tumor.

Case 2

A 64-year-old man had a 2-year history of right-sided serous otitis media, diffuse right-sided head and ear pain, right-sided tongue weakness, and severe right-sided mixed hearing loss. MR images and computed tomographic (CT) scans revealed a complex right-sided nasopharyngeal mass that extended posteriorly, laterally, and inferiorly to involve the petrous apex, parapharyngeal space, carotid space, right side of the lower clivus, and skull base medial to the jugular bulb, including the hypo-

Received April 23, 1996; accepted after revision October 28.

The opinions expressed in this article are those of the authors and do not necessarily represent those of the Department of Defense or other departments of the US Government.

From the Departments of Radiology (D.A.C., R.T.D., S.P.J.), Otolaryngology/Neurotology (M.A.A.), and Neurosurgery (M.J.G.), Wilford Hall Medical Center, Lackland Air Force Base, Texas.

Address reprint requests to David A. Carrier, MD, Department of Radiology, Danbury Hospital, 24 Hospital Ave, Danbury, CT 06810.

AJNR 18:1252-1256, Aug 1997 0195-6108/97/1807-1252 © American Society of Neuroradiology

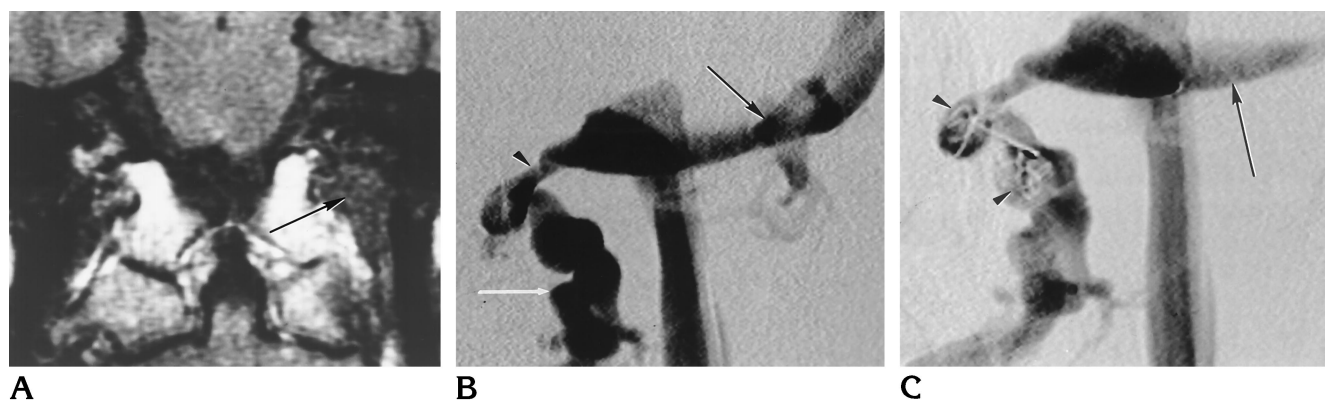


Fig 1. Case 1: 36-year-old man with hoarseness and left shoulder weakness.

A, Coronal T1-weighted (450/23/1 [repetition time/echo time/excitations]) MR image shows a well-circumscribed soft-tissue signal intensity mass (*arrow*) in the left jugular foramen extending slightly into the neck medial to the internal jugular vein. Heterogeneous enhancement was visible after administration of contrast material (not shown).

B, Anteroposterior venogram of the left jugular bulb shows reflux into the sigmoid sinus (*black arrow*) and filling of a large vein of the vertebral venous plexus (*white arrow*) via a moderate-sized anterior condylar vein (*arrowhead*). The inferior petrosal sinus does not fill.

C, Anteroposterior venogram of the left jugular bulb after deployment of coils into the anterior condylar vein and vertebral venous plexus vein (*arrowheads*) shows decreased filling and sluggish flow. The sigmoid sinus (*arrow*) remains patent.

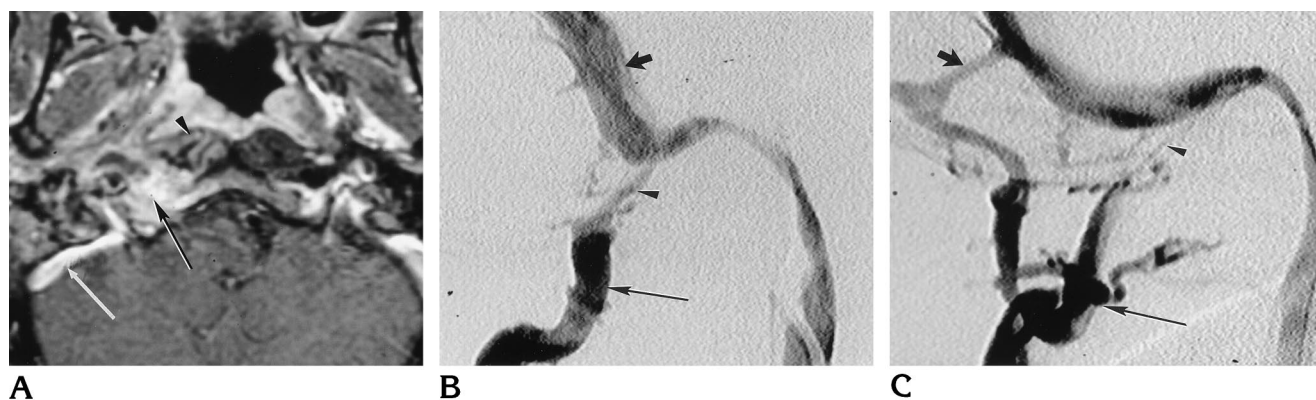


Fig 2. Case 2: 64-year-old man with right-sided serous otitis media, diffuse head and ear pain, tongue weakness, and mixed hearing loss.

A, Contrast-enhanced axial T1-weighted (450/23/1) MR image shows an enhancing mass extending posterolaterally from the nasopharynx to involve the lower right clivus and adjacent skull base in the region of the jugular bulb (*black arrow*). There is associated enhancement of the right longus colli muscle (*arrowhead*). The sigmoid sinus (*white arrow*) is patent and abuts the lateral aspect of the mass as it begins to enter the jugular bulb.

B, Lateral venogram of the right jugular bulb shows reflux into the sigmoid sinus (*short arrow*) but no filling of the inferior petrosal sinus or anterior condylar vein. A large vein of the posterior vertebral venous plexus (*long arrow*) fills via a moderate-sized posterior condylar vein (*arrowhead*).

C, Lateral venogram after deployment of coils in the posterior condylar vein shows markedly reduced flow (*arrowhead*). The posterior vertebral venous plexus (*long arrow*) still fills via an anastomosis (*short arrow*) to the sigmoid sinus. This vessel was not embolized, since it entered the sinus proximal to the planned point of ligation.

glossal canal (Fig 2). The tumor enhanced fairly homogeneously, with a few small areas of nonenhancement. The CT scan showed bony destructive changes as well as secondary changes of fluid in the mastoid air cells and denervation atrophy of the right side of the tongue. The left transverse and sigmoid sinuses were patent. Via a right femoral vein puncture, a 5F vertebral catheter was advanced into the jugular bulb and digital subtraction venography was performed. There was reflux of contrast material into the sigmoid sinus and a moderate-sized posterior condylar vein, which anastomosed with a large vein in the

posterior vertebral venous plexus in the neck. No filling occurred in the inferior petrosal sinus or anterior condylar vein, despite a dedicated search for these tributaries. The 5F catheter was able to be advanced into the posterior condylar vein, and two 3×20 -mm coils were deployed. Decreased flow was observed on the postembolization angiogram. The large vein in the posterior part of the neck continued to fill, but now primarily through an additional anastomosis arising from the sigmoid sinus. This vein was not embolized, since it was proximal to the planned point of ligation of the sigmoid sinus. When the jugular bulb was

opened at surgery, no back bleeding occurred, confirming the absence or occlusion of the inferior petrosal sinus/anterior condylar vein complex and thrombosis of the posterior condylar vein. The lesion was determined to be a petrous apex epidermoid with secondary actinomycosis infection. Neither embolization nor surgery caused any complications, and the 12th cranial nerve palsy improved after surgery.

Case 3

A 74-year-old woman had a 3-year history of recurrent warts (*verruccous vulgaris*) of the right external auditory canal and a 3-month history of severe pain in the right ear, imbalance, and mixed hearing loss. Results of a biopsy of a new fungating mass of the posterior external auditory canal disclosed a verrucous carcinoma. A CT scan of the temporal bone showed a mass involving the right mastoid air cells, mesotympanum, and epitympanum, with destruction of the posterior wall of the external auditory canal and the bone around the facial recess and mastoid segment of cranial nerve VII. The tumor abutted the sigmoid plate and tegmen without definite involvement. At MR imaging, the tumor was poorly enhancing and could be separated from the high signal intensity of obstructed mastoid air cells on the T2-weighted image. The tegmen was intact, but minimal enhancement of the overlying dura was thought to represent reactive change, although tumor involvement could not be excluded. Via a right common femoral vein puncture, a 5F vertebral catheter was placed in the jugular bulb. A digital subtraction venogram revealed a small anterior tributary and a large posterior condylar vein but no reflux into the sigmoid sinus. The anterior vein was selectively catheterized with the 5F catheter. This represented the inferior petrosal sinus/anterior condylar vein complex with a plexus of veins extending superiorly toward the cavernous sinus and anastomoses inferiorly with the vertebral venous plexus. Two 3×10 -mm coils were deployed in this position directly through the 5F catheter. On the postembolization study, the superior plexus did not fill and reduced flow was observed inferiorly. Since the vertebral catheter could not be advanced directly into the posterior condylar vein, a microcatheter was advanced coaxially and eight 10×30 -mm microcoils deployed. After embolization, markedly reduced flow was seen in the posterior condylar vein. The microcatheter was also advanced across the torcular to confirm patency. At surgery, after identifying the vein of Labbé and ligating the sigmoid sinus and internal jugular vein, the jugular bulb was opened. There was no back bleeding, and the surgeons were able to proceed directly with an en bloc resection of the temporal bone and skull base. A CT scan the next day revealed a small right-sided temporal lobe hematoma and surrounding edema, thought to be a venous infarct. The patient recovered and is without neurologic deficit other than that expected of the right seventh and eighth cranial nerves.

Discussion

Several skull base surgical procedures in and around the jugular foramen require the jugular bulb to be opened during surgery after ligation of the sigmoid sinus distal to the entry of the vein of Labbé and the internal jugular vein just distal to the jugular bulb. When the jugular bulb is opened, there is almost always marked back bleeding from other connections to the bulb (1), such as the inferior petrosal sinus, the anterior condylar vein, the posterior condylar vein, the vein of the cochlear aqueduct, and, rarely, from unnamed anastomoses (2, 3). Bleeding is initially controlled by packing with large amounts of absorbable hemostatic material, which is subsequently trimmed and repositioned in the individual lumens of veins opening into the jugular bulb. Owing to the intimate relationship of cranial nerves IX, X, and XI to the bulb and, in particular, to the inferior petrosal sinus (1–4), this procedure may result in injury to any of these lower cranial nerves (1). Our neuro-otologist estimates that this surgical procedure typically takes at least 15 minutes and results in about 300 mL of blood loss. To decrease surgical time, blood loss, and risk to the lower cranial nerves, we decided to embolize before surgery feeders to the jugular bulb that were destined to be occluded during surgery.

To ensure that the vein of Labbé and other veins draining the brain are not compromised when the jugular bulb is isolated, patency of the torcular and contralateral transverse and sigmoid sinuses should be verified by arteriography, MR imaging, or MR angiography, or by advancing a microcatheter across the torcular.

The next step in this procedure is to ascertain the venous anatomy of the jugular bulb with a digital subtraction venogram. We used a vertebral catheter, but any catheter suitable for inferior petrosal sinus sampling would be acceptable. The anatomy is complex and variable and was first defined by early European anatomists. More recently, venography done during inferior petrosal sinus sampling (5–8) and through direct catheterization of jugular bulb feeders has provided additional insight (9, 10). Shiu et al (5) described a classification system for the inferior petrosal sinus/anterior condylar vein complex that was further refined by Miller et al (6). In type I drainage (45%), the inferior petrosal sinus drains directly into the jugular bulb and connects to the suboccipital and vertebral plexus

via a small anterior condylar vein. In type II drainage (24%), the inferior petrosal sinus joins an anterior condylar vein of similar size before draining into the jugular bulb. The anterior condylar vein again has variable connections to the suboccipital and vertebral plexus. In type III drainage (24%), a plexus of veins extends from the cavernous sinus to the jugular bulb and the vertebral and suboccipital plexus. In type IV drainage (7%), the inferior petrosal sinus does not connect with the jugular bulb but anastomoses directly with the vertebral and suboccipital plexus. Miller et al (8) later defined an incomplete type IV pattern, in which a small vein connects the internal jugular vein to the point of anastomosis between the inferior petrosal sinus and vertebral venous plexus. In sum, the inferior petrosal sinus/anterior condylar vein complex anastomoses with the jugular bulb over 90% of the time. The posterior condylar vein that anastomoses with the posterior vertebral venous plexus is also a frequent tributary of the jugular bulb (10).

The anatomy in our cases was somewhat atypical. In case 1, there was only an anterior condylar vein and no inferior petrosal sinus, probably representing the unusual type IV drainage. In case 2, there was only a posterior condylar vein. The inferior petrosal sinus in this patient was most likely occluded because of its intimate association with the infection (11). In case 3, the inferior petrosal sinus extended from the cavernous sinus as a plexus before joining branches of the vertebral venous plexus and emptying into the jugular bulb as a single trunk, representing a hybrid of types II and III drainage. The exact pattern of drainage in a particular patient is unimportant, as the relevant feeders to the jugular bulb are easily defined on the preembolization venogram.

Catheterization of the jugular bulb and inferior petrosal sinus has been well described in large series for inferior petrosal sinus sampling (5–8). With a 5F catheter in the jugular bulb, a venogram is obtained to identify any feeders to the jugular bulb that could result in back bleeding when the bulb is opened at surgery. Typically, this will consist of some combination of the inferior petrosal sinus, anterior condylar vein, or posterior condylar vein. Pertinent tributaries are catheterized with the 5F diagnostic catheter, and standard vascular coils sized to the vein are deployed. For vessels not accessible with the 5F catheter, a coaxial microcath-

eter system can be used. Coils are deployed until flow becomes sluggish. We were unable to achieve complete thrombosis in any of our patients at the time of the procedure; however, in all cases, thrombosis occurred by the time of surgery, 24 to 48 hours later. In retrospect, the large number of coils used in patients 1 and 2 was probably not necessary.

We encountered no complications related to the procedure, and we believe the risks are extremely low. Jugular bulb surgery has been performed for over 25 years and, when patency of the torcular and contralateral transverse sinus has been confirmed before surgery, we found no episodes of venous infarction as a complication reported (12). Although the small venous infarct in case 3 was thought to be related to surgery, this probably resulted from occlusion of a small unrecognized cortical vein that joined the transverse sinus through a small tentorial sinus (13) rather than from isolation of the jugular bulb. The inferior petrosal sinus has alternative pathways of drainage to the opposite side through its connections to the vertebral and suboccipital plexus. The anterior and posterior condylar veins connect with complex plexus that have many alternative routes of drainage. Additionally, any vessels that are embolized are destined to be occluded at the time of surgery anyway. There is a theoretical risk of injury to lower cranial nerves, but this is probably less than the risk incurred from packing at surgery.

In conclusion, anastomoses to the jugular bulb that traditionally cause significant back bleeding when the bulb is opened at surgery can be embolized before surgery with endovascular deployment of coils. The technique is straightforward and the risks are low. Benefits include decreased blood loss, reduced surgical time, and lessened risk of injury to the lower cranial nerves.

References

1. Kveton JF, Cooper MH. Microsurgical anatomy of the jugular foramen region. *Am J Otol* 1988;9:109–112
2. Saleh E, Naguib M, Cokkeser Y, et al. Lower skull base: anatomic study with surgical implications. *Ann Otol Rhinol Laryngol* 1995; 104:57–61
3. Graham MD. The jugular bulb: its anatomic and clinical considerations in contemporary otology. *Laryngoscope* 1977;87:105–125
4. Rhoton AL, Buza R. Microsurgical anatomy of the jugular foramen. *J Neurosurg* 1975;42:541–550
5. Shiu PC, Hanafee WN, Wilson GH, Rand RW. Cavernous sinus venography. *AJR Am J Roentgenol* 1968;57–62

6. Doppman JL, Krudy AG, Girton ME, Oldfield EH. Basilar venous plexus of the posterior fossa: a potential source of error in petrosal sinus sampling. *Radiology* 1985;155:375-378
7. Miller DA, Doppman JL. Petrosal sinus sampling: technique and rationale. *Radiology* 1991;178:37-47
8. Miller DA, Doppman JL, Chang R. Anatomy of the junction of the inferior petrosal sinus and the internal jugular vein. *AJNR Am J Neuroradiol* 1993;14:1075-1083
9. Braun JP, Tournade A. Venous drainage in the craniocervical region. *Neuroradiology* 1977;13:155-158
10. Theron J, Djindjal R. Cervicovertebral phlebography using catheterization. *Radiology* 1973;108:325-331
11. Gebarski SS, Gebarski KS. Inferior petrosal sinus: imaging-anatomic correlation. *Radiology* 1995;194:239-247
12. Brackman DE, Arriaga MA. Surgery for glomus tumors. In: Brackman DE, Shelton C, Arriaga MA, eds. *Otologic Surgery*. Philadelphia, Pa: Saunders; 1994:579-594
13. Okurdera T, Huagh YP, Ohta T, et al. Development of posterior fossa dural sinuses, emissary veins and jugular bulb: morphological and radiologic study. *AJNR Am J Neuroradiol* 1994;15:1871-1883