

Normal MR Appearance of the Pituitary Gland in the First 2 Years of Life

Rosalind B. Dietrich, Leon E. Lis, Fred S. Greensite, and Duane Pitt

PURPOSE: To investigate changes in the size, shape, and signal intensity of the pituitary gland during the first 2 years of life. **METHODS:** One hundred consecutive MR studies, spin-echo T1- and T2-weighted sequences, of children 0 to 2 years of age were analyzed. Signal intensity and shape of the gland were graded and its signal intensity measured. **RESULTS:** There was a statistically significant difference in the signal intensity of both the anterior and posterior pituitary gland and in the shape between children younger than and older than 6 weeks of age and younger than and older than 27 weeks of age. There were definite trends in the size of the gland with age (decrease in height and increase in anteroposterior diameter and width). **CONCLUSIONS:** There are changes in the pituitary gland in the newborn period that may reflect the ongoing changes in pituitary hormones reported to occur during this time.

Index terms: Pituitary gland, anatomy; Pituitary gland, magnetic resonance; Brain, growth and development; Pediatric neuroradiology

AJNR Am J Neuroradiol 16:1413–1419, August 1995

Dynamic changes occur in the size, shape, and signal intensity of the pituitary gland during life (1, 2). These changes reflect the complex hormonal environment of the pituitary gland and are most pronounced at times of hormonal flux such as menarche (3, 4) and pregnancy (5, 6). It has been noted previously that the magnetic resonance (MR) appearance of the pituitary gland of newborn infants differs from that of older children and adults (7–10). We have therefore performed a study to determine the changes that occur in the size and signal characteristics of the normal pituitary gland during the first 2 years of life.

Subjects and Methods

One hundred consecutive MR brain studies of 84 infants were reviewed. The ages of the infants ranged from 1 day

to 2 years (mean age, 32.8 weeks); 42 were girls, and 58 were boys. Of the 100 children, 89 were born at term (36 weeks or later), 11 at 36 weeks or earlier. Of these, 2 were born at 35 weeks, 4 at 34 weeks, 3 at 32 weeks, 1 at 29 weeks, and 1 at 28 weeks of gestation. A breakdown of the ages by sex and age is shown (Fig 1). The findings were considered normal in 29, abnormal in 71 (Fig 2). Abnormalities identified in these studies are as follows (some children had more than one abnormality):

Congenital anomalies	
Holoprosencephaly	2
Lissencephaly	2
Schizencephaly	3
Heterotopic gray matter	2
Chiari II malformation	7
Other	7
Acquired abnormalities	
Ischemia/infarction	8
Hemorrhage	7
Atrophy	10
Delayed myelination	6
Gliosis	2
Other	1
Hydrocephalus	9
Total	95

All children suspected of having pituitary disease, supra-sellar masses, or growth disturbances were excluded from the study.

Images were obtained on a 1.5-T scanner, and patients were imaged in three planes using a combination of T1-weighted (600/20/2) and T2-weighted (3000/120/1)

Received September 17, 1991; accepted after revision February 6, 1995.

From the Department of Radiological Sciences, University of California, Irvine, Orange.

Address reprint requests to Rosalind B. Dietrich, MB ChB, Department of Radiological Sciences, UCI Medical Center, 101 The City Dr, Orange, CA 92668.

AJNR 16:1413–1419, Aug 1995 0195-6108/95/1607–1413

© American Society of Neuroradiology

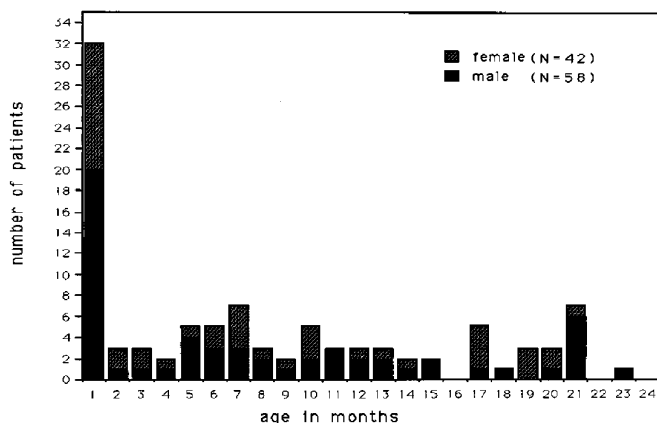


Fig 1. Age and sex distribution of patient population.

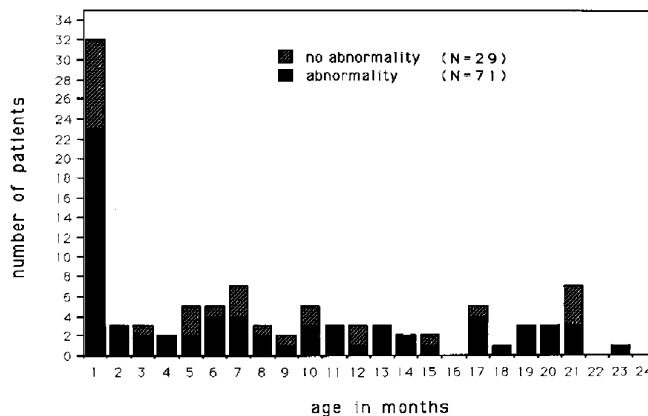


Fig 2. Distribution of normal and abnormal studies by age.

spin-echo images. T1-weighted sagittal images were obtained on all subjects. In addition, either axial T1-weighted and coronal T2-weighted or coronal T1-weighted and axial T2-weighted images also were obtained. T1-weighted sequences were obtained with a 3-mm section thickness and a 256×192 matrix, T2-weighted sequences using a 5-mm section thickness and a 256×192 matrix.

Evaluation of the Pituitary Gland

The pituitary gland images of the 100 children were evaluated by two of the authors (L.E.L., R.B.D.). The evaluations were carried out by the authors independently, with subsequent discussion, as necessary, to agree on the grade assigned to minimize observation variation (11). The readers graded all cases without prior knowledge of the age of the patient. Images were assessed according to the following criteria: (a) the signal intensities of the anterior and posterior portions of the gland as seen on the T1-weighted sagittal images were graded from 1 to 3: 1 being gray matter; 2, myelinated white matter in the posterior corpus callosum (in children older than 4 weeks) or higher than gray matter but lower than subcutaneous fat (in children younger than 4 weeks); and 3, subcutaneous fat; (b) the shape of the superior surface of the pituitary gland also was graded as convex, bimodal (giving the entire gland an hourglass configuration), flat, or concave; and (c) the dimensions of the pituitary gland were measured directly from the images. The anterior and posterior portions of the gland were not measured separately, because the small size of the gland and the relative isointensity of the two portions of the gland in a large number of infants precluded separate measurements of these structures. The T1-weighted sagittal sequence was used to measure both the anteroposterior diameter and the height. The width was measured from either axial or coronal images (Fig 3).

Statistical Analysis

For statistical analysis of signal, shape, and size with age variations, the patients were first divided into two groups: group A (0 to 26 weeks of age) consisted of the 50 youngest subjects, and group B (27 to 97 weeks of age) consisted of the 50 oldest subjects. Group A was subdivided into three subgroups of 17 subjects each: A1 (0 to 1.5 weeks), A2 (1.7 to 6 weeks), and A3 (6 to 27 weeks), and the youngest subject in group B (27 weeks) was added to group A3 so that there would be equal numbers in each subgroup. Group B was subdivided into two subgroups of 25 subjects each: B1 (27 to 55 weeks) and B2 (56 to 97 weeks). The χ^2 test was used to evaluate the significance of the differences in the distribution of the signal, shape, and size classes between different age groups. Spearman rank order correlation coefficients and their *P* values were computed for the means of pituitary dimensions (height, width, and anteroposterior length) versus each of the above age categories.

To determine whether gestational age at the time of birth affected the appearance of the pituitary gland, the Student's *t* test also was used to test for possible differences in pituitary parameters among subsets of different birth age (subjects born at 37 weeks gestational age or more, those born at 40 weeks or more, and all subjects without regard to gestational age at birth). Finally, because our patient population contained children with both normal and abnormal findings, the mean measurements for both groups of children were compared. Because group A1 contained only two normal studies, in this subgroup children with congenital anomalies were compared with those children without congenital anomalies.

Results

This study confirmed previous observations that there is a progressive change in the appearance of the pituitary gland during the first 2 years of life.

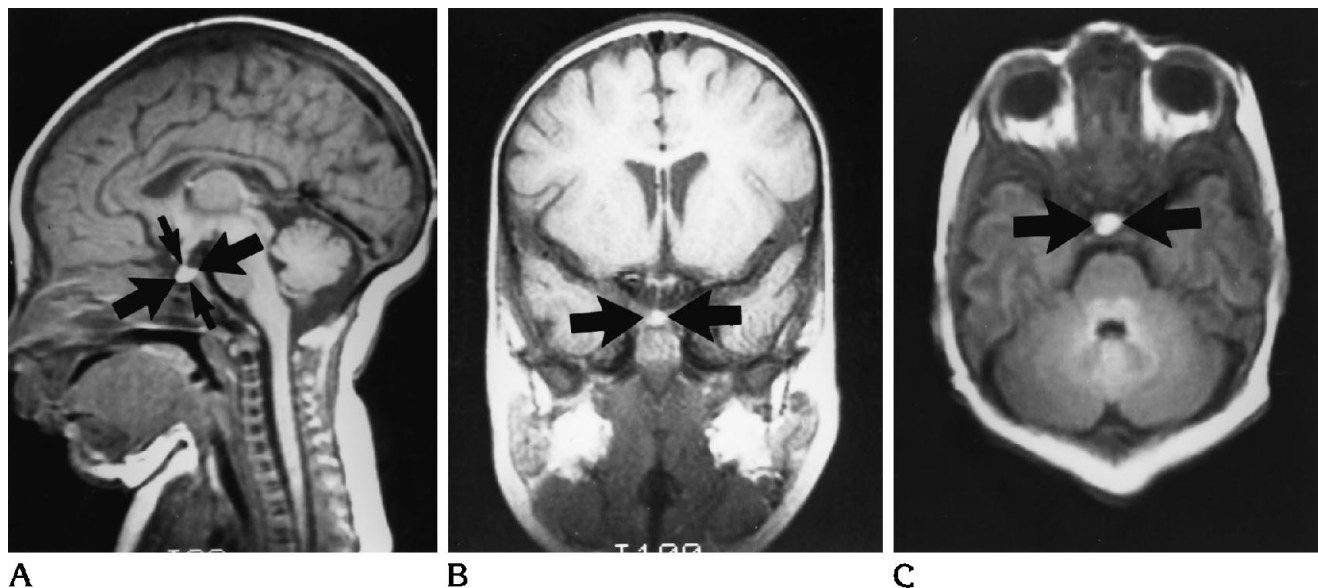


Fig 3. A, Sagittal (600/20); B, coronal (600/20); and C, axial (1500/700/30) MR images.

Signal Intensity

Correlation of the signal intensity of the anterior pituitary gland with age is shown in the Table. Before 6 weeks of age, no child demonstrated grade 1 signal intensity, 18% had grade 2, and 82% had grade 3. In children older than six weeks of age, the signal intensity was grade 1 in 52%, grade 2 in 43% and grade 3 in 4%. Figure 4 illustrates examples of the signal intensity grades assigned. There was a statistically significant difference between groups A and B (before and after 27 weeks of age [$P = .01$, $\chi^2 = 35.36$]) and between subgroups A1 + A2 together and subgroup A3 (before and after six weeks of age [$P < .01$, $\chi^2 = 20.11$]).

Correlation of the signal intensity of the posterior pituitary gland with age also is shown in the Table. The signal intensity of the posterior pituitary gland of children younger than 6 weeks of age was graded 2 in 3%, and 3 in 97%. In children older than 6 weeks of age, it was graded 1 in 7%, 2 in 55%, and 3 in 37%. Figure 4 illustrates examples of the shape categories assigned. Again noted was a statistically significant difference between groups A and B ($P < 0.01$, $\chi^2 = 25.50$), and between subgroups A1 + A2 and A3 ($P < 0.01$, $\chi^2 = 10.46$).

Shape

Correlation of pituitary shape with age is also shown in the Table. This demonstrates that all

the children younger than 6 weeks of age had a concave or bimodal superior surface of the pituitary gland. In children between 6 weeks and 2 years of age, the shape was graded as convex or bimodal in 46%, flat in 43%, and concave in 10%. There was a statistically significant difference in the shape of the pituitary gland between groups A and B ($P < 0.01$, $\chi^2 = 31.84$) and between subgroups A1 + A2 together and A3 (before and after 6 weeks of age [$P < .01$, $\chi^2 = 10.11$]).

Size

The Table lists the mean dimensions for each of the five age subgroups. Line graphs of these means (Fig 5) show a gradual but definite increase with age for both width and anteroposterior dimension of the pituitary gland and a decrease with age for height. However, if we also look at the standard deviations for these values, it becomes apparent that the large range in size does not allow any specific conclusions about age based on a simple measurement. Nevertheless, the trends in the mean of the size parameters were statistically significant for anteroposterior dimension and width. Although the changes seen in the height of the pituitary gland were not statistically significant, it can be seen that there is a gradual decrease in height with age.

Changes in signal intensity, shape, and size of the pituitary gland with age

Subgroup	Age	N	Anterior Pituitary Signal Grade			Posterior Pituitary Signal Grade			Shape			Measurements, mm			
			1	2	3	1	2	3	Convex	Hourglass	Flat	Concave	Mean Height (SD)	Mean Width (SD)	Mean Anteroposterior (SD)
A1	0.1-1.5 wk	17	0	2	15	0	1	16	1	0	0	0	4.12 (1.13)	8.41 (1.24)	6.79 (1.11)
A2	1.7-6 wk	17	0	4	13	0	17	15	2	0	0	0	3.94 (.64)	8.65 (1.13)	6.76 (1.16)
A3	6-27 wk	17	9	7	1	1	7	7	3	6	1	1	3.94 (1.20)	9.38 (1.22)	7.44 (1.12)
B1	27-55 wk	25	12	13	0	2	17	6	2	14	3	3	3.48 (1.17)	9.92 (.84)	7.84 (1.25)
B2	56-97 wk	25	14	9	2	2	13	10	8	9	3	3	3.72 (1.15)	10.08 (1.35)	8.16 (.92)

Note.—Grade 1 indicates gray matter; 2, myelinated white matter; and 3, subcutaneous fat.

Effect of Gestational Age at Birth on the Appearance of the Pituitary Gland

When the children were divided into three birth age subsets (all subjects, subjects born at 40 weeks and over, subjects born at 37 weeks and over) and their parameters compared using the Student's *t* test, the test failed to demonstrate any significant difference among the groups for any of the parameters analyzed.

Finally, when children within each subgroup were divided into subsets (normal versus abnormal in subgroups A2, A3, and B and congenital anomalies versus others in subgroup A1) and all the parameters again compared, there also was no significant difference between the subsets seen.

Discussion

This study demonstrates the range of appearances of the normal pituitary gland during the first 2 years of life. We have shown that both the anterior and posterior pituitary gland have high signal intensity on T1-weighted images at birth which, in the majority of patients, has decreased in intensity by about 6 weeks of age. Although our grading system for signal intensity of the anterior pituitary is subjective, we believe it is an accurate reflection of pituitary signal intensity. If computer-density measurements had been obtained, the small size of the infant pituitary gland would have been reflected in the sample areas measured. Fluctuations in the signal intensity of the posterior pituitary of adult patients have been described (12). In addition, the gland tends to be globular in shape at birth and becomes more flattened with age. This correlates with a trend toward decreasing height with age. However, the width and anteroposterior dimension tend to increase with age, consistent with overall growth of the child.

It is interesting to note that although there are differing views in the literature as to what type of tissue is responsible for the high signal intensity of the posterior pituitary gland of adults (13-18), several papers strongly support that its origin is from the neurosecretory granules or the protein neurophysin (13-15). A subsequent paper raises the possibility that the presence of phospholipid may be the cause of the high signal intensity seen in the posterior pituitary gland (17).

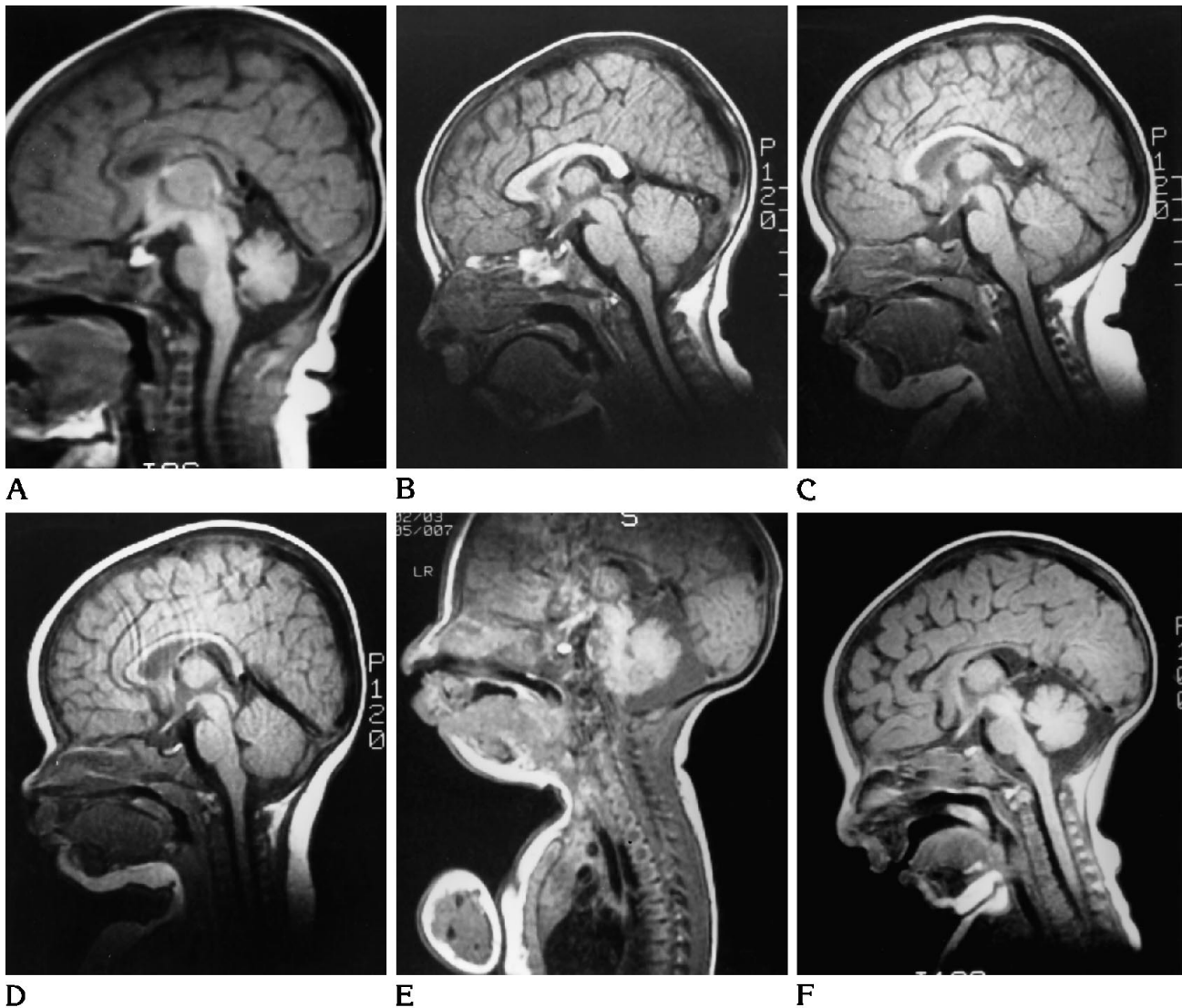


Fig 4. Grading criteria for the signal intensity and shape. Sagittal T1-weighted MR images (spin-echo 600/20) of the pituitary gland. A, Grade 3 anterior/grade 3 posterior pituitary gland with a convex superior surface. B, Grade 1 anterior/grade 3 posterior pituitary gland with a bimodal superior surface (hourglass-shape gland). C, Grade 1 anterior/grade 1 posterior pituitary gland with a flat upper surface. D, Grade 1 anterior/grade 3 posterior pituitary gland with a concave superior surface. E, At 8 days of age, grade 3 anterior/grade 3 posterior pituitary gland with a convex superior surface. F, At 6 weeks of age the pituitary gland demonstrates a grade 2 anterior/grade 3 posterior signal intensity and has a bimodal superior surface.

If we analyze the signal intensities of the anterior pituitary on the various pulse sequences, it is immediately clear that the water present in the anterior pituitary is not behaving as free water molecules. The water present that contributes to the signal is probably therefore bound in a protein hydration layer environment (19). Proteins are present in the anterior pituitary gland in the form of hormones and protein carrier molecules. It is most likely that the tran-

sient high signal seen in patients younger than 6 weeks of age comes from one of these.

It has been well documented in the pediatric endocrine literature that active pituitary hormone production begins early in fetal life and continues into the newborn period (20–23). This is necessary because maternal pituitary hormones do not cross the placenta (20). Knowledge of this development may help our understanding of the normal pituitary MR signal

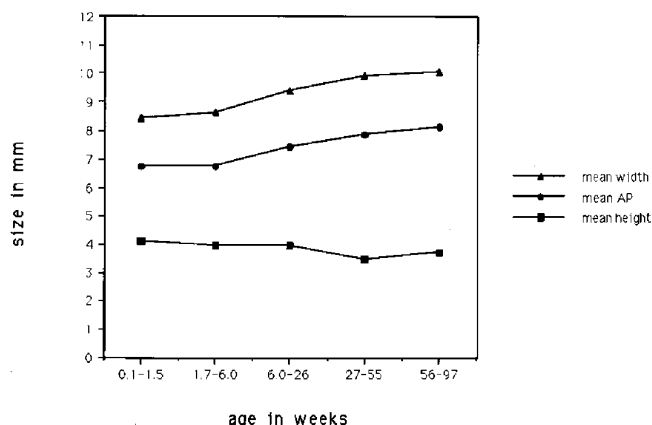


Fig 5. Pituitary size versus age. AP indicates anteroposterior dimension.

and its change with age. The anterior pituitary produces six hormones (growth hormone, prolactin, thyrotropin, luteotropic hormone [LH], follicle-stimulating hormone [FSH], corticotropin [ACTH]), which are either polypeptides or glycoproteins. The posterior pituitary stores and releases two oxy peptide hormones (oxytocin and vasopressin), which are associated with the transport of protein neurophysin. Histologic and immunocytochemical analyses of fetal pituitaries have shown aggregated changes in the relative number of various hormone-secreting cells as well as in the amount of a given hormone produced. Of particular relevance to our study is what occurs in the perinatal period when there is a rapid transient surge in the serum levels of several of the pituitary hormones. These levels then decrease to normal adult levels within several months. For example, prolactin cells, which make up approximately 40% of the adenohypophyseal population at birth, become hyperplastic in the last few weeks of gestation (20, 21). Concurrent with this, serum prolactin levels increase rapidly after 30 weeks' gestation and peak at term, returning to normal prepubertal levels at about 6 weeks of age (20, 21). In contrast, growth hormone levels peak at 20 to 24 weeks of gestation and have already declined to one fourth of their peak value at term; however, the birth level is still high relative to adult levels then declines, reaching adult values by 1 month of age (20, 21). Serum TFH levels surge at birth but decline to normal levels within a few days. Likewise, serum ACTH levels are high at birth and decrease by 1 week of age. In contrast, FSH and LH levels are low at birth but increase after about 2 weeks and peak at 1

month in boys, with a return to prepubertal levels by 4 months. In girls, the peak occurs at 3 months and then there is a gradual decline until 3 or 4 years of age (20, 21). The transient changes of the signal intensity of the infantile anterior pituitary therefore roughly parallel the hormonal changes occurring at this time.

Previous observers have noted transient changes in the shape or signal intensity of the pituitary gland at different stages of life, which also reflect concurrent changing hormonal levels. Observations of the pituitary gland during puberty have shown a definite but transient increase in size, attributed to the increased hormonal activity at this time; however, no obvious increase in signal has been documented (3, 4). Levels of pituitary hormones through puberty, although higher than adult levels, are much lower than those seen in the neonatal period. This may account for the change in size of the gland without significant change in signal intensity at this time.

It also has been documented that the pituitary gland also enlarges and may increase in signal intensity during pregnancy (5, 6), and changes in appearance of the gland during different phases of the menstrual cycle also have been shown (R. Shankwiler, M. E. Mawad, C. Valdes, K. Elkind-Hirsch, "Biphasic Morphological Changes of the Normal Menstrual Cycle Demonstrated on Gadolinium MRI," presented at the 29th Annual Meeting of the American Society of Neuroradiology, Washington, DC, June 13, 1991). It therefore appears that there is a strong link between the fluctuation in hormone levels and the changing appearances of the pituitary gland during life.

The transient high signal intensity seen in the newborn pituitary gland was seen with equal frequency and for the same time period in both premature and term infants. It therefore appears that this signal intensity change is related to time of birth (and the hormone surges that accompany it) rather than to the exact gestational age of the child. Similarly, children with precocious puberty may demonstrate changes in the gland paralleling those seen in healthy adolescents irrespective of their chronologic age (24).

Knowledge of the normal appearance of the pituitary gland in childhood also may have clinical application in the evaluation of children with possible pediatric endocrine abnormalities who may demonstrate an abnormal appearance of the gland for their age. For example, demon-

stration of a small, low-signal-intensity gland in an infant younger than 6 weeks of age may raise the possibility of panhypopituitarism. By contrast, in an older child with precocious puberty, an enlarged gland may be seen at a time when the gland should have a flat or concave appearance (24).

Although the relationship between the surge in adenyohypophyseal activity around the time of birth and the transient high signal in the anterior pituitary gland has not been definitively proved, it appears likely that the high signal is associated with an increased proportion of water in a protein hydration layer environment and that the two are related.

References

1. Elster AD. Modern imaging of the pituitary. *Radiology* 1993;187:1-14
2. Doraiswamy PM, Potts JM, Axelson DA, et al. MR assessment of pituitary gland morphology in healthy volunteers: age- and gender-related differences. *AJNR Am J Neuroradiol* 1992;13:1295-1299
3. Elster AD, Chen MYM, Williams DW, Key LL. Pituitary gland: MR imaging of physiologic hypertrophy in adolescence. *Radiology* 1990;174:681-685
4. Peyster RG, Hoover ED, Adler LP. CT of the normal pituitary stalk. *AJNR Am J Neuroradiol* 1984;5:45-47
5. Miki Y, Asato R, Okumura R, et al. Anterior pituitary gland in pregnancy: hyperintensity at MR. *Radiology* 1993;187:229-231
6. Elster AD, Sanders TG, Vines FS, Chen MYM. Size and shape of the pituitary gland during pregnancy and post partum: measurement with MR imaging. *Radiology* 1991;181:531-535
7. Wolpert SM, Osborne M, Anderson M, Runge VM. The bright pituitary gland: a normal MR appearance in infancy. *AJNR Am J Neuroradiol* 1988;9:1-3
8. Cox TD, Elster AD. Normal pituitary gland: changes in shape, size, and signal intensity during the first year of life at MR imaging. *Radiology* 1991;179:721-724
9. Tien RD, Kucharczyk J, Bessette J, et al. MR imaging of the pituitary gland in infants and children: changes in size, shape and MR signal with growth and development. *AJR Am J Roentgenol* 1992;158:1151-1154
10. Argyropoulou M, Perignon F, Brunelle F, et al. Height of normal pituitary gland as a function of age evaluated by magnetic resonance imaging in children. *Pediatr Radiol* 1991;21:247-249
11. Gilles FH, Winston K, Fulchiero A, Leviton A. Histologic features and observational variation in cerebellar gliomas in children. *J Natl Cancer Inst* 1977;58:175-181
12. Brooks BS, Gammal TE, Allison JD, Hoffman WH. Frequency and variation of the posterior pituitary bright signal on MR images. *AJNR Am J Neuroradiol* 1989;10:943-948
13. Nishimura K, Fujisawa I, Togashi K, et al. Posterior lobe of the pituitary: identification by lack of chemical shift artifact in MR imaging. *J Comput Assist Tomogr* 1986;10:899-902
14. Fujisawa I, Asato R, Nishimura K, et al. Anterior and posterior lobes of the pituitary gland: assessment by 1.5T MR imaging. *J Comput Assist Tomogr* 1987;11(2):214-220
15. Fujisawa I, Asato R, Kawata M, et al. Hyperintense signal of the posterior pituitary on T1-weighted MR images: an experimental study. *J Comput Assist Tomogr* 1989;13:371-377
16. Kucharczyk J, Kucharczyk W, Berry I, et al. Histochemical characterization and functional significance of the hyperintense signal on MR images of the posterior pituitary. *AJNR Am J Neuroradiol* 1988;9:1079-1083
17. Kucharczyk W, Lenkinski RE, Kucharczyk J, Henkelman RM. The effect of phospholipid vesicles on the NMR relaxation of water: an explanation for the MR appearance of the neurohypophysis. *AJNR Am J Neuroradiol* 1990;11:693-700
18. Mark L, Haughton V, Hendrix L, et al. High-intensity signals within the posterior pituitary fossa: a study with fat-suppression MR techniques. *AJNR Am J Neuroradiol* 1991;12:529-532
19. Fullerton GD. Physiologic basics of magnetic relaxation. In: Stark DD and Bradley WG Jr, eds *Magnetic Resonance Imaging*. St Louis: CV Mosby; 1988
20. Winter JSD. Hypothalamic-pituitary function in the fetus and infant. In: Bailey JD, ed. *Clinics of Endocrinology and Metabolism: Pediatric Endocrinology*. London: WB Saunders; 1982;11:41-55
21. Asa SL, Kovacs K. Functional morphology of the human fetal pituitary. In: Sommers SC, Rosen PP, eds. *Pathology Annual*. Norwalk, Conn: 1984;19:275-315
22. Asa SL, Kovacs K, Laszlo FA, Domokos I, Ezrin C. Human fetal adeno-hypophysis: histologic and immunocytochemical analysis. *Neuroendocrinology* 1986;43:308-316
23. Sizonenko PC. Post natal hormonal adaptation. *Acta Paediatr Jpn* 1988;30:139-145
24. Kao SCS, Cook JS, Hansen JR, et al. MR imaging of the pituitary gland in central precocious puberty. *Pediatr Radiol* 1992;22:481