
Methanol Intoxication with Putaminal and White Matter Necrosis: MR and CT Findings

David Rubinstein, Edward Escott, and James P. Kelly

Summary: We report a case of methanol intoxication in which the initial CT scans appeared normal. MR at 4 days showed the typical putaminal lesions of methanol intoxication and, in addition, peripheral white matter lesions that spared a thin rim of subcortical white matter. A CT scan at 17 days showed the putaminal and white matter lesions. The white matter lesions correspond well to lesions previously described in pathologic specimens.

Index terms: Brain, effect of toxic substances on; Brain, necrosis

Bilateral necrosis of the putamen is the most well known sequela of methanol intoxication that can be identified on computed tomography (CT) (1–9) and magnetic resonance (MR) imaging (10–14). Methanol can also produce separate necrotic lesions in the cerebral white matter (2, 7, 15), but these lesions are a less well recognized complication of methanol intoxication. Our patient had MR and CT scans that showed both putaminal necrosis and separate white matter lesions.

Case Report

A 36-year-old man who reportedly ingested an unknown amount of antifreeze was seen because of vertigo, blurred vision, memory loss, and weakness, followed by abdominal pain, nausea, and vomiting. His mental status deteriorated until he was comatose. He had metabolic acidosis (blood pH, 6.9) and was intubated. Initially, it was uncertain whether he had ethylene glycol poisoning from radiator antifreeze or methanol poisoning from gasoline antifreeze. Toxicology screening revealed a methanol level of 36 mg/dl. CT scans 1 and 2 days after ingestion of methanol appeared normal (Fig 1). On the third day he was still comatose and had a methanol level of 23 mg/dl; no ethylene glycol could be detected in the blood. He was treated with intravenous alcohol and hemodialysis. An MR image 4 days after ingestion of methanol showed lesions that were hyperintense on T2-weighted images of the putamina as well as in the peripheral white matter of the

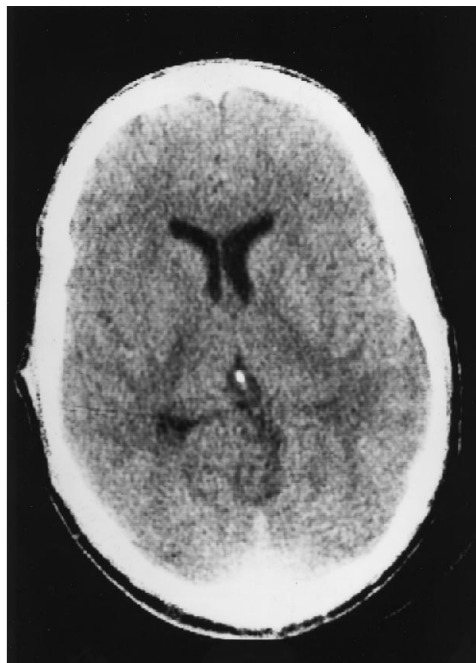


Fig 1. CT scan 1 day after ingestion of methanol does not show putaminal or white matter lesions.

cerebral hemispheres. These white matter changes were more prominent in the frontal and occipital lobes and spared a thin rim of subcortical white matter beneath (Fig 2). Several small cortical regions of T2-weighted hyperintensity were also demonstrated. Similar findings were seen in the cerebellum. A CT scan 2 weeks later showed hypodensity involving large areas of white matter and hypodensity in the putamina (Fig 3).

The patient remained comatose and died 25 days after admission. An autopsy was not performed.

Discussion

The clinical presentation of methanol intoxication can vary greatly from patient to patient. A latent period of 12 to 24 hours often follows

Received February 16, 1994; accepted after revision August 15.

From the Department of Radiology, University of Colorado Health Sciences, Denver.

Address reprint requests to David Rubinstein, MD, Department of Radiology, University of Colorado Health Sciences, 4200 E Ninth Ave, Campus Box A-034, Denver, CO 80262.

AJNR 16:1492–1494, Aug 1995 0195-6108/95/1607–1492 © American Society of Neuroradiology

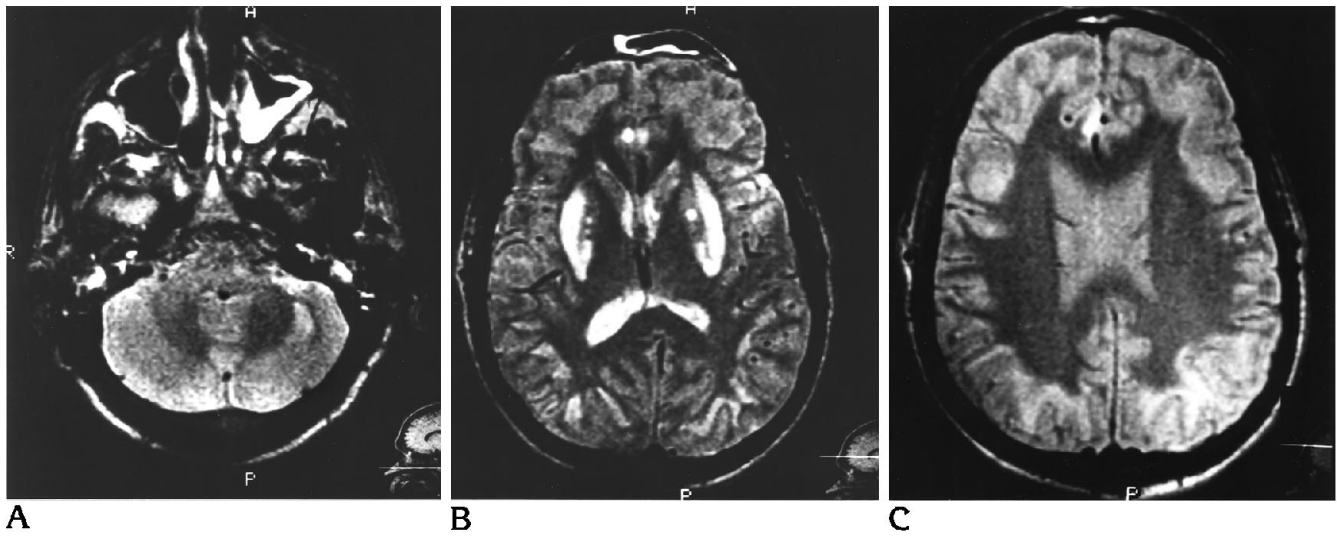


Fig 2. Hyperintense lesions on T2-weighted (A and B) and proton density-weighted (C) MR images 4 days after ingestion involve the putamina and peripheral cerebral and cerebellar white matter. The white matter lesions spare a thin rim of subcortical white matter. Smaller lesions involve the cingulate gyri and head of the left caudate nucleus.

methanol ingestion, and most patients note visual disturbances as one of the first symptoms. The latent period most likely corresponds to the time period in which methyl alcohol is metabolized into formaldehyde and formic acid, two chemicals more toxic than methanol (16). Central nervous system symptoms are common and include headache, dizziness, feelings of weakness, and malaise. Larger amounts of methanol ingestion can result in seizure, stupor, and coma. In addition to the central nervous system and ocular symptoms, gastrointestinal complaints are common (16).

The most characteristic pathologic findings after methanol intoxication are discrete regions

of necrosis involving the putamina, which may have varying degrees of hemorrhage. These characteristic changes can be seen if the patient survives for longer than 24 hours (17). Discrete regions of necrosis have also been described in the white matter of patients surviving longer than several days. These lesions spare the most peripheral white matter, the subcortical association fibers (2, 15). The bilateral putaminal necrosis or hemorrhage from methanol intoxication can be identified with CT (1-9) or MR (10-14). In addition to the putaminal lesions, separate lesions within the cerebral white matter have been identified with CT (2, 7).

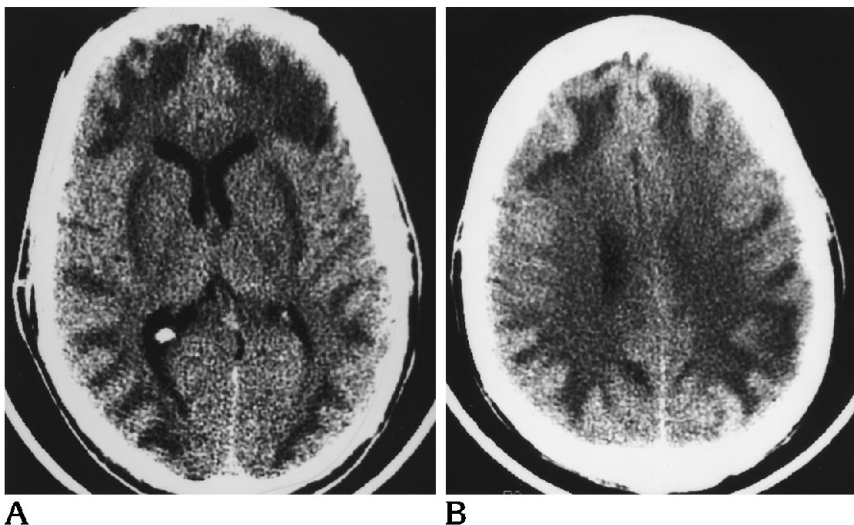


Fig 3. A, CT scan at the level of the basal ganglia 17 days after methanol ingestion shows mainly peripheral white matter lesions and hypodensities that might be located in either the putamina or external capsules.

B, A more superior section through the most superior portion of the right lateral ventricle shows discrete low-density lesions in the peripheral white matter with less discrete extension into the deeper white matter.

The MR images of our patient showed separate white matter lesions in the cerebral and cerebellar hemispheres that left a thin rim of normal white matter adjacent to the cortex (Fig 2). The peripheral nature of the white matter lesions and the sparing of a rim of the most peripheral white matter corresponds well to the previously reported pathologic findings (2, 15).

The CT scan 2 weeks later did show the white matter and putaminal lesions, but localization of the lesions was less precise than on the MR image (Fig 3). Sparing of a rim of white matter could not be seen on the CT scan, and the location of the putaminal lesions was more difficult to determine and could have been placed in the external capsule if the CT scan alone were used.

Although the later CT scan showed lesions typical for methanol intoxication, the initial CT scans appeared normal (Fig 1). In two other reported cases, CT scans on the first day appeared normal but later showed putaminal necrosis (5, 9). Two other reports, however, described findings on CT scans obtained within the first 3 days (3, 8).

The findings of peripheral white matter and putaminal lesions can also occur in Wilson disease (hepatolenticular degeneration) (18) or in Leigh disease (subacute necrotizing encephalomyelopathy) (19). In the proper clinical setting, however, methanol poisoning should be suspected when these findings are seen on CT or MR.

References

1. Aquilonius SM, Askmark H, Enoksson P, Lundberg PO, Mostrom U. Computerized tomography in severe methanol intoxication. *BMJ* 1978;2:929-930
2. McLean DR, Jacobs H, Mielke BW. Methanol poisoning: a clinical and pathological study. *Ann Neurol* 1980;8:161-167
3. Aquilonius SM, Bergstrom K, Enoksson P, et al. Cerebral computed tomography in methanol intoxication. *J Comput Assist Tomogr* 1980;4:425-428
4. Ley CO, Gali FG. Parkinsonian syndrome after methanol intoxication. *Eur Neurol* 1983;22:405-409
5. Bourrat C, Riboullard L, Flocard F, Chalumeau A, Guillaume C. Intoxication volontaire par le methanol encephalopathie severe et regressive avec anomalies au scanner x. *Rev Neurol (Paris)* 1986;142:530-534
6. Friedman L, O'Keeffe D, Patel M, Tchang S. Computed tomography findings in methanol intoxication. *S Afr Med J* 1987;71:800
7. Anderson TJ, Shuaib A, Becker WJ. Neurologic sequelae of methanol poisoning. *Can Med Assoc J* 1987;136:1177-1179
8. Phang P, Passerini L, Mielke B, Berendt R, King EG. Brain hemorrhage associated with methanol poisoning. *Crit Care Med* 1988;16:137-140
9. LeWitt PA, Martin SD. Brief report: dystonia and hypokinesia with putaminal necrosis after methanol intoxication. *Clin Neuropharmacol* 1988;11:161-167
10. Koopmans RA, Li DKB, Paty DW. Basal ganglia lesions in methanol poisoning: MR appearance. *J Comput Assist Tomogr* 1988;12:168-170
11. Bartoli JM, Laurent C, Moulin G, et al. Intoxication au methanol: a propos de deux observations explorees par tomographie et imagerie par resonance magnetique. *Ann Radiol (Paris)* 1990;33:257-259
12. Chen JC, Schneiderman JF, Wortzman G. Case report: methanol poisoning: bilateral putaminal and cerebellar cortical lesions on CT and MR. *J Comput Assist Tomogr* 1991;15:522-524
13. Pelletier J, Habib MH, Khalil R, Salamon G, Bartoli D, Jean P. Putaminal necrosis after methanol intoxication. *J Neurol Neurosurg Psychiatry* 1992;55:234-235
14. Glazer M, Dross P. Necrosis of the putamen caused by methanol intoxication: MR findings. *AJR Am J Roentgenol* 1993;160:1105-1106
15. Orthner H. Methylalkoholvergiftung mit besonders schweren Hirnveränderungen. *Virchows Arch A* 1953;323:442-464
16. Schneck SA. Methyl alcohol. In: Vinken PJ, Bruyn GW, eds. *Handbook of Clinical Neurology*. Amsterdam: North-Holland, 1989;37:351-360
17. Orthner H. *Die Methylalkohol Vergiftung*. Berlin: Springer-Verlag, 1950
18. Starosta-Rubinstein S, Young AB, Kluin K, et al. Clinical assessment of 31 patients with Wilson's disease: correlations with structural changes on magnetic resonance imaging. *Arch Neurol* 1987;44:365-370
19. Medina L, Chi TL, DeVivo DC, Hilal SK. MR findings in patients with subacute necrotizing encephalomyelopathy (Leigh syndrome): correlation and biochemical defect. *AJNR Am J Neuroradiol* 1990;11:379-384