
Bilateral Occipital Calcification Associated with Celiac Disease, Folate Deficiency, and Epilepsy

M. E. Lea, M. Harbord, and M. R. Sage

Summary: In a patient with celiac disease, folate and iron deficiency, and epilepsy, CT over a 4-month period showed parietooccipital calcifications in the corticomedullary junctions. The calcification was progressive, but it and the seizures stabilized after institution of a gluten-free diet and iron and folic acid supplements.

Index terms: Brain, calcification; Iron; Seizures; Metabolic disorder

Recent reports in the pediatric and neurologic literature have described an association between occipital calcification, similar to that seen in Sturge-Weber syndrome, and epilepsy in patients with celiac disease and folate acid deficiency. We report one case to illustrate this association and the differential diagnosis. The calcification is progressive but can be stabilized by institution of appropriate therapy.

Case History

A 4-year-old girl presented in September 1992 with a history of a 12-minute focal seizure involving the left arm and leg, associated with a febrile illness. There were no residual clinical signs. A computed tomography (CT) scan of the brain (Fig 1A) showed slight hyperdensity in the right parietal region. There was no enhancement with contrast. This was interpreted as hemorrhage, but a subsequent magnetic resonance image was normal. Anticonvulsant therapy with carbamazepine was commenced.

Four months later, the child presented with a second left-sided focal seizure lasting 30 minutes, without a fever on this occasion. There was a transient postictal left hemiparesis, which had resolved completely after 48 hours. Electroencephalogram showed focal slow waves in the right parietal region. CT scan of the brain (Figs 1B and C) now demonstrated well-defined, bilateral hyperdensity at the parietooccipital corticomedullary junctions, right greater than left. Magnetic resonance at this time (Fig 1D)

showed only a faint line of hypointensity at the corticomedullary junction in both parietal areas, supporting the revised CT diagnosis of calcification.

General examination revealed height and weight on the 30th percentile, normal developmental milestones, and no stigmata of Sturge-Weber syndrome or of other phakomatoses. Historical inquiry revealed a poor appetite, constipation, and a fondness for eating gravel, despite otherwise reasonable general health. There was no history of methotrexate therapy, radiotherapy, or other conditions associated with cerebral calcification.

Plain x-ray films of the abdomen showed gravel in the stomach. Laboratory investigations revealed a microcytic anemia, iron and folate deficiencies (hemoglobin, 7.6 g/dL [normal range, 11.6 to 13.6]; serum iron, 2 $\mu\text{mol/L}$ [normal, 8 to 30 $\mu\text{mol/L}$]; transferrin, 2.6 g/L [normal, 1.9 to 3.0 g/L]; saturation, 3% [normal, 20% to 50%]; and red cell folate, 195 nmol/L [normal, more than 362 nmol/L]). Serum glucose; liver enzymes; electrolytes; vitamins B12, A, and E; and immunoglobulins were normal. However, serum antigliadin antibodies were highly positive for both IgG and IgA. This strongly suggested the diagnosis of celiac disease, which was confirmed by duodenal biopsies showing subtotal villous atrophy and a marked plasma cell infiltrate, returning to normal after appropriate therapy. After treatment with a gluten-free diet and iron and folic acid supplements, there was a significant improvement in seizure control, with no further seizures on reduced doses of carbamazepine to date. A follow-up CT scan in May 1994 demonstrated no change in the extent of the cerebral calcifications.

Discussion

There are numerous causes of intracerebral calcification in children (1), but the differential diagnosis of parietooccipital, cortical, or subcortical calcification is limited. It includes Sturge-Weber syndrome and some atypical forms of other phakomatoses (2, 3), intrathecal methotrexate and central nervous system irra-

Received July 7, 1994; accepted after revision November 9.

From the Departments of Radiology (M.E.L., M.R.S.) and Pediatrics (M.H.), Flinders Medical Centre, Bedford Park, South Australia, Australia.

Address reprint requests to Dr M. Harbord, Department of Paediatrics, Flinders Medical Centre, Flinders Drive, Bedford Park, South Australia 5042, Australia.

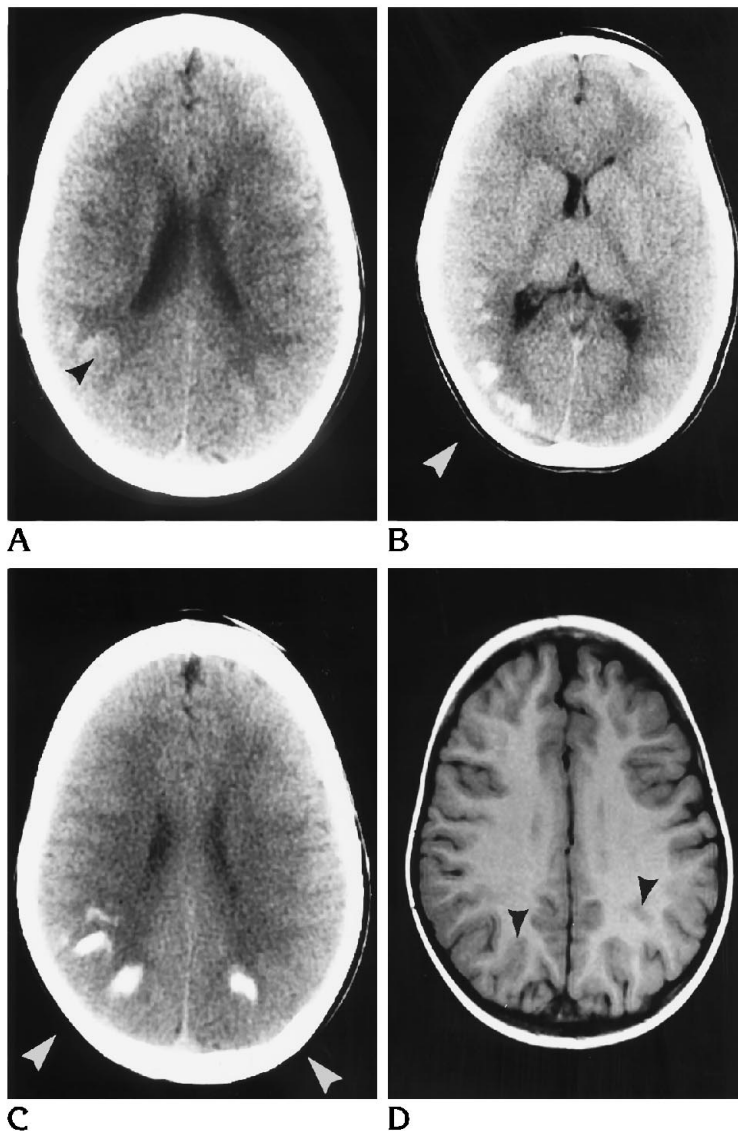


Fig 1. A, CT scan on initial presentation shows faint hyperdensity at the corticomedullary junction in the right parietal region (*arrowhead*).

B and C, CT after second convulsion, 4 months after the first. There is now well-defined calcification in both parietooccipital regions (*arrowheads*).

D, Magnetic resonance image taken soon after the CT in B and C. There is only minimal evidence of hypointensity at the corticomedullary junction (*arrowheads*).

diation in childhood leukemia (4–7), congenital folate malabsorption (8), and celiac disease (7, 9–13).

The case we describe could be differentiated from Sturge-Weber syndrome by the site of calcification at the gray-white matter interface rather than in the cortex itself. Furthermore, there were no other typical features of Sturge-Weber syndrome such as cortical atrophy, ipsilateral choroid plexus enlargement, or abnormal deep cerebral veins (9).

A definite association between epilepsy and celiac disease has been recognized since the late 1970s (14). Several anecdotal reports of epilepsy in children shown to have celiac disease and parietooccipital calcification (7, 11–13) recently prompted a larger study by an Ital-

ian group involving 43 patients (9). The association of epilepsy, celiac disease, and parietooccipital calcifications was found in 29 of the 43 patients (24 of 31 with epilepsy and cerebral calcification of unknown origin and biopsy-proved celiac disease; 5 of 12 with celiac disease and epilepsy had cerebral calcifications on CT scanning). In a number of these patients, celiac disease was diagnosed only after the onset of epilepsy and discovery of cerebral calcifications, although often there were clues to the presence of malabsorption in the history. It should be noted that some of the reported cases of “atypical Sturge-Weber syndrome” (ie, typical calcification without facial nevus) and other unexplained concurrences of epilepsy and calcifications, with or without folate deficiency (2–

8,13–19), in fact may be undiagnosed cases of celiac disease, as the Italian workers suggest.

The cause of epilepsy and cerebral calcification in celiac disease is uncertain but is thought to be related to the reduced central nervous system folate levels secondary to folate malabsorption (7, 9). Central nervous system folate deficiency also appears to be related to the cerebral calcification seen in childhood leukemia treated with central nervous system irradiation and intrathecal methotrexate (a folate antagonist) (1, 7, 9), as well as in cases of congenital folate malabsorption (8), both of which may be accompanied by epilepsy and other neurologic abnormalities. The actual pathologic process by which low folate levels cause cerebral calcification has not yet been determined (9).

The epilepsy associated with this type of calcification (usually focal or complex partial seizures) can be difficult to treat (9). However, in some of the cases in the literature about celiac disease, seizure control was improved after institution of a gluten-free diet with folic acid supplements (9, 11, 12), which also seems to have occurred in our case. The success of the diet in improving control of epilepsy appears to be potentiated by its institution soon after the onset of the epilepsy and at an early age (9). The natural history of the cerebral calcification after treatment of celiac disease is not well documented. Follow-up to date in our case has demonstrated an increase in calcification until institution of a gluten-free diet (thus restoring normal folate absorption) and static calcification after this; a similar pattern was observed in one case in the literature (7).

In conclusion, we have presented a case of a child with bilateral parietooccipital calcifications associated with celiac disease, folate deficiency, and epilepsy, illustrating a recently confirmed association. The radiologist should be aware of this association because the calcification may be the first clue to the presence of celiac disease, the prompt treatment of which maximizes the likelihood of seizure control.

References

1. Kendall B, Cavanagh N. Intracranial calcification in pediatric computed tomography. *Neuroradiology* 1986;28:324–330
2. Vogue M, Pasquini U, Salvolini U. CT findings of atypical forms of phakomatosis. *Neuroradiology* 1980;20:99–101
3. Wilms G, Van Wijck E, Demaerel P, Smet M-H, Plets C, Brucher JM. Gyriiform calcifications in tuberous sclerosis simulating the appearances of Sturge-Weber disease. *AJNR Am J Neuroradiol* 1992;13:295–298
4. McIntosh S, Fischer D, Rothman SG, Rosenfield N, Lobel JS, O'Brien RT. Intracranial calcifications in childhood leukemia: an association with systemic chemotherapy. *J Pediatr* 1977;91:909–913
5. Young LW, Jequier S, O'Gorman AM. Radiological case of the month: intracerebral calcifications in treated leukemia in a child. *Am J Dis Child* 1977;131:1283–1284
6. Borns TF, Rancier LF. Cerebral calcification in childhood leukemia mimicking Sturge-Weber syndrome: report of two cases. *AJNR Am J Roentgenol* 1974;122:52–55
7. Garwicz S, Mortensson W. Intracranial calcification mimicking the Sturge-Weber syndrome: a consequence of cerebral folic acid deficiency? *Pediatr Radiol* 1976;5:5–9
8. Corbeel L, Van den Bergh G, Jaeken N, Van Tornout J, Eeckels R. Congenital folate malabsorption. *Eur J Pediatr* 1985;143:284–290
9. Gobbi G, Bouquet F, Greco L, et al. Coeliac disease, epilepsy and cerebral calcifications. *Lancet* 1992;340:439–443
10. Crosato F, Senter S. Cerebral occipital calcifications in celiac disease. *Neuropaediatrics* 1992;23:214–217
11. Ventura A, Bouquet F, Sartorelli C, Barbi E, Torre G, Tommasini G. Celiac disease, folic acid deficiency and epilepsy with cerebral calcification. *Acta Paediatr Scand* 1991;80:559–562
12. Molteni N, Bardella NT, Valdassarri AR, Bianchi TA. Celiac disease associated with epilepsy and intracranial calcifications: report of two patients. *Am J Gastroenterol* 1988;83:992–994
13. Sammaritano N, Andermann F, Melanson D, Guberman A, Tinuper P, Gastaut H. The syndrome of intractable epilepsy, bilateral occipital calcifications, and folic acid deficiency. *Neurology* 1988;38(Suppl 1):239
14. Chapman RWG, Laidlow JM, Collin-Jones D, Eade OE, Smith CL. Increased prevalence of epilepsy in celiac disease. *Br Med J* 1978;2:250–251
15. Taly AB, Nagaraja D, Das S, Shankar SK, Pratibha MG. Sturge-Weber-Dimitri disease without facial nevus. *Neurology* 1987;37:1063–1064
16. Ambrosetto P, Ambrosetto G, Michelucci R, Bacci A. Sturge-Weber syndrome without port-wine facial nevus: report of two cases studied by CT. *Child Brain* 1983;10:387–392
17. Gobbi G, Sorrenti G, Santucci M, et al. Epilepsy with bilateral occipital calcifications: a benign onset with progressive severity. *Neurology* 1988;38:913–920
18. Del Giudice E, Pelosi L, Romano A, et al. Unexplained bilateral occipital calcification and reduced vision. *Neuropediatrics* 1984;15:218–219
19. Sammaritano N, Andermann F, Melanson D, Guberman A, Tinuper P, Gastaut H. The syndrome of epilepsy and bilateral occipital cortical calcifications. *Epilepsia* 1985;26:532