
The Dural Tail Sign Revisited

Eric C. Bourekas, Philip Wildenhain, Jonathan S. Lewin, Robert W. Tarr, Khurshed J. Dastur, M. Reza Raji, and Charles F. Lanzieri

Summary: We present three cases, a primary dural lymphoma, a syphilitic gumma, and an aggressive papillary middle-ear tumor, that exhibit dural enhancement adjacent to extraaxial masses on gadopentetate dimeglumine-enhanced MR, confirming the non-specific nature of the “dural tail sign.”

Index terms: Meninges, magnetic resonance; Meninges, neoplasms

The “dural tail sign” was described by Wilms and colleagues as a thin, tapering rim of dural enhancement, in continuity with a convexity meningioma on gadopentetate dimeglumine-enhanced magnetic resonance (MR) (1). Goldsher and associates subsequently, in 1990, demonstrated the dural tail sign in 60% of their series of meningiomas and concluded that its presence, associated with an extraaxial mass, was very specific for meningioma (2). The dural tail sign more recently has been described in patients having chloroma, lymphoma, sarcoidosis (3), acoustic neuroma (4), and metastatic tumors (5). We report three cases demonstrating the dural tail sign. The first is a case of primary central nervous system lymphoma of the dura mater in an immunocompetent young woman. The second case is a syphilitic gumma involving the dura mater. The third case is that of an aggressive papillary middle-ear tumor extending intracranially.

Case 1

A 31-year-old woman with a long history of migraine headaches presented with severe right frontal headache, worse than her normal migraines. On physical examination, the fundi showed questionable early papilledema, left greater than right. A slight increase in deep tendon reflexes was noted, left greater than right. MR examination showed a large, extraaxial mass in the right frontal region with compression and edema of the underlying parenchyma.

The mass was hypointense on T1-weighted images (750/20/1 [repetition time/echo time/excitations]) relative to cerebral white matter and slightly hyperintense on T2-weighted images (2800/80/0.75) relative to cerebral white matter, and showed marked uniform enhancement with an enhanced dural tail after gadopentetate dimeglumine infusion on T1-weighted (450/20/1) images (Fig 1). At surgery, the tumor primarily involved the dura and was adherent to the overlying bone. It was invading the underlying leptomeninges and brain parenchyma. Histologic examination revealed non-Hodgkin lymphoma, intermediate grade, diffuse small cleaved cell type. Further work-up including computed tomography (CT) of the chest, abdomen, and pelvis; bone scan; and iliac crest bone marrow aspiration revealed no evidence of systemic lymphoma, and the patient was human immunodeficiency virus-negative and not immunocompromised.

Case 2

A 40-year-old man presented with a right-sided headache and left facial twitching. On exam, the patient was obviously intoxicated. He was somnolent but arousable and oriented to name and place. Speech was slightly dysarthric. A left-central paresis was noted in the distribution of the seventh cranial nerve. Hearing was decreased on the left. A left Hoffman's sign was present. MR of the brain showed decreased signal in the region of the right sylvian fissure on T1-weighted images (576/14/2) and increased signal on T2-weighted images (2500/90/1). After gadolinium administration, there was intense enhancement of a 1.3-cm mass, with a small dural tail and with surrounding edema (Fig 2). At surgery, a dura-based lesion was noted. Histologic examination revealed a syphilitic gumma.

Case 3

A 47-year-old woman presented with a slowly progressive left facial weakness, double vision, hoarseness, and an irritating sensation of the left eye. Physical examination revealed a left horizontal gaze with no evidence of nystagmus. There was decreased sensation on the left in the distribution of the fifth cranial nerve, especially V-2, with

Received July 1, 1994; accepted after revision November 8.

From the Department of Radiology, University Hospitals of Cleveland (Ohio), Case Western Reserve University (E.C.B., J.S.L., R.W.T., C.F.L.); the Department of Radiology, Washington (Pa) Hospital (P.W.); and the Department of Radiology, Mercy Hospital of Pittsburgh (Pa) (K.J.D., M.M.R.).

Address reprint requests to Eric C. Bourekas, MD, Department of Radiology, Mt Sinai Medical Center, 1 Mt Sinai Dr, Cleveland, OH 44106-4198.

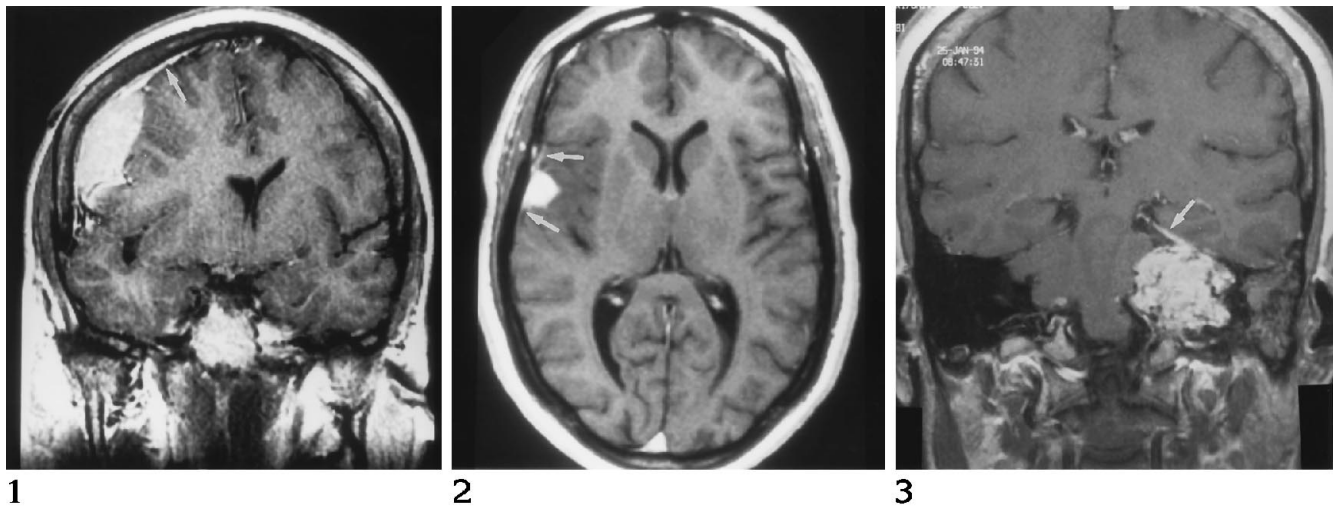


Fig 1. Coronal T1-weighted (450/20/1) image after the administration of gadopentetate dimeglumine shows intense, uniform enhancement of a large, extraaxial mass lesion in the right frontal region, with an associated dural tail (*arrow*). The mass proved to be a primary central nervous system lymphoma of the dura.

Fig 2. Enhanced axial T1-weighted (576/14/2) image shows intense enhancement of a 1.3-cm mass in the region of the right sylvian fissure, with enhancement of the adjacent dura (*arrows*). This is surgically proved syphilitic gumma.

Fig 3. Coronal T1-weighted (736/14/2) image after gadopentetate dimeglumine administration reveals a large, homogeneously enhancing mass lesion of the petrous bone, which is deforming the brain stem and extending intracranially. Extensive enhancement of the adjacent dura is noted (*arrow*). Biopsy revealed an aggressive papillary middle ear tumor.

decreased corneal reflex. A left upper and lower facial weakness was present. Hearing was decreased on the left, and there was a decreased gag reflex. MR examination revealed a 5.5 × 3.5 × 3.5-cm, irregularly shaped mass lesion, primarily involving the retrolabyrinthine portion of the petrous bone and extending to involve the left aspect of the clivus. It extended to the left cavernous sinus medially as well as the cochlea and semicircular canals laterally. There was intracranial extension, with compression of the pons, middle cerebellar peduncle, and cerebellum. The mass was isotense to brain parenchyma on T1-weighted images (500/14/3), with multiple small internal areas of increased and decreased signal, and was of somewhat heterogeneous increased signal on T2-weighted images (2050/90/1). After gadolinium administration, there was relatively intense enhancement, with a prominent dural tail and multiple small areas of heterogeneity (Fig 3). A biopsy of the lesion was performed via the middle ear and revealed an aggressive papillary middle ear tumor.

Discussion

The dural tail represents enhancement of thickened dura, adjacent to and tapering away from a dura-based lesion, on MR imaging. Aoki et al used the following criteria: (a) linearly enhanced areas along the dura originating from and extending outward from the tumor margin; (b) linear enhancement greater than similar regions contralaterally or greater than the distant dura when midline structures were involved;

and (c) findings observed in two different planes (6). Goldsher et al adopted three criteria for the definition of a dural tail: (a) presence on at least two consecutive sections through the tumor at the same site and in more than one plane; (b) greatest thickness adjacent to the tumor and tapering away from it; and (c) enhancement greater than that of the tumor mass itself (2).

The dural tail was described in 1989 by Wilms et al as thickening of dura surrounding meningiomas (1). In 1990, two reports showed that the sign was present in 60% to 72% of meningiomas (2, 6). Goldsher et al stated that the dural tail was never associated with other extraaxial tumors, such as neuromas, superficial gliomas, and metastases, suggesting that it was very specific for meningioma. After this, Aoki et al postulated that other disorders may exhibit the sign, such as tumors originating from meninges (sarcomas, dural metastases, and extracerebral extension of aggressive gliomas) and nonneoplastic disorders that produce meningeal irritation, such as abscesses. Since then, there have been reports of dural tails with metastatic tumors (5), chloroma, lymphoma, and sarcoid (3), as well as acoustic neuromas (4).

The tail was initially thought to result from invasion of the dura from the tumor (2), but Tokumaru et al (7) showed that the enhance-

ment was not necessarily the result of tumor invasion. In two of his four cases, there was no evidence of tumor invasion, and in the other two, there was neoplastic invasion but only at the immediate junction of the tumor and dura, with maximal extension within 1 mm of the tumor margin. Histologic examination revealed reactive changes, such as increased loose connective tissue, hypervascularity, and dilated vessels (7). Goldsher et al (2) had three cases evaluated histologically, and all showed tumor nodules within the enhanced areas on MR. Thus it appears that the dural tail may be caused by either direct tumor invasion or reactive changes of connective tissue and vessels adjacent to the dura-based tumor.

Why all dura-based lesions do not cause a dural tail and why the three lesions presented in our report did is up for speculation. The common element of all these lesions is that they are associated with the dura, whether primarily dura-based or secondarily extending to the dura. Lymphomas in general tend to be infiltrative and tend to incite little adjacent reaction and edema. One would presume that the dural tail in this case would be the result of direct tumor infiltration. Cerebral gummas are mass lesions of inflammatory granulomatous tissue, so one would hypothesize that the dural tail is caused by reactive changes of the adjacent connective tissue and by hypervascularity. Our third case, an aggressive papillary middle-ear tumor, is an aggressive and destructive lesion of the petrous apex, which arises from the endolymphatic sac and frequently extends in-

tracranially. The dural tail in this case may represent actual tumor invasion along the dura, given the aggressiveness of the lesion.

In conclusion, these three cases extend the list of dural lesions that may give rise to the dural tail sign and further strengthen the contention that this sign is nonspecific and may be seen with many dural lesions in addition to meningioma.

Acknowledgment

We thank Valerie Chiappone for her word processing assistance.

References

1. Wilms G, Lammens M, Marchal G, et al. Thickening of dura surrounding meningiomas: MR features. *J Comput Assist Tomogr* 1989;13:763-769
2. Goldsher D, Litt AW, Pinto RS, et al. Dural "tail" associated with meningiomas on Gd-DTPA-enhanced MR images: characteristics differential diagnosis value, and possible implications for treatment. *Radiology* 1990;176:447-450
3. Tien RD, Yang PJ, Chu PK. "Dural tail sign": a specific MR sign from meningioma? *J Comput Assist Tomogr* 1991;15(1):64-66
4. Kutcher T, Brown DC, Maurer PK, et al. Dural tail adjacent to acoustic neuroma: MR features. *J Comput Assist Tomogr* 1991; 15(4):669-670
5. Senegor M. Prominent meningeal "tail sign" in a patient with a metastatic tumor. *Neurosurgery* 1991;29(2):294-296
6. Aoki S, Sasaki Y, Machida T, Tanioka H. Contrast-enhanced MR images in patients with meningioma: importance of enhancement of the dura adjacent to tumor. *AJNR Am J Neuroradiol* 1990;11: 935-938
7. Tokumaro A, Toshihiro O, Tsuneyoshi E, et al. Prominent meningeal enhancement adjacent to meningioma on Gd-DTPA-enhanced MR images: histopathologic correlation. *Radiology* 1990; 175:431-433