
Hepatoerythropoietic Porphyria: Neuroimaging Findings

Juan Berenguer, Jordi Blasco, Carlos Cardenal, Teresa Pujol, M. J. Cruces Prado, Carmen Herrero, José M. Mascaró, C. de la Torre, and José M. Mercader

Summary: CT and MR findings in two patients with hepatoerythropoietic porphyria are presented. CT scans showed atrophy and cortical mineralization at the same level. MR examination performed in one of the two patients showed mainly frontal cortical atrophy and punctate bright signal on T1- and T2-weighted sequences.

Index terms: Brain, metabolism; Degenerative disease

Porphyria is a hereditary disorder characterized by enzyme defects in heme biosynthesis, and can affect the central nervous system (CNS) (1–4). We describe two patients with hepatoerythropoietic porphyria (HEP) who had cortical atrophy and frontal mineralization on computed tomographic (CT) and magnetic resonance (MR) studies of the brain.

Case Reports

Two unrelated patients with clinical features and laboratory findings of HEP experienced several seizures during follow-up. CT and MR examinations were performed to clarify the pathogenesis of the seizures. Dermatological, biochemical, and genetic aspects of both patients have been published previously (3, 5–7).

Case 1

A 28-year-old woman had had progressive photosensitivity since the age of 1 year, with hypertrichosis, scars, blisters, and sclerodermoid changes. Laboratory findings showed an increase in uroporphyrin and 7-carboxylic porphyrins in the urine, with elevated levels of isocoproporphyrin in the feces, and protoporphyrin in the erythrocytes. The activity of the erythrocyte uroporphyrinogen decarboxylase was decreased to 10% of normal values. These enzymatic features confirmed the diagnosis of HEP, and treatment with cutaneous protecting substances for external application was begun.

At the age of 23 years, the patient experienced a posterior generalized focal seizure. A CT study performed 4

months later (Fig 1) showed cortical atrophy, located mainly in the frontal lobes, with associated parenchymatous calcifications at the same level. No abnormal contrast enhancement was detected.

An MR examination 1 year later revealed the same frontal atrophy seen on the CT scans, as well as punctate bright signal on T1-weighted images at the same level as the parenchymatous calcifications shown on the CT study. Several focal areas of high-signal change on T2-weighted images were visible in the region of the bifrontal calcifications. No other parenchymatous alterations of interest were found (Fig 1B and C).

A CT scan 4 years later showed progression of the atrophy, possibly due to the antiepileptic treatment, with no change in the number or morphology of the calcifications (Fig 1D).

Case 2

A 21-year-old man had experienced severe photosensitivity since infancy with the same cutaneous lesions as the patient described in case 1. His enzymatic alterations, with increased levels of uroporphyrin and 7-carboxylic porphyrins in the urine and elevated quantities of isocoproporphyrin in the feces and protoporphyrin in the erythrocytes, pointed to the diagnosis of HEP. The diagnosis was confirmed when values lower than 18% of normal were found in the enzyme erythrocyte uroporphyrinogen decarboxylase. Treatment with cutaneous protecting substances was initiated at that time.

At the age of 21 years, he began to experience several episodes of seizures with no evidence of precipitating factors. These seizures required pharmacological treatment with carbamazepine. A CT examination showed cortical atrophy, mainly in the frontal lobes, with associated parenchymatous mineralization (Fig 2).

Discussion

Porphyria cutanea tarda (PCT) is the most common form of porphyria and is caused by a

Received April 16, 1996; accepted after revision October 31.

From the Departments of Radiology (J.Be., J.Bl., C.C., T.P., J.Me.) and Dermatology (C.H., J.Ma.), Hospital Clinic i Provincial de Barcelona, Universitat de Barcelona, and the Department of Dermatology, Hospital Provincial de Pontevedra (M.J.C.P., C.D.L.T.), Spain.

Address reprint requests to Juan Berenguer MD, Department of Radiology, Section of Neuroradiology, Hospital Clinic i Provincial de Barcelona, Villarroel, 170 E-08036 Barcelona, Spain.

AJNR 18:1557–1560, Sep 1997 0195-6108/97/1808–1557 © American Society of Neuroradiology

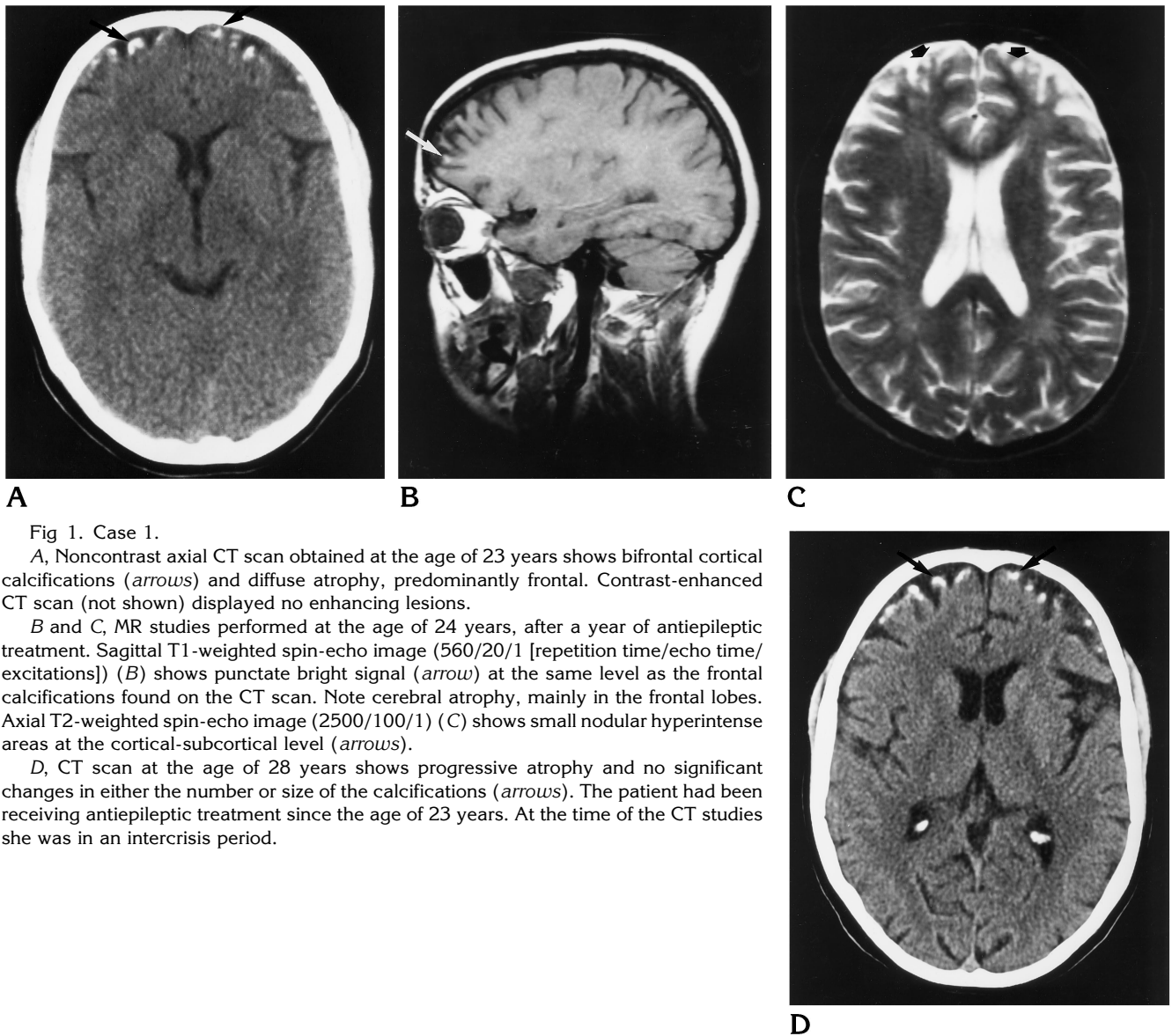


Fig 1. Case 1.

A, Noncontrast axial CT scan obtained at the age of 23 years shows bifrontal cortical calcifications (*arrows*) and diffuse atrophy, predominantly frontal. Contrast-enhanced CT scan (not shown) displayed no enhancing lesions.

B and C, MR studies performed at the age of 24 years, after a year of antiepileptic treatment. Sagittal T1-weighted spin-echo image (560/20/1 [repetition time/echo time/excitations]) (B) shows punctate bright signal (*arrow*) at the same level as the frontal calcifications found on the CT scan. Note cerebral atrophy, mainly in the frontal lobes. Axial T2-weighted spin-echo image (2500/100/1) (C) shows small nodular hyperintense areas at the cortical-subcortical level (*arrows*).

D, CT scan at the age of 28 years shows progressive atrophy and no significant changes in either the number or size of the calcifications (*arrows*). The patient had been receiving antiepileptic treatment since the age of 23 years. At the time of the CT studies she was in an intercrisis period.

reduction in uroporphyrinogen decarboxylase activity. Two types of PCT have been described: the sporadic form, in which the uroporphyrinogen decarboxylase activity in the hepatocytes falls by 50%, and the familial form, in which other cell types, such as erythrocytes, are also affected by the enzymatic defect. HEP, described by Piñol et al (5) in 1975, is considered to be the homozygous form of PCT. In HEP, hematologic and severe cutaneous manifestations appear from infancy as a result of deficient uroporphyrinogen decarboxylase activity (3, 6, 8, 9).

Neurologic manifestations, such as abdominal pain, neuritis, seizures, encephalopathy, depression on the conscious level, and psychoses,

are clinical symptoms typical of acute intermittent porphyria (10), and they are also frequently seen with hereditary coproporphyria and variegate porphyria (8). Increase of the porphyrin precursors δ -aminolevulinic acid and porphobilinogen may be observed in urine during the attacks. Neurologic manifestations are caused by the excessive presence of porphyrins (4).

Previous reports of the neuroimaging aspects of porphyria include a case of intracranial calcifications located on the dura mater and calvaria in a patient with congenital erythropoietic porphyria (Gunther disease) (2). MR changes after paramagnetic contrast administration, with multiple areas of bright signal on T2-weighted sequences (1, 4, 9–11) and diffuse

gyriform enhancement on T1-weighted sequences (1, 4, 10), have been reported in patients with acute neurologic symptoms of porphyric encephalopathy. These MR changes may be caused by a transient vasoreactive ischemia due to a reversible vasculopathy (1, 4, 10, 11). Transient diffuse vasospasm at MR angiography has been described in one case of porphyric encephalopathy (4). The pathogenesis of vasospasm is unknown, but it may be associated with a decrease in nitric oxide synthase enzyme activity when there is a heme deficiency, as in acute intermittent porphyria. Because nitric oxide is an important CNS vascular dilator, its deficit could be related to vasoconstriction and ischemic lesions (10). Other possible explanations for the neurologic lesions in patients with porphyric encephalopathy include neurotoxic effects due to excessive porphyrin and/or intracellular heme deficiency in neural tissues (1). Other MR changes, such as areas of bright signal in the posterior cord in a patient with hereditary coproporphyrin (9), have also been documented.

Our two patients experienced several episodes of generalized seizures. A CT examination of the brain performed several months after the seizures showed cerebral cortical atrophy located mainly in the frontal lobes with associated parenchymatous cortical calcifications. We do not know whether the calcifications were present before the seizures, as no CT examination was performed at that time. MR images in the patient in case 1 showed cortical atrophy and punctate bright signal, located in the same place as the frontal calcifications on the T1-

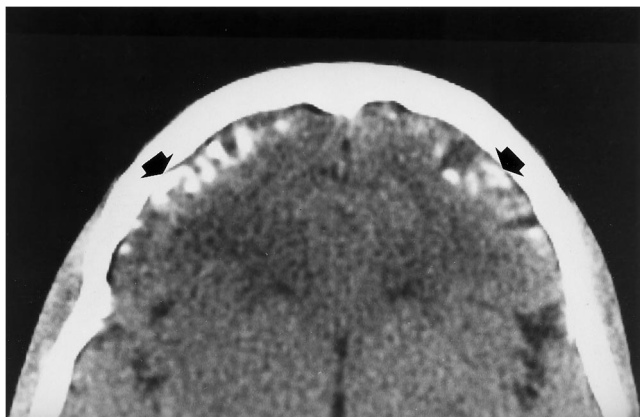


Fig 2. Case 2. Noncontrast CT scan shows frontal cortical calcifications (arrows) and atrophy. At the time of the imaging study, at the age of 21 years, the patient had no neurologic signs or symptoms.

weighted images. Hyperintensities on T2-weighted images were also seen, and probably corresponded to the encephalomalacic areas.

Cortical calcifications and seizures can be seen in many diseases. In phakomatoses, such as Sturge-Weber syndrome (12, 13), calcifications are located mainly in the occipital lobes, and contrast enhancement usually occurs (13). Epilepsy and brain calcifications can also be seen in coeliac disease (14), in tuberous sclerosis (15), in association with open heart surgery (16), and in relation to "cerebral steal" phenomenon from an arteriovenous malformation (17). Other possible origins of brain calcifications, such as radiation therapy (18), tuberculosis, purulent meningitis (19), lupus erythematosus (20), Prader-Willy syndrome (21), osteopetrosis (22), pseudohypoparathyroidism (23), congenital cytomegalovirus (24), and cerebral infarction (25), have also been documented.

None of these other causes of cerebral calcifications were present in either of our patients. We do not think that the calcifications were associated with the cutaneous protecting substances used externally or with the antiepileptic medication, since these treatments were initiated a few weeks before CT was performed. We believe that both the calcifications and the hyperintensities on the T2-weighted images were associated with the illness. The calcifications may have appeared earlier, and may not have progressed quickly, as follow-up CT studies 5 years after the first seizure showed no significant changes in either their number or distribution.

Our patients had neurologic signs and symptoms of epilepsy. Acute left hemiplegia and a focal seizure in a patient with HEP have been described (9). It is therefore reasonable to suggest that intermittent episodes of hypoxic and/or ischemic injury described in other types of porphyria may cause dystrophic mineralization, laminar necrosis, encephalomalacic changes, and atrophy.

In our view, neurologic screening of these patients is useful to confirm findings and to disclose their possible origin, although it will probably not influence therapy.

References

1. Aggarwal A, Quint DJ, Lynch JP. MR imaging of porphyric encephalopathy. *AJR Am J Roentgenol* 1994;162:1218-1220

2. Levesque M, Legmann P, Le Cloirec A, Deybach JC, Nordmann Y. Radiological features in congenital erythropoietic porphyria (Gunther's disease). *Pediatr Radiol* 1988;18:62-66
3. Verneuil H, Moreau-Gaudry F, Laradi S, Cruces MJ, de la Torre C, Aris LF. Etudes enzymatique et moléculaire d'un cas de porphyrie hépato-érythrocytaire. *Arch Fr Pediatr* 1992;49:907-911
4. Black KS, Mirsky P, Kalina P, et al. Angiographic demonstration of reversible cerebral vasospasm in porphyric encephalopathy. *AJNR Am J Neuroradiol* 1995;16:1650-1652
5. Piñol J, Herrero C, Almeida J, et al. Porphyrie hépato-érythrocytaire: une nouvelle forme de porphyrie. *Ann Dermatol Venereol* 1975;102:129-136
6. Roberts AG, Elder GH, De Salamanca RE, Herrero C, Lecha M, Mascaró JM. A mutation (G281E) of the human uroporphyrinogen decarboxylase gene causes both hepatoerythropoietic porphyria and overt familial porphyria cutanea tarda: biochemical and genetic studies on Spanish patients. *J Invest Dermatol* 1995;104:500-502
7. Cruces MJ, Enriquez R, Vereá M, Peña ML, Catalán T, Robledo A. Two cases of infantile and familial porphyria cutanea tarda. *Dermatologica* 1980;161:205-210
8. Smith SG. Hepatoerythropoietic porphyria. *Semin Dermatol* 1986;5:125-137
9. Parsons JL, Sahn EE, Holden KR, Shashidhar Pai G. Neurologic disease in a child with hepatoerythropoietic porphyria. *Pediatr Dermatol* 1994;11:216-221
10. Kupferschmidt H, Bont A, Schnorf H, et al. Transient cortical blindness and bioccipital brain lesions in two patients with acute intermittent porphyria. *Ann Intern Med* 1995;123:598-600
11. King PH, Bragdon AC. MRI reveals multiple reversible cerebral lesions in an attack of acute intermittent porphyria. *Neurology* 1991;41:1300-1302
12. Giroud M, Nivelon-Chevalier A, Vicard C, Couaillier JF, Dumas R. Epilepsie et calcifications corticales occipitales bilatérales: une entité nouvelle. *Presse Med* 1987;16:308-309
13. Masson C, Gallet JP, Cheron F, Masson M, Cambier J. Epilepsie avec calcifications corticales bilatérales. *Rev Neurol* 1988;144:499-502
14. Magaudda A, Dalla Bernardina B, De Marco P, et al. Bilateral occipital calcification, epilepsy and coeliac disease: clinical and neuroimaging features of a new syndrome. *J Neurol Neurosurg Psychiatry* 1993;56:885-889
15. Wilms G, Van Wijck E, Demaerel Ph, Smet MH, Plets C, Brucher JM. Gyriiform calcifications in tuberous sclerosis simulating the appearance of Sturge-Weber disease. *AJNR Am J Neuroradiol* 1992;13:295-298
16. Begeer JH, Rutgers AWF, Vencken LM, Hoorntje TM, Meuzelaar JJ, Woltersom-Zwierzynska BD. Vanishing calcification of the brain in an infant after open heart surgery. *Neuroradiology* 1991;33:374-376
17. Yu YL, Chiu EKW, Woo E, et al. Dystrophic intracranial calcification: CT evidence of "cerebral steal" from arteriovenous malformation. *Neuroradiology* 1987;29:519-522
18. Lewis E, Lee YY. Computed tomography findings of severe mineralizing microangiopathy in the brain. *J Comput Tomogr* 1986;10:357-364
19. Sener RN. Gyriiform calcifications following purulent meningitis. *Pediatr Radiol* 1993;23:491
20. Yamamoto K, Nogaki H, Takase Y, Morimatsu M. Systemic lupus erythematosus associated with marked intracranial calcification. *AJNR Am J Neuroradiol* 1992;13:1340-1342
21. Reske-Nielsen E, Lund E. Prader-Willi syndrome and central nervous system calcifications: chance or fundamentally related findings? *Clin Neuropathol* 1992;11:6-10
22. Patel PJ. Some rare causes of intracranial calcification in childhood: computed tomographic findings. *Eur J Pediatr* 1987;146:177-180
23. Smit L, van Wijk RM, Rico RE, Sitalsing AD. Intracerebral bilateral symmetrical calcifications demonstrated in a patient with pseudohypoparathyroidism. *Clin Neurol Neurosurg* 1988;90:145-150
24. Barkovich AJ, Lindan CE. Congenital cytomegalovirus infection of the brain: imaging analysis and embryologic considerations. *AJNR Am J Neuroradiol* 1994;15:703-715
25. Sener RN. Gyral calcifications detected on the 45th day after cerebral infarction. *Pediatr Radiol* 1993;23:570-571