

Location of Language in the Cortex: A Comparison between Functional MR Imaging and Electrocortical Stimulation

David B. FitzGerald, G. Rees Cosgrove, Steven Ronner, Hong Jiang, Brad R. Buchbinder, John W. Belliveau, Bruce R. Rosen, and Randall R. Benson

PURPOSE: To determine the accuracy of functional MR imaging in locating language areas for planning surgical resection. **METHODS:** Intraoperative photographs were digitized and overlaid on functional MR language maps. The sensitivity and specificity of functional MR imaging for identifying language areas were determined for five different language tasks by comparing functional MR areas of language activation with results of electrocortical stimulation. A match was considered to occur if an activated area contacted, overlapped, or surrounded a language tag. The borders of the activation areas were extended by 1 and 2 cm to determine whether the number of matches changed. Language and nonlanguage tag matches were tabulated separately. **RESULTS:** Sensitivity/specificity for all patients and all language tasks ranged from 81%/53% for areas that touched to 92%/0% for areas separated by 2 cm. Individual language tasks were not as sensitive as a battery of language tasks combined. Location of language areas varied among subjects for a given task and among tasks for a given subject. **CONCLUSION:** Functional MR imaging should be considered a useful presurgical planning tool for mapping cortical language areas, because it is sensitive, it provides increased time for planning before surgery, and it is noninvasive.

Index terms: Magnetic resonance, functional; Magnetic resonance, in treatment planning

AJNR Am J Neuroradiol 18:1529–1539, September 1997

Surgical resection in the dominant hemisphere near cortical language areas can result in language deficits after surgery. The distance of the resection from language sites, as determined with cortical stimulation, is the most important variable predicting recovery from postoperative aphasia (1). Thus, accurately locating all essential language areas is critical for a

speedy recovery as well as for avoiding postoperative deficits.

Functional imaging of cortical language areas is an extension of work done with somatosensory and motor areas in the cortex. Functional magnetic resonance (MR) activation during language tasks has been identified in Broca's area (2) (R. R. Benson, J. W. Belliveau, K. K. Kwong, et al, "Lateralization and Localization of Language Using Functional MR," In: *Proceedings of the Society for Neuroscience 24th Annual Meeting*, Washington, DC: Society for Neuroscience; 1994:6[9.7]). Activation in the posterior superior temporal gyrus (Benson et al, "Lateralization...") as well as in the left middle or superior temporal gyrus (A. C. Nobre, R. T. Constable, G. McCarthy, J. C. Gore, "Activation of Brain Areas during a Language Task Using Conventional MRI," In: *Proceedings of the Society for Neuroscience 23rd Annual Meeting*, Washington, DC: Society for Neuroscience; 1993:740.11) has also been reported, suggesting Wernicke's area can be located through

Received September 3, 1996; accepted after revision March 24, 1997.

Dr Belliveau's sources of funding are National Institutes of Health grant MH50054, the Human Frontier Science Program, and the American Heart Association Established Investigator Award.

Presented in part in functional MR imaging workshops held at Massachusetts General Hospital and at the annual meeting of the Congress of Neurological Surgeons, Montreal, Quebec, Canada, September 1996.

From the NMR Center (D.B.F., J.W.B., B.R.R., R.R.B.), the Department of Neurosurgery (G.R.C., S.R., H.J.), and the Neuroradiology Division (H.J., B.R.B.), Massachusetts General Hospital, Charlestown.

Address reprint requests to David B. FitzGerald, c/o Bruce Rosen, MD, MGH NMR Center, Building 149 (2301), 13th Street, Charlestown, MA 02129.

AJNR 18:1529–1539, Sep 1997 0195-6108/97/1808–1529

© American Society of Neuroradiology

functional MR imaging. In one report (T. Makabe, H. Handa, K. Kinoshita, et al, "Usefulness of Functional MR Imaging [fMRI] for Presurgical Evaluation of the Eloquent Area," In: *Proceedings of the Society of Magnetic Resonance 3rd Scientific Meeting*, Berkeley, Calif: Society of Magnetic Resonance; 1995:1343), areas identified by functional MR imaging were considered to agree with results of electrocortical stimulation in Broca's area in two patients.

Our purpose in conducting this study was to evaluate functional MR imaging as a predictive technique for locating eloquent areas in the dominant hemisphere. Our approach was to locate the cortical language areas using functional MR imaging, map essential language sites by using direct electrocortical stimulation, and evaluate sensitivity and specificity of functional MR areas of activation as compared with essential language areas identified by electrocortical stimulation.

Materials and Methods

Patients

Thirteen patients with lesions in the presumed dominant hemisphere underwent functional MR imaging. At surgery they underwent electrocortical stimulation under local anesthesia. Patients gave informed consent and our protocol was approved by our hospital's subcommittee on human studies. Of the 13 patients, one patient was claustrophobic and was excluded because of motion during the functional MR study. Another patient was excluded owing to an unreliable cortical stimulation result.

Of the 11 remaining patients, eight had tumors, one had a benign cyst, one had epilepsy, and one had a cavernous angioma. One patient (P4) had surgery at another institution, but the functional MR imaging was performed at our hospital. This patient's surgical report, discharge summary, and intraoperative photographs were forwarded to us. One patient (P8) was bilingual; her native language was Greek and she had a good working knowledge of English.

All 11 patients were right-handed. One patient (P10) who was strongly right-handed, which would usually predict left-hemisphere dominance (3), was determined with Wada testing and later confirmed with functional MR testing to be right-hemisphere dominant. The patient's hemispheric laterality ratio (4) was computed to be an average of 0.925 based on four runs of visual verb generation, indicating slight right-hemisphere dominance. For this patient, mapping between cortical stimulation and functional imaging was performed in the right hemisphere. In all other patients, language maps and cortical stimulation were performed in the left hemisphere. In four patients (P1, P3, P5, P7), Wada testing confirmed left-hemisphere dominance;

one patient (P2) had equivocal Wada test findings, which tended toward left-hemisphere dominance.

Imaging

Whole-brain MR imaging was done on a 1.5-T Signa scanner with multisection echo-planar imaging. The initial scan included 59 sagittal sections ear to ear, with a section thickness of 3 mm. After the sagittal scan was obtained, an automated shim sequence was performed (5), which reduced inhomogeneities in the magnetic field over the whole brain, thus increasing local sensitivity to activity-related signal change.

High-resolution echo-planar T1-weighted images consisted of 13 sections 7 mm thick with an in-plane resolution of 1.5 mm. The gap between sections varied from 1.0 mm to 2.5 mm depending on the size of the patient's brain. The sections were oriented parallel to a line connecting the inferior frontal and temporal poles in an oblique axial plane. This section orientation minimized artifacts caused by orbit and neck structures as well as the number of sections needed to image the whole brain, thus maximizing the number of images per section that could be acquired.

For functional imaging, we used an echo-planar asymmetric spin-echo sequence (2000/70 [repetition time/echo time]; 180° offset of -25 milliseconds) in the same orientation and location as the high-resolution echo-planar T1-weighted sections using a 128 × 64 matrix (field of view, 400 × 200 mm), giving an in-plane resolution of 3.1 mm. Each section was imaged 78 times over 156 seconds with the first three images discarded because of initial nonequilibrium magnetization.

Foci for language activation as determined by electrocortical stimulation are inferred to be 1 to 2 cm² (6). Projecting a functional imaging voxel of 3.1 × 3.1 × 7 mm to the cortical surface results in a pixel size of 3.1 × 7 mm. This pixel size is sufficiently smaller than the expected foci size so as to provide fine-grained resolution of functional MR language task areas as compared with areas identified by electrocortical stimulation.

Finally, we acquired two conventional T1-weighted spoiled gradient-echo volumetric (1.2-mm isotropic) scans, first without then with contrast agent (gadopentetate dimeglumine) to generate surface renderings of the brain. These renderings, which included blood vessels, were used to register the activation maps with the surgical site.

To minimize movement, patients' heads were immobilized in a standard head coil with a combination of a pillow, Velcro head straps, and foam rubber pads. Visual stimuli were presented on a video projector driven by an Apple Macintosh IIVX running Psychlab (Teren Gum, Montreal Neurological Institute). A mirror above the head coil allowed the patients to see the stimuli, which were projected onto a rear projection screen mounted on the head coil. Binaural auditory stimuli were generated from an audio-cassette and transmitted to the patient via air conduction

tubes to plastic high ambient sound attenuation headphones.

Tasks

Five tasks were used to activate language areas by means of either auditory or visual input. The format for each scan consisted of two periods of 30 seconds each of a task, with 30-second periods of fixation before, between, and after the tasks, for a total of 150 seconds. Up to two scans of each task were acquired per patient.

Visual Tasks.—*Word reading* is presumed to impose linguistic demands on the brain, with results from positron emission tomographic (PET) studies indicating that lateralized activation is produced during the reading of single words (7). A total of 80 medium- to high-frequency concrete nouns of three to seven letters were chosen and separated into two lists. Each noun was presented for 150 milliseconds, with 1350 milliseconds between nouns, giving a total elapsed time of 1500 milliseconds for each stimulus. Patients were instructed to read the word to themselves, without moving their mouth. The control task was visual fixation on a crosshair.

Visual verb generation has also been shown to produce lateralized language activity in PET studies (8, 9). The same set of stimuli as in the word reading task, although in a different order, was projected onto the screen, with patients instructed to think of a verb that is associated with the noun. For example, the word "ball" might generate the verb "hit."

Auditory Tasks.—For auditory tasks, the primary and higher-order auditory cortex may be activated in addition to frontal language areas. This is consistent with our goal of evaluating the accuracy of tasks in determining language-activated areas.

Listening to single words was used to stimulate auditory and language areas. The words used were the same as in the word reading task. Words were recited on average every 1.5 seconds, with two periods of 20 words per scan. The control task involved attending to scanner noise.

Listening to text, as opposed to isolated words, was also used. A passage from a simple text on language and the brain had been previously recorded at a typical reading rate. The passage was then played through the headphones. The tape was played for two periods of 30 seconds each, alternating with the control task, which was attending to scanner noise.

Auditory verb generation used the same set of words as the visual verb-generation task, but the words were presented through the headphones. Patients were instructed to think of the response, but not to vocalize it.

Ten patients performed visual verb generation, six performed auditory verb generation, four listened to a passage, three read words, and two listened to words. The bilingual patient was given the visual verb-generation task in both Greek and English.

Although the task of naming objects has been validated and used extensively by neurosurgeons for cortical stimulation, it was not included in our battery of tasks, because

our experience with this task in functional MR imaging is that it produces poorly lateralized activity with a large amount of visual cortical activity. Since our goal was to minimize nonlinguistic activity as much as possible, object naming was therefore not included. Counting and over-learned speech are frequently preserved in aphasia and was therefore not considered a good predictor of language cortex.

Patients who were likely to have the sensorimotor region (the precentral and postcentral gyri) exposed during surgery were asked to perform a tongue movement task, consisting of moving only their tongue from side to side. Tongue movement and the control task of rest were alternated for 30-second periods each. In some cases, patients were also instructed to open and close the hand contralateral to the hemisphere that would be exposed during surgery. Hand activity and rest tasks alternated for 30 seconds each. Both tongue and hand tasks were performed to reduce the possibility of confusing language and somatosensory/motor areas.

Postscan Processing

The high-resolution 3-D spoiled gradient-echo image of the cortex was merged with the MR angiogram by using Analyze (Mayo Clinic, Minneapolis, Minn), which provided a surface rendering with anatomic landmarks. Statistical maps for each scan were generated from each section and time series on a pixel-by-pixel basis using the Komolgorov-Smirnov nonparametric test (J. Baker, R. Weisskoff, C. Stern, et al, "Statistical Assessment of Functional MRI Signal Change," In: *Proceedings of the Society of Magnetic Resonance 2nd Scientific Meeting*, Berkeley, Calif: Society of Magnetic Resonance; 1994:626; and D. Wu, and J. S. Lewin, "Evaluation of Non-parametric Statistical Measures and Data Clustering for Functional MR Data Analysis, In: *Proceedings of the Society of Magnetic Resonance 2nd Scientific Meeting*, Berkeley, Calif: Society of Magnetic Resonance; 1994:629). Komolgorov-Smirnov maps were converted to $-\ln(P)$ statistical maps (10). Each functional scan was checked for motion before proceeding. Typically, the first and last time point in the middle section were subtracted from each other. If a "halo" or "corona" appeared, indicating rigid body motion of the brain, the time series was motion corrected (11) (R. Turner, K. J. Friston, R. Howard, S. C. R. Williams, R. S. J. Frackowiak, "Automated Registration and Normalization of Functional MR Time Course Images," In: *Proceedings of the Society of Magnetic Resonance 3rd Scientific Meeting*, Berkeley, Calif: Society of Magnetic Resonance; 1995: 235).

The statistical maps were coregistered with the 3-D surface rendering. Cortical activation was then projected onto the surface of the brain, with noncortical activation deleted for clarity of presentation and irrelevance to cortical surgery. The statistically thresholded data were projected onto the lateral, superior, and oblique planes of the head.

The need to focus on results at the individual rather than group level made a fixed statistical threshold unrealistic, as people vary in their functional MR activation levels for a given task. Our experience in the lab across a wide variety of task paradigms in many brain regions is that some subjects are "strong" activators (eg, exhibit a large percentage change in blood flow) and others are "weak" activators. The high degree of variability in location of language areas as well as differing surgical sites also prohibits setting thresholds based on a priori defined anatomic locations.

Usually, functional MR studies and statistical analyses focus on setting thresholds at the voxel level to reduce type 1 (false-positive) error (12–14). However, the desire for deficit-free neurosurgery requires a balance between avoiding type 1 and type 2 (false-negative) errors. Type 1 errors can be reduced by use of cluster criteria to exclude single-voxel activation (12). Setting a requirement in which too many voxels are displayed results in the possibility of missing small but valid areas of language activation.

The display threshold for this study was adjusted on a task-by-task basis for each patient, resulting in the projection to the cortical surface of areas of activation of about 1 cm or larger. This is consistent with the inference made by Steinmetz and Seitz (6), on the basis of a review of cortical stimulation data, that foci of language may be 1 to 2 cm², distributed throughout the cortex, and variable in location. The choice of 1-cm clusters is also consistent with the observation that resecting 1 cm or more away from an essential language site results in fewer permanent deficits than resecting closer to a language site (1). The least stringent threshold for single-voxel display was a *P* value of .032.

The rendering was colorized, with yellow indicating a lesion, green indicating language activation, and red or blue indicating motor or sensory activation. Multiple views of the cortex and site(s) of activation were then printed for reference during surgery.

Cortical Stimulation

All craniotomies were performed with the patient under a local anesthetic (0.5% lidocaine and 0.25% bupivacaine hydrochloride) and mild intravenous sedation (propofol). Cortical stimulation was carried out using a constant current generator (Model S-12, Grass Instruments, Quincy, Mass) to produce biphasic stimulation (0.5 milliseconds per phase) with a frequency of 50 pulses per second. A hand-held bipolar stimulator probe with 2-mm-diameter ball tips and 5-mm spacing was used as the cortical probe.

Somatosensory and motor areas were identified first to avoid confusing motor control areas for speech with areas essential for language. During stimulation, the patient was questioned about motor and sensory phenomena. Such responses as involuntary muscle contractions in the lips, involuntary finger movements, or tingling in the tongue were considered to identify motor or somatosensory areas, respectively. Sites found to control sensory or motor areas around the mouth, tongue, or hand were marked with sterile tags with a number or letter on the tag. Sites that

showed an effect on language were tagged in the same manner.

Current levels during cortical stimulation were adjusted by raising the stimulation level in 1-mA increments until an effect on language occurred. Thresholds for motor and sensory areas were generally lower than those found for speech or language areas. All thresholds for tagged areas were lower than the after-discharge level as assessed by simultaneous multichannel electrocorticography. Typical stimulation currents for threshold responses were in the 3- to 7-mA range. Functional MR images were used initially to assess which cortical regions should be stimulated and tagged.

Language areas were identified by using several tasks. Patients were presented with a line drawing on a card and asked to say, "This is a . . ." followed by the name of the object. Patients were also requested to recite overlearned speech (eg, naming the days of the week or the months of the year, counting from 1 to 20) as well as reversals of overlearned speech (eg, listing the days of the week backward from Thursday). Patients also read words aloud, which consisted of the same words as those used during functional MR imaging. A sterile tag was placed on the cortex if cortical stimulation caused perseveration, hesitation, phonemic, or semantic errors or speech arrest for any of the four tasks on repetitive testing.

The bilingual patient performed the object-naming task in her primary language (Greek) and then in her second language (English). An interpreter in the room validated the answers given.

After completion of the cortical mapping procedure, an intraoperative photograph was taken for comparison purposes. Cortical resection then proceeded in a routine manner.

Data Analysis

The intraoperative photograph was digitized with the use of a desktop scanner and imported into Adobe Photoshop 3.0 (Adobe Systems Inc, Mountain View, Calif). The lateral projection from the 3-D renderings of activation was also imported into Adobe Photoshop. Both images were then scaled, rotated, and coregistered for maximum agreement, using the cortical surface veins and sulci as anatomic landmarks. Each image was given a separate layer in Photoshop and then superimposed via a transparency option to evaluate the degree of mismatch between the two images of the surface vessels. The worst-case mismatch between the photograph and the rendering was 0.7 cm at the edge of the surgical field for patient P6, with agreement improving to 0.3 cm in the area of highest mismatch near a tag. Mismatch for other patients was 0.2 cm or less, with 1-millimeter matching or better for four patients.

Areas of functional MR activation were compared with language tags placed during electrocortical stimulation, with a match considered to occur if an activated area contacted, overlapped, or surrounded a language tag. Matches between language areas and the centroid of the

Sensitivity and specificity over distance by paradigm for all patients

Task	Touching		1-cm Separation		2-cm Separation		No. of Language Tags	No. of Nonlanguage Tags
	Sensitivity, %	Specificity, %	Sensitivity, %	Specificity, %	Sensitivity, %	Specificity, %		
Visual verb generation	58	59	82	32	84	0	38	34
Reading	33	80	67	60	67	20	3	5
Listening to words	80	44	100	0	100	0	5	9
Listening to a passage	75	88	100	56	100	50	12	16
Auditory verb generation	92	40	100	20	100	0	13	5
No. of tags	48	44	63	24	64	9	71	69

Note.—Sensitivity and specificity for each of the five language tasks are shown for each of the three separation criteria.

cortical stimulation tags were also assessed as a function of distance. On the basis of previous assessments of distance between cortical stimulation tags and essential language areas (1, 6, 15), the borders of the activation areas were extended by 1 and 2 cm to see whether the number of matches changed. Language and nonlanguage tag matches were tabulated separately.

The percentage of language stimulation tags that matched language activation areas was considered the true-positive rate, or sensitivity, of functional MR imaging. Specificity was the percentage of true-negatives (nonlanguage tags; ie, sensory or motor tags) not found by functional MR imaging. The absence of a language tag was interpreted as the absence of activity in that area for a particular language task. However, cortical stimulation with a different language task might have resulted in speech arrest at the same site (16). Time constraints in an intraoperative setting limited testing to simple tasks, precluding comprehensive language testing. Thus, a true-negative for language was not defined as an area without a language tag but rather as an area with a nonlanguage tag. Therefore, our working definition of specificity is the percentage of nonlanguage tags (which we must define as true negatives given the constraints of electrocortical stimulation testing) that did not match with functional MR language areas. Two repetitions of the same task for a given patient (eg, two trials of visual verb generation) were averaged together and considered to be a single task for the purposes of this article.

Receiver operator curves based on sensitivity and specificity for functional MR imaging were calculated for three match criteria: areas of activation contacting, overlapping, or surrounding language tags; areas of activation within 1 cm of the centroid of the tags; and areas of activation within 2 cm of the centroid of the tags. For each patient, all tasks were combined to compute an overall or combined sensitivity and specificity for that patient. As an example, assuming one language task matched one of three language tags and another language task matched a different language tag, the combined sensitivity for the patient would be 67%, in that two of three tags matched.

Task sensitivity and specificity were evaluated by task across patients for each of the three criteria (Table). The

number of tags matched by functional MR imaging were added across patients for a single task and divided by the total number of language tags for all patients. As an example, all auditory verb-generation tasks were added together, giving 12 tags that contacted language activation and a total of 13 language tags, for a contact sensitivity of 92%. Each tag was only counted once. Motor or sensory stimulation sites were not always obtained during cortical stimulation, so specificity could not be calculated for those patients.

Results

Intraoperative photographs and functional images were combined for all patients. A representative data set is shown in Figure 1.

Variation among Patients

As few as one and as many as seven language tags were placed on a patient. The average was 3.4 tags per patient. Stimulation threshold current levels for language ranged from 1.5 to 11.5 mA for all patients as a group. Current levels at different language sites varied by as much as 5 mA for a given patient.

Considerable variability was found among patients for a given language task. For example, the task of visual verb generation, performed by 10 of the 11 patients, produced variable patterns of activation as shown in Figure 2. All patients showed activation in the frontal lobe (inferior frontal gyrus and middle frontal gyrus), with activation areas differing in size and shape. All patients also showed activation in the temporal or parietal lobes, although these areas were generally smaller and more variable than areas of frontal activity across patients.

Listening to text produced activation at or near the superior temporal gyrus in all patients.

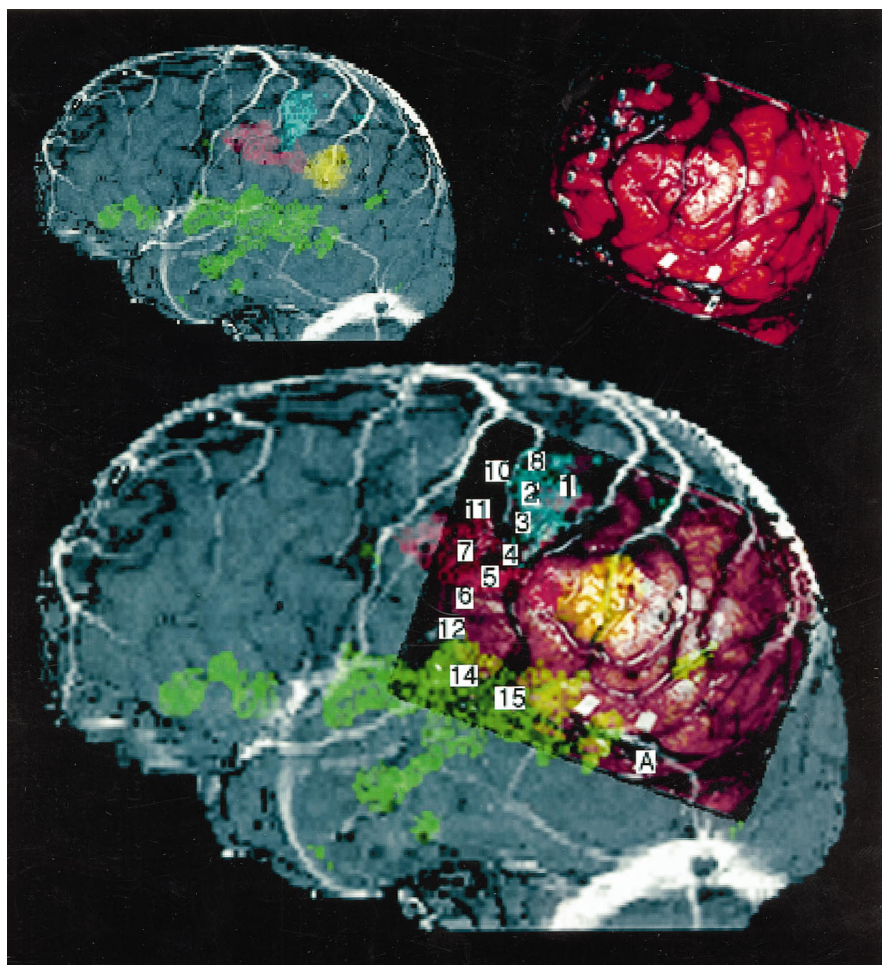
Fig 1. Patient P11.

Top left, Functional MR rendering of activation maps combined with 3-D rendering and MR angiogram.

Top right, Intraoperative photograph shows language and sensorimotor tags.

Bottom, Merged intraoperative photograph, 3-D rendering, and MR angiogram.

Note, photographs are not to same scale. 1 indicates 3 mA: sensation right fourth finger; 2, 3.5 mA: sensation right index finger; 3, 3.5 mA: sensation right thumb; 4, 3.5 mA: sensation right lower lip; 5, 3.5 mA: sensation right upper tongue midportion; 6, 3.5 mA: sensation right anterior tongue; 7, 3.5 mA: movement right lower jaw tonic contraction; 8, 3.5 mA: sensation right middle and ring finger; 10, 4 mA: right wrist extension and rotation; 11, 4 mA: speech difficulties/contractions of mouth; 12, 3.5 mA: sensation right side of tongue; 14, 6 mA: speech arrest and jaw tightening; 15, 6 mA: speech arrest; A, 6 mA: speech arrest. *Yellow* indicates lesion; *green*, language activation; *blue*, hand; *red*, tongue/mouth; *blank tags* were used to identify sites of no response.



All patients showed activation in the frontal lobe, but these areas were generally smaller and more variable than the areas in the temporal lobe. A sample functional image of activation produced by listening to text is shown in Figure 3C.

Auditory verb generation produced activation at or near the superior temporal plane or superior temporal gyrus in the five patients in whom it was tested. Activation also occurred elsewhere in the cortex in differing locations. A sample of an auditory verb generation functional image is shown in Figure 3D.

The number of patients who performed the task of reading and listening to words was too small to articulate differences across patients effectively.

Variation among Tasks

Using the match criterion by which the activation areas must contact the tags, an auditory

task was more sensitive than a visual task in six patients (P4, P5, P6, P8, P9, and P11). Patient P4 had neither of two language sites for visual verb generation, but had the same one tag for both auditory verb generation and listening to recited text. Passive word reading captured one of two tags in visual verb generation for patient P5, while the auditory tasks of passive word listening and auditory verb generation captured both tags. Visual verb generation captured two of three tags, while both auditory verb generation and passive listening to text captured all three tags for patient P6.

Of the five language tags for patient P1, four were clearly contacting language activation areas anterior to the motor areas. The one tag not touching was in Wernicke's area. Although speculative, we believe that if an auditory task had been included in the battery of tasks given, this region might have been located by functional MR imaging.

Neither of the visual tasks (passive word

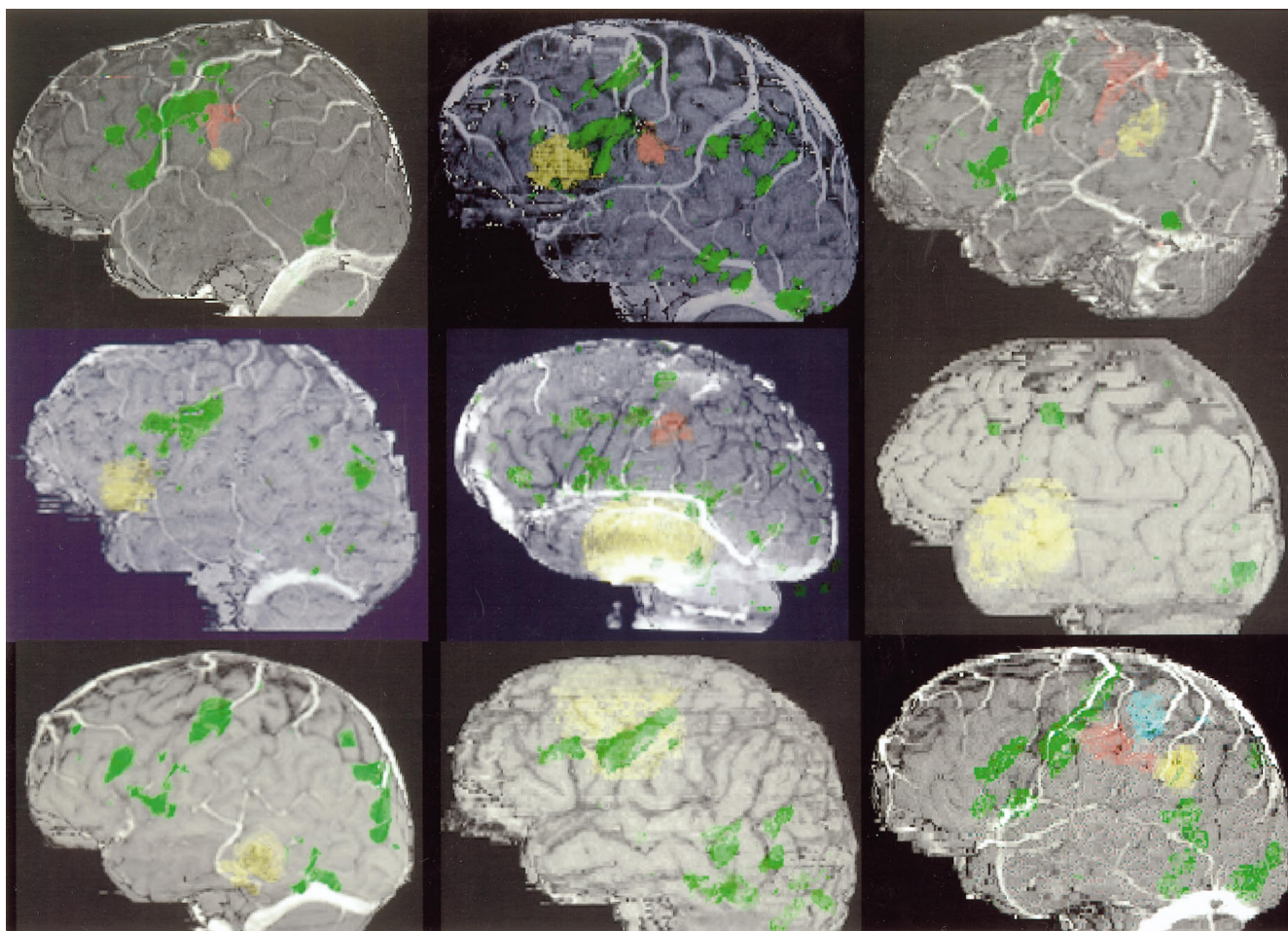


Fig 2. Mosaic of nine patients tested for visual verb generation. From left to right, top to bottom, patients P1, P2, P3, P4, P5, P6, P7, P9, P10 (reversed for consistency), and P11 (patient P8 is shown in Figure 4). Yellow indicates lesion; green, language activation; blue and red, hand and/or mouth.

reading and visual verb generation) matched the single language tag for patient P9, although both passive listening to text and auditory verb generation did capture the tag. Interestingly, patient P11 had one of three language tags captured by visual verb generation. Listening to text captured the two tags not captured by visual verb generation. Thus, both auditory and visual tasks were needed to achieve 100% sensitivity for this patient.

Nonnative Language

For the bilingual patient (P8), sensitivity to visual verb generation was found to depend on the language used. With English, three language tags were in direct contact with language activation areas. In comparison, visual verb generation in Greek had only one language tag in contact with a functional activation area, us-

ing the same activation threshold ($P = .01$) (see Fig 4). Furthermore, when verb generation was done with auditory input in English, all four tags were matched (auditory verb generation was not performed in Greek).

Sensitivity and Specificity among Patients

A graph of sensitivity and specificity of data is shown in Figure 5. Sensitivity for all tasks combined across all patients increased from 81% when the most stringent criterion (contact) was used to 92% when the 2-cm criterion was used. This means that 81% of all language tags were contacted by functional MR areas of language activation, with activation from only one of the tasks required to touch the language tag. Interpersonal variability was high, with individual values ranging from 0% to 100% sensitivity across the three criteria. For six patients, all

Fig 3. Mosaic of patient P9 during four language tasks. From *left to right, top to bottom*: reading words, visual verb generation, listening to passage, auditory verb generation. *Yellow* indicates lesion; *green*, language activation.

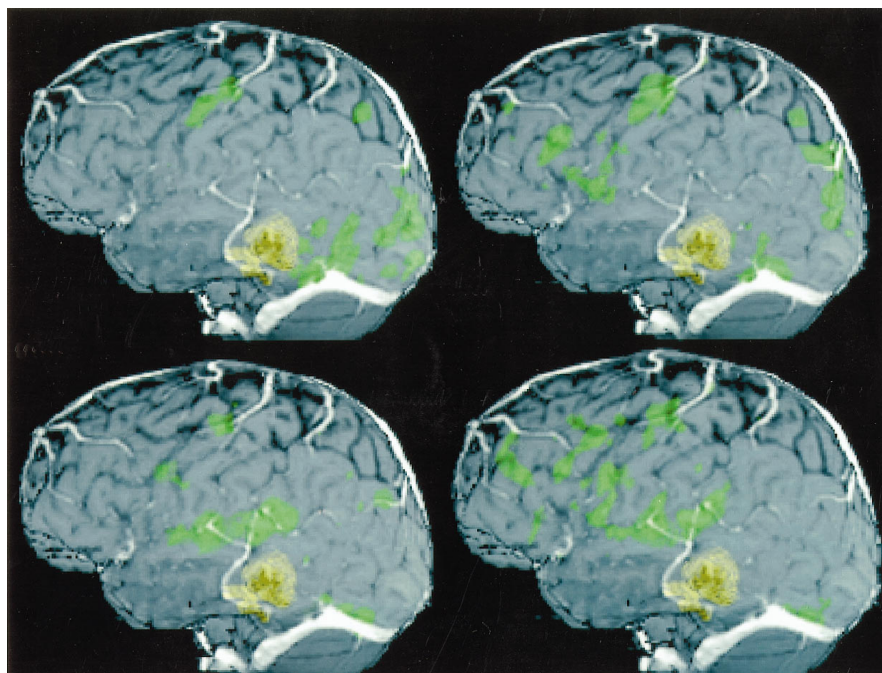
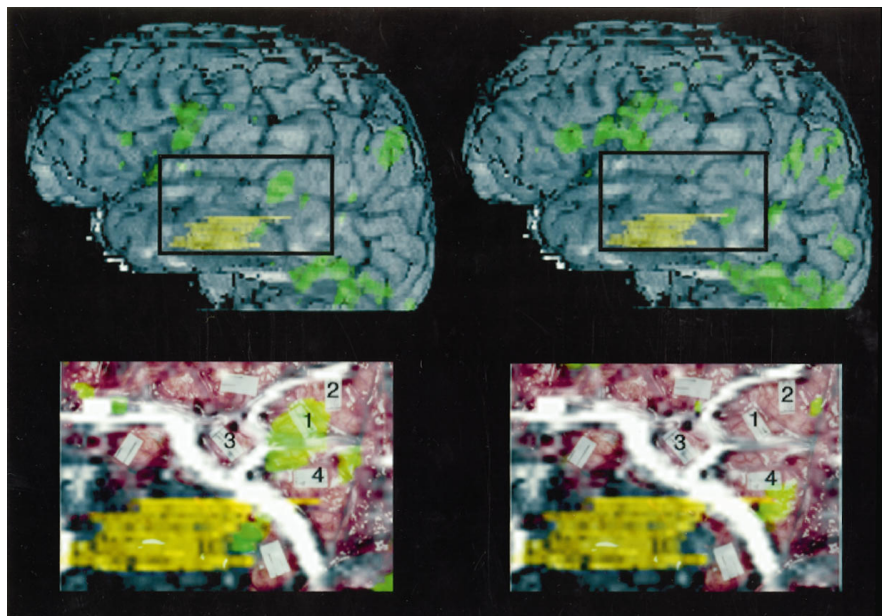


Fig 4. Patient P8. From *left to right, top to bottom*: activation map of visual verb generation in English; activation map of visual verb generation in Greek; intraoperative photograph merged with activation map (area shown corresponds to the square drawn on *top left* image); intraoperative photograph merged with activation map (area shown corresponds to the square drawn on *top right* image). 1 indicates 5 mA: hesitation naming object in Greek, English not tested; 2, 5 mA: speech arrest in both Greek and English; 3, 4.5 mA: hesitation in English during number recitation, no hesitation in Greek; 4, 4.5 mA: hesitation in English during number recitation, no hesitation in Greek. *Blank tags* were used to identify sites of no response. *Yellow* indicates lesion; *green*, language activation.



tags were found to be touching areas of functional MR activation. For three patients, sensitivity increased to 100% from 80%, 50%, and 71%, respectively, as the criterion changed from contact to 1 cm away from the centroid of the tags. Sensitivity for the remaining two patients remained the same, at 80% and at 0%, from contact to 2 cm of separation.

Specificity for all tasks combined across all patients decreased from 54% to 0% as the cri-

terion was relaxed from contact to 2 cm from the boundary of activation to the centroid of the tags. This decrease is not surprising, as the criteria for specificity require that nonlanguage tags not be touched by language areas of functional MR activation. Thus, if any sensorimotor tag is touched by a language activation area, the specificity measure for that patient is considered to decrease. Given the close location of sensory or motor centers to speech centers

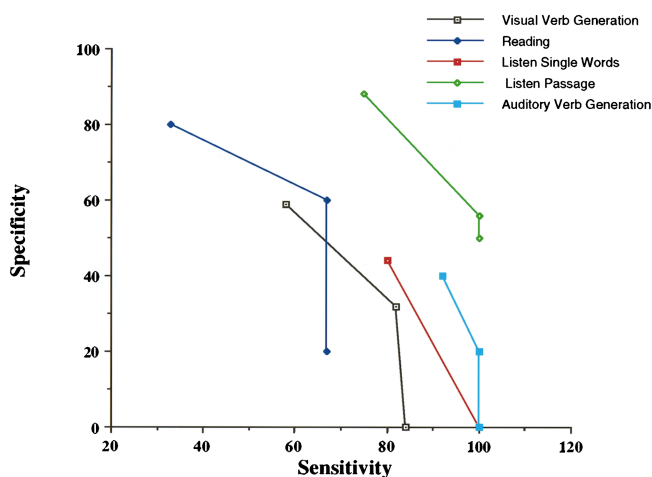


Fig 5. Receiver operator curves for the five paradigms tested.

along the central sulcus (as an example, see Fig 1), an increase in the area of separation between activation and tags is certain to include more nonlanguage tags, thus decreasing specificity.

Discussion

Variation among Patients

Our results agree with other published studies (17–19) of language mapping and cortical stimulation in that there is variation across individuals for the levels of current in cortical stimulation that cause language errors. The wide variation in cortical location of language function observed in this functional MR study for a given task (see Fig 2) agrees with the findings by Ojemann et al (17). Visual verb generation was also concluded to be distinct from picture naming or word reading and to vary in location across subjects in a study comparing cortical stimulation and functional PET imaging (J. G. Ojemann, G. A. Ojemann, E. Lettich, "Cortical Stimulation during a Language Task with Known Blood Flow Changes," In: *Proceedings of the Society for Neuroscience 23rd Annual Meeting*, Washington, DC: Society for Neuroscience; 1993:740.12).

Further agreement on variation across patients was found in a study by Davies et al (20) of temporal lobe resections assisted by subdural grids, which showed substantial variation in the distance from the temporal pole of the dominant hemisphere to the area of speech arrest (3 to 9 cm). In a study of 45 patients by Schaffler et al (19), language maps showed a "core" and

"shell" area for both anterior and posterior language areas, but a broad interpatient region of variability on the periphery of these areas.

The differences in language maps among individuals as determined by both cortical stimulation and functional MR imaging are also consistent with anatomic findings for healthy subjects. Variable asymmetries are found between the right and left side of the brain in language areas, with gyral patterns in the opercular area different in terms of packing and width than those on the other side of the brain (21, 22). Four different topographies of the parietal opercular region have been reported, with 38% of subjects showing different patterns between left and right hemispheres (23).

Single versus Multiple Tasks

The finding that more than one task is necessary to maximize identification of essential language areas by using functional MR imaging is consistent with the need for multiple tasks during cortical stimulation (16). That different areas of the brain are involved in different language tasks agrees with PET findings as well (9). Although auditory verb generation had the best sensitivity for a single task, visual verb generation was also needed for one patient (P11) to maximize the number of language tag matches. Our results suggest the need to administer a battery of language tasks, both visual and auditory, while the patient is in the scanner to ensure identification of the maximal number of language areas. A possible explanation for the observed greater sensitivity of aural tasks than visual tasks was a tendency toward heightened activation of the temporoparietal cortex.

Nonnative Language

Patient P8 showed hesitation in her second language at tags 3 and 4, but at the same current level there was no hesitation in her first language. Although the converse did not occur (ie, hesitation in her first language without hesitation in her second language), the existence of cortical areas specific for one language is consistent with findings reported in other multilingual patients undergoing cortical stimulation (24–27). Interestingly, in all seven subjects reported in those studies, errors occurred in only one of the two languages tested. In our study,

patient P8 only had errors in her second language, English.

Differing patterns of activation for two languages are consistent with a study in which finger spelling and oral language were located in different sites in a single patient (28). This is also consistent with the observation that languages not acquired at the same time are spatially differentiated (K. Kim, J. Hirsch, N. Relkin, R. DeLaPaz, K-M. Lee, "Localization of Cortical Areas Activated by Native and Second Languages with Functional Magnetic Resonance Imaging (fMRI)," In: *Proceedings of the International Society for Magnetic Resonance in Medicine, Fourth Scientific Meeting and Exhibition*, Berkeley, Calif: Society of Magnetic Resonance; 1996:283). Lesion data also indicate that, for some patients, there is differential impairment of language in which only one language is affected (29). Thus, in addition to the battery of language tests mentioned above, our results suggest that bilingual patients should be tested in both languages to avoid deficits in either language.

Aggregate Sensitivity

The change in aggregate sensitivity that occurred between the criterion of touching and that of 1 cm separation (from 81% to 92%) together with the lack of change that occurred from 1 to 2 cm is noteworthy. It is suggestive of the finding by Haglund et al (1) that significantly fewer language deficits result if resection margins are greater than 1 cm and suggests that functional MR imaging may find virtually all language areas.

This report and that of Makabe et al ("Usefulness...") help to establish a correlation between cortical stimulation and functional MR imaging for identification of language areas. These reports of physiological correlation as well as a report of PET and MR correlation (D. R. Weinberger, N. F. Ramsey, B. Kirkby, et al, "Three-dimensional Bold Functional MR and O-15 Water PET Neuroactivation Maps Are Highly Correlated," In: *Proceedings of the Society for Neuroscience 25th Annual Meeting*, Washington, DC: Society for Neuroscience; 1995:273) help to validate the use of functional MR imaging in healthy volunteers, and not just in patients scheduled for a craniotomy, for purposes of language research. The location of a given language task varied across patients. For all

patients, different language tasks produced activation in different locations of the cortex. The use of multiple language tasks increased the sensitivity of functional MR imaging to cortical language areas as revealed by electrocortical stimulation. The performance of tasks in both native and second languages raised the sensitivity to essential language cortex in the one patient tested in more than one language.

In conclusion, functional MR imaging shows a high degree of promise for language location for presurgical planning. The correlation between functional MR language location and electrocortical stimulation helps to validate functional MR imaging both as a clinical and a research tool for language processing. Further work is needed in assessing the language tasks used during imaging. This technique should be considered a strong presurgical planning tool, a valuable adjunct to electrocortical stimulation, and a valuable resource in language research.

Acknowledgments

We thank Thomas Talavage, William Logan, Tetsuo Makabe, and Alice W. Flaherty for their helpful comments and proofreading. Peyman Pakzaban, Timo Krings, and W. Jerry Oakes contributed photographs and clinical materials.

References

- Haglund MM, Berger MS, Shamseldin M, Lettich E, Ojemann GA. Cortical localization of temporal lobe language sites in patients with gliomas. *Neurosurgery* 1994;34:567-576
- Hinke RM, Hu X, Stillman AE, et al., Functional magnetic resonance imaging of Broca's area during internal speech. *Neuroreport* 1993;4:675-678
- Bryden MP, Steenhuis RE. Issues in the assessment of handedness. In: Kitterle FL, ed. *Cerebral Laterality*. Hillsdale, NJ: Lawrence Erlbaum Associates; 1991:35-51
- Benson RR, Logan WJ, Cosgrove GR, et al., Functional MRI localization of language in a 9-year-old child. *Can J Neurol Sci* 1996; 23:213-219
- Reese TG, Davis TL, Weisskoff RM. Automated shimming at 1.5T using echo-planar image frequency maps. *J Magn Reson Imaging* 1995;5:739-745
- Steinmetz H, Seitz RJ, Functional anatomy of language processing: neuroimaging and the problem of individual variability. *Neuropsychologia* 1991;29:1149-1161
- Petersen SE, Fox PT, Posner MI, Mintun M, Raichle ME. Positron emission tomographic studies of the processing of single words. *J Cogn Neurosci* 1989;1:153-170
- Pardo JV, Fox PT. Preoperative assessment of the cerebral hemisphere dominance for language with CBF PET. *Hum Brain Mapping* 1993;1:57-68
- Wise R, Chollet F, Hadar U, Friston K, Hoffner E, Frackowiak R. Distribution of cortical neural networks involved in word comprehension and word retrieval. *Brain* 1991;114:1803-1817

10. Press WH, Teukolsky SA, Vetterling WT, Flannery BP. *Numerical Recipes in C*. 2nd ed. Cambridge, United Kingdom: Cambridge University Press; 1992:623–629
11. Jiang A, Kennedy DN, Baker JR, et al. Motion detection and correction in functional MR imaging. *Hum Brain Mapping* 1995; 3:224–235
12. Forman SD, Cohen JD, Fitzgerald M, Eddy WF, Mintun MA, Noll DC. Improved assessment of significant activation in functional magnetic resonance imaging (fMRI): use of a cluster-size threshold. *J Magn Res Med* 1995;33:636–647
13. Friston KJ, Jezzard P, Turner R. Analysis of functional MRI time-series. *Hum Brain Mapping* 1994;1:153–171
14. Friston KJ, Worsley KJ, Frackowiak RSJ, Mazziotta JC, Evans AC. Assessing the significance of focal activations using their spatial extent. *Hum Brain Mapping* 1994;1:210–220
15. Ojemann GA. Functional mapping of cortical language areas in adults, intraoperative approaches. In: Devinsky O, Beric A, Dogali M, eds. *Electrical and Magnetic Stimulation of the Brain and Spinal Cord*. New York, NY: Raven Press; 1993:154–163
16. Ojemann GA, Sutherling WW, Lesser RP, Dinner DS, Jayakar P, Saint-Hilaire J-M. Cortical stimulation. In: Engel J Jr, ed. *Surgical Treatment of the Epilepsies*. New York, NY: Raven Press; 1993: 399–414
17. Ojemann G, Ojemann J, Lettich E, Berger M. Cortical language localization in left, dominant hemisphere: an electrical stimulation mapping investigation in 117 patients. *J Neurosurg* 1989;71: 316–326
18. Lesser RP, Luders H, Klem G, Dinner DS, Morris HH, Hahn JG. Cortical afterdischarge and functional response thresholds: results of extraoperative testing. *Epilepsia* 1984;25:615–621
19. Schaffler L, Luders HO, Beck GJ. Quantitative comparison of language deficits produced by extraoperative electrical stimulation of Broca's, Wernicke's and basal temporal language areas. *Epilepsia* 1996;37:463–475
20. Davies KG, Maxwell RE, Jennum P, et al. Language function following subdural grid-directed temporal lobectomy. *Acta Neurol Scand* 1994;90:201–206
21. Rubens AB, Mahowald MW, Hutton JT. Asymmetry of the lateral (sylvian) fissures in man. *Neurology* 1976;26:620–624
22. Wada JA, Clarke R, Hamm A. Cerebral hemispheric asymmetry in humans: cortical speech zones in 100 adults and 100 infant brains. *Arch Neurol* 1975;32:239–246
23. Steinmetz H, Ebeling U, Huang Y, Kahn T. Sulcus topography of the parietal opercular region: an anatomic and MR study. *Brain Lang* 1990;38:515–533
24. Black PM, Ronner SF. Cortical mapping for defining the limits of tumor resection. *Neurosurgery* 1987;20:914–919
25. Ojemann GA, Whitaker HA. The bilingual brain. *Arch Neurol* 1978;35:409–412
26. Rappaport RL, Tan CT, Whitaker HA. Language function and dysfunction among Chinese- and English-speaking polyglots: cortical stimulation, Wada testing and clinical studies. *Brain Lang* 1983;18:342–366
27. Ojemann GA. Brain organization for language from the perspective of electrical stimulation mapping. *Behav Brain Sci* 1983;6: 189–230
28. Mateer CA, Polen SB, Ojemann GA. Cortical localization of finger spelling and oral language: a case study. *Brain Lang* 1982;17: 46–57
29. Paradis M. Bilingualism and aphasia. *Stud Neuroling* 1977;3:65–122