

Benign versus Secondary-Progressive Multiple Sclerosis: The Potential Role of Proton MR Spectroscopy in Defining the Nature of Disability

A. Falini, G. Calabrese, M. Filippi, D. Origgi, S. Lipari, B. Colombo, G. Comi, and G. Scotti

PURPOSE: We determined the clinical utility of proton MR spectroscopy in defining the extent of disability in benign versus secondary-progressive multiple sclerosis (MS).

METHODS: Thirty patients with clinically definite MS, including 16 patients with benign MS and 14 with secondary-progressive MS, and a group of 13 healthy volunteers were studied with combined stimulated-echo acquisition mode proton MR spectroscopy and MR imaging (all patients received contrast material).

RESULTS: Acute enhancing lesions of benign and secondary-progressive MS were characterized by a reduction in *N*-acetylaspartate (NAA)/choline and NAA/creatine and an increase in inositol compounds/creatine as compared with normal white matter. Such variations were also detected in chronic unenhancing lesions in patients with secondary-progressive MS, although they were not found in chronic unenhancing lesions in patients with benign MS. Chronic lesions of the two forms of the disease have significant differences in NAA and inositol signals.

CONCLUSION: Proton MR spectroscopy is able to show metabolic changes occurring in the white matter of patients with MS. Such changes differ according to the phase (acute versus chronic) and the clinical form (benign versus secondary-progressive) of the disease.

Multiple sclerosis (MS) is a demyelinating autoimmune disorder characterized by an inflammatory process involving myelin. The clinical course of the disease can be highly variable depending on the number and severity of relapses and the degree of progression (1, 2). It is not uncommon to find clinically silent MS lesions at autopsy in some patients, whereas in others death occurs a few weeks after onset (3-5). Several patterns of the disease have been delineated. The most common classification includes benign (20%), relapsing-remitting (25%), secondary-progressive (40%), and primary-progressive (15%) forms (6). Magnetic resonance (MR) imaging is able to depict MS lesions in the spinal cord and brain with high sensitivity, but the amount of white matter involvement seen on T2-weighted MR images is poorly related to clinical disability (7). Recent studies have shown that patients with benign MS have only slightly

smaller T2 lesion loads than do patients with secondary-progressive MS (8), but these lesions display much less contrast enhancement than lesions associated with early relapsing-remitting disease (9). The lack of clinical/conventional MR imaging correlation can be better understood by considering that T2 hyperintensity is present not only in regions of demyelination or axonal loss but also in edematous, potentially reversible lesions. Even a recent brain water-diffusion study failed to show differences in the apparent diffusion coefficients between benign and secondary-progressive MS (10).

Many studies have evaluated the possibility of investigating the metabolic characteristics of MS lesions by using MR spectroscopy. The spectral patterns of acute, subacute, and chronic lesions have been described, as have several proposed markers of the demyelinating process (11-23). In this study, we used proton MR spectroscopy and MR imaging to identify metabolic changes in the lesions that might be related to MS evolution. We tested the utility of proton MR spectroscopy in differentiating lesions present in benign and in secondary-progressive MS.

Materials and Methods

Thirty patients with clinically definite MS (24) were studied: 16 had benign MS (mean age, 42 years) and 14 had secondary-

Received February 4, 1997; accepted after revision July 7.

From the Departments of Neuroradiology (A.F., G.C., D.O., S.L., G.S.) and Neurology (M.F., B.C., G.C.), Scientific Institute San Raffaele Hospital, University of Milan (Italy).

Address reprint requests to Andrea Falini, MD, Department of Neuroradiology, Scientific Institute San Raffaele Hospital, Via Olgettina 60, 20132 Milan, Italy.

Main metabolite ratios \pm SD in control subjects and in lesions in patients with benign and secondary-progressive MS

	Control Subjects (n = 13)	Patients with Benign MS		Patients with Secondary-Progressive MS	
	White Matter	Acute Lesions (n = 3)	Chronic Lesions (n = 13)	Acute Lesions (n = 5)	Chronic Lesions (n = 13)
Inositol/Cr	0.45 \pm 0.16	0.60 \pm 0.22	0.47 \pm 0.09	0.66 \pm 0.15	0.68 \pm 0.15
Cho/Cr	0.84 \pm 0.12	0.86 \pm 0.22	0.81 \pm 0.10	0.94 \pm 0.06	0.83 \pm 0.13
NAA/Cr	2.12 \pm 0.29	1.34 \pm 0.23	1.70 \pm 0.29	1.54 \pm 0.35	1.43 \pm 0.19
NAA/Cho	2.48 \pm 0.52	1.68 \pm 0.63	2.19 \pm 0.64	1.66 \pm 0.44	1.76 \pm 0.32

Note.—**Bold type** indicates differences between chronic lesions of benign and secondary-progressive MS. No corrections were made for T1 and T2 relaxation.

progressive MS (mean age, 45 years). Patients with benign MS scored 3.0 or less on the Expanded Disability Status Scale (EDSS) after a disease duration of more than 15 years (25). Patients with secondary-progressive MS had an initial relapsing-remitting course followed by progressive disability with or without superimposed relapses of at least 6 months; their mean EDSS score at the time of the study was 4.9 ± 1.4 . None of the patients was receiving treatment or had had relapses in the 6 months preceding the study. A group of 13 healthy volunteers (mean age, 41 years) served as control subjects. All patients first underwent a conventional MR imaging study with contrast material to distinguish enhancing and chronic unenhancing lesions. We studied 13 unenhancing and three enhancing lesions in the benign MS group and 13 chronic unenhancing and five enhancing lesions in the secondary-progressive MS group. Images were used to identify suitable MS lesions for spectroscopy. The MR spectroscopic study was performed 24 hours after the MR imaging examination to avoid artifacts from susceptibility associated with the contrast material. Informed consent was obtained from all subjects prior to examination.

MR imaging and MR spectroscopy were performed on a 1.5-T unit equipped with a quadrature head coil. Patients were imaged with conventional proton density- and T2-weighted spin-echo sequences (2500/15,90/1 [repetition time/echo time/excitations]) followed by a T1-weighted spin-echo (605/15/2) sequence after administration of contrast material (0.1 mmol/kg). Transverse 5-mm contiguous sections through the brain were obtained with a 256×256 matrix and a 230-cm field of view.

Single-voxel localized proton MR spectroscopy was performed using a stimulated-echo acquisition mode sequence with parameters of 1500/20. Water suppression was achieved with the chemical shift-selective (CHESS) technique (26) using three consecutive CHESS pulses centered on the water resonance. An 8-mL voxel was centered on the MS lesions of interest, which were chosen, as far as possible, to fill the spectral voxel and to avoid excessive contamination from surrounding tissue. The relative lesion size contained in the voxel was determined by considering the T2 hyperintense area on each of the 5-mm-thick images that included the voxel of interest (VOI). Small lesions, filling less than 25% of the VOI, were studied in both groups, as they are common in MS and are potentially qualitatively different from large lesions (23). A second VOI was measured in the normal-appearing white matter when present, and a third VOI was placed on the frontal interhemispheric cortex. Field homogeneity was optimized with global and local shimming. The acquired free-induction decay was multiplied with a gaussian function (center, 0 milliseconds; half-width, 256 milliseconds), Fourier-transformed with the fast Fourier transform algorithm, and phase-corrected in the zero and first orders. Peak area ratios were calculated from the integration of the single peaks obtained by manually positioning the cursor at the feet of each peak, using the standard software. For this relative peak quantification, creatine (Cr) at 3.0 ppm was taken as reference for choline-containing compounds (Cho) at 3.2 ppm and inositol compounds at 3.54, and

Cr and Cho as references for *N*-acetylaspartate (NAA) at 2.0 ppm. Spectral peak areas were analyzed independently by four spectroscopists who were blinded to the patients and to the nature of the lesions. Reliability among the four operators was tested, and the Cronbach α was greater than .91 for all the ratios considered. Mean values of the four measurements were considered for statistical analysis. Differences between patient groups and lesions were evaluated with a Student's *t* test for unpaired data.

Results

Considering all the patients together, regardless of the clinical form of their MS, lesions showed lower levels of NAA/Cr and NAA/Cho relative to normal white matter in the control subjects. When the two subgroups of patients were considered separately and compared with control subjects, the reduction of NAA was more pronounced in patients with secondary-progressive MS for both acute (NAA/Cr: *t* test = 3.58, *P* = .002; NAA/Cho: *t* test = 3.08, *P* = .007) and chronic (NAA/Cr: *t* test = 7.00, *P* = .0000004; NAA/Cho: *t* test = 4.20, *P* = .0003) lesions than for acute (NAA/Cr: *t* test = 4.32, *P* = .0008; NAA/Cho: *t* test = 2.31, *P* = .03) and chronic (NAA/Cr: *t* test = 3.61, *P* = .001; NAA/Cho: *t* test = 1.25, *P* = .22) lesions in patients with benign MS (Table).

Patients with secondary-progressive disease also had increased levels of inositol in both acute (*t* test = -2.4 , *P* = .03) and chronic (*t* test = -3.5 , *P* = .002) lesions.

No significant differences were found among the acute lesions that exhibited a similar spectral pattern in both groups (Table and Fig 1).

A significant reduction of NAA (NAA/Cr: *t* test = 2.76, *P* = .01; NAA/Cho: *t* test = 2.13, *P* = .04) and an increase of inositol/Cr (*t* test = -4.15 , *P* = .0004) were detected in the chronic lesions of patients with secondary-progressive disease as compared with the chronic lesions of patients with benign MS (see Table and Fig 2). The differences observed in chronic lesions were independent of the size of the lesions, as the percentage of small lesions (filling less than 25% of the VOI) was similar in the two groups (35.2% for the benign MS group and 21% for the secondary-progressive MS group).

Lipids at 0.9 and 1.3 ppm were detected in 37.5% of acute and in 23% of chronic lesions (Fig 1). Such percentages varied between the benign MS and the

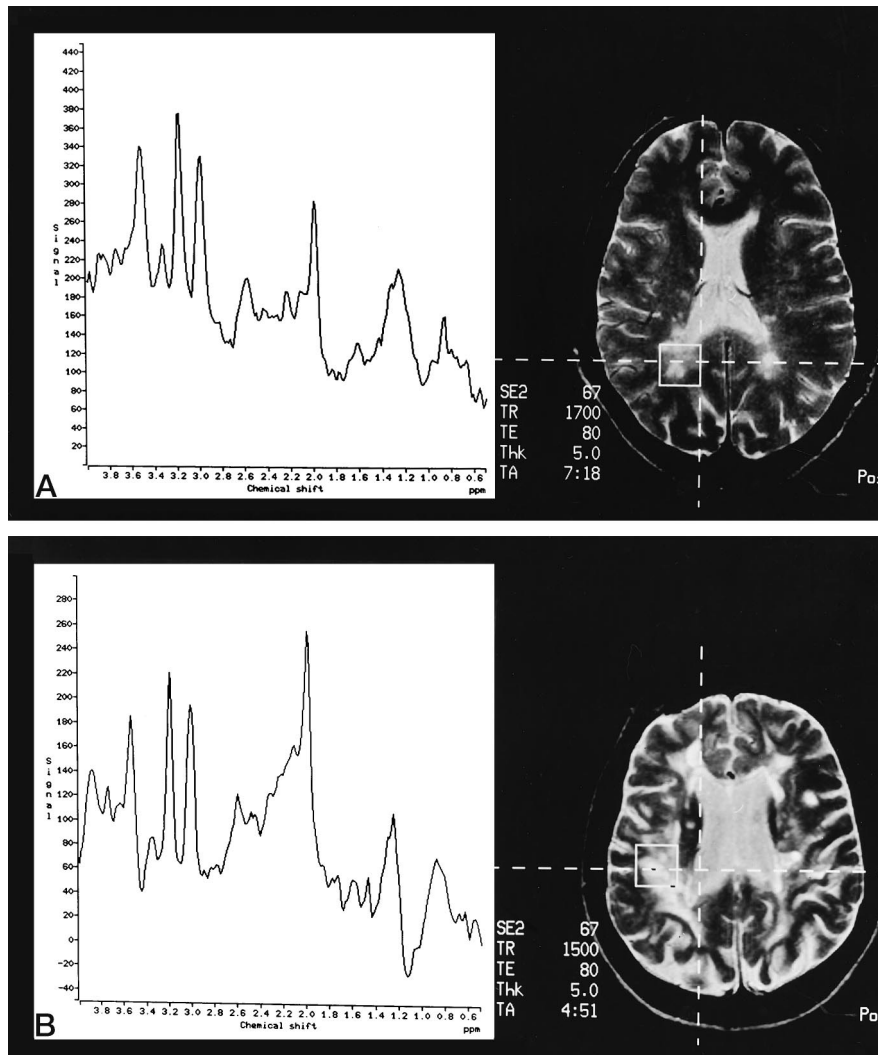


FIG 1. Proton MR spectra (1500/20) of acute lesions in patients with benign (A) and secondary-progressive (B) MS. The spectra are similar, showing a huge peak of inositol at 3.54 ppm and a reduction of the NAA peak at 2 ppm. In both cases, lipids at 1.3 ppm are present.

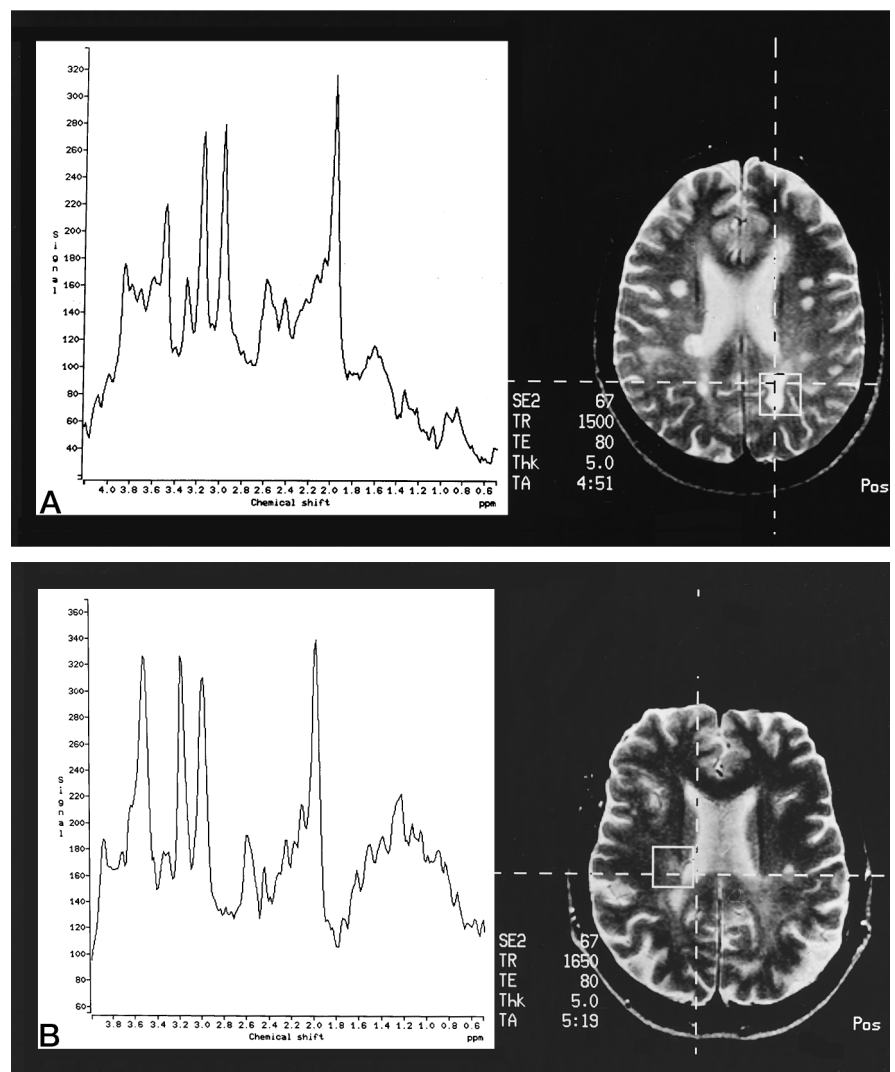
secondary-progressive MS groups, with higher values in the latter (40% of acute and 28% of chronic lesions) compared with the former (30% and 14%, respectively). Marker peaks at 2.1 to 2.6 ppm (20, 22) were not significantly different between patients and healthy volunteers.

No significant abnormalities in metabolite levels were observed in the normal-appearing white matter, although there was a trend toward an increase of Cho/Cr in benign MS (0.93 ± 0.15 , $n = 11$; t test = -0.76 , $P = .45$) and in secondary-progressive MS (0.96 ± 0.18 , $n = 4$; t test = -0.86 , $P = .40$) as well as increased inositol/Cr for secondary-progressive MS (0.61 ± 0.37 , $n = 4$; t test = -1.18 , $P = .25$). An opposite trend with a reduction of NAA levels was evident in benign MS (NAA/Cr: 1.86 ± 0.44 , $n = 11$; t test = 1.67 , $P = .11$; NAA/Cho: 2.03 ± 0.50 , $n = 11$; t test = 2.09 , $P = .04$) and in secondary-progressive MS (NAA/Cr: 2.06 ± 0.20 , $n = 4$; t test = 0.41 , $P = .69$; NAA/Cho: 2.21 ± 0.32 , $n = 4$; t test = 0.98 , $P = .34$). Finally, the spectra measured in the VOI placed in the frontal cortex of each group of patients were similar to those obtained in healthy subjects.

Discussion

Once conventional MR imaging was accepted as a fundamental tool in the diagnosis of MS, its clinical use expanded progressively, becoming exponential after the encouraging results obtained with interferon beta-1b therapy (27–29). Guidelines for the use of MR imaging in monitoring therapy have been settled and published in order to control the application of such techniques (30). After the initial enthusiasm, a general concern has arisen, based on several reports of a relatively poor relationship between MR imaging findings and the clinical parameters of MS (31). The discrepancy between MR imaging abnormalities and the clinical reality of MS patients stems from the relative lack of specificity of signal alterations on T2-weighted MR images (mainly water content variations). The inability of conventional MR to differentiate among edema, demyelination, axonal loss, and gliosis may be overcome by MR spectroscopy. A number of studies have already demonstrated that MR spectroscopy can be useful in evaluating MS lesions of different ages and at different times (11–

FIG 2. Proton MR spectra (1500/20) of chronic lesions in patients with benign (A) and secondary-progressive (B) MS. While heights of peaks are quite normal in the patient with benign MS, both the NAA peak reduction at 2 ppm and the inositol peak increase at 3.54 ppm are pronounced in the patient with secondary-progressive MS.



23). In this study, we used single-voxel proton MR spectroscopy to evaluate the metabolic pattern of lesions in patients with clinically definite benign or secondary-progressive MS.

The decision to choose a short echo-time sequence (20 milliseconds) was made so as to enhance the sensitivity of the technique toward those spectral components that we thought might be different in the two clinical forms. Among these, lipids and marker peaks were probably involved in myelin breakdown, and amino acids and inositol were possibly related to cell death.

When all patients were considered together and compared with healthy age-matched control subjects, the NAA/Cho and NAA/Cr ratios in the lesions were clearly reduced, consistent with results obtained in previous studies (11, 13–15, 17–21, 23). The observation that the magnitude of the reduction varies with the type of lesion and clinical form of the disease is more interesting. Our comparison of NAA/Cho and NAA/Cr ratios in patients with benign MS with those in control subjects showed that the reduction in NAA was more evident in acute lesions, with recovery in chronic lesions. On the other hand, in the secondary-

progressive MS group, the reduction in NAA was stable in acute and chronic lesions. These different metabolic patterns became clearer when the two groups were compared directly. In acute lesions, the metabolite ratios were not significantly different (Fig 1). In chronic lesions, the reduction of NAA/Cr and NAA/Cho predominated in the secondary-progressive MS group (Fig 2B).

In attempting to interpret the meaning of NAA reduction, it is useful to consider its biological significance and the variation of NAA concentration measured in previous studies. NAA is generally accepted as a neuronal marker, in agreement with the neuronal assignment of this metabolite shown in cell cultures and biopsy examinations (32) and further confirmed with the use of specific antibodies (33) and in clinical studies (34). A reduction of NAA levels in MS lesions was initially correlated with secondary axonal loss in chronic lesions, representing irreversible damage to the central nervous system (11). In a serial study, the same authors observed the absence of recovery of NAA at follow-up examinations (18). Van Hecke et al (17) suggested that an NAA decrease could reflect the gliosis that accompanies the process of demyelination.

nation subsequent to the initial focal inflammatory reaction with lymphocytic infiltration. Matthews et al (14) introduced the concept of axonal injury in addition to irreversible axonal degeneration, and underlined the fact that signal at 2.01 ppm includes contributions from *N*-acetylated groups other than those of NAA. The same concept of axonal sufferance was cited by Miller et al (15), who suggested that the slight NAA reduction observed in acute lesions could reflect a less severe axonal loss or axonal shrinkage caused by demyelination, inflammatory edema, or, perhaps, axonal dysfunction. The progressive change in the interpretation of NAA signal parallels results indicating that the reduction of this metabolite is reversible. Davie et al (21) described the reversibility of NAA/Cr reduction, postulating that edema and impaired function of mitochondria in the acute phase are responsible for the NAA decrease and the presence of oligodendrocyte type 2 astrocyte progenitor cells containing NAA, which promote remyelination for reversibility. An analogous recovery of NAA signal was described by De Stefano et al (35), who found a high correlation with a decrease in the volume of brain lesions in all patients during the follow-up period, and a strong correlation between a decrease in EDSS score and recovery of NAA resonance intensities. The results of these recent studies are in agreement with our observations. When we looked at acute lesions we did not find significant differences between benign MS and secondary-progressive MS. This suggests that in the acute phase, the NAA signal reduction is relatively nonspecific, resembling T2 hyperintensity on conventional MR images. Edema with inflammatory elements, demyelination, neuronal dysfunction, and axonal destruction can all cause NAA depletion. Measurements made in chronic lesions in patients with benign MS show evidence of recovery of NAA/Cho and NAA/Cr (Fig 2A); these lesions show no significant reduction in NAA/Cr and NAA/Cho ratios relative to those of healthy volunteers. This recovery of NAA may be attributed to an absence of inflammatory processes and/or to remyelination. In patients with secondary-progressive MS, NAA levels are still depressed in chronic lesions, suggesting the irreversible loss of integrity of axons, possibly associated with gliosis.

The differences in NAA levels noted between the two forms of MS are supported by the coherent variations of inositol at 3.54 ppm. Inositol was elevated in lesions of both benign and secondary-progressive forms of MS during the acute phase (Fig 1), whereas chronic lesions were characterized by high inositol levels only in the secondary-progressive group (Fig 2B). The pattern of inositol level observed in benign MS with higher values in acute lesions than in chronic lesions is in agreement with the study by De Stefano et al (35), who observed increased inositol in acute lesions that returned to normal levels at follow-up, correlating with reduced volume of the plaques. On the other hand, in patients with secondary-progressive MS, inositol increase was stable in both acute and chronic stages.

Although the real meaning of inositol variations in MS remains unclear (36, 37), recent studies have underlined the importance of these factors in maintaining neuroglial cell homeostasis (38–42). Moreover, multinuclear spectroscopy performed in rats indicates that neuroglial cells have a higher inositol content as compared with neurons (43). It is possible that in acute lesions, glial cell damage and/or edema might account for inositol increase, owing to the respective release or intracellular accumulation of such factors. On the other side, gliosis could be consistent with the constant high inositol value in chronic lesions of the secondary-progressive group. In this view, the combined metabolic variations of inositol and NAA are the best discriminators between benign MS and secondary-progressive MS lesions. The return of both metabolites to normal values in the chronic lesions of patients with benign MS suggests cell damage that is still susceptible to partial recovery, whereas the persistent NAA reduction and inositol increase in patients with secondary-progressive MS might suggest a definitive neuronal loss, which correlates well with severe disability.

The differences observed in chronic plaques in the two groups of patients were independent of the size of the lesions measured. The frequency of lesions that filled less than 25% of the VOI was similar in both populations. Moreover, Van Hecke et al (17) and more recently Roser et al (23) and De Stefano et al (35) demonstrated that metabolic variations measured in MS lesions are not confined to the area shown by MR imaging but involve surrounding tissue. However, involvement of the normal-appearing white matter in our study is only partially confirmed. In fact, comparing the metabolic ratios measured in normal-appearing white matter with those in healthy volunteers, we noted a trend toward an increase of Cho/Cr and inositol/Cr (only in secondary-progressive MS) and a decrease of NAA/Cho that did not reach statistical significance.

As far as specific markers of the demyelinating process are concerned, our results are not conclusive. We detected the presence of peaks at 1.3 and 0.9 ppm, assigned, respectively, to the methylene and methyl groups of lipids (44) in only 37.5% of acute enhancing lesions (30% in benign MS and 40% in secondary-progressive MS) (Fig 1) and in 23% of chronic unenhancing lesions (28% in benign MS and 14% in secondary-progressive MS). However, in the remaining acute lesions, and in particular in the remaining 60% of secondary-progressive MS lesions, where demyelination might more likely be present, no lipid peaks were seen.

Similarly, observation of the spectral area, which comprised 2.1 to 2.6 ppm, where demyelination marker peaks were reported (20, 22), was unsatisfactory. The lack of absolute quantitation of metabolites and the presence of a high standard deviation (mainly due to the difficulties related to precise peak assignment in this area) decreased the reliability of the apparently normal values obtained.

Finally, the absence of variation in the spectra mea-

sured in the frontal gray matter of patients with MS suggests a greater involvement of neural connection than the primitive neuronal loss responsible for mental deterioration frequently observed in more compromised patients (45–48).

Conclusions

Proton MR spectroscopy is able to show metabolic changes in the white matter of patients with MS. Such changes differ according to the phase (acute versus chronic) and the clinical form (benign versus secondary-progressive) of the disease. A comparison of chronic lesions in benign MS with those in secondary-progressive MS reveals significant differences in NAA/Cr, NAA/Cho, and inositol/Cr ratios, suggesting a potential clinical role for MR spectroscopy in contributing to the identification of the pathologic substrate of the lesions of differently disabling forms of MS.

Acknowledgments

We thank Sarah J. Nelson for critical review of the manuscript and Suzanne E. Anderson for her helpful advice.

References

- Sadiq SA, Miller JR. **Multiple sclerosis, Devic syndrome and Balo disease.** In: Rowland LP, ed. *Meritt Textbook of Neurology*. 9th ed. Baltimore, Md: Williams & Wilkins; 1995:804–826
- Adams RD, Victor M. **Multiple Sclerosis and allied demyelinating diseases.** In: Adams RD, Victor M, eds. *Principles of Neurology*. 5th ed. New York, NY: McGraw-Hill; 1993:776–798
- Marburg O. **Die sogenannte "akute multiple sklerosis" (encephalomyelitis periaipicalis scleroticans).** *J Psychiatr Neurol* 1906;27:211–312
- Johnson MD, Lavin P, Whetsell WO Jr. **Fulminant monophasic multiple sclerosis, Marburg's type.** *J Neurol Neurosurg Psychiatry* 1990;53:918–921
- Niebler G, Harris T, Davis T, Ross K. **Fulminant multiple sclerosis.** *AJNR Am J Neuroradiol* 1992;13:1547–1551
- Lublin FD, Reigold SC, for the National Multiple Sclerosis Society (USA) Advisory Committee on Clinical Trials of New Agents in Multiple Sclerosis. **Defining the clinical course of multiple sclerosis: results of an international survey.** *Neurology* 1996;46:907–911
- Koopmans RA, Li DKB, Grochowsky E, Cutler PJ, Paty DW. **Benign versus chronic progressive multiple sclerosis: magnetic resonance imaging features.** *Ann Neurol* 1989;25:74–81
- Filippi M, Campi A, Mammì S, et al. **Brain magnetic resonance imaging and multimodal evoked potentials in benign and secondary progressive multiple sclerosis: a follow up study.** *J Neurol Neurosurg Psychiatry* 1995;58:31–37
- Kidd D, Thompson AJ, Kendall BE, Miller DH, McDonald WI. **Benign form of multiple sclerosis: MRI evidence for less frequent and less inflammatory disease activity.** *J Neurol Neurosurg Psychiatry* 1994;57:1070–1072
- Horsfield MA, Lai M, Webb SL, et al. **Apparent diffusion coefficients in benign and secondary progressive multiple sclerosis by nuclear magnetic resonance.** *Magn Reson Med* 1996;36:393–400
- Arnold DL, Matthews PM, Francis G, Antel J. **Proton magnetic resonance spectroscopy of human brain in vivo in the evaluation of multiple sclerosis: assessment of the load of disease.** *Magn Reson Med* 1990;14:154–159
- Wolinsky JS, Narayana PA, Fenstermacher MJ. **Proton magnetic resonance spectroscopy in multiple sclerosis.** *Neurology* 1990;40:1764–1769
- Larsson HB, Christiansen P, Jensen M, et al. **Localized in vivo proton spectroscopy in the brain of patients with multiple sclerosis.** *Magn Reson Med* 1991;22:23–31
- Matthews PM, Francis MD, Antel J, Arnold DL. **Proton magnetic resonance spectroscopy for metabolic characterization of plaques in multiple sclerosis.** *Neurology* 1991;41:1251–1256
- Miller DH, Austin SJ, Connelly A, Youl BD, Gadian DG, McDonald WI. **Proton magnetic resonance spectroscopy of an acute and chronic lesion in multiple sclerosis.** *Lancet* 1991;337:58–59
- Richards TL. **Proton MR spectroscopy in multiple sclerosis: value in establishing diagnosis, monitoring progression, and evaluating therapy.** *AJR Am J Roentgenol* 1991;157:1073–1078
- Van Hecke P, Marchal G, Johannik K, et al. **Human brain proton localized NMR spectroscopy in multiple sclerosis.** *Magn Reson Med* 1991;18:199–206
- Arnold DL, Matthews PM, Francis GS, O'Connor J, Antel J. **Proton magnetic resonance spectroscopic imaging for metabolic characterization of demyelinating plaques.** *Ann Neurol* 1992;31:235–241
- Bruhn H, Frahm J, Merboldt KD, et al. **Multiple sclerosis in children: cerebral metabolic alterations monitored by localized proton magnetic resonance spectroscopy in vivo.** *Ann Neurol* 1992;32:140–150
- Grossman RI, Lenkiski RE, Ramer KN, Gonzalez-Scarano F, Cohen JA. **MR proton spectroscopy in multiple sclerosis.** *AJNR Am J Neuroradiol* 1992;13:1535–1543
- Davie CA, Hawkins CP, Barker CJ, et al. **Serial proton magnetic resonance spectroscopy in acute multiple sclerosis lesions.** *Brain* 1994;117:49–58
- Hiehle JF, Lenkiski RE, Grossman RI, et al. **Correlation of spectroscopy and magnetization transfer imaging in the evaluation of demyelinating lesions and normal appearing white matter in multiple sclerosis.** *Magn Reson Med* 1994;32:285–293
- Roser W, Hagberg G, Mader I, et al. **Proton MRS of gadolinium-enhancing MS plaques and metabolic changes in normal-appearing white matter.** *Magn Reson Med* 1995;33:811–817
- Poser CM, Paty DW, Scheinberg L, et al. **New diagnostic criteria for multiple sclerosis: guidelines for research protocols.** *Ann Neurol* 1983;13:227–231
- Kurtze JF. **Rating neurological impairment in multiple sclerosis: an expanded disability status scale (EDSS).** *Neurology* 1983;33:1442–1452
- Haase A, Frahm J, Haenicke W, Matthei D. **¹H NMR chemical shift selective (CHESS) imaging.** *Phys Med Biol* 1985;30:341–344
- The IFNB Multiple Sclerosis Study Group. **Interferon beta-1b is effective in relapsing-remitting multiple sclerosis.** *Neurology* 1993;43:655–661
- Paty DW, Li DKB, UBC MS/MRI Study Group, IFNB Multiple Sclerosis Study Group. **Interferon beta-1b is effective in relapsing-remitting multiple sclerosis. II: MRI analysis results of a multicenter, randomized, double-blind, placebo-controlled trial.** *Neurology* 1993;43:662–667
- The IFNB Study Group, University of British Columbia MS/MRI Analysis Group. **Interferon beta-1b in the treatment of multiple sclerosis: final outcome of the randomized, controlled trial.** *Neurology* 1995;45:1277–1285
- Miller DH, Barkhof F, Berry I, et al. **Magnetic resonance imaging in monitoring the treatment of multiple sclerosis: concerted action guidelines.** *J Neurol Neurosurg Psychiatry* 1991;54:683–688
- Miller DH, Albert PS, Barkhof F, et al. **Guidelines for the use of magnetic resonance techniques in monitoring the treatment of multiple sclerosis.** *Ann Neurol* 1996;39:6–16
- Nadler JV, Cooper JR. **N-acetyl-L-aspartic acid content of human neural tumors and bovine peripheral nervous tissue.** *J Neurochem* 1972;19:313–319
- Simmons ML, Frondoza CG, Coyle JT. **Immunocytochemical localization of N-acetyl-aspartate with monoclonal antibodies.** *Neuroscience* 1991;45:37–45
- Hanstock CC, Rothman DL, Prichard JW, Jue T, Shulman RG. **Spatially localized ¹H NMR spectra of metabolite in the human brain.** *Proc Natl Acad Sci* 1988;85:1821–1825
- De Stefano N, Matthews PM, Antel JP, Preul M, Francis G, Arnold LA. **Chemical pathology of acute demyelinating lesions and its correlation with disability.** *Ann Neurol* 1995;38:901–909
- Tzika AA, Ball WS, Vigneron DB, Scott Dunn R, Kirks DR. **Clinical proton MR spectroscopy of neurodegenerative disease in childhood.** *AJNR Am J Neuroradiol* 1993;4:1267–1281
- Ross BD. **Biochemical consideration in ¹H spectroscopy: glutamate and glutamine; myo-inositol and related metabolites.** *NMR Biomed* 1991;4:59–62
- Murphy S. **Astrocytes: Pharmacology and Function.** San Diego, Calif: Academic Press; 1993
- Lien HH, Shapiro JL, Chan L. **Effects of hypernatremia on organic brain osmolytes.** *J Clin Invest* 1990;85:1427–1435
- Graf J, Guggino WB, Turnheim K. **Volume regulation in trans-**

- porting epithelia. In: Lang F, Haussinger D, eds. *Interactions in Cell Volume and Cell Function*. Heidelberg, Germany: Springer-Verlag; 1993:67-117
41. Kimelberg HK, O'Connor ER, Kettenmann H. **Effect of swelling on glial cell function.** In: Lang F, Haussinger D, eds. *Interactions in Cell Volume and Cell Function*. Heidelberg, Germany: Springer-Verlag; 1993:158-186
 42. Laubenberger J, Haussinger D, Bayer S, et al. **HIV-related metabolic abnormalities in the brain: depiction with proton MR spectroscopy with short echo times.** *Radiology* 1996;199:805-810
 43. Brand A, Richter-Landsberg C, Leibfritz D. **Multinuclear NMR studies on the energy metabolism of glial and neurons cells.** *Dev Neurosci* 1993;15:289-298
 44. May GL, Wright LC, Holmes KT, Williams PG, Smith ICP, Wright PE. **Assignment of methylene proton resonances in NMR spectra of embryonic and transformed cells to plasma membrane triglyceride.** *J Biol Chem* 1986;261:3048-3053
 45. Feinstein A, Kartsounis LD, Miller DH, Youl BD, Ron MA. **Clinically isolated lesions of the type seen in multiple sclerosis: a cognitive, psychiatric, and MRI follow up study.** *J Neurol Neurosurg Psychiatry* 1992;55:869-876
 46. Millefiorini E, Padovani A, Pozzilli C, et al. **Depression in the early phase of MS: influence of functional disability, cognitive impairment and brain abnormalities.** *Acta Neurol Scand* 1992;86:354-358
 47. Møller A, Wiedemann G, Rohde U, Backmund H, Sonntag A. **Correlates of cognitive impairment and depressive mood disorder in multiple sclerosis.** *Acta Psychiatr Scand* 1994;89:117-121
 48. Comi G, Filippi M, Martinelli V, et al. **Brain MRI correlates of cognitive impairment in primary and secondary progressive multiple sclerosis.** *J Neurol Sci* 1995;132:222-227