
MR Findings in Methanol Intoxication

H. Penney Gaul, Carla J. Wallace, Roland N. Auer, and T. Chen Fong

Summary: We report the MR and CT findings with pathologic correlation in a case of severe methanol intoxication. There was bilateral hemorrhagic necrosis of the putamen and caudate nuclei and, in addition, extensive subcortical necrosis and symmetric bilateral necrosis of the pontine tegmentum and optic nerves, which may indicate poor prognosis.

Index term: Brain, effects of toxic substances on

Case Report

A 51-year-old man was found unresponsive at home. Before his arrival from a peripheral hospital, he had two generalized seizures and required intubation and mechanical ventilation. There was no known period of respiratory or cardiac arrest.

On admission, he was unresponsive and had a score of 3 on the Glasgow coma scale. Blood methanol level, measured approximately 6 hours after being found, was 95 mmol/L, indicative of severe intoxication. Ethanol and ethylene glycol levels were undetectable. His pH was 6.87. He was treated with an ethanol drip and hemodialysis until his methanol level was 0, with only marginal improvement in his clinical status.

Nonenhanced computed tomography (CT) at the time of admission (not shown) showed hypodensity in the putamina and left caudate nucleus and ill-defined frontal lobe white matter hypodensity. CT on day 4 (Fig 1A) demonstrated massive deep cortical/subcortical white matter hypodensity and diffuse brain edema in addition to the striatal hypodensities. Magnetic resonance (MR) performed on day 5 showed hyperintensity on the T1-weighted images in the striatum consistent with hemorrhagic necrosis. T2-weighted images (Fig 1B) showed extensive hyperintensity in the peripheral subcortical and deep cortical regions as well as diffuse brain swelling. Foci of T2 hyperintensity in the pontine tegmentum bilaterally (Fig 1C), cerebellar white matter, and optic nerves (Fig 1D) also were noted.

The patient died several hours after MR imaging. Neuropathologic examination revealed disseminated foci of

necrosis in the cerebral cortex, subcortical white matter, and striatum (Fig 1E). In addition, symmetric bilateral necrosis was seen in the posterior aspects of the pontine tegmentum bilaterally, just medial to the superior cerebellar peduncles (Fig 1F). Symmetric necrosis was evident in both optic nerves just behind the lamina cribrosa (Fig 1G) and in the striatum. The cortical, subcortical, and striatal necrosis was hemorrhagic, whereas the necrosis of the optic nerves and pontine tegmentum was not.

Discussion

This case compares the MR and pathologic findings of bilateral hemorrhagic necrosis in the putamen and caudate nuclei, diffuse subcortical white and grey matter necrosis, cerebellar and optic nerve necrosis, and diffuse cerebral edema in a patient with severe methanol intoxication. It also demonstrates bilaterally symmetric tegmental necrosis, which, in addition to the striatal and optic nerve lesions, indicates the propensity of methanol intoxication to produce remarkable symmetric necrosis in specific brain regions. The basis for the selective vulnerability in these regions remains unknown, although the nature of the distribution in the optic nerves, caudate nuclei, putamen, and pontine tegmentum is counterevidence of a vascular cause. The lesions seen in the pontine tegmentum are not a feature of anoxic/ischemic brain damage.

The imaging findings of bilateral putaminal hemorrhagic necrosis, cerebral and intraventricular hemorrhage, cerebellar necrosis, and diffuse cerebral edema all have been described as sequelae of severe methanol intoxication (1-7). Bilateral subcortical white matter necrosis seen on CT also has been reported with

Received December 8, 1994; accepted after revision March 3, 1995.

From the Departments of Radiological Sciences and Diagnostic Imaging (H.P.G., C.J.W., T.C.F.) and Pathology (R.N.A.), Foothills Hospital, Calgary, Alberta, Canada.

Address reprint requests to Dr Carla J. Wallace, Department of Radiologic Sciences and Diagnostic Imaging, Foothills Hospital, 1403-29 St NW, Calgary, Alberta T2N 2T9, Canada.

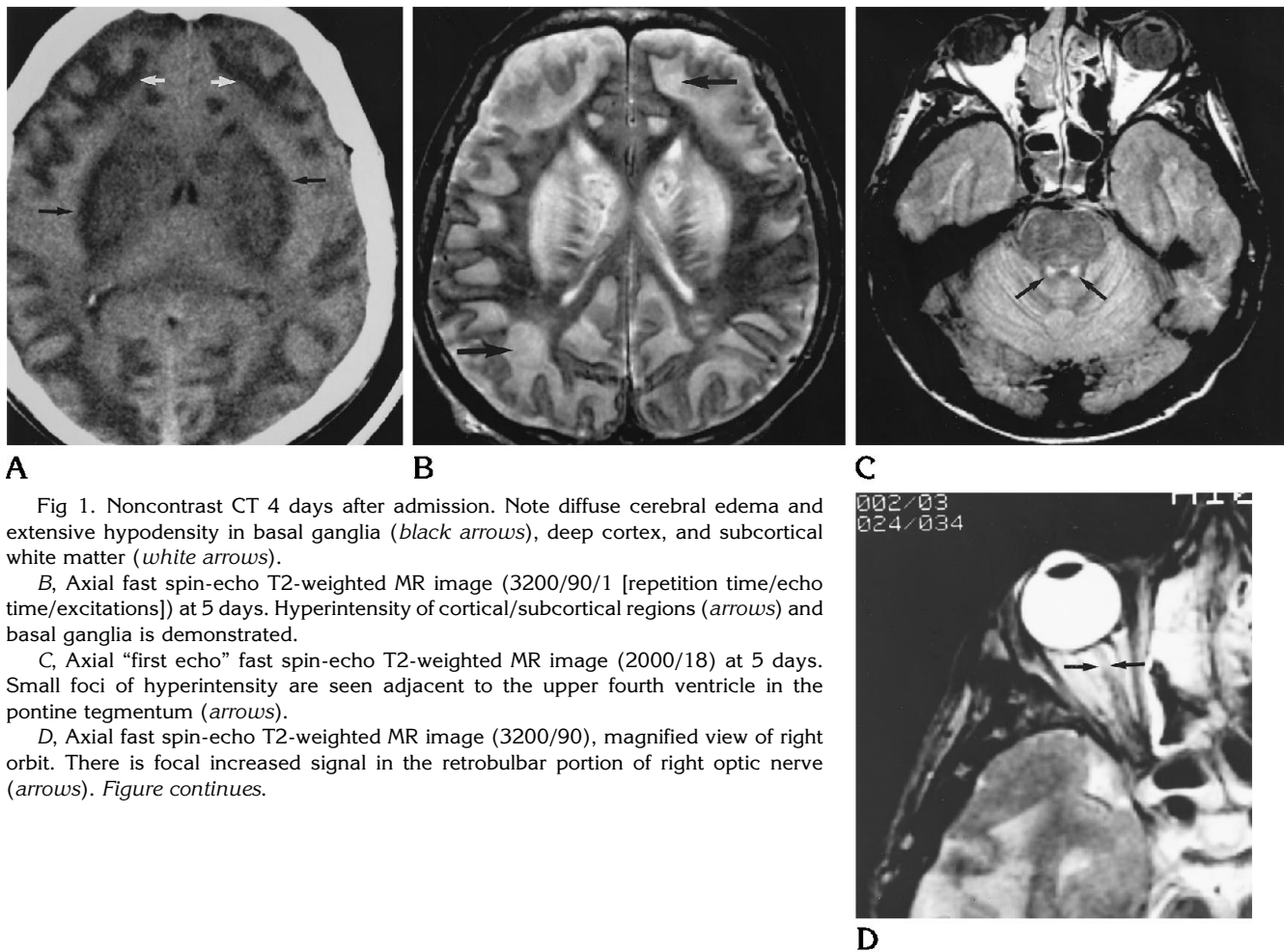


Fig 1. Noncontrast CT 4 days after admission. Note diffuse cerebral edema and extensive hypodensity in basal ganglia (*black arrows*), deep cortex, and subcortical white matter (*white arrows*).

B, Axial fast spin-echo T2-weighted MR image (3200/90/1 [repetition time/echo time/excitations]) at 5 days. Hyperintensity of cortical/subcortical regions (*arrows*) and basal ganglia is demonstrated.

C, Axial "first echo" fast spin-echo T2-weighted MR image (2000/18) at 5 days. Small foci of hyperintensity are seen adjacent to the upper fourth ventricle in the pontine tegmentum (*arrows*).

D, Axial fast spin-echo T2-weighted MR image (3200/90), magnified view of right orbit. There is focal increased signal in the retrobulbar portion of right optic nerve (*arrows*). *Figure continues.*

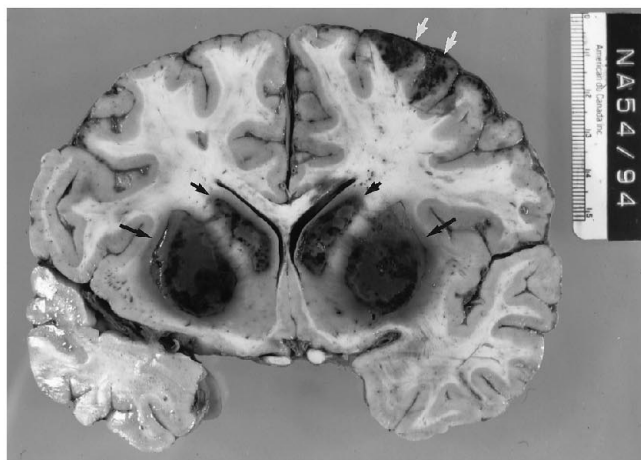
acute methanol toxicity (5, 8); other reports interpret cerebral white matter alterations as edema (1-3).

The white matter changes with methanol intoxication also may be fairly specific in location. It is probable that direct toxic effects of methanol metabolites also were responsible for the extensive cortical/subcortical, tegmental, and optic nerve necrosis seen in this patient. Another possible cause of the diffuse cortical/subcortical necrosis is ischemia secondary to cardiac arrest. However, a period of global ischemia was not documented in this patient.

Optic nerve demyelination (without axonal loss) secondary to the myelinoclastic effect of formic acid has been suggested by Sharpe et al (9) as the explanation for optic nerve damage. However, extensive demyelination may itself

give rise to secondary axonal digestion. In fact, Bielschowsky staining in Sharpe's case and in our patient showed evidence of digested axons indicative of more severe damage than merely demyelination after methanol ingestion.

Methanol is most commonly ingested intentionally as a substitute for alcohol or as a suicide attempt. It is found in many easily available commercial products such as windshield wiper fluid, gasoline antifreeze, paint remover, and photocopying fluid. The presence of the toxic metabolites of methanol, namely formaldehyde and formic acid, in addition to the severe metabolic acidosis is felt to be responsible for the basal ganglionic changes; the fundamental mechanism of selective vulnerability is unknown. It has been suggested that heparinization during hemodialysis may contribute to



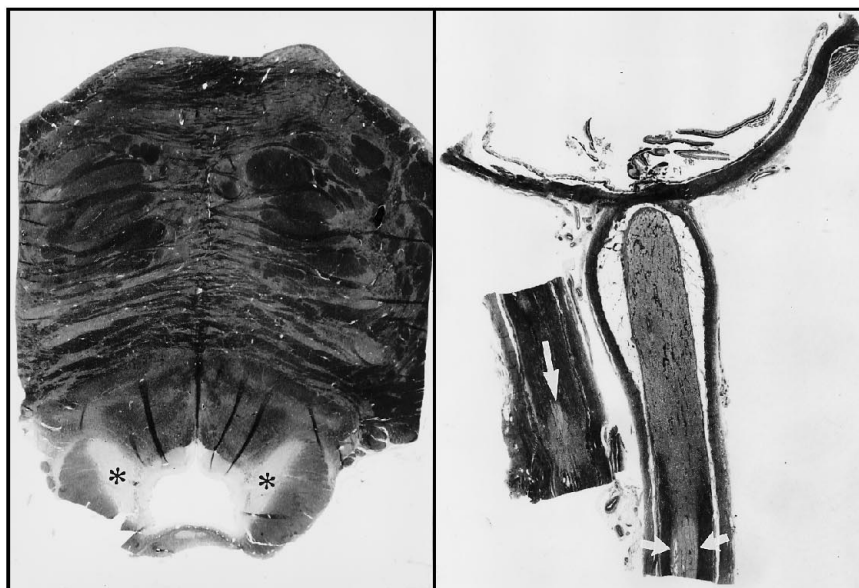E

Fig 1, continued.

E, Coronal section of the cerebral hemispheres shows dark, hemorrhagic necrosis in the caudate nucleus (*small black arrows*) and putamen bilaterally (*large black arrows*) and in the neocortex on the left (*white arrows*).

F, The pons shows symmetric areas of coagulative necrosis (*asterisks*) in the dorsolateral tegmentum.

G, Posterior portion of the globe and retrobulbar portion of the optic nerve. Only the central portion of the optic nerve is demyelinated at a distance from the globe (*small arrows*) but behind the orbit the entire nerve shows degeneration nearer the lamina cribrosa. A more posterior segment of nerve (*left*) shows only patchy demyelination (*large arrow*).



F

G

hemorrhage or hemorrhagic transformation of necrosis (4). Putaminal changes on MR imaging are not specific to methanol intoxication and have been described in various sporadic and familial neurodegenerative disorders and in Wilson disease (3) and hypoxic/ischemic injury (10).

With the increasing use of MR imaging in the evaluation of the unconscious patient, it is important to be able to recognize findings that suggest certain causes, specifically toxins. The imaging findings of hemorrhagic putaminal ne-

erosis with severe methanol intoxication have been well described (1-5, 7). The additional descriptions of lesions in subcortical white matter, tegmentum, and optic nerve may increase the detection and characterization of methanol intoxication and prompt appropriate toxic screens and early aggressive treatment. The presence of hemorrhagic necrosis in the putamen has been suggested to indicate poor prognosis (7). These subcortical white matter changes, tegmental changes, and optic nerve findings also may indicate poor prognosis.

References

1. Glazer M, Dross P. Necrosis of the putamen caused by methanol intoxication: MR findings. *AJR Am J Roentgenol* 1993;160:1105-1106
2. Koopmans RA, Li DKB, Paty DW. Basal ganglia lesions in methanol poisoning: MR appearance. *J Comput Assist Tomogr* 1988;12:168-169
3. Chen JC, Schneiderman JF, Wortzman G. Methanol poisoning: bilateral putaminal and cerebellar cortical lesions on CT and MR. *J Comput Assist Tomogr* 1991;15:522-524
4. Phang PT, Passerini L, Mielke B, Berendt R, King EG. Brain hemorrhage associated with methanol poisoning. *Crit Care Med* 1988;16:137-140
5. Hsieh FY, Leu TM, Chia LG. Bilateral putaminal necrosis caused by methanol poisoning: a case report. *Chin Med J (Taipei)* 1992;49:283-288
6. Mascalchi M, Dal Pozzo GC, Pinto F. MRI demonstration of the cerebellar damage in diffuse hypoxic-ischemic encephalopathy: case report. *Ital J Neurol Sci* 1992;13:517-519
7. Aquilonius SM, Bergström K, Enoksson P, et al. Cerebral computed tomography in methanol intoxication. *J Comput Assist Tomogr* 1980;4:425-428
8. McLean DR, Jacobs H, Mielke BW. Methanol poisoning: a clinical and pathological study. *Ann Neurol* 1980;8:161-167
9. Sharpe JA, Hostovsky M, Bilbao JM, Rewcastle NB. Methanol optic neuropathy: a histopathologic study. *Neurology* 1982;32:1093-1100
10. Birbamer G, Aichner F, Felber S, et al. MRI of cerebral hypoxia. *Neuroradiology* 1991;33S:53-55