

Intracranial Tuberculoma: Comparison of MR with Pathologic Findings

Tae Kyoung Kim, Kee Hyun Chang, Chong Jai Kim, Jin Mo Goo, Myeong Cheri Kook, and Moon Hee Han

PURPOSE: To compare the MR signal intensity patterns and enhancement pattern of intracranial tuberculomas with their histopathologic features. **METHODS:** MR images of six patients with surgically proved intracranial tuberculoma were reviewed retrospectively and were compared with histologic findings of the resected specimen. Detailed histologic examination was performed to look for the extent and characteristics of caseation necrosis, fibrosis, and inflammatory cellular infiltrates at each area of different signal intensities and at the enhancing areas on MR. Signal intensities for T1- and T2-weighted images were compared with normal gray matter. **RESULTS:** On T1-weighted images, the granulomas showed a slightly hyperintense rim surrounded by a complete or partial rim of slight hypointensity and central isointensity or mixed isointensity and hyperintensity in five patients and homogeneous isointensity in one patient. Histologically, the zone of central isointensity or mixed intensity corresponded to caseation necrosis plus adjacent cellular infiltrates. The hyperintense and hypointense rims corresponded to the layers of collagenous fiber and the layers of the inflammatory cellular infiltrates, respectively. On T2-weighted images, the entire portion of the granuloma showed slightly heterogeneous isointensity or hypointensity with small markedly hypointense foci in five patients, and a hyperintense center surrounded by a hypointense rim in one patient. Histologic layers were not discriminated on T2-weighted images. On postcontrast T1-weighted images, there were single or multiple conglomerate ring enhancements within a tuberculoma in all six patients, corresponding to the layers of both collagenous and inflammatory cells. **CONCLUSION:** Combination of the described signal intensity patterns and conglomerate ringlike enhancing appearance of the lesion is characteristic of tuberculoma, and may play an important role in differentiating intracranial tuberculomas from other ring-enhancing brain lesions.

Index terms: Brain, magnetic resonance; Tuberculoma

AJNR Am J Neuroradiol 16:1903–1908, October 1995

Central nervous system tuberculosis is an infectious disease process that continues to be a prevalent endemic problem in certain world regions. In recent times, the incidence of tuberculosis has been on the rise because of the increased incidence of acquired immunodeficiency syndrome (1, 2). Intracranial tuberculo-

mas are space-occupying masses of granulomatous tissue that result from hematogenous spread from a distant focus of tuberculous infection. Histologically, the mature tuberculomas are composed of a necrotic caseous center surrounded by a capsule that contains fibroblasts, epithelioid cells, Langhans giant cells, and lymphocytes (3). The magnetic resonance (MR) appearances of intracranial tuberculoma have been well documented in the literature (4–7); tuberculoma has been known to be usually isointense relative to gray matter on both T1- and T2-weighted images and to appear as a conglomerated ring-enhancing mass on gadolinium-enhanced T1-weighted images. Even though comparison of the MR signal intensity with histopathology has been reported in the literature (7), this study has not compared all

Supported in part by a grant from Seoul National University Hospital Research Fund, 1995.

Received February 2, 1995; accepted after revision May 18.

From the Departments of Diagnostic Radiology (T.K.K., K.H.C., J.M.G., M.H.H.) and Pathology (C.J.K., M.C.K.), Seoul National University College of Medicine, Korea.

Address reprint requests to Kee Hyun Chang, MD, Department of Diagnostic Radiology, Seoul National University Hospital, 28, Yongon-dong, Chongno-gu, Seoul 110-744, Korea.

AJNR 16:1903–1908, Oct 1995 0195-6108/95/1609–1903

© American Society of Neuroradiology

MR-observed layers of different signal intensities. The purpose of this study was to compare MR features of intracranial tuberculomas in a series of six surgically proved cases with corresponding histopathologic features.

Subjects and Methods

Six female patients, 21 to 45 years of age, with surgically proved intracranial tuberculomas were retrospectively included in this study. Pulmonary tuberculosis also was present in all six, and spinal tuberculosis was present in one.

MR imaging was performed with a 2.0-T scanner in five, and with a 1.5-T scanner in one. With a head coil (diameter, 30 cm), all images were obtained by using spin-echo pulse sequences and a two-dimensional Fourier transform image reconstruction. T1-weighted spin-echo (500–600/20–30/2–4 [repetition time/echo time/excitations]), proton- and T2-weighted spin-echo (2500–3000/30, 80/1), and postcontrast T1-weighted images after intravenous injection of gadopentetate dimeglumine (0.1 mmol/kg body weight) were obtained in all patients. The section thickness/gap was 8 mm/2 mm in T1-weighted images, and 5 to 6 mm/1 to 2 mm in proton- and T2-weighted images. The images were acquired on a 256 × 256 matrix, with field of view of 25 cm.

The MR studies were retrospectively reviewed and evaluated for the signal intensity of the granuloma compared with cerebral gray matter on T1- and T2-weighted images and the extent of enhancement.

All pathologic specimens were obtained from open excisional biopsy. The resected specimens were 10 to 30 mm and had a slightly lobulated contour. Histologically, they consisted of coalescent granulomas containing central caseation necrosis surrounded by a zone of fibrosis and inflammatory cells. On microscopic examination, each tuberculoma was arbitrarily divided into three layers, which appeared to conform to different signal intensities on MR by consensus of one pathologist (C.J.K.) and two radiologists (K.H.C., T.K.K.). The inner layer was composed of central caseation necrosis with a variable amount of nuclear debris and adjacent inner inflammatory cellular infiltrates. The middle layer was composed of hyaline collagenous connective tissue. The outer layer was composed of outer inflammatory cellular infiltrates of epithelioid cells and lymphocytes.

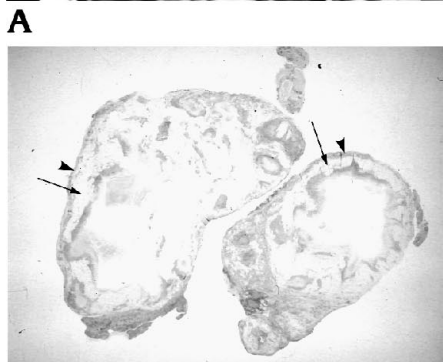
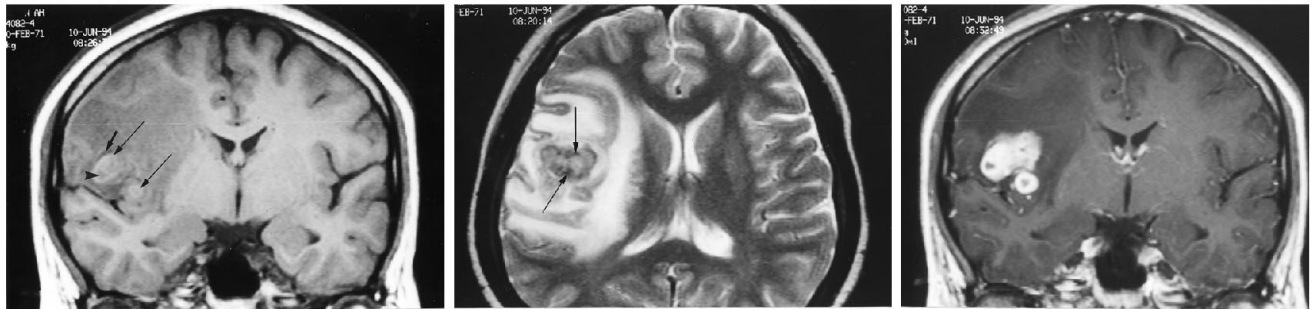
Results

The tuberculoma was located at the subcortical area of the cerebral hemisphere in five patients, and in the cerebellum in one. The tuberculomas were approximately 12 × 12 to 23 × 25 mm in size and showed a lobulated contour of varying degrees on MR. Grossly, these appearances generally matched the gross specimens.

On the T1-weighted images, the lesions had a thick rim of slight hyperintensity compared with normal gray matter with surrounding complete (n = 2) or partial (n = 3) rim of slight hypointensity. The central portion of the lesion displayed isointensity (n = 3) or mixed isointensity and slight hyperintensity (n = 2) in five patients (Figs 1 and 2), and showed homogeneous isointensity in one patient (Fig 3). Histologically, the hyperintense rim corresponded to the layer of collagenous fibers, and the hypointense rim corresponded to the layer of outer inflammatory cellular infiltrates, which was composed of epithelioid cells and lymphocytes. The central isointense or mixed intense portions reflected the caseation necrosis with lining of inflammatory cellular infiltrates. In one patient, in whom no discernible layering appearance is shown on MR, the specimen consisted of aggregates of multiple variable-sized tubercles, each containing all three layers on microscopic examination (Fig 3).

On T2-weighted images, the entire portion of the lesions, including central caseation necrosis, showed slightly heterogeneous isointensity (n = 3) or hypointensity (n = 2) in five patients (Figs 1 through 3), and had central hyperintensity surrounded by a hypointense rim in one patient. Within the hypointense or isointense granulomas, multiple small markedly hypointense foci were found in five patients. The heterogeneous hypointense or isointense portions histologically corresponded to all three layers. It was impossible to separate each of the three layers on T2-weighted images. The hyperintense center seen in one granuloma was felt to correspond to mature liquefied caseating material or tuberculous abscess, but histologic confirmation was impossible in this case, because this portion in the microscopic slides was sloughed during the preparation of the slides. No areas of focal hemorrhage or other specific histologic findings corresponding to the multiple small markedly hypointense foci were identified on the microscopic examination in any patient.

After contrast enhancement, there was ring-like enhancement, either single ring or multiple conglomerate rings, that corresponded to the rims seen on nonenhanced T1-weighted images and correlated histologically with both the inner collagen and the outer cellular layers in all six patients. The nonenhancing portions corresponded to central caseation necrosis (Figs 1



D

B

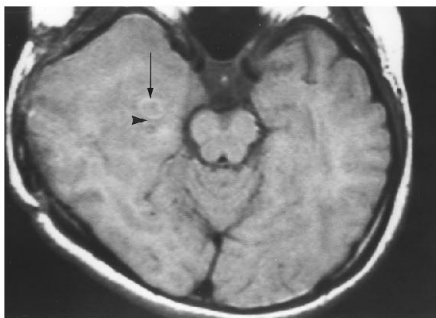
C

Fig 1. Case 1. A, T1-weighted coronal image (600/20/2) shows two rims of slight hyperintensity (*long arrows*) relative to cerebral gray matter with surrounding partial rim of slight hypointensity (*short arrow*) and central isointensity (*arrowhead*) in the right frontal lobe.

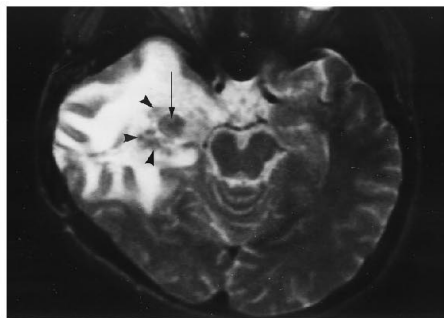
B, T2-weighted axial image (3000/80/1) shows heterogeneous isointensity containing multiple scattered markedly hypointense foci (*arrows*) in the mass. Adjacent hyperintense edema also is seen.

C, Gadolinium-enhanced T1-weighted coronal image (600/20/2) shows multiple conglomerated ring enhancement at the areas of slight hyperintense and hypointense rims on precontrast T1-weighted image.

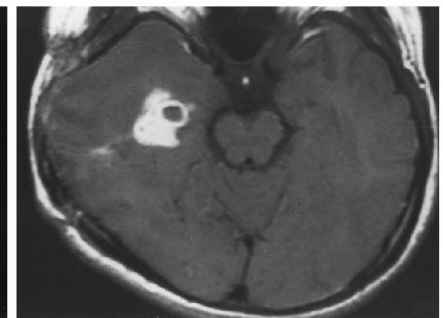
D, Photomicrograph of the resected granuloma shows two ovoid-shaped tuberculomas that consist of central caseation necrosis surrounded by a thick layer of collagen fiber (*arrows*) and thin layer of inflammatory cellular infiltrates (*arrowheads*). The layers of collagen fiber and inflammatory cellular infiltrates correspond to rims of slight hyperintensity and hypointensity on T1-weighted MR images, respectively.



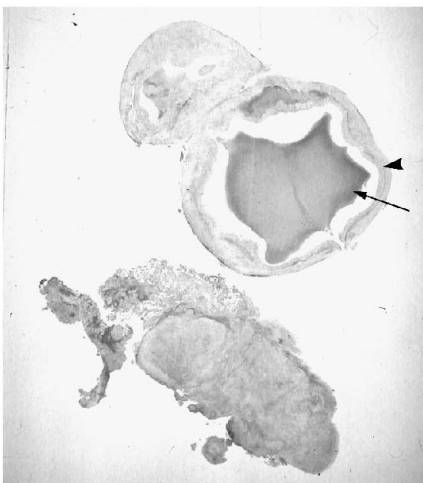
A



B



C



D

Fig 2. Case 2. A, T1-weighted axial image (500/30/3) shows a thick rim of slight hyperintensity (*arrow*) with central isointensity partially surrounded by a slightly hypointense rim (*arrowhead*) in the right temporal lobe.

B, T2-weighted axial image (2500/80/1) shows a round slightly heterogeneous isointense and hypointense mass (*arrow*) and adjacent multiple small conglomerate hypointense nodules (*arrowheads*). Diffuse surrounding edema also is seen.

C, Gadolinium-enhanced T1-weighted axial image (500/30/3) shows ring-shaped homogeneous enhancements in the round lesion and adjacent conglomerate nodules seen on T2-weighted images, respectively.

D, Photomicrograph of the resected specimen consists of variable-sized multiple conglomerated tuberculomas. The largest one contains retracted central caseation necrosis (*arrow*) surrounded by a thick rim of collagen fiber (*arrowhead*), which corresponds to a slightly hyperintense rim on T1-weighted MR.

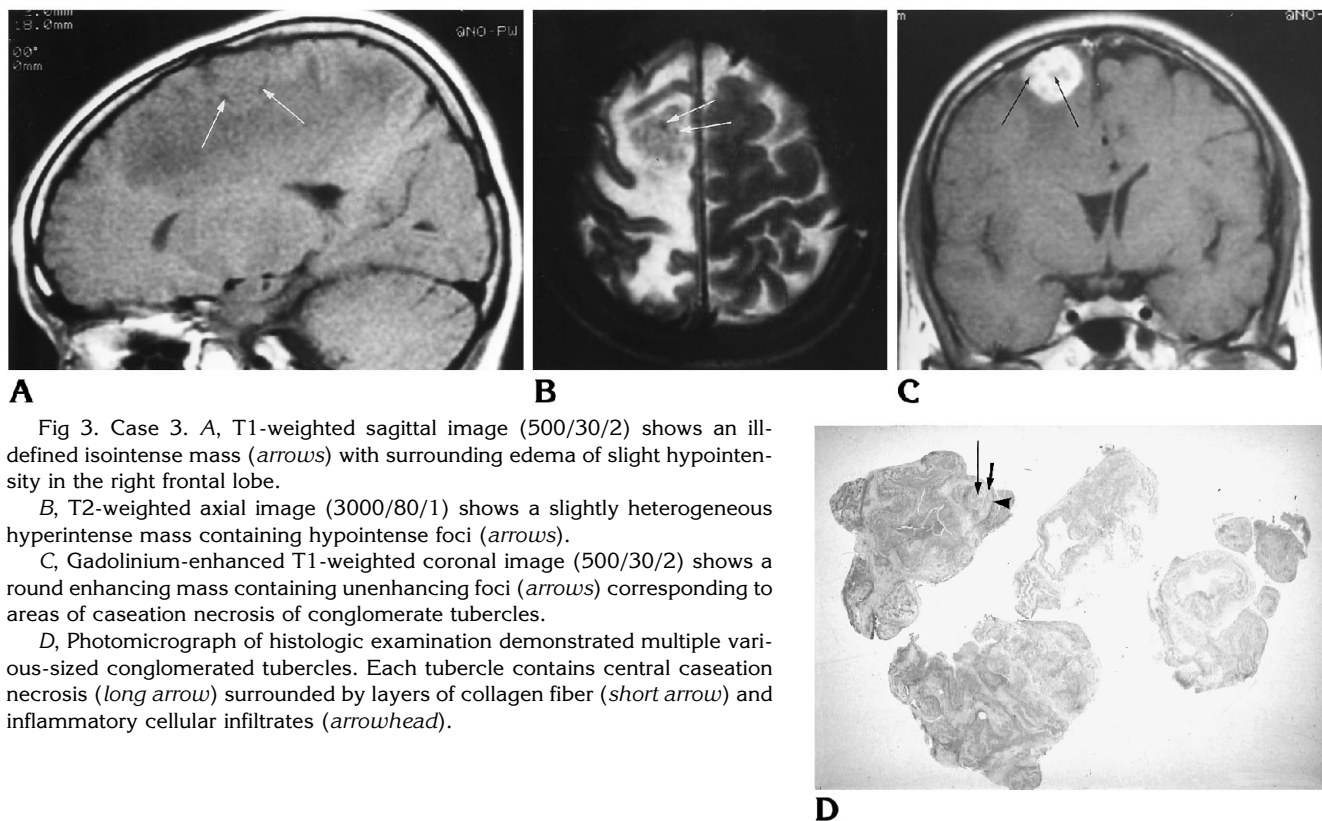


Fig 3. Case 3. A, T1-weighted sagittal image (500/30/2) shows an ill-defined isointense mass (arrows) with surrounding edema of slight hypointensity in the right frontal lobe.

B, T2-weighted axial image (3000/80/1) shows a slightly heterogeneous hyperintense mass containing hypointense foci (arrows).

C, Gadolinium-enhanced T1-weighted coronal image (500/30/2) shows a round enhancing mass containing unenhancing foci (arrows) corresponding to areas of caseation necrosis of conglomerate tubercles.

D, Photomicrograph of histologic examination demonstrated multiple various-sized conglomerated tubercles. Each tubercle contains central caseation necrosis (long arrow) surrounded by layers of collagen fiber (short arrow) and inflammatory cellular infiltrates (arrowhead).

through 3). There was a lot of vascularity in the cellular and collagen fiber layers on microscopic examination.

MR and histopathologic findings of tuberculomas in six patients are summarized in the Table.

Discussion

Intracranial tuberculomas originate as a conglomerate of small tubercles that join to form a mature tuberculoma composed of a central caseation necrosis surrounded by a zone of fibroblasts, epithelioid cells, Langhans giant cells, and lymphocytes. In the early stage of tuberculoma formation, there is a predominate inflammatory reaction with an abundance of giant cells and a capsule poor in collagenous tissue. Later, the capsule becomes richer in collagen, and the surrounding inflammatory reaction may disappear. The central portion of the lesion is transformed into caseous material by a necrotic process (1, 6).

It has been shown that intracranial tuberculomas usually are isointense to cerebral gray matter on T1- and T2-weighted images (4–7). In a previous study correlating histologic appear-

ance with MR findings of intracranial tuberculomas (7), the tuberculomas were described as containing more macrophages, fibrosis, gliosis, and fewer inflammatory cellular infiltrates appeared hypointense on T2-weighted images. In this series, the tuberculomas showed isointensity with or without central hypointensity or hypointensity on T1-weighted images, unlike the cases in the present series. However, direct comparison between MR signal intensity and histopathology at the corresponding area was not performed, and detailed histopathologic correlation with multiple rims frequently seen on MR was not described in this report. In our series, we found a slightly hyperintense rim with surrounding complete or partial rim of hypointensity and central isointensity or mixed isointensity and hyperintensity was usually present on T1-weighted images (Figs 1, 2). Multiple markedly hypointense foci scattered in isointensity or hypointensity on T2-weighted images (Figs 1 through 3) frequently were seen.

On T1-weighted images, histologic correlation revealed that the central isointensity or mixed isointensity and hyperintensity corresponded to caseation necrosis with adjacent inflammatory cellular infiltrates. Surrounding

MR and histopathologic findings of intracranial tuberculoma in six patients

Case	Sex/ Age, y	Location	MR Findings			Histologic Findings
			T1	T2	Gd-T1	
1	F/23	R frontal	10 to 23-mm conglomerated thick rims of slight hyperintensity with isointense center and partially surrounding thin rim of slight hypointensity	Heterogeneous isointensity containing multiple markedly hypointense foci	Conglomerated rim enhancement of slightly hyperintense and surrounding slightly hypointense rims	Two conglomerated tubercles with caseation necrosis surrounded by thick fibrous capsule and thin inflammatory cellular infiltrates each
2	F/21	R temporal	11-mm-thick rim of slight hyperintensity with isointense center and partially surrounding thin rim of slight hypointensity	11-mm heterogeneous isointensity and hypointensity containing multiple markedly hypointense foci and adjacent small (1 to 3 mm) conglomerated isointense and hypointense nodules	Solitary rim enhancement of hyperintense rim and diffuse solid enhancement of adjacent small nodules	11-mm tuberculoma with caseation necrosis surrounded by thick fibrous capsule and scanty inflammatory cell layers and adjacent small (1 to 3 mm) conglomerated tubercles with caseation necrosis in some tubercles
3	F/25	R frontal	Ill-defined isointensity	23-mm slight heterogeneous hyperintensity containing hypointense foci	Conglomerated rim enhancement of variable sizes (2 to 8 mm)	Numerous conglomerated tubercles with caseation necrosis in some tubercles
4	F/23	L temporal	20-mm-thick rim of slight hyperintensity with central mixed isointensity and hyperintensity and partially surrounding thin rim of slight hypointensity	Heterogeneous isointensity containing multiple markedly hypointense foci	Solitary rim enhancement of slightly hyperintense and surrounding slightly hypointense rims	Tuberculoma with caseation necrosis surrounded by thick fibrous capsule and thin inflammatory cell layers
5	F/28	R cerebellar	15-mm-thick rim of slight hyperintensity with central mixed isointensity and hyperintensity and surrounding thin rim of slight hypointensity	Heterogeneous hypointensity containing multiple markedly hypointense foci	Solitary rim enhancement of slightly hyperintense and surrounding slightly hypointense rims	Tuberculoma with caseation necrosis surrounded by thick fibrous capsule and thin inflammatory cell layers
6	F/45	R occipital	12-mm-thick rim of slight hyperintensity with central isointensity and surrounding thin rim of slight hypointensity	Hypointense rim with central bright hyperintensity	Solitary rim enhancement of slightly hyperintense and surrounding slightly hypointense rims	Tuberculoma with caseation necrosis surrounded by thick fibrous capsule and thin inflammatory cell layers

slight hyperintense and hypointense rims corresponded to a layer of collagenous fibrosis and a layer of outer inflammatory cellular infiltrates, respectively. The variable signal intensity of central caseation necrosis might be related to the variable protein concentration, because the variety of macromolecular protein concentration can have varied T1 relaxation time (8). The hyperintensity of the fibrotic layer may be related to the relatively high protein concentration

and low water content compared with adjacent tissue. In one patient who did not show a layering appearance on T1-weighted images, histologic examination demonstrated multiple conglomerated tubercles of varying size, each containing all three layers. Poor discrimination of the histologic layers on T1-weighted images was probably caused by the small size of each of the tubercles and the limit of spatial resolution of MR.

On T2-weighted images, the MR appearances of intracranial tuberculomas may vary according to the stage of evolution of the lesion. In the immature stage, tuberculomas appear as multiple scattered areas of isointensity or hypointensity surrounded by hyperintense edema. Pathologically, these scattered hypointense nodules represent small tubercles composed of inflammatory cells and a collagen-poor capsule. In the mature stage, the signal intensity of tuberculomas usually is heterogeneously hypointense or isointense throughout the entire portion of the granuloma, regardless of the presence of caseation necrosis. The isointense or hypointense portion of the granuloma histologically matches with caseation necrosis, inflammatory cellular infiltrates, and collagenous capsule. Therefore, T2-weighted images cannot distinguish the various histologic layers in the mature granuloma. The hypointensity or isointensity on T2-weighted images may reflect restricted mobile protons within high protein contents in organized caseation, cellular and collagenous layers, the presence of heterogeneously distributed free radicals produced by macrophages during active phagocytosis, and/or highly immobile saturated fatty acids (7). Additionally, we found multiple markedly hypointense foci within the tuberculomas. There was, however, no evidence of hemorrhage within the tuberculomas that could result in T2 shortening on microscopic examination. It is possible that these markedly hypointense foci within the tuberculomas in our series were caused by irregularly distributed free radicals. Sometimes, the caseous center may show hyperintensity on T2-weighted images, as in one case (case 6) of the present series. This finding might be caused by more water content in the central caseation necrosis, such as loose liquefied caseation or tuberculous abscess. But, it was not possible to prove this explanation, because the central portion in the granuloma in case 6 was lost during the preparation of the microscopic slides.

Postcontrast T1-weighted images usually showed ring enhancement, either single ring or multiple conglomerate rings that corresponded to the rims seen on nonenhanced T1-weighted images and correlated histologically with both the inner collagen and the outer cellular layers. This finding might be caused in part by prominent vascularity seen on microscopic examination. The conglomerate ring-enhancing appear-

ance may suggest a granulomatous lesion rather than a neoplasm.

A slightly hyperintense rim on T1-weighted images also was described in pyogenic abscesses and is known to correspond to mature abscess capsules containing fibrous collagen (9). These findings are similar to those of tuberculomas. However, hypointensity or isointensity frequently seen in the central portion of tuberculomas on T2-weighted images can differentiate them from pyogenic abscesses, which usually have central hyperintensity on T2-weighted images.

In conclusion, the outer enhancing portion of the tuberculoma histologically consisted of layers of inner collagenous fibers and outer inflammatory cellular infiltrates; the former usually correlated with a rim of slight hyperintensity and the latter correlated with complete or partial rim of slight hypointensity on T1-weighted images. On T2-weighted images both layers showed heterogeneous isointensity or hypointensity not separable from each other. Central caseation necrosis of the tuberculoma was seen mostly as isointense or hypointense on all pulse sequences, particularly on T2-weighted images. The signal intensity and ring-enhancing pattern of the lesion may play an important role in differentiating an intracranial tuberculoma from other ring-enhancing lesions in the brain.

References

1. Castro CC, Hesselink JR. Tuberculosis. *Neuroimag Clin N Amer* 1993;3:305-317
2. Pitchenik AE. Tuberculosis control and the AIDS epidemic in developing countries. *Ann Intern Med* 1990;113:89-91
3. Sheller JR, DesPrez RM. CNS tuberculosis. *Neurol Clin* 1986;4:143-158
4. Gupta RK, Jena A, Sharma A, Guha DK, Khushu S, Gupta AK. MR imaging of intracranial tuberculoma. *J Comput Assist Tomogr* 1988;12:280-285
5. Salgado P, Del Brutto OH, Talamas O, Zenteno MA, Carbajal JR. Intracranial tuberculoma MR imaging. *Neuroradiology* 1989;31:299-302
6. Chang KH, Han MH, Roh JK, et al. Gd-DTPA enhanced MR imaging in intracranial tuberculosis. *Neuroradiology* 1990;32:19-25
7. Gupta RK, Pandey P, Khan EM, Mittal P, Gujral RB, Chhabra DK. Intracranial tuberculomas: MRI signal intensity correlation with histopathology and localized proton spectroscopy. *Magn Reson Imag* 1993;11:443-449
8. Som PM, Dillon WP, Fullerton GD, Zimmerman RA, Rajagopalan B, Marom Z. Chronically obstructed sinonasal secretions: observations on T1 and T2 shortening. *Radiology* 1989;172:515-520
9. Haimes AB, Zimmerman RD, Morgello S, et al. MR imaging of brain abscesses. *AJNR Am J Neuroradiol* 1989;10:279-291