
Aventriculy: A New Entity?

William B. Garfinkle

Summary: In an 11-year-old girl who had repeated episodes of aspiration pneumonia, no lateral ventricles and no third or fourth ventricle could be identified on T1-, T2-, or proton density-weighted MR images. This condition was associated with failure of midline cleavage of the cerebral hemispheres, rhombencephalosynapsis, and complex migrational disorders.

Index terms: Brain, abnormalities and anomalies; Brain, ventricles

This report describes the magnetic resonance (MR) appearance of an absent ventricular system and massive associated developmental anomalies.

Case Report

An 11-year-old girl, delivered by emergency cesarean section at 32 weeks' gestation and institutionalized since age 4 months, was admitted to the hospital with repeated episodes of aspiration pneumonia. Her birth weight had been 7.7 kg and the pregnancy had been complicated by maternal diabetes (onset at age 13 years), toxemia, and multiple "colds." The mother did not use alcohol or drugs, did not smoke cigarettes, and had no radiography during pregnancy.

The subject has a 15-year-old sister born at 35 weeks' gestation. There had been four spontaneous abortions at 1 month's gestation and one at 5.5 months' gestation. The mother was an only child; the father has one brother with three healthy sons.

At physical examination, the subject's height was 136 cm (10th percentile) and weight was 110 kg (below third percentile). The head circumference was 40 cm (below third percentile), the ears displayed normal position and rotation, and the nose had a normal appearance. Interpupillary distance was 2.5 cm (25th percentile). The subject was noted to have a small forehead and a flat occiput and high, arched eyebrows. There were no heart murmurs. Scoliosis was apparent. She was cortically blind, deaf, and in status epilepticus.

MR imaging was performed with a 1.0-T scanner in multiple planes using T1-, T2-, and proton density-weighted sequences. The imaging studies revealed ab-

sence of the lateral, third, and fourth ventricles (Fig 1). The thalami were fused and the corpus callosum was absent. A single intracranial artery (ie, an azygous anterior cerebral artery) was visible intracranially, although two carotid arteries were visible in the cavernous sinus. The cerebral hemispheres were severely dysplastic without recognizable sylvian fissures or precentral and central sulci. The interhemispheric fissure was partially formed. There were no other definable sulci or gyri. Diffuse admixture of gray and white matter, and polymicrogyria were clearly visible. Also noted was rhombencephalosynapsis with fusion of the cerebellar hemispheres.

Discussion

The neural tube begins to form from the neural folds at approximately 21 days' gestation (1). The rostral and caudal neurospores close during the 25th to 27th day. The primary brain vesicles form during the fourth gestational week, and in the fifth gestational week the secondary brain vesicles are formed (2). From approximately the 28th through 44th days the cerebellum arises from the alar plate of the rhombencephalon (3). Thus, by the end of the fifth week of gestation, differentiation into recognizable structures should be occurring. An insult to the developing embryo early in its formation would result in the severe anomalies described above.

A comparison can be made between a holoprosencephaly and aventriculy, as they have many features in common. In a holoprosencephaly, there is variable failure of both lateral and transverse cleavage into hemispheres and lobes. In the alobar and semilobar holoprosencephalies, the thalami are fused, the interhemispheric fissure and falx is absent or poorly defined, and the cerebral hemispheres show variable fusion in the midline. There appears to be a lack of induction of the forebrain and the

Received July 27, 1995; accepted after revision January 22, 1996.

Presented at annual meeting of the American Society of Neuroradiology, Chicago, Ill, April 1995.

From the Department of Radiology, Albert Einstein Medical Center, 5501 Old York Rd, Philadelphia, PA 19141. Address reprint requests to William B. Garfinkle, MD.

AJNR 17:1649-1650, Oct 1996 0195-6108/96/1709-1649 © American Society of Neuroradiology

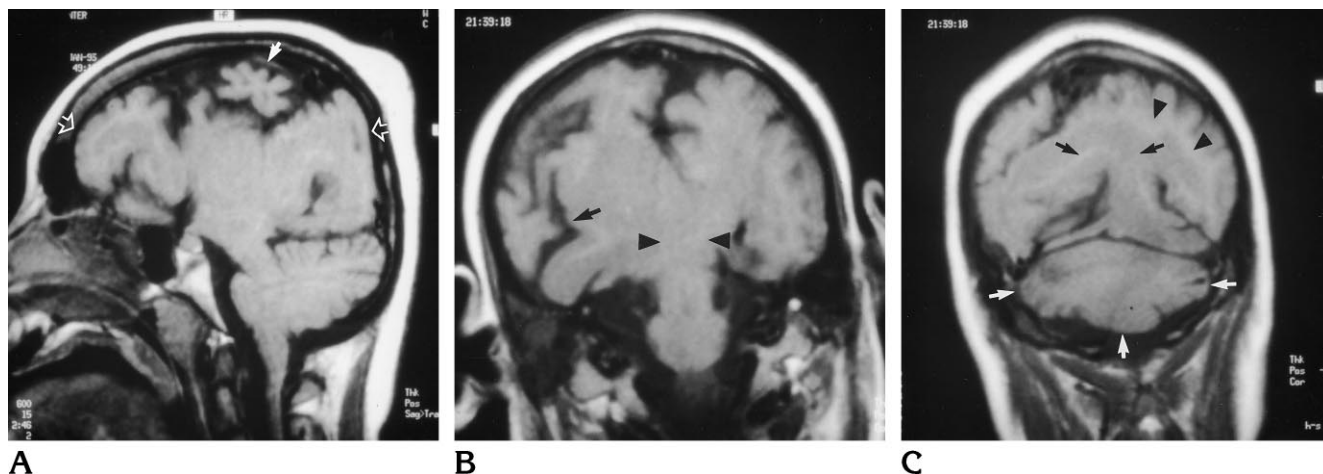


Fig 1. MR findings in an 11-year-old girl with absent ventricular system and massive associated developmental anomalies.

A, Sagittal T1-weighted image shows absence of the third and fourth ventricles. There is marked dysplasia of the cerebral hemispheres (*solid arrow*) and the cortex is smooth with few, shallow sulci visible, indicative of polymicrogyria (*open arrows*).

B, Coronal T1-weighted image shows absence of the lateral ventricles. The hemispheres are dysplastic with absence of normal sylvian fissures (*arrow*). There is fusion of the thalami across the midline (*arrowheads*), and virtually no white matter is visible.

C, Coronal T1-weighted image shows a single cerebellar hemisphere with absence of vermis, indicative of rhombencephalosynapsis (*white arrows*). Marked migrational abnormality in the supratentorial brain is again seen (*black arrows and arrowheads*).

premaxillary segments of the face (4). The primary failure is in the olfactory epithelium derived from the olfactory placode (5). The major anatomic difference between this case of aventriculy and a holoprosencephaly is the lack of any ventricular structure in the former and the presence of a variable size holoventricle in the latter. The presence of common features of cerebral and cerebellar formation between aventriculy and holoprosencephaly would suggest that aventriculy may also develop during the period of ventral induction.

Since there is an absence of ventricles and choroid plexus, cerebrospinal fluid production must occur elsewhere. Normally, about 30% of cerebrospinal fluid is produced in the choroid plexus, 30% by the ventricular ependyma and

20% by the intracranial subarachnoid lining, and 20% derives from the spinal subarachnoid lining (6).

References

1. Moore KL. *The Developing Human*. 4th ed. Philadelphia, Pa: Saunders; 1988:355
2. Moore KL. *The Developing Human*. 4th ed. Philadelphia, Pa: Saunders; 1988:367
3. Altman NR, Naidich TP, Braffman BH. Posterior fossa malformations. *AJNR Am J Neuroradiol* 1992;13:691-724
4. Barkovich AJ. *Pediatric Neuroimaging*. New York, NY: Raven Press; 1988:104
5. Rosenberg RN, Schochet SS, ed. *The Clinical Neurosciences*. New York, NY: Churchill Livingstone; 1983:14
6. Rumack C, Wilson SR, Charboneau WJ, eds. *Diagnostic Ultrasound*. St Louis, Mo: Mosby-Year Book; 1988:1023