
MR of Benign Chondroblastoma of the Temporal Bone

Calvin H. Flowers, Justo Rodriguez, Mohammad Naseem, Marc M. Reyes, and Andre S. Verano

Summary: A benign chondroblastoma of the temporal bone in an 8-year-old boy is reported. Head CT showed an expansile mass with calcifications in the center. The tumor appeared as a well-lobulated, hypointense intraosseous mass on T1-weighted brain MR; it was isointense to brain parenchyma on intermediate-weighted images and enhanced homogenously with gadolinium.

Index terms: Temporal bone, neoplasms; Chondroma; Children, neoplasms

Benign chondroblastoma is an uncommon primary bone tumor usually seen in the long bones of young persons. Described as an epiphyseal chondromatous giant cell tumor by Codman in 1931, this tumor was reclassified by Jaffe and Lichtenstein as benign chondroblastoma in 1942 because of its origination from chondroblasts (1, 2). Chondroblastoma of the cranial bones is extremely rare. The most common location of chondroblastoma involving the cranial bones is the squamous portion of the temporal bone (2-7).

Case Report

An 8-year-old boy presented to the emergency room with a soft tissue swelling over the right temporal region. According to his mother, the swelling was first noticed 3 years earlier, but was increasing progressively in size. The patient denied any headaches, seizures, or sensorimotor symptoms. The neurologic examination was normal, and there was a 3-cm nontender, nonerythematous soft mass that was palpated over the right temporal bone. Skull radiographs revealed a well-defined osteolytic lesion with sclerotic margins in the squamous portion of the right temporal bone. Computed tomography (CT) examination of the head revealed an expansile mass with calcifications in the center of the mass. The inner and outer tables of the temporal bone were expanded with minimal compressive erosion of the outer cortex but with no intracranial extension. A thick piece of bone seen bridging the diploic space represented uninvolved bone (Fig 1A). The differential

diagnoses before magnetic resonance (MR) imaging included: (a) aneurysmal bone cyst; (b) chondrosarcoma; (c) chondromyxoid fibroma; and (d) giant cell tumor. MR of the brain revealed a well-lobulated, hypointense intraosseous mass on T1-weighted images (Fig 1B), which was isointense to the brain parenchyma on intermediate-weighted images. On T2-weighted images, the lesion was slightly hyperintense with heterogenous areas of low signal intensity throughout the mass, which most likely represent areas of enchondral bone formation as well as contribution from the cartiliginous tumor matrix. The 1- to 2-cm foci of low signal seen in the tumor mass represent uninvolved diploic bone (Fig 1C). After intravenous administration of gadolinium contrast, the tumor exhibited homogenous enhancement (Fig 1D). No evidence of dural or intracranial extension was noted on MR imaging. An "en bloc" wide resection was performed with cranioplasty after a nondiagnostic aspiration biopsy. Microscopically, the tumor was moderately cellular with varied histologic patterns; most areas of the tumor were characterized by lobules of polygonal, stellate, or spindle-shaped cell along with multinucleated giant cells embedded in a myxoid stroma. The center of the lobules exhibited increased cellularity and chondroid areas with enchondral bone formation which is diagnostic of a chondroblastoma (Fig 2A and B).

Discussion

Benign chondroblastoma is a relatively rare bone tumor comprising approximately 1% of all primary bone tumors (1-10). The tumor usually arises in the epiphyses of long bones, with the humerus and tibia being the most common sites (1-10). Chondroblastoma occurs predominantly during the first 2 decades of life, and boys are affected twice as often as girls (2-8). Cranial bone involvement is extremely rare. The average age reported for patients with chondroblastoma involving the temporal bone is 53 years old (2-8). Our patient is one of the youngest with chondroblastoma of the temporal

Received May 17, 1991; accepted after revision April 8, 1993.

From the Departments of Radiology (C.H.F., J.R., M.N.) and Neuropathology, Hektoen Institute of Pathology (M.M.R., A.S.V.), Cook County Hospital, Chicago.

Address reprint requests to Calvin H. Flowers, MD, Department of Diagnostic Radiology, Rush-Presbyterian-St Luke's Medical Center, 1653 W Congress Pkwy, Chicago, IL 60612.

AJNR 16:414-416, February 1995 0195-6108/95/1602-0414 © American Society of Neuroradiology




Fig 1. 8-year-old boy with chondroblastoma of the temporal bone.

A, Axial CT scan of the head shows a lobulated and expanding intraosseous bone mass with partial discontinuity of the outer cortical margin of the temporal bone. Notice a piece of uninvolved bone (*arrow*).

B, Axial T1-weighted MR image (800/25 [repetition time/echo time]) shows low signal intensity in the tumor compared with brain parenchyma. There is moderate compression of the temporal lobe without dural extension (*open arrow*). The area of low signal in the center of the tumor mass (*solid arrow*) represents a piece of the remnant bone seen on the CT examination.

C, Axial T2-weighted MR image (2500/80) shows the hyperintense tumor mass with scattered foci of low signals representing calcifications and enchondral bone formation.

D, Axial postgadolinium T1-weighted image (500/30) shows uniform enhancement of the tumor mass. Uninvolved bone is noted at *black arrow* and compression of the right temporal lobe is seen without dural extension.

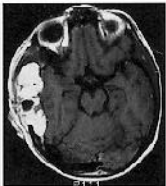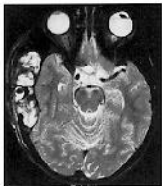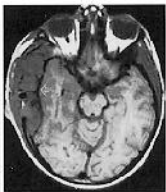bone (2–7). Most bones at the base of the skull develop from cartilage and therefore have a greater potential for development of a benign chondroblastoma. The most common location of chondroblastoma involving the temporal bone is the squamosal portion (2, 3–7). In contrast to chondroblastoma of long bones, which usually present with localized pain and swelling, the most frequent presentation of chondroblas-

toma involving the temporal bone is as a nontender mass with varied otologic complaints (2, 3–7). The radiographic features of chondroblastomas in long bones are characteristic, consisting of a well-defined osteolytic lesion that involves an epiphysis or secondary ossification center. Calcific foci within the lesion are documented in 30% to 50% of patients and the degree of calcification may be identified with CT


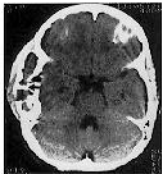
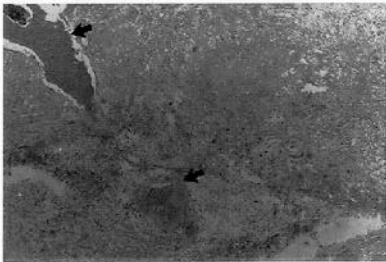


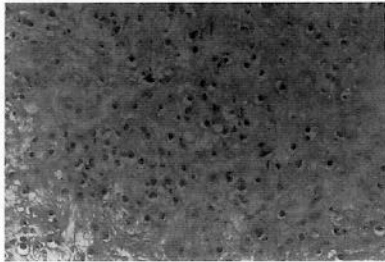
Fig 2. A, Photomicrograph shows a highly cellular chondroid matrix with foci of enchondrial bone formation (*arrows*) (hematoxylin and eosin, $\times 40$).

B, Higher magnification shows numerous chondroblast cells embedded in a highly mesenchymal cartiliginous matrix (hematoxylin and eosin, $\times 200$).





A



B

evaluation. Our findings of an expansile intraosseous mass with some internal calcification are similar to the CT findings of previously reported cases of benign chondroblastoma (3–7). In long bones, MR imaging may be hypointense to isointense on T1-weighted images and either isointense or hyperintense on the T2-weighted images (8, 11). An aneurysmal bone cyst, the prime differential in our case, may mimic a benign chondroblastoma because it is expansile and osteolytic on radiologic imaging (9, 10). MR evaluation may demonstrate intermediate to high signal intensities on T1-weighted images but exhibit high signals on T2-weighted images depending on the chronicity of the hemorrhage in the mass (8–10). Chondrosarcoma may exhibit low signals on both T1- and T2-weighted images, with less inhomogeneity than chondroblastoma (8). Septations and fluid levels may be evident in aneurysmal cysts, which helps to differentiate them from chondroblastoma (9, 10). Histologically, chondroblastomas are considered benign and usually exhibit two predominant cells types: the chondroblast and the osteoclast-like giant cell (1–5). The most important histologic features are areas of chondroid or hyaline cartilage with calcific deposits in the stroma (1, 2). Microscopically benign chondroblastoma may be worrisome because of its cellularity and variability; however, unlike chondrosarcoma, mitoses are rare. Treatment includes curettage and

en bloc resection (3, 4, 7). Although radiation may be used to decrease the recurrence rate of the tumor (3–7), it is not commonly used because of a few reports of sarcomatous changes after treatment (2–7).

References

1. Jaffe HL, Lichtenstein L. Benign chondroblastoma of bone: a reinterpretation of the so-called calcifying or chondromatous giant cell tumor. *Am J Pathol* 1942;18:969–991
2. Dahlin DC, Ivins JC. Benign chondroblastoma: a study of 125 cases. *Cancer* 1972;30:401–413
3. Blaauw G, Prick JJW, Versteeg C. Chondroblastoma of the temporal bone. *Neurosurgery* 1988;22:1102–1107
4. Harner SG, Cody DT, Dahlin DC. Benign chondroblastoma of the temporal bone. *Otolaryngol Head Neck Surg* 1979;87:229–236
5. Tanohata K, Noda M, Katoh H, Okazaki A, et al. Chondroblastoma of temporal bone. *Neuroradiology* 1986;28:367–370
6. Piepgras U, Hirth R, Stadler F, Kammerer V. Chondroblastoma of the temporal bone: an unusual cause of increasing intracranial pressure. *Neuroradiology* 1972;4:25–29
7. Horn KL, Hankinson H, Nagel B, Erasmus M. Surgical management of chondroblastoma of the temporal bone. *Otolaryngol Head Neck Surg* 1990;102:264–269
8. Fobben ES, Dalinka MK, Schiebler ML, et al. The magnetic resonance imaging appearance at 1.5 Tesla of cartilaginous tumors involving the epiphysis. *Skeletal Radiol* 1987;16:647–651
9. Beltram J, Simon DC, Levy M, et al. Aneurysmal bone cysts: MR imaging. *Radiology* 1986;158:689–690
10. Abdelwahab IF, Herman G, Klein MJ, Kenan S, Lewis MM. Case report 635: chondroblastoma of fourth metatarsal bone with secondary aneurysmal bone cyst. *Skeletal Radiol* 1990;19:539–541
11. Resendes M, Parker BR, Kempson RL, et al. Case report 663: unusual chondroblastoma of the scapula. *Skeletal Radiol* 1991;20:222–225