

---

# Bilateral Orbital Metastases from Prostate Carcinoma: Case Presentation and CT Findings

Sheryl Green, Peter M. Som, and Pablo G. Lavagnini

**Summary:** A patient with known prostatic cancer presented with bilateral orbital masses. On CT there was a bulky soft-tissue mass in the cranial aspect of each orbit. An open biopsy revealed undifferentiated tissue that stained strongly positive for prostatic-specific acid phosphatase, confirming the diagnosis of metastatic prostate carcinoma.

**Index terms:** Prostate; Carcinoma; Orbits, neoplasms

Orbital metastasis is uncommon, representing only 2% to 9% of all adult orbital neoplasms (1–4). Even if, as some investigators believe, the true incidence is somewhat more common than these reports indicate, such metastases still remain uncommon (5). It is somewhat perplexing that despite prostate cancer's being the second most common malignant neoplasm in adult men, orbital metastases from prostate carcinoma are uncommon (1–9). It has been noted that because such prostate orbital metastases are so uncommon, any such diagnosis must be viewed with skepticism unless there is histologic and, if possible, histochemical confirmation. The purpose of this paper is to report a case of bilateral prostatic orbital metastases with biopsy confirmation that had a strong prostatic-specific acid phosphatase staining.

## Case Report

The patient is a 62-year-old diabetic man with known prostate cancer, who was admitted to the hospital for treatment of a urinary tract infection. Two years earlier, adenocarcinoma of the prostate gland had been diagnosed (Gleason score 9), and he underwent a radical prostatectomy and bilateral orchiectomy. One year ago he received two courses of palliative radiation therapy for painful osteoblastic metastases to the lumbosacral spine and pelvis with a good therapeutic response. During the course of the current admission, he was noted to have proptosis of the left eye. He denied any pain or change in his visual acuity. Examination was remarkable for proptosis of the left eye

with some impaired abduction. There was no evidence of visual impairment or corneal ulceration. A contrast-enhanced computed tomography (CT) scan was performed that showed bilateral, bulky extraconal soft-tissue masses in the cranial aspect of each orbit (Fig 1). The masses were sharply delineated from the adjacent orbital structures, and there was no CT evidence of either gross bone erosion or osteoblastic disease. Despite the apparent absence of such bone disease, a soft-tissue fullness was present in the left temporal fossa adjacent to the orbit and along the dura of the left middle cranial fossa, suggesting that metastases were, in fact, present.

Unrelated inflammatory soft-tissue disease was present in the paranasal sinuses. A biopsy of the left orbital mass showed inflammation, fibrosis, and cellular atypia suggestive of tumor. Immunohistochemical studies showed these cells to be strongly positive for prostatic specific antigen and low molecular weight cytokeratin, findings consistent with a prostatic origin of the tumor. During the patient's hospitalization, the left proptosis progressed and mild right proptosis was noted. When left visual acuity decreased, the patient was started on steroid therapy and referred for irradiation to both orbits. A minimal response to radiation therapy was obtained, and there was some residual bilateral proptosis. There was no change in the impaired left visual acuity.

## Discussion

There are at least three unusual aspects of this case. First is the rare orbital metastasis from prostate cancer, second is the even rarer bilateral occurrence of such metastases, and third is such large, bulky soft-tissue metastases with sparse adjacent bone disease.

In a series of 227 cases with carcinomatous metastasis to the eye and orbit, only three (1.3%) patients had the primary lesion in the prostate gland (4). A second series of 28 patients having orbital, but not ocular, metastasis placed the incidence of a prostate primary at 3.5% (one case) (3). From such articles and a

---

Received February 2, 1993; accepted after revision March 29.

From the Departments of Radiation Oncology (S.G., P.G.L.) and Radiology (P.M.S.), Mount Sinai School of Medicine, City University of New York.

Address reprint requests to Peter M. Som, MD, Department of Radiology, Mount Sinai Hospital, 1 Gustave L. Levy Pl, Box 1234, New York, NY 10029.




Fig 1. A, Coronal CT scan shows bilateral, bulky, soft-tissue extraconal orbital masses. There is no obvious infiltration of the adjacent orbital soft tissues.

B, Axial CT scan shows the main portion of the bulky soft tissue mass in the left orbit. The medial and lateral extensions of the extraconal soft-tissue mass are seen in the right orbit (*arrows*). The superior muscle bundle on the right is seen between these masses. Although this axial image might suggest that it is the extraocular muscles that are enlarged, the coronal image (A) shows that these muscles are grossly normal and that the tumor is most probably "outside" the periorbita. In addition, there is thickening of the left intracranial temporal fossa dura (*open arrow*), and there is a mass in the left extracranial temporal fossa (*small arrow*).

C, Axial wide window view of B shows that there are no areas of either gross bone destruction or blastic disease. The soft-tissue disease in the ethmoid and sphenoid sinuses was unrelated sinusitis.

review of the literature, we found very few such orbital metastases from a prostate primary carcinoma. Bilateral metastases were extremely rare.

With regard to bone metastasis in prostate cancer, bone disease is common; more than 90% of the metastatic sites are predominately or entirely osteoblastic (1). The minimal bone reaction in this case is not typical of such metastatic disease.

Regarding the radiation therapy given to this patient, such irradiation is generally effective in the treatment of distant metastases from carcinoma of the prostate. Marked relief of symptoms occurs in more than 80% of patients treated with adequate doses (10).

One series of orbital tumors showed that 30% of metastatic orbital tumors were, in fact, the presenting signs of an unknown primary malignant neoplasm (10), and prostatic carcinoma appears to follow this tendency. Review of the literature indicates that about two thirds of the cases with such metastatic prostatic carcinoma were diagnosed after the development of ocular symptoms and that these metastases could mimic a variety of other conditions such as primary orbital tumor, secondary tumor extension from adjacent primary neoplasms, lymphomas, meningiomas, and arteriovenous malformations (1). In our case, the history of prostatic carcinoma was known before the presentation of orbital disease.

It also has been pointed out in the literature that histology of a biopsy can be helpful if the lesion is well enough differentiated to identify the primary tumor as being in the prostate (1, 7). However, many such tumors are poorly differentiated, and the primary malignancy site may not be identifiable based solely on the histologic findings. In such cases, immunohistologic stains can be used as a diagnostic tool, with immunoperoxidase stains for prostatic-specific acid phosphatase being highly specific (7). Our case was very strongly stained positive for prostatic specific acid phosphatase.

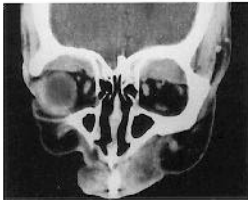The CT appearance of bilateral bulky, sharply delineated soft-tissue masses was also uncharacteristic of metastatic disease, and with the rarity of case reports of such bilateral metastatic prostate carcinoma, the diagnosis was not obvious from the imaging study despite the history of prostate carcinoma.

This case is presented to remind both radiologists and clinicians of the diagnosis of metastatic prostate carcinoma to the orbit and the usefulness of histochemical staining of biopsy material for prostatic-specific acid phosphatase.

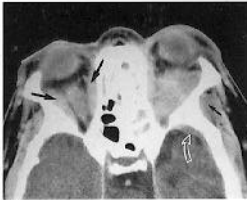
## References

1. Carriere VM, Karcioğlu ZA, Apple DJ, Insler MS. A case of prostate carcinoma with bilateral orbital metastasis and the review of the literature. *Ophthalmology* 1982;89:402-406

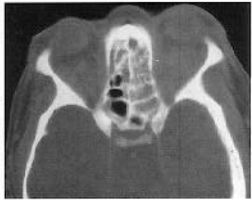2. Moss HM. Expanding lesions of the orbit: a clinical study of 230 consecutive cases. *Am J Ophthalmol* 1962;54:761-770
3. Font RL, Ferry AP. Carcinoma metastatic to the eye and orbit, III: a clinicopathologic study of 28 cases metastatic to the orbit. *Cancer* 1976;38:1326-1335
4. Ferry AP, Font RL. Carcinoma metastatic to the eye and orbit, I: a clinicopathologic study of 227 cases. *Arch Ophthalmol* 1974;92:276-286
5. Albert DM, Rubenstein RA, Scheie HG. Tumor metastases to the eye, I: incidence in 213 adult patients with generalized malignancy. *Am J Ophthalmol* 1967;63:723-726
6. Reifler DM, Kini SR, Liu D, Littleton RH. Orbital metastases from prostate carcinoma. *Arch Ophthalmol* 1984;102:292-295
7. Kopelman JE, Shorr N. A case of prostatic carcinoma metastatic to the orbit diagnosed by fine needle aspiration and immunoperoxidase staining for prostatic specific antigen. *Ophthalmic Surg* 1987;18:599-603
8. Winkler CF, Goodman GK, Eiferman RA, Yam LT. Orbital metastasis from prostatic carcinoma: identification by an immunoperoxidase technique. *Arch Ophthalmol* 1981;99:1406-1408
9. Kennerdell JS, Dekker A, Johnson BL, Dubois PJ. Fine-needle aspiration biopsy: its use in orbital tumors. *Arch Ophthalmol* 1979;97:1315-1317
10. Blitzer PH. Reanalysis of the RTOG study of the palliation of symptomatic osseous metastasis. *Cancer* 1985;55:1468-1473



**A**



**B**



**C**