
Aneurysm Formation after Carotid Occlusion

Paul E. Timperman, Thomas A. Tomsick, John M. Tew, Jr, and Harry R. van Loveren

Summary: We present two cases of subarachnoid hemorrhage caused by aneurysm development and enlargement in the anterior communicating artery complex. The cases occurred in a series of 58 balloon occlusions for unclippable giant aneurysms of the internal carotid artery.

Index terms: Aneurysm, cerebral; Aneurysm, therapeutic blockade; Subarachnoid space, hemorrhage; Interventional neuroradiology, complications of; Iatrogenic disease or disorder

In treatment of difficult-to-clip giant aneurysms of the internal carotid artery, there are currently several therapeutic approaches. Attempts to preserve internal carotid artery flow with balloon placement directly in the aneurysm may be successful (1). Experimental thrombogenic coil occlusion of aneurysms to maintain parent artery patency has been reported and is currently under investigation in a multicenter trial (2). Another approach seeks to maintain natural hemodynamics with a bypass graft, either a petrous-carotid to supraclinoid-carotid saphenous vein graft bypassing the aneurysmal segment or a graft from the external carotid artery to the middle cerebral artery, both accompanied by internal carotid artery occlusion (3–5). There is controversy regarding the value of augmenting blood flow considering the complexity and potential morbidity of an extensive surgical procedure to secure the bypass graft. Another approach is to occlude the involved internal carotid artery by clamping, ligation, trapping, or balloon occlusion after adequate collateral circulation has been demonstrated (6–8).

Aneurysm formation is a late complication associated with a ligation or clamp-occlusive procedure (9–11). To date, aneurysm formation has not been reported as a complication of carotid balloon occlusion but may become important with increasing numbers of carotid bal-

loon occlusions. To increase awareness of this potential complication, we report two cases of subarachnoid hemorrhage caused by aneurysms that developed in the anterior cerebral artery region after balloon occlusion of an aneurysmal internal carotid artery.

Case Reports

Case 1

A 58-year-old white woman presented with a 1-year history of persistent headache and gradual onset of diplopia. In October 1988, a complete left sixth-nerve palsy developed. Arteriography demonstrated a 20 × 25-mm aneurysm of the left cavernous internal carotid artery without other intracranial abnormalities. In November 1988, she underwent detachable balloon occlusion of the left internal carotid artery proximal to the aneurysm. The left sixth-nerve palsy persisted. The patient did well until September 1990, when she had sudden severe headache and neck stiffness. A computed tomographic (CT) scan revealed a subarachnoid hemorrhage predominantly in the anterior communicating artery region. Angiography demonstrated a 2.5-mm anterior communicating artery aneurysm not present during initial studies (Fig 1), and, as expected, thrombosis of the giant internal carotid artery aneurysm. The anterior communicating artery aneurysm was clipped at surgery.

Case 2

In 1967, a 49-year-old white woman presented with intermittent diplopia; arteriography showed a giant right internal carotid artery aneurysm. She refused surgical treatment, and her vision gradually deteriorated to complete blindness in 1980. She also experienced left-sided headaches, which not only increased in frequency and severity but also were often accompanied by nausea and vomiting. In 1983, right facial twitching, numbness, hearing loss, and falling episodes developed.

On examination in 1985, the right eye was blind, chemotic, and proptotic. Right third, sixth, and seventh nerve palsies, and sensory deficits of right V1 and V2 were

Received December 7, 1992; accepted after revision April 6, 1993.

From the Departments of Radiology (Section of Neuroradiology) (P.E.T., T.A.T.) and Neurosurgery (T.A.T., J.M.T., H.R.v.L.), University of Cincinnati College of Medicine.

Address reprint requests to Thomas A. Tomsick, MD, Department of Radiology, University Hospital, 234 Goodman St, Cincinnati, OH 45267-0742.

AJNR 16:329–331, Feb 1995 0195-6108/95/1602-0329 © American Society of Neuroradiology




Fig 1. Case 1. Oblique right internal carotid artery arteriogram shows a 2-mm aneurysm from the posterior aspect of the anterior communicating artery (*arrow*). The left internal carotid artery is occluded by the balloon in the cavernous segment (*curved arrow*).

present. A CT scan and angiography performed on August 28, 1985, showed a largely thrombosed, giant right cavernous internal carotid artery cavernous aneurysm (Fig 2A), a focal aneurysm near the left A1-A2 junction, and a second very small distal anterior communicating artery aneurysm (Fig 2B). No other aneurysms were shown. On September 18, 1985, she underwent balloon occlusion of the internal carotid artery proximal to the aneurysm and internal carotid artery ligation. A follow-up angiogram, performed on September 25, demonstrated the giant aneurysm to be almost completely thrombosed. Contrast-enhanced CT on September 4, 1986, revealed no luminal aneurysm enhancement and a minimal decrease in size.

The patient did well until September 17, 1989, when she presented with sudden severe headache, stiff neck, nausea, and vomiting. A CT scan revealed subarachnoid blood predominantly in the anterior communicating artery region. Arteriography revealed two aneurysms of the anterior cerebral complex (Fig 2C). The giant aneurysm was thrombosed. Craniotomy demonstrated a ruptured aneurysm arising from the distal A1 segment (at the anterior communicating artery junction) and an aneurysm that arose from the proximal A1-A2 junction. The two aneurysms were clipped at surgery.

Discussion

Symptomatic formation and/or enlargement of aneurysms as a late complication of internal carotid artery occlusion has been sparsely reported. A review of the literature in 1989 by Dyste and Beck (10) reported an incidence of symptomatic aneurysm formation between 4% and 10%.

A hemodynamic case for aneurysm formation has been made before and may very likely play a role in the formation and/or enlargement of these aneurysms (9-13). In case 1, angiographic demonstration of increased blood flow through the anterior communicating artery supports the theory that increased blood flow and turbulence pattern may favor aneurysm development. Case 2 is less easy to explain hemodynamically, because there was no significant contralateral-collateral arteriographic flow in




Fig 2. Case 2. A, Contrast CT shows a 6.5×4.5 -cm largely thrombosed right internal carotid artery aneurysm eroding the sphenoid and temporal bones (including the internal auditory canal and labyrinth) and compressing the anterior communicating artery region.

B, Oblique left internal carotid artery arteriogram shows the complex anatomy of the compressed anterior cerebral artery region, interpreted as an aneurysm of the A1-A2 junction (*solid arrow*), hemodilution from a patent anterior communicating artery (*open arrow*), and a very small aneurysm of the A2 (*curved arrow*).

C, Oblique left internal carotid artery arteriogram shows little change of the aneurysm of the A1-A2 junction (*solid arrow*) and a 6-mm aneurysm of the A2 segment, which likely represents an enlargement of the previous very small aneurysm (*curved arrow*). Minimal spasm is evident.

the anterior communicating artery before or after occlusion.

These two cases illustrate the risk of symptomatic aneurysm formation and/or enlargement and rupture after balloon occlusion of the internal carotid artery. The potential for this complication, therefore, is expected to increase with time. As yet, this infrequently documented incidence of symptomatic anterior communicating artery aneurysm development is insufficient to alter our usual recommendation for balloon occlusion of the internal carotid artery for difficult-to-clip aneurysms in patients who tolerate temporary balloon occlusion (14,15).

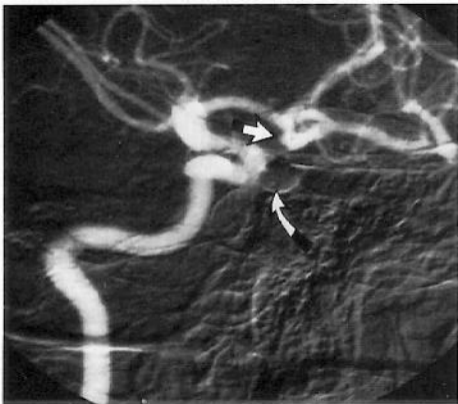Careful arteriographic evaluation of the anterior communicating artery region is indicated in every patient in whom carotid artery occlusion is being considered so that preexisting aneurysms may be documented and treated. Follow-up CT, magnetic resonance imaging, and magnetic resonance angiography examinations after internal carotid artery occlusion should be scrutinized for the possible development of an aneurysm in the anterior communicating artery region.

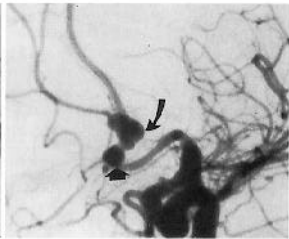
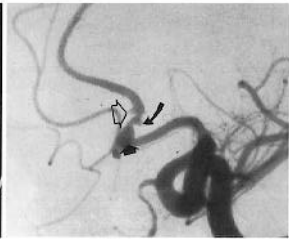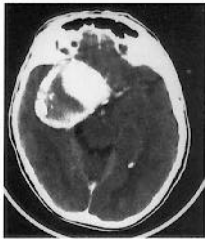Acknowledgments

We thank Alexis Rostoker for medical transcription and Mary Kemper for editorial assistance.

References

- Higashida RT, Halbach VV, Dowd CF, Barnwell SL, Hieshima GB. Intracranial aneurysms: interventional neurovascular treatment with detachable balloons: results in 215 cases. *Radiology* 1991; 178:663-670
- Gugliemi G, Vinuela F, Dion J, Duckwiler G. Electrothrombosis of saccular aneurysms via endovascular approach. *J Neurosurg* 1991;75:8-14
- Sekhar LN, Chandra SN, Hae DJ. Saphenous vein graft bypass of the cavernous internal carotid artery. *J Neurosurg* 1990;72:35-41
- Spetzler RF, Schuster H, Roski RA. Elective extracranial-intracranial arterial bypass in the treatment of inoperable giant aneurysms of the internal carotid artery. *J Neurosurg* 1980;53:22-27
- Spetzler RF, Fukushima T, Martin N, Zabramski JM. Petrous carotid-to-intradural carotid saphenous vein graft for intracavernous giant aneurysms, tumor, and occlusive cerebrovascular disease. *J Neurosurg* 1990;73:496-501
- Fox AJ, Vinuela F, Pelz DM, et al. Use of detachable balloons for proximal artery occlusion in the treatment of unclippable cerebral aneurysms. *J Neurosurg* 1987;66:40-46
- Higashida RT, Halbach VV, Dowd C, et al. Endovascular detachable balloon embolization of cavernous carotid artery aneurysms: results in 87 cases. *J Neurosurg* 1990;72:857-863
- Little JR, Rosenfeld JV, Awad IA. Internal carotid artery occlusion for cavernous segment aneurysm. *Neurosurgery* 1989;25: 398-404
- Clark WC, Ray MW. Contralateral intracranial aneurysm formation as a late complication of carotid ligation. *Surg Neurol* 1982;18: 485-462
- Dyste GW, Beck DW. *De Novo* aneurysm formation following carotid ligation: case report and review of the literature. *Neurosurgery* 1989;24:88-92
- Fujiwara S, Fujiik, Fukuim. De novo aneurysm formation and aneurysm growth following therapeutic carotid occlusion for intracranial internal carotid artery (ICA) aneurysms. *Acta Neurochir* 1993;120:21-25
- Hashimoto N, Handa H, Nagata I, Hazama F. Experimentally induced cerebral aneurysms in rats, V: relation of hemodynamics in the circle of Willis to formation of aneurysm. *Surg Neurol* 1980;13:41-45
- Hassler O. Experimental carotid ligation followed by aneurysmal formation and other morphological changes in the circle of Willis. *J Neurosurg* 1990;72:35-41
- Tomsick TA, Tew JM Jr, Lukin RL, Johnson KK. Balloon catheters for aneurysms and fistulae. *Clin Neurosurg* 1984;31:135-164
- Weil SM, van Loveren HR, Tomsick TA, Quallen BL, Tew JM Jr. Management of inoperable cerebral aneurysms by the navigational balloon technique. *Neurosurgery* 1987;21:296-302





A

B

C