
Unusual Location of an Intracranial Chondroma

Beatrice De Coene, Claude Gilliard, Cecile Grandin, Jean-Francois Nisolle, Jean-Paul Trigaux, and Joseph Bou Lahdou

Summary: We describe the MR findings in a case of chondroma arising from the falx. At MR imaging, the mass appeared well defined, lobulated, hypointense to isointense on T1-weighted images, and very heterogeneous with marked hyperintense areas on T2-weighted images. After contrast administration, this tumor enhanced slightly on delayed images.

Index terms: Chondroma; Falx cerebri

Chondromas are benign tumors that may be found in any part of the body. Among intracranial neoplasms, tumors of cartilaginous origin are rare (1). It has been shown that most of these tumors arise from the skull base; their occurrence in other parts of the intracranial cavity is unusual (1). We describe the MR findings of a solitary intracranial chondroma arising from the falx.

Case Report

Acute mental deterioration developed in a 35-year-old man who had a long history of psychiatric disorders. Findings at neurologic examination were normal. Computed tomography (CT) of the brain revealed a 45 × 30 × 55-mm mass in the right posterior parietal region. On plain CT scans, the tumor was slightly hyperdense with irregular calcifications (Fig 1A). No enhancement was noted on contrast-enhanced studies, and there was no bone destruction or hyperostosis.

Magnetic resonance (MR) imaging of the brain revealed a multilobulated, well-defined mass. On T1-weighted images (Fig 1B), the tumor showed low signal intensity; on T2-weighted images (Fig 1C), it showed moderately high signal intensity and some areas of very high signal intensity within its nonmineralized portion. Zones of low signal intensity corresponded to the sites of calcification detected on the CT scan. No contrast enhancement was observed immediately after injection of contrast material (Fig 1D), but 15 minutes later, a slight peripheral enhancement could be seen. No precise diagnosis could be made because it was difficult to define the intraaxial or extraaxial location of this tumor on the basis of the MR images.

Differential diagnosis was between meningioma, oligodendroglioma, and vascular malformation.

At surgery, the mass was extraaxial with an attachment to the falx, and it appeared well defined, firm, and calcified. Microscopically, the tumor consisted of a well-encapsulated moderately cellular mass with abundant chondroid matrix. No hemorrhage was noted. The cells were well defined with no evidence of mitotic activity. The diagnosis of a chondroma was made. Postoperative MR studies showed complete resection.

Discussion

Intracranial chondroma is a benign, cartilaginous tumor that accounts for fewer than 1% of all intracranial tumors. It can be solitary, a component of Ollier disease, or part of the Maffucci syndrome (2). Solitary intracranial chondromas are usually located at the base of the skull or in the paranasal sinuses with extension into the cranial cavity. Tumors arising from the dura, choroid plexus, leptomeninges, or within the brain parenchyma are less common (1). They can occur at any age, with a peak prevalence in the third decade (3, 4).

Most authors agree that the majority of chondromas develop from the cartilage found in the basilar synchondroses. The scenario of chondromas arising from the dura is more controversial. Cartilaginous metaplasia of meningeal fibroblasts has been suggested most frequently. However, other origins, such as ectopic embryologic rests of cartilage cells, metaplasia of perivascular mesenchymal tissue, or traumatic displacement of cartilaginous elements, have also been proposed (1–4). Cranial chondromas are similar to those found elsewhere in the body, but they are more irregular in pattern and grow predominantly by expansion (5).

Microscopically, the tumor consists of a fine fibrous capsule surrounding lobules of well-dif-

Received November 30, 1995; accepted after revision May 13, 1996.

From the Departments of Radiology (B.D.C., J-F.N., J-P.T.) and Neurosurgery (Cl.G., J.B.), Cliniques Universitaires (UCL de Mont-Godinne, and the Department of Radiology, Cliniques Universitaires UCL de Woluwe (Ce.G.), Belgium.

Address reprint requests to Beatrice De Coene, MD, Department of Radiology, Cliniques Universitaires (UCL de Mont-Godinne, B-5530 Yvoir, Belgium.

AJNR 18:573-575, Mar 1997 0195-6108/97/1803-0573 © American Society of Neuroradiology

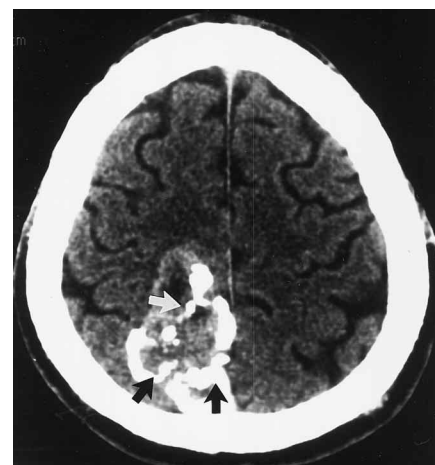Fig 1. A 35-year-old man with acute onset of mental deterioration.

A, Noncontrast axial CT scan shows lobulated, well-defined, slightly hyperdense posterior parietal mass containing dense, irregular calcifications (*arrows*).

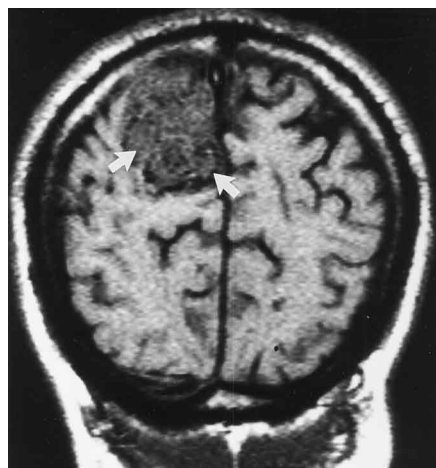
B, Noncontrast coronal T1-weighted (500/20) MR image shows the tumor with low to intermediate signal intensity (*arrows*).

C, Axial T2-weighted (2500/90) MR image shows areas of moderately high (*straight arrows*) and very high (*curved arrows*) signal intensity within the nonmineralized portion of the tumor.

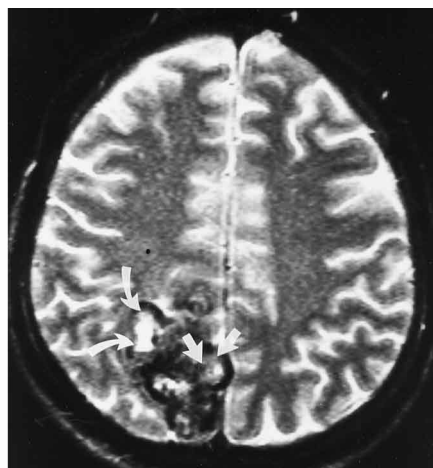
D, Contrast-enhanced coronal MR image (500/20) 15 minutes after intravenous injection of gadopentetate dimeglumine shows slight peripheral enhancement (*arrows*)



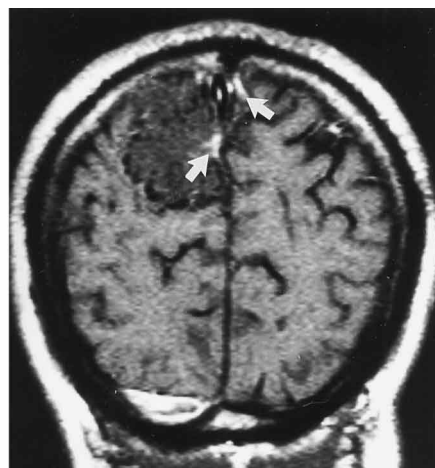A



B



C



D

ferentiated cartilaginous bone. The chondrocytes are situated in an abundant chondroid matrix and show no evidence of atypical cells, multinucleation, or mitotic activity (2). Chondromas form hyaline cartilage, which is trabeculated and lobulated (5). On CT scans, intracranial chondromas are well-circumscribed, extraaxial lesions with either globular or diffuse calcification that may show areas of attenuation and that demonstrate slight enhancement after administration of contrast material (2). In one case (3), rim calcification was noted.

Bone destruction occurs in over 50% of the cases, and the tumor may also produce hyperostosis of the inner table of the skull (6). Calcifications are usually irregular and mottled and are seen in about 60% of cases (4). Chondromas are avascular lesions (7) that compress the brain but do not invade it. On delayed postcontrast CT scans, the tumor may show marked enhancement (4).

Chondromas of the convexity and falx can be difficult to distinguish from meningiomas or calcified extraaxial hematomas. However, meningiomas usually display intense, homogeneous contrast enhancement (3). Intratumoral calcifications militate against neurinoma. When intracranial chondromas are calcified and located in the anterior and middle cranial fossae, the sellar and parasellar region, a confident diagnosis of chondroma may be made on the basis of their rather typical appearance (7). CT findings that may help in the differential diagnosis are intratumoral calcifications and delayed contrast enhancement. Early contrast enhancement is suggestive of meningioma, whereas marked delayed contrast enhancement with or without early contrast enhancement is a finding that should suggest the diagnosis of chondroma (4).

Geirnaerd et al (8) observed postcontrast peripheral enhancement in osteochondromas that corresponded to fibrovascular tissue cover-

ing the nonenhancing hyaline cartilage. These authors also noted that fibrovascular septa are found only in low-grade chondrosarcomas, suggesting that septal enhancement is specific for low-grade chondrosarcomas. Aoki et al (9) concluded that an enhancement pattern of rings and arcs on contrast-enhanced MR images was another reflection of the lobulated growth pattern of enchondromas and chondrosarcomas.

Owing to the rarity of intracranial chondromas, their imaging characteristics have not been well described. Generally, these are circumscribed, extraaxial, avascular lesions with globular or diffuse calcifications showing, unlike meningiomas, little or no enhancement on post-contrast studies. In our patient, delayed post-contrast examination showed marked enhancement, enabling differentiation from an old hematoma.

Treatment of these lesions is complete surgical removal, and the long-term prognosis is good. Local invasion or recurrence should raise

the possibility of malignant degeneration into chondrosarcoma (3).

References

1. Tunçalp O, Necmettin P, Nejat A, Vural B, Behsan O. Intracranial solitary chondroma. *J Neurosurg* 1984;61:399-401
2. Matz S, Israeli Y, Shalit MN, Cohen ML. Computed tomography in intracranial supratentorial osteochondroma. *J Comput Assist Tomogr* 1982;5:109-115
3. Yang PJ, Seeger JF, Carmody RF, Fleischer AS. Chondroma of falx: CT findings. *J Comput Assist Tomogr* 1986;10:1075-1076
4. Tanohata K, Maehara T, Aida N, et al. Computed tomography of intracranial chondroma with emphasis on delayed contrast enhancement. *J Comput Assist Tomogr* 1987;11:820-823
5. Zülch KJ. *Brain Tumors*. 3rd ed. New York, NY: Springer-Verlag; 1986:479-481
6. Palacios E. Intracranial solitary chondroma of dural origin. *AJR Am J Roentgenol* 1970;110:67-70
7. Sarwar M, Swischuk LE, Schechter MM. Intracranial chondromas. *AJR Am J Roentgenol* 1976;127:973-977
8. Geirnaerd MJA, Bloem JL, Eulderink F, Hogendoorn PCW, Taminiou AHM. Cartilaginous tumors: correlation of gadolinium-enhanced MR imaging and histopathologic findings. *Radiology* 1993;186:813-817
9. Aoki J, Sone S, Fujioka F, et al. MR of enchondroma and chondrosarcoma: rings and arcs of Gd-DTPA enhancement. *J Comput Assist Tomogr* 1991;15:1011-1016