

CT of the Normal Suspensory Ligaments of the Ossicles in the Middle Ear

Marc M. Lemmerling, Hilda E. Stambuk, Anthony A. Mancuso, Patrick J. Antonelli, and Paul S. Kubilis

PURPOSE: To establish the range of normal variation in the CT appearance of the middle ear ligaments and the stapedius tendon as an aid in detecting abnormal changes in these structures. **METHODS:** CT scans of the temporal bone in 75 normal middle ears, obtained with 1-mm-thick sections, were reviewed by two observers, who rated the visibility of the structures of interest on a scale of 1 to 5. **RESULTS:** The anterior, superior, and lateral malleal ligaments and the medial and lateral parts of the posterior incudal ligament were seen in 68%, 46%, 95%, 26%, and 34% of the ears, respectively. The stapedius tendon was seen in 27% of the cases. When visible, the ligaments were judged to be complete in 90% to 100% of the ears and the stapedius tendon was complete in 65% of cases. Their width varied considerably. Interobserver variability was high for most observations. **CONCLUSION:** CT scans are more likely to show the malleal than the incudal ligaments. Although the interobserver agreement was statistically significant for most study parameters, the percentage of agreement above that expected by chance was low. When seen, the ligaments usually appeared complete. Understanding the normal range of appearance may help identify abnormalities of the ligaments and tendons of the middle ear.

Index terms: Ear, anatomy; Ear, computed tomography

AJNR Am J Neuroradiol 18:471-477, March 1997

High-resolution computed tomography (CT) of the temporal bone has been the method of choice for evaluating middle ear disease since the late 1970s and early 1980s. Many authors have described the normal appearance and abnormal changes of the ossicles (1-5); a few studies have focused on the normal and abnormal variations of the ossicular ligaments (6). Work related to the high-resolution CT appearance of the normal tendons and ligaments of the middle ear was done as part of a study of ossification of the stapedius tendon (7). In that

study, 50 normal middle ears were examined to establish the range of variation in the stapedius tendon as compared with a group of abnormal ears (7).

Since 1992 there has been a major change in CT equipment having to do with improvements in tube, detector, and collimator technology. One-millimeter-thick sections are now available. The resultant gain in spatial and contrast resolution can potentially improve the visibility of the middle ear ligaments and stapedius tendon.

The purpose of this study was to establish the normal range of variation in the CT appearance of the ossicular ligaments and the stapedius tendon and to anticipate the value of these normative data in evaluating middle ear disease and conductive hearing loss. Illustrative cases are provided.

Materials and Methods

Seventy-five high-resolution CT examinations of 50 normal middle ears were reviewed (both middle ears were studied in 25 cases). The studies were selected from ar-

Received May 28, 1996; accepted after revision September 24.

The visiting research fellowship of Dr Lemmerling is supported by a grant from the Royal Belgian Society of Radiology (Koninklijke Belgische Vereniging voor Radiologie/Société Royale Belge de Radiologie).

From the Departments of Radiology (M.M.L., H.E.S., A.A.M.), Otolaryngology (P.J.A.), and Biostatistics (P.S.K.), University of Florida College of Medicine, Gainesville; and Dienst Radiologie en Medische Beeldvorming (M.M.L.), Universitair Ziekenhuis Gent, Belgium.

Address reprint requests to Anthony A. Mancuso, MD, Department of Radiology, Box 100374, University of Florida College of Medicine, 1600 SW Archer Rd, Gainesville, FL 32610.

AJNR 18:471-477, Mar 1997 0195-6108/97/1803-0471

© American Society of Neuroradiology

TABLE 1: Origin and insertion of suspensory middle ear ligaments

Ligament	Origin	Insertion
Anterior malleal	Head of the malleus	Anterior epitympanic wall
Lateral malleal	Neck of the malleus	Bony margin of tympanic notch
Superior malleal	Head of the malleus	Roof of the middle ear cavity
Posterior incudal	Short process of the incus	Fossa incudis

chived reports and consisted of patients examined for sensorineural hearing loss, vertigo, tinnitus, or minor developmental inner ear malformations considered unlikely to be associated with alterations of middle ear anatomy (eg, large vestibular aqueduct). Ears with any evidence of conductive hearing loss were excluded from this analysis. In some patients with unilateral conductive hearing loss or trauma, studies of the contralateral ear were included in the study.

Axial and coronal scans of the temporal bone were obtained with a General Electric Advantage CT scanner (General Electric Medical Systems; Milwaukee, Wis) with HiLite detectors at 120 kV and 200 mAs, and a scanning time of 2 seconds. Contiguous axial sections were made parallel to the infraorbital-meatal line or hard palate with a thickness of 1 mm. Coronal sections were made as nearly perpendicular to the axial plane as possible. Images were reconstructed with a bone algorithm, a matrix size of 512×512 , and a 9.6-cm field of view. Images were retrieved from a digital archive and viewed on an independent workstation (ISG Technology Diagnostic Review Station) at a magnification factor of 1.8 to 2.0 and at a window level of approximately 200 Hounsfield units (HU) and window width of approximately 4000 HU. Window widths up to 5000 HU were used to occasionally improve visibility of the ligaments.

Sample temporal bone CT examinations and a histopathologic resource were reviewed before the start of the study to create a consensus among the investigators as to the criteria used to define a ligament, its completeness, and its width. An ossicular ligament was defined as the linear soft-tissue density seen along the expected course of the ligament between its two osseous points of attachment, as summarized in Table 1. Since the posterior incudal ligament has fibers inserting on the medial and lateral walls of the incudal fossa, these two observations were scored separately (8).

Data concerning the ligaments were collected in the scan plane parallel to the long axis of the ligament in question. The anterior malleal ligament, the medial and lateral incudomalleal ligaments, and the posterior incudal ligament were studied on axial sections, while the superior and lateral malleal ligaments were studied in the coronal plane. Ligamentous visibility was scored 1 to 5 as follows: 1 indicates not seen; 2, probably not seen; 3, indeterminate; 4, probably seen; and 5, definitely seen. Ligament width, estimated by comparing the ligament with the anterior crus of the stapes on the axial images and with the tensor tympani tendon on the coronal images, was judged on a scale of 1 to 5 points, where 1 indicates half the width

or less; 2, smaller; 3, equal; 4, larger; and 5, double the width or thicker. If the ligament was ossified, the impression of ossification was confirmed by performing a density measurement and comparing it with the bone of the otic capsule. Density values of 400 HU or more were accepted as evidence of ligamentous calcification or ossification. Completeness of the ligament was judged in cases rated 4 or 5 on the visibility scale as follows: 1 indicates not complete; 2, probably not complete; 3, indeterminate; 4, probably complete; and 5, definitely complete. A ligament was considered complete if it could be seen in its entirety between both points of attachment on one section or it could be reasonably traced continuously on two or three contiguous sections between its points of attachment.

The visibility and completeness of the stapedius tendon were rated in the axial plane on the same scale used for the ligaments. The width of the tendon was compared with the anterior crus of the stapes when the visibility of the tendon was rated 4 or 5 on the visibility scale.

The analysis of normal structures was done independently by two observers, a junior attending nonspecialty-trained radiologist and a second-year neuroradiology fellow. Interpretations were considered to be in agreement if they differed by no more than one unit on the rating scale. Statistical analysis was undertaken to determine the sensitivity of visualization by both raters and to establish interobserver variability as expressed as a percentage of agreement within one unit. This analysis assumed that all ligaments are normally present. The κ statistic, which estimates the proportion of interrater agreement above that expected by chance, was computed for each ligament and tendon seen, and was tested for significant difference greater than 0. Spearman's rank correlation coefficient was used to assess the degree of correlation between age and visibility scores and the degree of within-subject correlation between left- and right-side visibility scores for the 25 patients in whom both ears were included in the study. The Kruskal-Wallis test was used to compare the rank of visibility among three subject groups defined by ordered age intervals.

Results

Of the 50 patients studied, 30 were female and 20 were male. The mean age was 35 years (range, 1 to 77 years). CT findings were stratified into three age groups: 16 patients between 1 and 18 years old, 17 patients between 19 and 47 years old, and 17 patients between 48 and

TABLE 2: Visibility of the ligaments (n = 75)

Ligament	Sensitivity*	Percentage of Agreement†	Percentage of Expected Agreement‡	κ §	P§
AML	A: 64 (68) B: 71	66	54	.26	.005
SML	A: 49 (46) B: 43	83	46	.68	<.0001
LML	A: 98 (95) B: 92	92	91	.12	.029
PIL (m)	A: 24 (26) B: 27	67	50	.33	<.0001
PIL (l)	A: 36 (34) B: 32	60	49	.21	.020
MIL	A: 36 (42) B: 47	53	44	.16	.042
LIL	A: 0 (0) B: 0	99	99	0	.500

Note.—AML indicates anterior malleal ligament; SML, superior malleal ligament; LML, lateral malleal ligament; PIL (m), medial part of posterior incudal ligament; PIL (l), lateral part of posterior incudal ligament; MIL, medial incudomalleal ligament; LIL, lateral incudomalleal ligament; A, first rater; and B, second rater.

* Values in parentheses are the mean sensitivities for both raters.

† Percentage of agreement within one unit between the two raters.

‡ Percentage of agreement within one unit expected by chance given each rater's distribution of ratings.

§ For agreement within one unit.

77 years old. No correlation with age was found for any of the study parameters. No left versus right within-subject correlation was found for any of the parameters in the population group in which both ears were studied.

Findings of the visibility, width, and completeness of the ossicular ligaments and statistical analysis with regard to interobserver variability are summarized in Tables 2 through 4. Data in Tables 2 and 4 relate to visibility or completeness ratings of 4 (probably seen/probably complete) and 5 (definitely seen/definitely complete). In Table 3, the average score is given, based on a rating scale of 1 to 5, as described before.

Table 5 contains data relating to the visibility and completeness of the stapedius tendon. The average score for the ligament width was 3.26 and 2.41, respectively, for the two raters, with a standard deviation of 0.87 and 1.23, respectively.

Discussion

The ossicular ligaments, the tensor tympani tendon, and the stapedius tendon contribute to the normal conduction of sound across the middle ear. The anterior, lateral, and superior mal-

leal ligaments and the posterior incudal ligament are suspensory ligaments that connect the malleus and incus to the tympanic wall (Table 1). The malleus and incus are connected by the diarthrodial incudomalleal joint, which has a capsule as well as medial and lateral incudomalleal ligaments. The incus lenticular process and the head of the stapes are connected at the incudostapedial joint. The annular ligament, connecting the stapes footplate to the oval window, was not included in this analysis, since this ligament cannot be reliably separated from the footplate on high-resolution CT studies. The tensor tympani tendon and stapedius tendon limit the ossicular chain motion. The anterior malleal ligament, the incus short process, and the posterior incudal ligament are classically described as the axis around which the ossicles rotate. However, a recent study suggests that this motion is only sustained in low frequencies, while at mid and high frequencies, additional or even predominantly translational motion occurs (9). Abnormal calcification or absence of these suspensory structures has been associated with conductive hearing loss (10).

In the process of establishing criteria for evaluating the ligaments, we recognized that differentiating among ligaments, mucosal folds, and thin bony septa in the middle ear cavity might be difficult. This difficulty was expected to be the source of uncertainty in the recognition of normal ligaments and to result in a lack of complete agreement between the observers. The data in Table 2 confirm these expectations, except for the findings in the lateral malleal ligament. All other normal ligaments and the stapedius tendon were seen in only 25% to 67% of cases and, although the agreement between the two observers is statistically significant, the agreement above that obtained by chance is low ($\kappa < .4$), except for the superior malleal ligament, where this degree is moderate ($\kappa = .68$). These data suggest that, in patients with conductive hearing loss, ligaments seen "too well" may be a sign of abnormal involvement. Some guidelines are available from our data to suggest when a ligament may be too thick. These are apparent if one carefully examines the mean scores and standard deviations provided in Table 3. Those data suggest that the malleal ligaments may be abnormally thickened if they are twice as wide as the anterior stapes crus or tensor tympani tendon. Raw data on this matter (not shown in the Table) empha-

TABLE 3: Width of the ligaments

Ligament	Mean Score	SD	Percentage of Agreement*	Percentage of Expected Agreement†	κ ‡	<i>P</i> ‡
AML (n = 50)	A: 3.79 B: 3.79	A: 1.00 B: 0.95	89	76	.56	.009
SML (n = 40)	A: 2.78 B: 2.64	A: 0.85 B: 0.86	90	80	.50	.044
LML (n = 72)	A: 2.84 B: 3.03	A: 0.66 B: 0.83	88	85	.22	.097
PIL (m) (n = 19)	A: 3.62 B: 3.35	A: 1.15 B: 0.87	89	84	.31	.285
PIL (l) (n = 25)	A: 4.22 B: 3.37	A: 1.01 B: 0.97	77	76	.03	.471

Note.—AML indicates anterior malleal ligament; SML, superior malleal ligament; LML, lateral malleal ligament; PIL (m), medial part of posterior incudal ligament; PIL (l), lateral part of posterior incudal ligament; MIL, medial incudomalleal ligament; LIL, lateral incudomalleal ligament; A, first rater; and B, second rater.

* Percentage of agreement within one unit between the two raters.

† Percentage of agreement within one unit expected by chance given each rater's distribution of ratings.

‡ For agreement within one unit.

TABLE 4: Completeness of the ligaments

Ligament	Sensitivity*	Percentage of Agreement†	Percentage of Expected Agreement‡	κ §	<i>P</i> §
AML (n = 50)	A:100 (98) B: 96	97	97	−0	...
SML (n = 40)	A: 92 (95) B: 97	97	97	0	...
LML (n = 72)	A: 92 (93) B: 94	88	86	.14	.069
PIL (m) (n = 19)	A:100(100) B:100	100	100
PIL (l) (n = 25)	A:100(100) B:100	100	100

Note.—AML indicates anterior malleal ligament; SML, superior malleal ligament; LML, lateral malleal ligament; PIL (m), medial part of posterior incudal ligament; PIL (l), lateral part of posterior incudal ligament; MIL, medial incudomalleal ligament; LIL, lateral incudomalleal ligament; A, first rater; and B, second rater.

* Values in parentheses are the mean sensitivities for both raters.

† Percentage of agreement within one unit between the two raters.

‡ Percentage of agreement within one unit expected by chance given each rater's distribution of ratings.

§ For agreement within one unit.

size that this is particularly true for the lateral and superior malleal ligaments, whose width was rated as twice as wide in only 3% and 10% of normal ears, respectively. This is in contrast to the observations in the anterior malleal ligament, which was rated twice as thick as the anterior stapes crus in 25% of normal ears.

In general, the malleal ligaments are better seen than those of the incus on high-resolution CT scans (Figs 1–4). The lateral malleal ligament is seen most frequently (Fig 2); this ligament delineates the upper limit of Prussak's space (11). Bony spurs of the anterior tympanic

wall, nearby anterior epitympanic recess, and superior tympanic wall complicate the observations with regard to the anterior and superior malleal ligaments (Fig 4). These bone spurs, when thin and/or volume averaged, may be confused with normal ligaments. While density measurements proved helpful for discriminating between a bony septum and a ligament at times, these measurements were often unreliable because of the smallness of the measured structure and resultant volume averaging with air. In a similar manner, volume averaging of the bony walls of the incudal fossa, especially

TABLE 5: Visibility and completeness of the stapedius tendon

	Sensitivity*	Percentage of Agreement†	Percentage of Expected Agreement‡	κ §	P§
Visibility of tendon (n = 75)	A: 29 (27) B: 24	64	51	.26	.005
Completeness of tendon (n = 19)	A: 63 (65) B: 67	100	51	1	.004

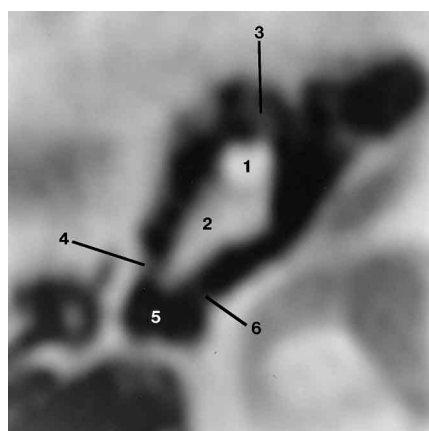
Note—n indicates number of ears studied; A, first rater; B, second rater.

* Values in parentheses are the sensitivities for both.

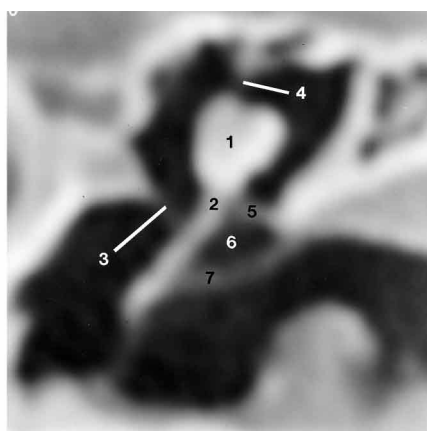
† Percentage of agreement within one unit between the two raters.

‡ Percentage of agreement within one unit expected by chance given each rater's distribution of ratings.

§ For agreement within one unit.



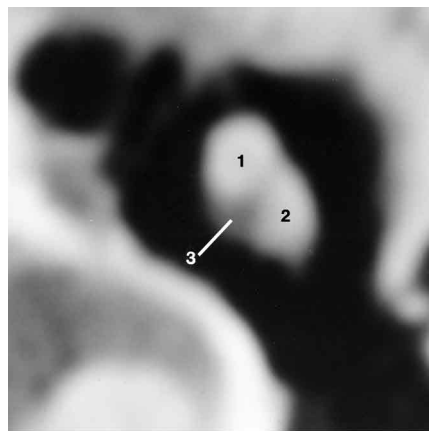
1



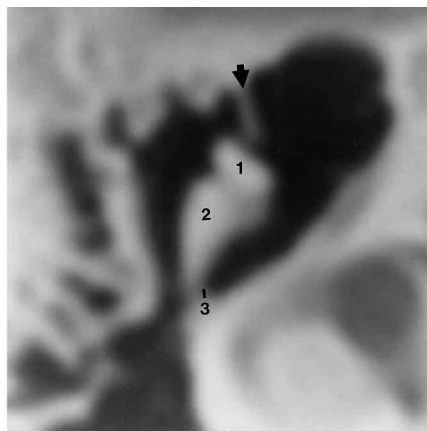
2

Fig 1. Axial 1-mm-thick CT section through a normal epitympanum shows the malleus head (1), incus body and short process (2), anterior malleal ligament (3), lateral part of the posterior incudal ligament (4), incudal fossa (5), and medial part of the posterior incudal ligament (6).

Fig 2. Coronal 1-mm-thick CT section through the malleus in a normal ear shows the malleus head (1), malleus neck (2), tensor tympani tendon (3), superior malleal ligament (4), lateral malleal ligament (5), Prussak's space (6), and tympanic membrane (7).



3



4

Fig 3. Axial 1-mm-thick CT section through the normal incudomalleal articulation shows the malleus head (1), incus body (2), and presumed medial incudomalleal ligament (3).

Fig 4. Axial 1-mm-thick CT section through a normal incudomalleal articulation shows a bony spur in the region of the anterior malleal ligament (arrow) and the malleus head (1), incus body and short process (2), and medial part of the posterior incudal ligament (3).

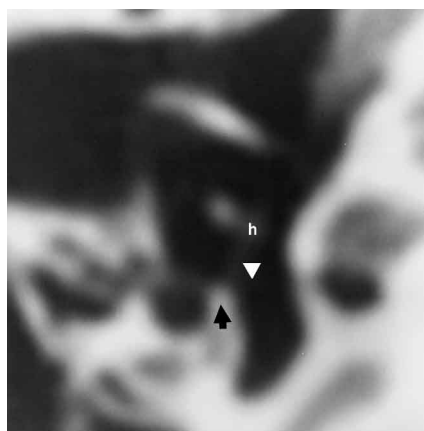
when the fossa is narrow, limits the reliability of the observations with regard to the medial and lateral parts of the posterior incudal ligament.

The malleal and incudal ligaments appeared complete in 90% to 100% of cases when they were rated as probably or definitely visible. In contrast, the ligament width varied considerably; thus, abnormal thickening of the ligaments should be

diagnosed with caution. A normal ligament was only occasionally twice as thick as the tensor tympani tendon or anterior stapes crus and tended to be equal to or slightly thicker than those reference structures in most cases. These criteria have yet to be tested in a clinical series.

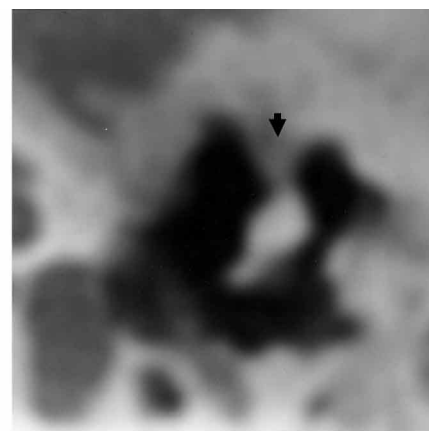
The medial incudomalleal ligament was seen in 42% of cases and the lateral incudomalleal ligament

Fig 5. Axial 1-mm-thick CT section through the incudostapedial articulation in a normal mesotympanum shows the stapedius tendon (*arrowhead*) coursing from the pyramidal eminence (*arrow*) to the stapes head (*h*).

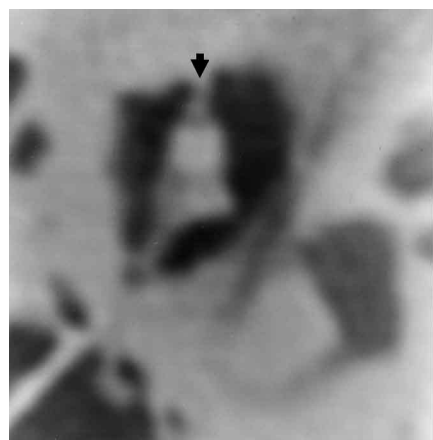


5

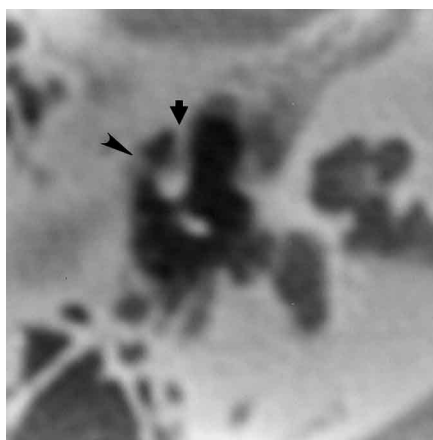
Fig 6. Axial 1-mm-thick CT section through the malleus head in a patient with conductive hearing loss shows abnormal thickening of the anterior malleal ligament (*arrow*).



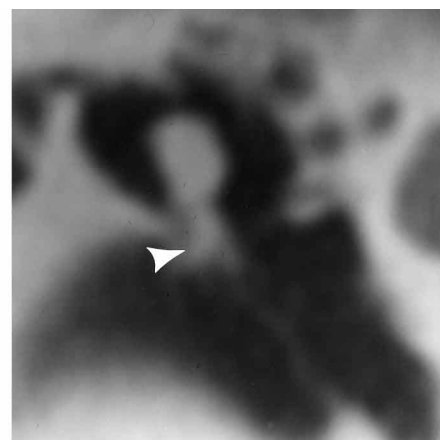
6



A



B



C

Fig 7. A and B, Axial CT sections show thick and calcified anterior (*arrows*) and lateral (*arrowhead*) malleal ligaments in a patient with conductive hearing loss.

C, Coronal CT section shows Prussak's space being obliterated by the abnormal lateral malleal ligament (*arrowhead*). CT findings were surgically confirmed.

was never seen (Fig 3). Since human histopathologic sections through this area do not provide an obvious explanation for this discrepancy (8), it is most likely related to volume averaging by the bone near the medial lip of the cup-shaped articular surface of the incus body.

The stapedius muscle is the smallest of all skeletal muscles. It arises within the interior of the hollow pyramidal eminence and from a sulcus in the wall of the third segment of the facial canal. The stapedius tendon escapes through an opening on top of the pyramidal eminence to insert on the head or the posterior crus of the stapes (12). The stapedius tendon was seen in 27% of cases and, when seen, appeared complete in 65% of cases (Fig 5). In 1995, Kurosaki et al (7) reported the findings in nine ears with congenital ossification of the stapedius tendon.

These authors concluded that a linear area of soft-tissue attenuation extending from the pyramidal eminence to the monopod stapes is suggestive of congenital ossification of the stapedius muscle tendon or a bony bar adjacent to it. Their conclusion was based on a control group of 50 normal middle ears, in which the tendon was never seen clearly. The discrepancy between their findings and the findings in this study is probably explained by a difference in CT technique; their study was done with 1.5-mm-thick CT sections and less sensitive tube and detector systems than used in this study. In light of the normative data presented here, their results will need to be revisited with a higher degree of spatial resolution.

In summary, knowledge of the normal rate of visibility and range of variation in the appear-

ance of the ligaments and stapedius tendon of the middle ear may be helpful in examining patients with conductive hearing loss. Ligaments that are seen "too well" (Figs 6 and 7) on high-resolution CT scans, such as described in this study, might, in the proper clinical setting, be a sign of abnormal change.

Acknowledgment

We thank Tony Litwiller for his help in making the illustrations and in providing technical data on the CT equipment.

References

1. Swartz JD. High-resolution computed tomography of the middle ear and mastoid, I: normal radioanatomy including normal variations. *Radiology* 1983;148:449-454
2. Swartz JD, Goodman RS, Marlowe FI, Wolfson RJ. High-resolution computed tomography of the middle ear and mastoid, II: tubotympanic disease. *Radiology* 1983;148:455-459
3. Swartz JD, Goodman RS, Russell KB, Landenheim SE, Wolfson RJ. High-resolution computed tomography of the middle ear and mastoid, III: surgically altered anatomy and pathology. *Radiology* 1983;148:461-464
4. Johnson DW, Hinshaw DB, Hasso AN, Thompson JR, Stewart CE III. Computed tomography of local complications of temporal bone cholesteatomas. *J Comput Assist Tomogr* 1985;9:519-523
5. Fuse T, Aoyagi M, Koike Y, Sugai Y. Diagnosis of the ossicular chain in the middle ear by high-resolution CT. *ORL J Otorhinolaryngol Relat Spec* 1992;54:251-254
6. Swartz JD, Wolfson RJ, Marlowe FI, Popky GL. Postinflammatory ossicular fixation: CT analysis with surgical correlation. *Radiology* 1985;154:697-700
7. Kurosaki Y, Kuramoto K, Matsumoto K, Itai Y, Hara A, Kusakari J. Congenital ossification of the stapedius tendon: diagnosis with CT. *Radiology* 1995;195:711-714
8. Schucknecht HF, Gulya AJ. The middle ear. In: *Anatomy of the Temporal Bone with Surgical Applications*. Philadelphia, Pa: Lea & Febiger; 1986:47-76
9. Decraemer WF, Khanna SM. Modelling the malleus vibration as a rigid body motion with one rotational and one translational degree of freedom. *Hear Res* 1994;72:1-18
10. Goodhill V. *Diseases, Deafness and Dizziness*. Hagerstown, Md: Harper & Row; 1979:132-135
11. Proctor B, Alexander Prussak. *Ann Otol Rhinol Laryngol* 1968; 77:344-349
12. Donaldson JA, Duckert LG, Lambert PM, Rubel EW. *Surgical Anatomy of the Temporal Bone*. 4th ed. Philadelphia, Pa: Saunders; 1992:156