

Intense Emotional Stress Over Potential Coronavirus Disease Vaccination Side Effects Leads to Takotsubo Cardiomyopathy

Takahiro Sakamoto, MD; Yuzo Kagawa, MD;
Akihiro Endo, MD, PhD; Kazuaki Tanabe, MD, PhD

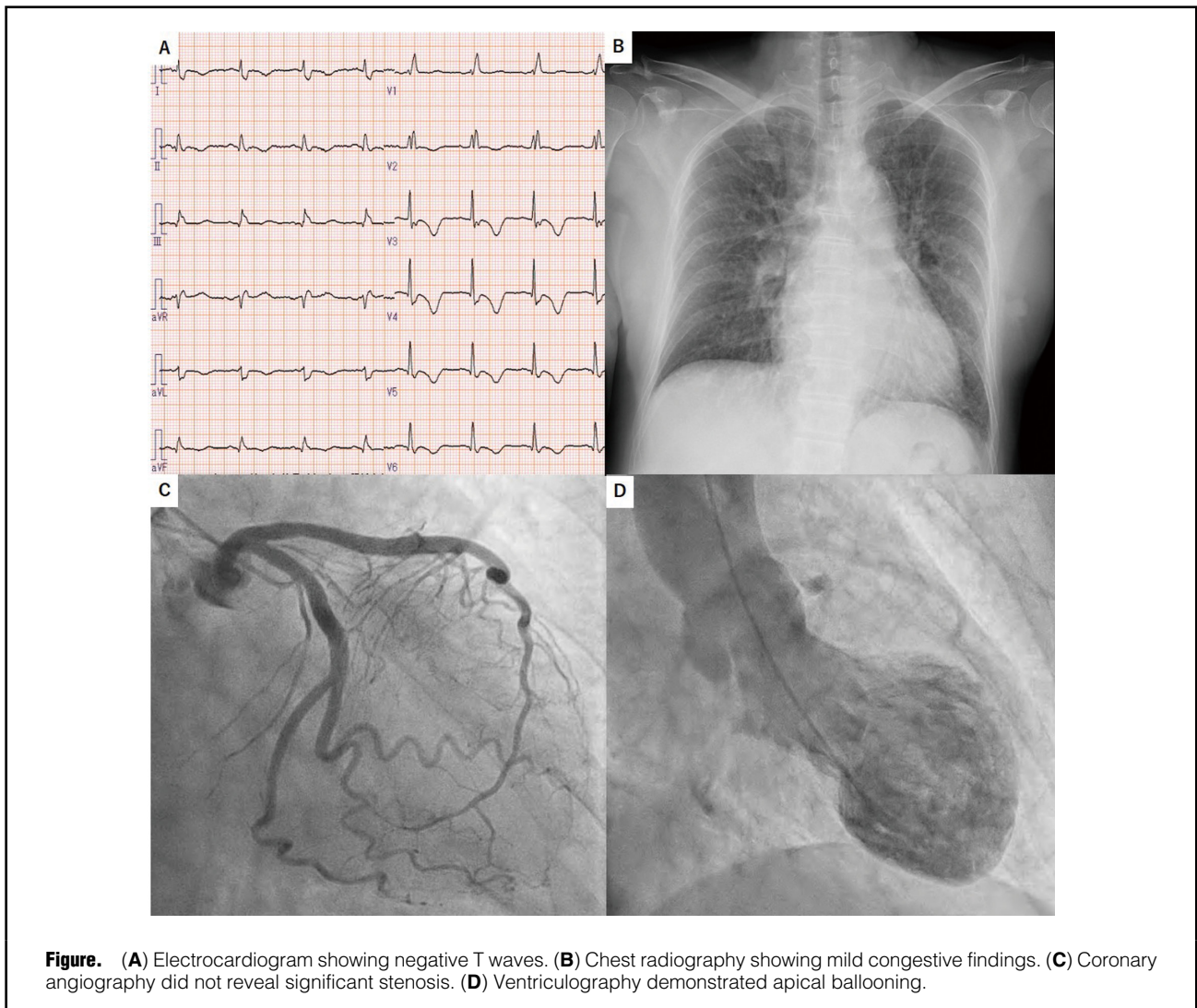


Figure. (A) Electrocardiogram showing negative T waves. (B) Chest radiography showing mild congestive findings. (C) Coronary angiography did not reveal significant stenosis. (D) Ventriculography demonstrated apical ballooning.

Received June 15, 2021; accepted June 15, 2021; J-STAGE Advance Publication released online July 10, 2021 Time for primary review: 1 day

Division of Cardiology, Shimane University Faculty of Medicine, Izumo, Japan

K.T. is a member of *Circulation Reports*' Editorial Team.

Mailing address: Takahiro Sakamoto, MD, Division of Cardiology, Shimane University Faculty of Medicine, 89-1 Enya-cho, Izumo 693-8501, Japan. E-mail: t.saka@med.shimane-u.ac.jp

All rights are reserved to the Japanese Circulation Society. For permissions, please e-mail: cr@j-circ.or.jp

ISSN-2434-0790



Takotsubo cardiomyopathy (TCM) is often triggered by intense emotional stress. Here we report a case of TCM induced by stress due to concerns about side effects after being vaccinated for coronavirus disease (COVID)-19.

A 64-year-old woman received COVID-19 vaccines on April 26 and May 17, 2021, and no post-vaccination side effects were noted. However, her anxiety grew as she regularly heard about the potential side effects of the COVID-19 vaccine on various media platforms. On May 27, she presented to Shimane University Hospital with severe chest pain. The electrocardiogram showed negative T waves (**Figure A**) with positive troponin I. Mild congestion was observed on radiography (**Figure B**), and echocardiography revealed left ventricular apical akinesia and basal hyperkinesia. Emergency coronary angiography showed no significant stenosis (**Figure C**), whereas left ventriculography demonstrated apical ballooning (**Figure D; Supplementary Movie**). The left ventricular wall motion improved without any medical treatment. The patient was discharged on Day 10 without any complications.

TCM caused by intense emotional stress from voluntary quarantine during the COVID-19 crisis has been reported;¹ however, this is the first report on TCM triggered by stress

and concern about COVID-19 vaccine side effects. In Japan, many patients are concerned about vaccine side effects, and it may be necessary to pay attention to a possible increase in TCM cases in the future.

Disclosures

K.T. is a member of *Circulation Reports*' Editorial Team. The other authors declare no conflicts of interest.

IRB Information

This study was approved by the Shimane University Faculty of Medicine Ethics Committee (Reference no. 5588).

Reference

1. Sakamoto T, Endo A, Yoshitomi H, Tanabe K. Takotsubo cardiomyopathy caused by intense emotional stress induced by voluntary quarantine during the coronavirus disease crisis. *Circ Rep* 2020; **2**: 382–383.

Supplementary Files

Supplementary Movie. Left ventriculography.

Please find supplementary file(s);
<http://dx.doi.org/10.1253/circrep.CR-21-0075>