

Giant Perimedullary Arteriovenous Fistulas of the Spine: Clinical and Radiologic Features and Endovascular Treatment

F. Ricolfi, P. Y. Gobin, A. Aymard, F. Brunelle, A. Gaston, and J. J. Merland

PURPOSE: To present the clinical and radiologic features of giant perimedullary arteriovenous fistulas (GAVFs) in 12 consecutive cases and to evaluate the results of endovascular treatment. **METHODS:** We retrospectively reviewed the clinical and radiologic data as well as the results of balloon endovascular treatment obtained from 1980 to 1989. **RESULTS:** GAVFs, defined as large intradural perimedullary direct arteriovenous high-flow shunts, are revealed mainly in childhood either by subarachnoid hemorrhage or by progressive neurologic disorders. MR imaging and myelography show major vascular dilatations. The angioarchitecture of GAVFs can only be assessed by selective spinal angiography. Ten patients were treated by balloon occlusion resulting in eight anatomic cures and six good clinical results. One balloon migrated to the venous side, leading to clinical deterioration. **CONCLUSION:** GAVF is a special subgroup of intradural perimedullary arteriovenous fistula. The endovascular approach should be the first line of treatment, with surgery reserved for special circumstances. Nondetachable balloon occlusion is a safe and efficient method for treating GAVFs.

Index terms: Fistula, arteriovenous; Fistula, therapeutic blockade; Spinal cord

AJNR Am J Neuroradiol 18:677-687, April 1997

Giant perimedullary arteriovenous fistula (GAVF) is a rare intraspinal vascular malformation that consists of a large direct arteriovenous shunt between anterior and/or posterior spinal arteries and a spinal vein. The shunt is intradural and lies on the surface of the spinal cord (1, 2). Selective spinal cord angiography enables this lesion to be distinguished from other, more common dural or intradural vascular malformations. These GAVFs are usually revealed in childhood by subarachnoid hemorrhage or by a progressive neurologic deficit. We report the clinical and radiologic findings of 12 consecutive cases of GAVFs and present the outcome of endovascular treatment. GAVF, with its specific

single-shunt pattern, is suitable for balloon occlusion.

Material and Methods

Patients

From 1980 to 1989, 12 patients with GAVFs were admitted for examination and treatment. Two patients from this series (cases 3 and 4) have been the subjects of previous reports (3, 4). The data obtained from clinical records, radiologic studies, and follow-up examinations were available in 11 of the 12 cases.

Clinical data are summarized in Table 1. The first symptoms appeared before the age of 10 years in eight patients and before the age of 40 years in all cases. Clinical presentation consisted of subarachnoid hemorrhage in five cases (three isolated and two associated with regressive paraplegia), sudden and regressive hemiplegia in one case, progressive paraparesis or tetraparesis in three cases, sciatic pain in two cases, and isolated sphincter disturbances in one case. The interval between initial symptoms and treatment ranged from 1 week to 23 years (mean, 5 years). The clinical course consisted of progressive deterioration in nine cases and acute neurologic deterioration in two cases. Three patients had an initial subarachnoid hemorrhage with normal findings at cerebral angiography followed by progressive paraparesis a few

Received April 4, 1995; accepted after revision October 7, 1996.

From the Service de Neuroradiologie, Hôpital Henri Mondor, Créteil (F.R., A.G.), the Service de Neuroradiologie Interventionnelle, Hôpital Lariboisière, Paris (P.Y.G., A.A., J.J.M.), and the Service de Radiologie, Hôpital Necker Enfants Malades, Paris (F.B.), France.

Address reprint requests to Frederic Ricolfi, MD, Service de Neuroradiologie, Hôpital Henri Mondor, 51, avenue du Marechal delattre de Tassigny, 94010, Créteil, France.

AJNR 18:677-687, Apr 1997 0195-6108/97/1804-0677

© American Society of Neuroradiology

TABLE 1: Clinical findings in 12 patients with giant arteriovenous fistula (GAVF)

Case	Age, y, at Diagnosis and Treatment/Sex	Site of GAVF	Initial Symptoms	Clinical Course	Symptoms at Treatment
1	2, 5/F	C-5	Hemiplegia	Progressive deterioration over 3 y	Tetraparesis
2	0.3, 5/F	L-1	Regressive paraplegia	Two episodes of regressive access	Sphincter disturbance
3	24, 43/M	L-1	SAH	Progressive paraparesis over 2 y	Paraparesis
4	19, 22/M	T-11	SAH	Progressive deterioration over 1 y	Brown-Séquard paralysis at L T-10
5	9, 10/M	T-9	Paraparesis	Progressive deterioration over 1 y	Paraparesis
6	5, 28/M	T-8, L1	SAH with regressive paraplegia	Progressive deterioration over 10 y	Sciatic pain and sphincter disturbance
7	4, 5/M	C-6	Paraparesis	Progressive deterioration over 1 y	Tetraparesis
8	2, 4/M	T-12	SAH	Progressive deterioration over 1 y and second SAH	Paraplegia
9	4, 6/M	T-12	Sciatic pain	Stepwise progression	Cauda equina syndrome
10	39, 39/F	L-2	Sphincter disturbance	Progressive over 6 mo	Sphincter disturbance
11	28, 33/F	T-12	Sciatic pain	Stable	Sciatic pain
12	5, 5/M	L-1	SAH with paraplegia	Regressive access	Normal

Note.—SAH indicates subarachnoid hemorrhage.

years later. Two patients experienced deterioration of their symptoms during exertion. The upper limit of clinical symptoms (spinal and nerve root) corresponded to the level of the GAVF. The AVF was cervical in location in two cases, thoracic in one case, and at the level of the conus medullaris in eight cases. One patient (case 6) had both thoracic and lumbar GAVFs. One patient (case 1) suffered from metameric angiomatosis (Cobb syndrome) with a diffuse cutaneous high-flow arteriovenous malformation (AVM) of the upper limb and thorax associated with a cervical GAVF. Another patient (case 6) had a family history of Weber-Osler-Rendu disease. A spinal bruit was present in one patient (case 1).

Plain radiographs of the spine were obtained for all patients. Myelography was performed in nine cases. Five patients had computed tomography (CT) and five patients had magnetic resonance (MR) imaging. Since most of the CT and MR studies were performed in other hospitals, the examination protocols were not standardized. Spinal angiography was performed by a transfemoral approach, via an arterial sheath, using local anesthesia and neurolept-analgesia in adults and general anesthesia in children. Thoracoabdominal aortography was initially performed in five patients. Selective spinal angiography was performed with 5F catheters in adults and 3.6F catheters in children, with a distal end custom shaped with steam. Either ionic or nonionic contrast medium was injected. Selective injections were done by hand. Angiograms were obtained either on conventional film in the earliest cases or with the use of digital equipment at an exposure rate of one frame per second (prolonged for 25 seconds when abnormal vascularity was identified) for the more recent cases. Supine anteroposterior views were routinely obtained with additional lateral views for radiculomedullary arteries.

Radiologic findings are summarized in Table 2. Plain radiographs showed enlargement of the spinal canal in five cases (Fig 1). Large serpentine filling defects suggestive of large vessels were obvious at myelography. A partial

blockage of contrast material was observed in one case. In another case, the myelogram suggested a tumor, but an accurate diagnosis (vascular enhancement) was obtained with CT and confirmed by spinal angiography. CT was performed in five patients (in three, after intravenous administration of contrast material and in two after intrathecal administration) and showed large serpentine intradural vascular structures. MR imaging was performed in five patients, and the vascular abnormalities were always seen as large serpentine signal voids (Fig 2A and Fig 3A). In three cases a venous aneurysm compressed the cord (Fig 2A and Fig 3A). The spinal cord signal was normal in three of the five patients examined with MR imaging. In one of the remaining cases, MR images revealed a hemorrhagic area surrounding an intramedullary venous aneurysm (case 9) (Fig 2A). In the remaining case (case 12), an intramedullary low-intensity signal on a T1-weighted image above the level of the GAVF was associated with a slight enlargement of the spinal cord (Fig 3A).

Myelography, CT, and MR imaging are all able to show spinal vascular lesions, but only spinal angiography can accurately depict a GAVF by showing the high-flow shunt and the absence of interposed nidus between the arterial and venous sides of the vascular lesion (Fig 1A and B; Fig 2; and Fig 3B and C). Initial thoracoabdominal aortography identified the multiple arterial feeders of the GAVF in five cases, and in one patient (case 1) a metameric lesion was injected. Superselective angiography was required to identify the various arterial feeders, their size and tortuosity, the flow, the exact location of the shunt and its morphology, and the venous drainage. The selective angiograms guided the choice of the best approach for embolization of the malformation. Owing to the large shunt and dilution of contrast material by neighboring spinal arteries and collaterals, the side of the shunt could not always be clearly demonstrated until balloon test occlusion was performed (Fig 2B and C). The main arterial supply was derived from the anterior spinal artery in eight

TABLE 2: Radiologic findings in 12 patients with giant arteriovenous fistula

Case	Radiography	Myelography	CT	MR Imaging	Angiography: Arteries†	Angiography: Veins
1	Cervical spinal canal widening	...	Whole cervical spinal canal enhancement*	...	L C4-C6 ASA (L vertebral artery)	Huge fistula venous aneurysm
2	Normal	Large vessels	L L-2 ASA ; L T-9 ASA; R T-12 ASA	Fistula venous aneurysm
3	Normal	Large vessels	R T-10 ASA ; L L-1 ASA; R and L L-2 PSA	...
4	Normal	Large vessels	L T-11 PSA ; R T-11 PSA; R T-12 ASA	...
5	Normal	Large vessels	R T-9 PSA ; L T-6 ASA; R T-12 PSA	...
6	L1-2 spinal canal widening	Large vessels	Intradural large vessel enhancement*	Large vessels; T-8 compressive venous aneurysm	L T-10 ASA ; R T-9 PSA ; R T-12 PSA	Huge distant venous aneurysm
7	Cervical spinal canal widening	Partial block	Whole cervical spinal canal enhancement*	...	L C-5 ASA ; L C-1 ASA; R T-3 ASA	Huge fistula venous aneurysm
8	T11-12 spinal canal widening	Large vessels	Dilated perimedullary vessels†	...	L T-9 ASA	Fistula venous aneurysm
9	T11-L2 spinal canal widening	Large vessels; T-12 venous aneurysm with local hemorrhage	R T-11 PSA ; L T-9 and R L-1 ASA; L T-12 and R L-3 PSA	Distant T-12 huge venous aneurysm
10	Normal	Large vessels	L T-9 ASA ; L T-10; R T-11; L T-12; L L-2; L L-3 PSA	...
11	Normal	Large vessels	Dilated perimedullary vessels†	Large vessels	L L-1 ASA ; L T-9 ASA; L T-11 PSA	...
12	Normal	Large vessels	...	Large vessels; T-5 compressive venous aneurysm; spinal cord T2 hypersignal	L L-1 PSA ; R T-12 and R T-4 ASA; R L-2; L T-12; R and L T-7, L T-9 PSA	Huge distant T-5 venous aneurysm posterior fossa venous drainage

* Intravenous contrast-enhanced CT scan.

† Postmyelography CT scan.

‡ ASA indicates anterior spinal artery; PSA, posterior spinal artery; boldface indicates main arterial feeder.

cases (Fig 4A) and from the posterior spinal artery in five cases (Fig 2B). Venous drainage was regional (less than five metameric levels above or beneath the shunt) in 11 cases (ascending, descending, or mixed). In case 12 (conus GAVF draining to the posterior fossa via an anterior spinal vein), the venous drainage resembled that of lower flow perimedullary AVFs and of dural AVFs (Fig 3). The draining veins were severely dilated ("giant" AVF). A venous aneurysm with the radiologic features of an intraspinal space-occupying lesion was present in seven cases. The venous aneurysm was located at the AVF venous site in four cases (Fig 1) and distant from the shunt in three cases (Fig 3).

Endovascular Treatment

All adult embolization procedures were performed using local anesthesia and neuroleptanalgesia with frequent

testing of motor and sensory functions. Children younger than 12 years were treated while under general anesthesia. In case 12, somatosensory evoked cortical potentials were monitored during treatment. Except for two patients (cases 1 and 2), who were treated at the beginning of our series with gelatin sponge particles, all patients were treated by balloon occlusion.

A double femoral artery puncture was performed in all patients except one (case 7), in whom an axillary puncture was performed. One vascular approach was used to introduce the balloon and the other was used to control the other arterial feeders. Latex balloons, inflated with contrast agent, were used in all cases (Figs 1C, 2D, 3D, and 4B). In cases 3 and 4, a detachable balloon was used with an internal valve attached to the tip of a polytef catheter (outer diameter, 0.5 mm; inner diameter, 0.3 mm) and was positioned through a 7F guiding catheter. In all the following cases, the balloon delivery system consisted of a

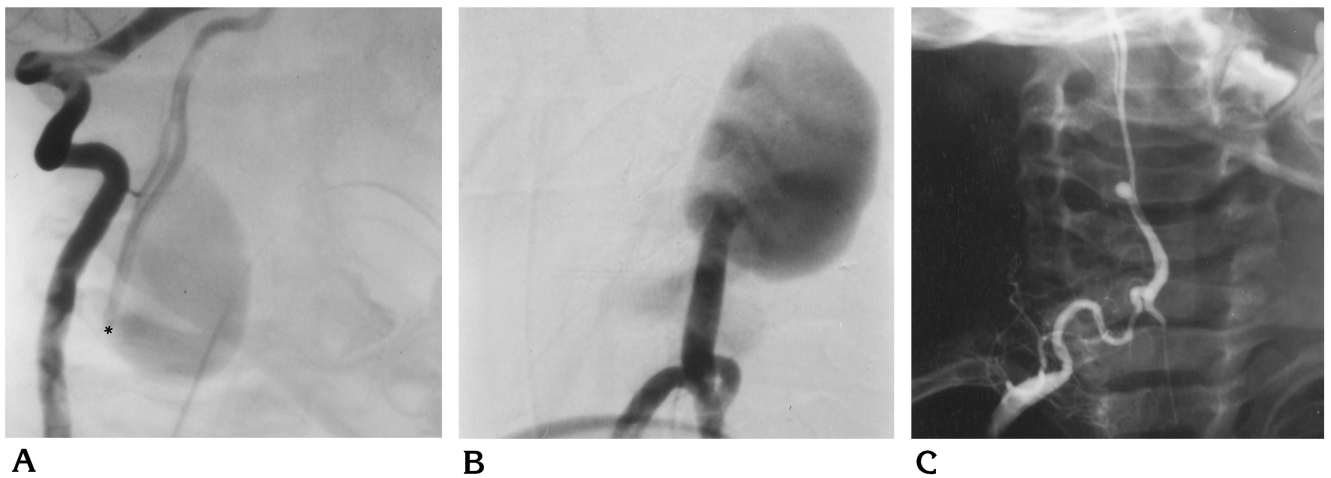


Fig 1. Case 7: 5-year-old boy with progressive tetraparesis.
 A, Anteroposterior view of right vertebral artery angiogram (head turned to left) shows fenestrated anterior spinal artery displaced to the right side of the spinal canal. The shunt (*asterisk*) fills directly a huge venous aneurysm.
 B, Lateral view of right deep cervical artery angiogram before treatment.
 C, One-month follow-up control angiogram of right deep cervical artery shows that the shunt is occluded by a nondetachable balloon (via a deep cervical artery) and the anterior spinal artery is reduced in size. Note the enlarged spinal canal.

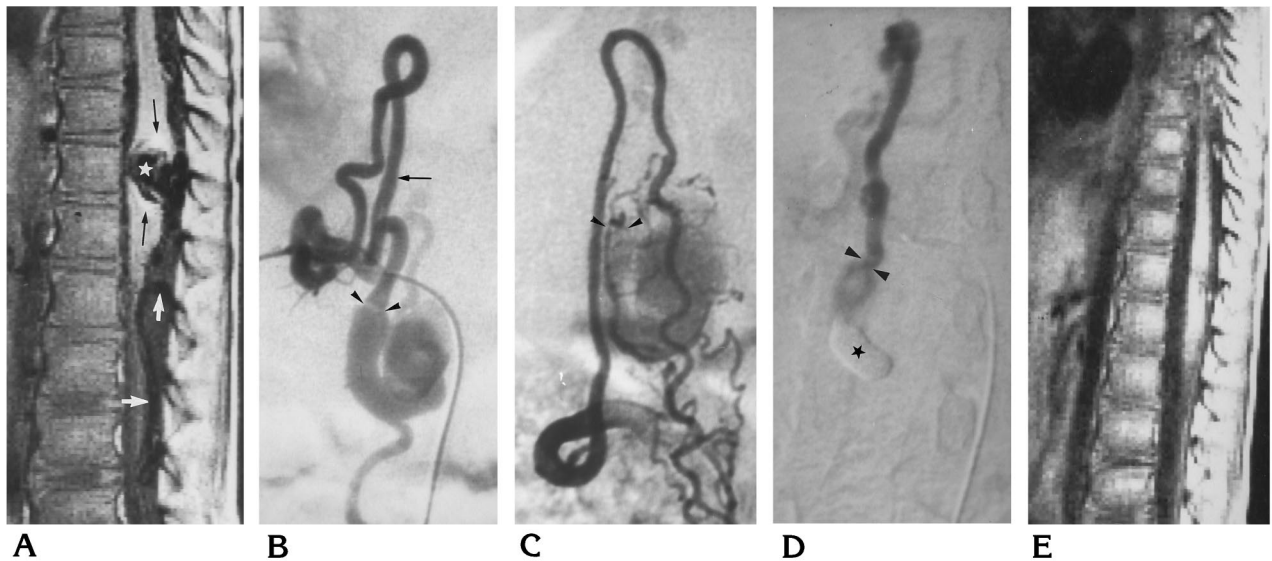


Fig 2. Case 9: 6-year-old boy with a stepwise progression of a cauda equina syndrome.
 A, Sagittal T1-weighted MR image shows a vascular aneurysm (*star*) surrounded by a rim of hyperintense signal, attributed to subacute hemorrhage (*black arrow*), which is compressing the conus medullaris. Note the intradural large vascular signal voids (*white arrows*).
 B and C, Selective angiograms of right T-11 (*B*) posterior spinal artery and right L-1 anterior spinal artery (*C*). The shunt is marked by an enlargement of the vessel (*arrowheads*). All the afferent arteries join this shunt by the perimedullary arterial network. Note the dilution of contrast material and/or an enlargement of the artery when two arterial feeders join in a common trunk before the shunt (*black arrow*).
 D, Occlusion of the GAVF by a nondetachable balloon (*star*) floated through the main arterial feeder (right T-11 posterior spinal artery) with a good clinical result. Good stability of the balloon is obtained on the venous side of the shunt (*arrowheads*).
 E, Sagittal T1-weighted MR image 3 months after treatment shows that the venous aneurysm and large vessels have disappeared. A small hypointense signal at the posterior surface of the conus remains.

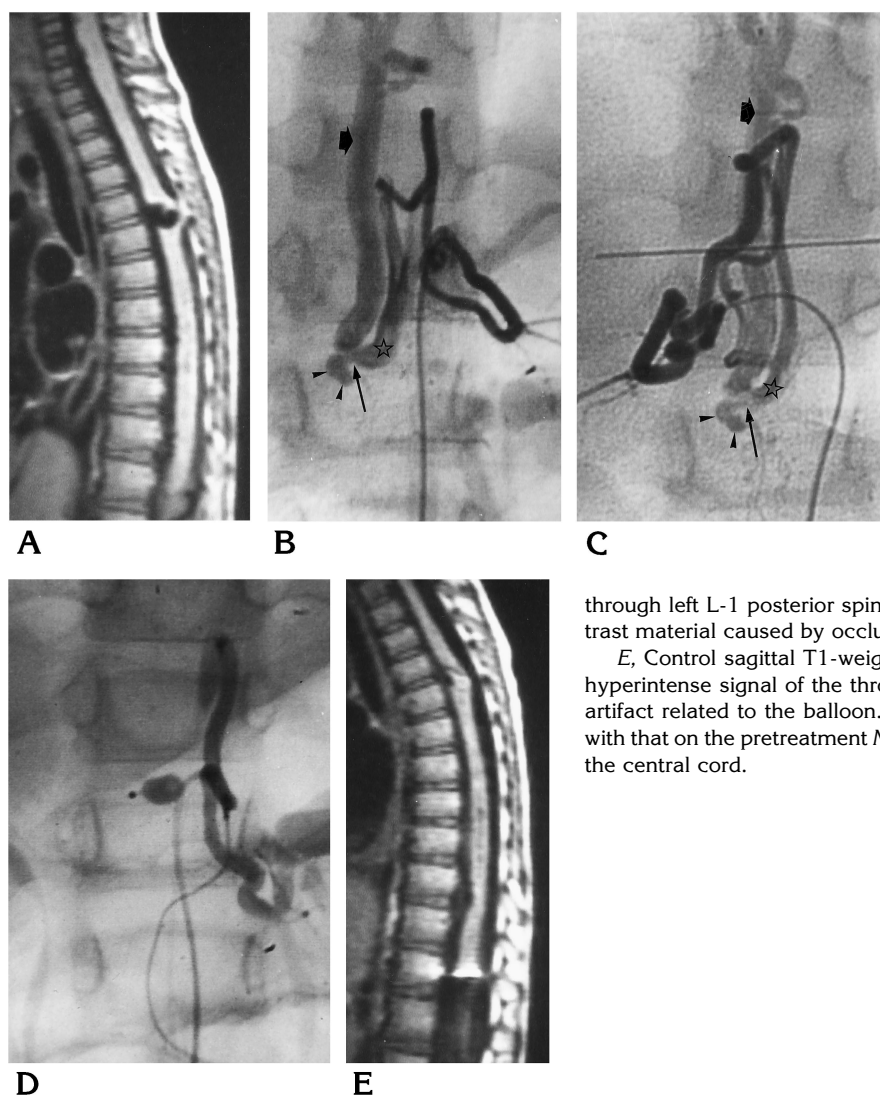


Fig 3. Case 12: 5-year-old boy with subarachnoid hemorrhage and progressive paraplegia.

A, Sagittal T1-weighted MR image shows large intradural vascular signal voids with an anterior intramedullary vascular aneurysm at T4-5 level. Note the central hypointense signal of the thoracic spinal cord.

B and C, Selective angiograms of left T-12 (B) posterior spinal artery and right T-12 anterior spinal artery (C). The shunt *situ* (long arrow) is marked by focal vascular ectasia (arrowheads). Two large arteries meet at this point: left L-1 posterior spinal artery (not shown) and a common trunk fed by right T-12 anterior spinal artery and left T-12 posterior spinal artery (star). Note the anterior ascending venous drainage (short arrow), which reaches the posterior fossa (not shown).

D, Balloon floated into the shunt through left L-1 posterior spinal artery and inflated. Note stagnation of contrast material caused by occlusion of the AVF.

E, Control sagittal T1-weighted MR image 1 week after treatment shows hyperintense signal of the thrombosed T4-5 venous aneurysm and metallic artifact related to the balloon. The spinal cord is reduced in size compared with that on the pretreatment MR image, with persistent hypointense signal of the central cord.

coaxial 1F polyethylene catheter inside a 3F polyethylene catheter (5, 6). The balloon and flexible 1F catheter were carried by blood flow to the fistula. Once the balloon was inflated, complete occlusion of the shunt was confirmed by angiograms obtained via the control catheter (Fig 3D). Balloons were either detachable (cases 5 and 6) or nondetachable (cases 7 through 12). In the latter case, the end of the polyethylene 1F catheter was enlarged by steam and introduced into the lumen of the balloon. Once the neck of the balloon was fixed well around the catheter, a short piece of supple tube, forming a cuff over the neck, secured the balloon. After the nondetachable balloon was positioned, the proximal end of the catheter was tied into several tight knots, the introducer system was withdrawn over the knots, and the knotted catheter was implanted in the subcutaneous tissues near the arterial puncture site during the same session. (At the beginning of our experience, in case 7, we left the catheter exposed at the axilla for 48 hours for the purpose of deflating the balloon in case of clinical worsening due to thrombosis. Infection at the

site of the puncture was complicated by septicemia leading to removal of the balloon system. This patient was successfully treated in a later session). The space between the two coaxial catheters is small enough to prevent blood reflux, thereby making perfusion unnecessary. No anticoagulation therapy was used during or after the procedure.

Clinical follow-up was performed 1 week, 1 month, and every year after treatment. Position and inflation of the balloon was monitored by spinal plain films until its disappearance and deflation. Angiographic follow-up was performed at 1 week and 1 year after treatment. The fistula was considered to be occluded when both shunt and venous drainage were no longer opacified by the arterial feeders and collaterals and when the spinal vessels had returned to their normal size (Fig 1C).

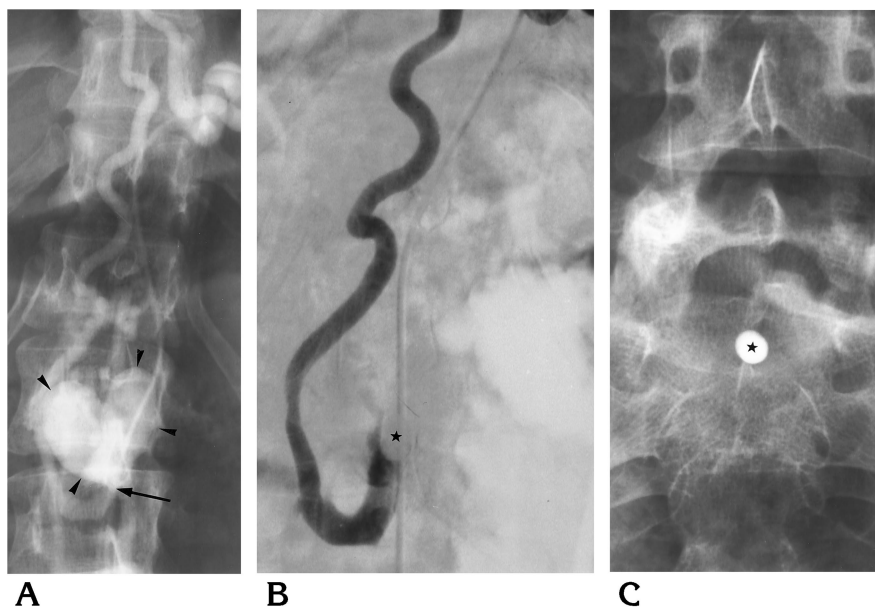
The clinical status of the patients before and after treatment was classified according to the following criteria: *good* meant the patient was independently ambulatory, with no restricted activity; *fair* indicated the need for crutches or a cane to walk, with occasional urinary incontinence or reten-

Fig 4. Case 6: Patient with subarachnoid hemorrhage with regressive paraplegia at 5 years of age and progressive cauda equina syndrome at 28 years of age. Spinal angiography revealed a double GAVF at T-8 and L-1 levels.

A, Left T-9 anterior spinal artery opacifies a single-hole shunt (arrow) at L-1 level. Shunt is marked by a venous aneurysm (arrowheads).

B, Treatment by a detachable balloon (star), which was carried to the site of the AVF through left T-9 anterior spinal artery.

C, Migration of the balloon filled with contrast material to a sacral level (star). The migrated balloon occludes the venous outflow of the GAVF distally, leading to a venous hypertension that was followed by paraplegia.



tion; and *poor* meant the patient was unable to stand and had incapacitating urinary incontinence or retention.

Results

Findings at clinical follow-up (2 to 9 years) were available for 11 of the 12 patients. Clinical and angiographic results before and after treatment are presented in Table 3.

Angiographic Results

Complete GAVF occlusion was achieved in 10 patients and partial occlusion was obtained in one patient (case 5). In this latter case, the GAVF had three arterial feeders with two shunts marked by two small ectatic veins draining into a large common vein. One shunt was completely occluded with the first balloon, the second balloon partially occluded the second shunt. Treatment failed in one patient owing to unsuccessful catheterization. This patient remained clinically unchanged during hospitalization and was subsequently lost to follow-up.

No early or late revascularization of completely treated GAVFs was observed.

Clinical Results

Good results were observed in six patients, with complete recovery and occlusion of the GAVF. Of these six patients, three were clinically classified before treatment as poor, two as fair, and one was asymptomatic. In two cases a

dramatic improvement was observed (two patients suffering from paraparesis were able to walk within 48 hours after embolization). The other patients recovered progressively over a period of 6 months. No cases of late deterioration were observed.

A fair result was observed in one patient (case 7) who had a cervical GAVF with a huge venous compressive aneurysm (Fig 1). This patient improved clinically from poor to fair. Partial recovery of tetraparesis occurred after embolization. A follow-up MR examination revealed spinal cord atrophy.

Poor results were obtained in three patients. One patient who was initially in poor clinical condition (case 2) showed no improvement despite complete occlusion of the fistula by particles with preservation of the parent artery. Another partly treated patient (case 5) obtained a good initial clinical result, which lasted 6 years. In view of this excellent result, the family declined any subsequent treatment or follow-up. Unfortunately, the patient subsequently bled and became paraplegic. Venous balloon migration occurred in another patient (case 6) (Fig 4) during the procedure, causing occlusion of a single venous outflow. This was followed by immediate clinical deterioration, leading us to occlude the main arterial feeder (left T-10 anterior spinal artery) during the same session. The patient never recovered completely.

One patient died (case 1). Sudden tetraplegia and death occurred 36 hours after a large piece

TABLE 3: Results of endovascular treatment in 12 patients with giant arteriovenous fistula

Case	Clinical Score before Treatment*	Endovascular Procedure†	Angiographic Result	Clinical Score after Treatment*	Follow-up, y‡
1	Poor	Particles (L vertebral ASA)	Cured	Death (2 d later)	...
2	Poor	Particles (L L-2 ASA)	Cured	Poor; progressive deterioration	... A:2 C:4
3	Poor	Detachable balloon (L T-10 ASA)	Cured	Good	A:0.5 C:2
4	Fair	Detachable balloon (L T-11 PSA)	Cured	Good	A:1 C:9
5	Poor	Detachable balloon (R T-9 PSA; R T-12 PSA)	Partial	Poor; initially good: SAH and paraplegia at 6 y	A:0.4 C:8
6	Fair	First procedure: detachable balloon (L T-10 ASA); second procedure: detachable balloon (R T-9 PSA)	Cured	Poor (balloon migration)	A:1 C:2
7	Poor	First procedure: nondetachable balloon (L C-5 ASA); second procedure: nondetachable balloon	Cured	Fair (sepsis, spinal cord atrophy)	A:0.3 C:8
8	Poor	Nondetachable balloon (L T-9 PSA)	Cured	Good	A:0.1 C:4
9	Poor	Nondetachable balloon (L T-9 PSA)	Cured	Good	A 0.1 C:5
10	Fair	Nondetachable balloon (L T-9 ASA)	Cured	Good	A:1 C:4
11	Good	Nondetachable balloon (L L-1 ASA)	Failure (spasm)	Unchanged
12	Good	Nondetachable balloon (PSA)	Cured	Good	A:1 C:4

* Good indicates independent ambulant patient with no restriction of activity; Fair means the patient requires crutches or one stick to walk; Poor indicates the patient is unable to stand and has incapacitating urinary incontinence or retention.

† ASA indicates anterior spinal artery; PSA, posterior spinal artery.

‡ A indicates control angiogram; C, clinical follow-up.

of gelatin sponge was used to occlude completely the three radicular feeders of a cervical GAVF with a huge venous pouch.

Discussion

Spinal AVMs are classified according to their anatomic location and angioarchitecture (7-11). The three types of vascular malformations of the spine may be distinguished by their angiographic anatomy (12): AVFs characterized by the direct communication between fewer than three arteries and a single vein, AVFs characterized by several arteries feeding shunts in the wall of a single vein, and AVFs characterized by multiple shunts (nidi) between arterioles and venules (AVMs). This distinction is of major importance, since the endovascular treatments are radically different. AVFs and

AVMs may be part of a more complex vascular malformative syndrome, such as metameric Cobb syndrome or disseminated Weber-Osler-Rendu disease.

Depending on the site of the arteriovenous anomalies (AVFs or AVMs), several anatomic groups may be described. Dural AVFs with perimedullary venous drainage are situated within the dura and are supplied by meningeal arteries. These slow-flow malformations were initially described by Kendall and Logue (13) and Merland et al (14). They are typically seen in male adults and manifested by progressive myelopathy with exacerbation of symptoms at physical activity. The myelopathy is due to venous hypertension of the spinal cord.

Epidural AVFs with or without perimedullary venous drainage may clinically resemble dural AVFs if there is slow flow with perimedullary

venous drainage (15). They may present with hemorrhage in cases of high-flow reflux into the intradural veins.

Intradural AVMs (true AVMs) are supplied by radiculomedullary arteries and may be situated partially or totally within the spinal cord (subpial) or at the surface of the spinal cord (pial), where they may be either arteriovenous fistulas or AVFs. Intradural spinal AVMs are usually diagnosed in young patients who are less than 30 years old and present with an acute onset of symptoms and the presence of subarachnoid hemorrhage.

Perimedullary direct AVFs, initially described by Djindjian et al (16), are defined by a single shunt and have been classified into three types according to flow (4, 7–9). Type I corresponds to a single, slow-flow direct AVF between a non-dilated anterior spinal artery and a spinal vein. This type can be easily misdiagnosed. It occurs in young adults with progressive myelopathy. Type II is also a single direct AVF, with greater flow than in type I and an ampullary dilatation of the venous side of the shunt. In both types I and II, the venous drainage is extensive, as in the dural AVF type. Type III, or giant, AVFs, which are the subject of this article, are high-flow shunts with one or several large or giant feeders. Veins are severely dilated and ectasia or true venous aneurysms are encountered either near the shunt or more distally. This group differs from the two other types by its high flow and its local venous drainage to the epidural space. We found 25 cases in the literature that satisfy the type III perimedullary AVF criteria (17–27).

Pathogenesis

The congenital origin of GAVFs is suggested by the following arguments. GAVFs are usually discovered during childhood (mean age of diagnosis in our cases, 11.5 years; in the literature, 13.5 years) (Table 1). They may be associated with or be part of complex vascular malformation syndromes as described in the literature and as was seen in two of our patients (cases 1 and 6) (1, 18, 20–22, 26, 27). These angiodyplasias (Klippel-Trenaunay, Parkes-Weber, Cobb syndrome, Weber-Osler-Rendu disease) are known to be caused by early (3 to 5 weeks) developmental abnormalities of the primary vascular network (28, 29).

GAVFs may develop at all levels of the spinal cord with a higher prevalence at the conus med-

ullaris (see Table 1). This latter location has a physiologically rich blood supply of the posterior neuropore during embryonic life corresponding to high mitotic and/or metabolic activity (30, 31). It is conceivable that this area of rich blood supply may frequently be the site of dysplasia, whether it be of genetic or teratogenic origin (32). This hypothesis may be generalized to other sites of GAVFs (cervical and thoracic) in that the primary vascular network is situated on the anterior surface of the spinal cord and the GAVFs are usually located at the anterior surface of the spinal cord (33).

Pathophysiology of Clinical Signs

GAVFs are manifested by two major types of symptoms: subarachnoid hemorrhage and progressive neurologic deficits. Subarachnoid hemorrhage was present in five (42%) of our patients and in 10 patients reported in the literature (1, 17, 18, 20, 22, 27). Only two of our patients had associated paraplegia without evidence of hematomyelia on MR images. Pathologic or surgical data concerning the mechanism of bleeding are lacking, but the role of venous impairment due to high flow may be suggested. In case 9, MR images revealed venous ectasia surrounded by a clot (Fig 2A), suggesting the site of venous rupture. Venous ectasia may reflect not only the high flow of the shunt but also the relative insufficiency of venous drainage. Moreover, arterial aneurysms (constituting possible hemorrhagic lesions) have not been reported in GAVFs. The role of flow in the development of hemorrhage in perimedullary AVFs may be suggested by the fact that types I and II do not bleed (4, 9).

Progressive neurologic deficits (including myelopathy, radiculomyelopathy, and radiculopathy) were encountered in 57% of cases. Three mechanisms are commonly proposed to explain these symptoms: steal syndrome, venous ischemia, and nerve compression.

A steal syndrome is conceivable, since GAVFs are supplied by the anterior spinal artery. However, because no method is available for measuring spinal cord blood flow, a steal syndrome remains a matter of speculation. In the cases reported in the literature, acute occlusion of the GAVF was never followed by so-called normal arterial breakthrough, which would reflect vascular dysregulation due to chronic ischemia (34).

Venous ischemia due to increased venous pressure may be a possibility, since venous drainage may not always adapt to the amount of arterial inflow. No mention of cord edema or swelling is made in the single reported case with pathologic work-up (1). Only five of our patients were studied by MR imaging. In four cases we were unable to see any sign of spinal cord edema. Nevertheless, in one patient (case 12) who had a conus GAVF and an ascending venous drainage into the posterior fossa, swelling of the thoracic spinal cord associated with a central low signal intensity on T1-weighted images was observed (Fig 3A). These findings may correspond to medullary edema as observed in dural fistulas with perimedullary venous drainage. This hypothesis is further supported by the fact that after treatment the spinal cord returned to its normal size (Fig 3E).

A direct cord or nerve root compression by hypertrophied vascular structures was clearly evident in five of our cases and in four cases reported in the literature (18–20, 24). Regardless of the mechanism proposed to explain the clinical symptoms, they are clearly related to flow and are dramatically improved after correction of the shunt.

Treatment

Balloon occlusion of an AVF is suitable in these lesions by virtue of the angioarchitecture of GAVFs with their single arteriovenous shunt. Balloon procedures seem to be safe and efficient regardless of AVF location. In our experience, these balloons (filled with contrast material only) deflated between 1 month and 1 year after the procedure. No recurrence of the fistula or pulmonary migration was observed, probably because of the thrombosis of the feeder and the initial vein after AVF occlusion; thus, balloon inflation with a polymerizing material, which is more complex and less safe, appears to be unnecessary. The advantages of balloon occlusion are that balloons are easily carried by the flow to the fistula, even in very tortuous vessels, and that they can be repositioned. Balloon occlusion was achieved in 10 cases, effecting a technical cure in eight cases.

We observed two complications, as follows. Venous occlusion due to (detachable) balloon migration occurred in one patient. When the balloon was inflated, just before complete occlusion, the AVF flow caused the balloon to

detach. The balloon migrated into the venous drainage and blocked the single venous outlet at a sacral level (Fig 4). The patient suffered acute back pain with paraplegia a few minutes later. To reduce pressure in the AVF, we performed a more proximal occlusion of the arterial feeders in the same session, with occlusion of the anterior spinal artery. This complication led us to use a nondetachable balloon in subsequent procedures. In another patient, septicemia occurred following infection from the catheter, which was left in place too long. No vascular trauma occurred as a result of balloon inflation; nevertheless, such a risk cannot be completely excluded, as Halbach et al (27) described in a case of anterior spinal artery rupture due to inflation of a silicone balloon.

Neurologic impairment was not observed in any of the nine patients in whom acute and total occlusion was performed. Acute occlusion of an AVF has been considered to be responsible for edematous and/or hemorrhagic complications associated with dysautoregulation of the neural arteries (normal blood pressure breakthrough) (34). Our impression is that successful treatment requires correct positioning of the balloon on the arterial side of the fistula; but in one of our patients (case 9), stability of the balloon could only be obtained on the venous side of the shunt.

In the days following balloon occlusion, three patients with good results experienced moderate back pain and slight fever, which spontaneously resolved after 3 days. These symptoms were attributed to thrombosis of the GAVF.

Particulate embolization was used in the first two patients (before embolization balloons were routinely available) who had neurologic deterioration, suggesting extensive arterial obstruction or venous thrombosis. In the autopsy case reported by Benhaiem-Sigaux et al (1), a massive gelatin sponge pulmonary embolism was thought to be the cause of death. Particulate embolic material is not adapted for use in large direct fistulas because particles may pass through the arteriovenous shunt.

In our experience, embolization using a flow-guided nondetachable balloon was safe and effective, and no recurrence was observed. The advantage of a nondetachable balloon is that it assists in localizing the shunt and causes stagnation of all the afferent arteries of the fistula. The balloon may be repositioned. Its nondetachability assures safety, and experience has

shown that it has a good long-term tolerance. If occlusion of an AVF is performed with a detachable balloon instead of our device, it is our opinion that a more proximal nondetachable balloon should be used temporarily to stop or decrease flow in order to prevent unwanted migration of the detached balloon and subsequent, potentially catastrophic, complications.

Alternative endovascular procedures have been developed, including more supple microcatheters and microcoils. These methods are not flow-dependent, but allow for progressive deposit of embolic agents. Furthermore, these methods can be used in a venous approach. Halbach et al (27) reported a series of 10 GAVFs (types II and III) in which the use of microcoils in combination with particles (polyvinyl alcohol or silk suture) was favored. One patient reported by Nakstad et al (26), in whom the location of the shunt was clearly defined, was cured by microcoil embolization.

Nine patients were operated on before the introduction of endovascular treatment (18–21, 23–25). Surgery was considered to be difficult and hemorrhage occurred in two cases. Owing to the improvement of embolization techniques, we think that surgery should be proposed only after an unsuccessful endovascular attempt, as reported by Heros et al (2) and Halbach et al (27). If a surgical approach is chosen, superselective identification of the shunt is required to allow safe and precise placement of the clip. Intraoperative spinal angiography enables verification of the correct position of the clip.

In conclusion, GAVFs are rare conditions that are more common in children than in adults. Spinal MR imaging facilitates diagnosis of these intradural vascular malformations and visualization of medullary compression caused by a venous aneurysm. On the basis of our experience and because of the angioarchitecture of AVFs, we believe that endovascular intraarterial treatment by nondetachable latex balloons is a safe and reliable method for occluding this type of AVF. The transvenous approach, AVF coiling, or surgery may be indicated in instances of unusual anatomic conditions or unsuccessful balloon occlusion.

References

1. Benhaiem-Sigaux N, Zerah M, Gherardi R, Bellot J, Hurth M, Poirier J. A retromedullary arteriovenous fistula associated with the Klippel-Trenaunay-Weber syndrome. *Acta Neuropathol* 1985; 66:318–324
2. Heros RC, Debrun GM, Ojemann RG, Lasjaunias PL, Naessens PJ. Direct spinal arteriovenous fistula: a new type of spinal AVM. *J Neurosurg* 1986;64:134–139
3. Riche MC, Scialfa G, Gueguen B, Merland JJ. Giant extramedullary arteriovenous fistula supplied by the anterior spinal artery: treatment by detachable balloons. *AJNR Am J Neuroradiol* 1983; 4:391–394
4. Gueguen B, Merland JJ, Riche MC, Rey A. Vascular malformations of the spinal cord: intrathecal perimedullary arteriovenous fistulas fed by medullary arteries. *Neurology* 1987;37:969–979
5. Merland JJ, Rüfenacht D, Guimaraens L, Riche MC. A polyethylene microcatheter with a latex balloon as an implant for permanent vascular occlusions: a way for the treatment of distal intracranial or intraspinal large A. V. fistulas or aneurysms. In: Valk J, ed. *Neuroradiology 1985/1986*. International Congress series 698. New York, NY: Elsevier; 1986:299–300
6. Rüfenacht DA, Merland JJ, Guimaraens L. A nondetachable latex balloon for temporary diagnostic or permanent therapeutic occlusions of cerebral vessels and assistance for intravascular manipulations during hyperselective catheterizations. In: Valk J, ed. *Neuroradiology 1985/1986*. International Congress series 698. New York, NY: Elsevier; 1986:295–298
7. Merland JJ, Reizine D. Malformations vasculaires vertebromedullaires. In: *Encycl Med Chir: Radiodiagnostic II*. 5 ed. Paris, France: Techniques; 1987:31671 G10:1–21
8. Riche MC, Reizine D, Melki JP, Merland JJ. Classification of spinal cord vascular malformations. *Radiat Med* 1985;3:17–24
9. Casasco AE, Houdart E, Gobin YP, Aymard A, Guichard JP, Rufenacht DA. Embolization of spinal vascular malformations. *Neuroimaging Clin N Am* 1992;2:337–358
10. Symon L, Kuyama H, Kendall B. Dural arteriovenous malformations of the spine: clinical features and surgical results in 55 cases. *J Neurosurg* 1984;60:238–247
11. Rosenblum B, Oldfield EH, Doppman JL, Di Chiro G. Spinal arteriovenous malformations: a comparison of dural arteriovenous fistulas and intradural AVM's in 81 patients. *J Neurosurg* 1987;67:795–802
12. Houdart E, Gobin YP, Casasco A, Aymard A, Herbreteau D, Merland JJ. A proposed angiographic classification of intracranial arteriovenous fistulae and malformations. *Neuroradiology* 1993; 35:381–385
13. Kendall BE, Logue V. Spinal epidural angiomatous malformations draining into intrathecal veins. *Neuroradiology* 1977;13:181–189
14. Merland JJ, Riche MC, Chiras J. Intraspinally extramedullary arteriovenous fistulae draining into medullary veins. *J Neuroradiol* 1980; 7:271–320
15. Cahan LD, Higashida RT, Halbach VV, Hieshima GB. Variants of radiculomeningeal vascular malformations of the spine. *J Neurosurg* 1987;66:333–337
16. Djindjian M, Djindjian R, Rey A, Hurth M, Houdart R. Intradural extramedullary spinal arterio-venous malformations fed by the anterior spinal artery. *Surg Neurol* 1977;8:85–93
17. Picard L, Vert P, Renard M, Hepner H, Lepoivre J. Aspects radio-anatomiques des angiomes médullaires. *Neurochirurgie* 1969;18: 519–528
18. Djindjian R, Hurth M, Rey A, Houdart R. Spinal angiomias in Rendu-Osler disease. *J Neuroradiol* 1974;1:289–350
19. Sutton T, Murray PJ, Alexander WJ, Blundell JE. Arteriovenous malformations of the spinal cord in childhood. *Radiology* 1973; 109:621–622
20. Kaplan P, Hollenberg RD, Frazer FC. A spinal arteriovenous malformation with hereditary cutaneous hemangiomas. *Am J Dis Child* 1976;130:1329–1331

21. Merry GS, Appleton DB. Spinal arterial malformation in a child with hereditary hemorrhagic telangiectasia. *J Neurosurg* 1976;44:613-616
22. Djindjian M, Djindjian R, Hurth M, Rey A, Houdart E. Spinal cord arteriovenous malformations and Klippel-Trenaunay-Weber syndrome. *Surg Neurol* 1977;8:229-237
23. Scarff TB, Reigel DH. Arteriovenous malformation of the spinal cord in children. *Childs Brain* 1979;5:341-351
24. Binder B, Eng GD, Milhorat TH, Galioto F. Spinal arteriovenous malformations in an infant: unusual symptomatology and pathology. *Dev Med Child Neurol* 1982;24:380-385
25. Doppman JL, Di Chiro G, Dwyer AJ, Frank JL, Oldfield EH. Magnetic resonance imaging of spinal arteriovenous malformations. *J Neurosurg* 1987;66:830-834
26. Nakstad PH, Hald JK, Bakke SJ. Multiple spinal arteriovenous fistulas in Klippel-Trenaunay-Weber syndrome treated with platinum fibre coils. *Neuroradiology* 1993;35:163-165
27. Halbach VV, Higashida RT, Dowd CF, Fraser KW, Edwards MS, Barnwell SL. A treatment of giant intradural (perimedullary) arteriovenous fistulas. *Neurosurgery* 1993;33:972-980
28. Andre JM. *Les Dysplasies Vasculaires Systematisées*. Paris, France: L'Expansion Scientifique Française; 1973:31-43
29. Dobbelaere P, Dhellemmes P, Bousquet C, Urbain JP, Michaux F. Metameric angiomas: a report of two cases. *J Neuroradiol* 1978;5:225-235
30. Lemire RJ, Loeser JD, Leech RW, Alword EC. Secondary caudal neural tube formation. In: *Normal and Abnormal Development of the Human Nervous System*. Hagerstown, NJ: Harper & Row; 1975:71-83
31. Moore KL. The nervous system. In: *The Developing Human*. 4th ed. Philadelphia, Pa: Saunders; 1988:52-54, 365-390
32. Barkovich AJ, Raghavan N, Chuang S, Peck WW. The wedge-shaped cord terminus: a radiographic sign of caudal regression. *AJNR Am J Neuroradiol* 1989;10:1223-1231
33. Torr JBD. The embryological development of the anterior spinal artery in man. *J Anat* 1957;91:587
34. Halbach VV, Higashida RT, Hieshima GB, Norman D. Normal perfusion pressure breakthrough occurring during treatment of carotid and vertebral fistulas. *AJNR Am J Neuroradiol* 1987;8:751-756