
Percutaneous Transvenous Coil Embolization of a Djindjian Type 4 Tentorial Dural Arteriovenous Malformation

D. F. Kallmes, M. E. Jensen, H. J. Cloft, N. F. Kassell, and J. E. Dion

Summary: We report a 60-year-old man who had a progressive neurologic deficit resulting from a Djindjian type 4 tentorial dural arteriovenous malformation (DAVM). The DAVM was repaired via percutaneous transvenous coil embolization.

Index term: Arteriovenous malformations, embolization

The clinical manifestations of and therapeutic options for patients with dural arteriovenous malformations (DAVMs) have received much attention in the neurosurgical and neuroradiologic literature (1–5). DAVMs with leptomeningeal venous drainage have been identified as the lesions with the greatest propensity to manifest aggressive clinical symptoms, mandating prompt therapy (1, 3). Surgical resection (2) and/or endovascular obliteration, particularly via the transvenous route (6), can be used to cure many of these lesions.

Tentorial DAVMs represent a particularly challenging clinical problem. Not only do they almost always display aggressive behavior but they are also difficult to approach via standard surgical or endovascular means (5, 7–9). The percutaneous transvenous endovascular approach, which is highly effective in curing other types of DAVMs (6), historically has been avoided in tentorial DAVMs, as this method would require catheter navigation through tortuous leptomeningeal veins (5, 7, 9, 10).

We report a case of a Djindjian type 4 (leptomeningeal venous drainage with a large venous lake) (1) tentorial DAVM treated via percutaneous transvenous embolization.

Case Report

A 60-year-old left-handed man was treated in November 1995 at an outside institution for left-sided dysesthesias and transient weakness. A cerebral angiogram re-

vealed a DAVM of the right tentorial edge with deep leptomeningeal venous drainage. At that time, the patient refused further examination and decided to defer any therapy. He was reexamined in June 1996 for progressive hemiparesis. On neurologic examination, a left homonymous hemianopsia was detected in addition to the left-sided motor weakness. The patient was then transferred to our institution for further examination.

Magnetic resonance (MR) imaging showed tortuous and aneurysmal perimesencephalic veins and extensive edema in the deep aspect of the right cerebral hemisphere (Fig). Angiography showed a DAVM involving the anterior aspect of the right tentorium fed via cavernous branches of the right internal carotid artery (ICA), as well as multiple external carotid artery branches, and drained by perimesencephalic veins to the straight sinus (Fig 1B and C). A large varix was also noted. There was no antegrade direct dural sinus drainage from the DAVM.

Therapeutic options included transarterial embolization, either alone or combined with surgery or gamma knife therapy; surgery alone; or transvenous embolization. Since transarterial embolization alone was thought to be unlikely to result in cure, and because the patient had a strong preference not to undergo surgery, the percutaneous transvenous embolization was attempted.

A 5F catheter was placed via the left common femoral artery into the right common carotid artery to allow roadmapping during the transvenous procedure. A triaxial system was placed via the right common femoral vein. An 8F guiding catheter (Balt, Montmorency, France), which had been cut and smoothed to the minimum length that would allow catheterization of the mid right jugular vein, was placed. Through this guiding catheter, a Tracker 38 catheter (Target Therapeutics, Fremont, Calif) was placed over a Taper 22 guidewire (Target Therapeutics) via the right sigmoid and transverse sinuses to the junction of the straight sinus and vein of Galen (Fig 1D and E). Through the Tracker 38 catheter a TurboTracker 18 microcatheter (Target Therapeutics) was advanced over a hydrophilic Dasher 0.014 microguidewire (Target Therapeutics) into the deep venous system draining the DAVM. The microguidewire/microcatheter system was advanced toward the

Received August 19, 1996; accepted without revision October 21.

From the Departments of Radiology (D.F.K., M.E.J., H.J.C., J.E.D.) and Neurosurgery (N.F.K.), University of Virginia Health Sciences Center, Charlottesville.

Address reprint requests to D. F. Kallmes, Department of Radiology, University of Virginia Health Sciences Center, Charlottesville, VA 22908.

AJNR 18:673–676, Apr 1997 0195-6108/97/1804–0673 © American Society of Neuroradiology

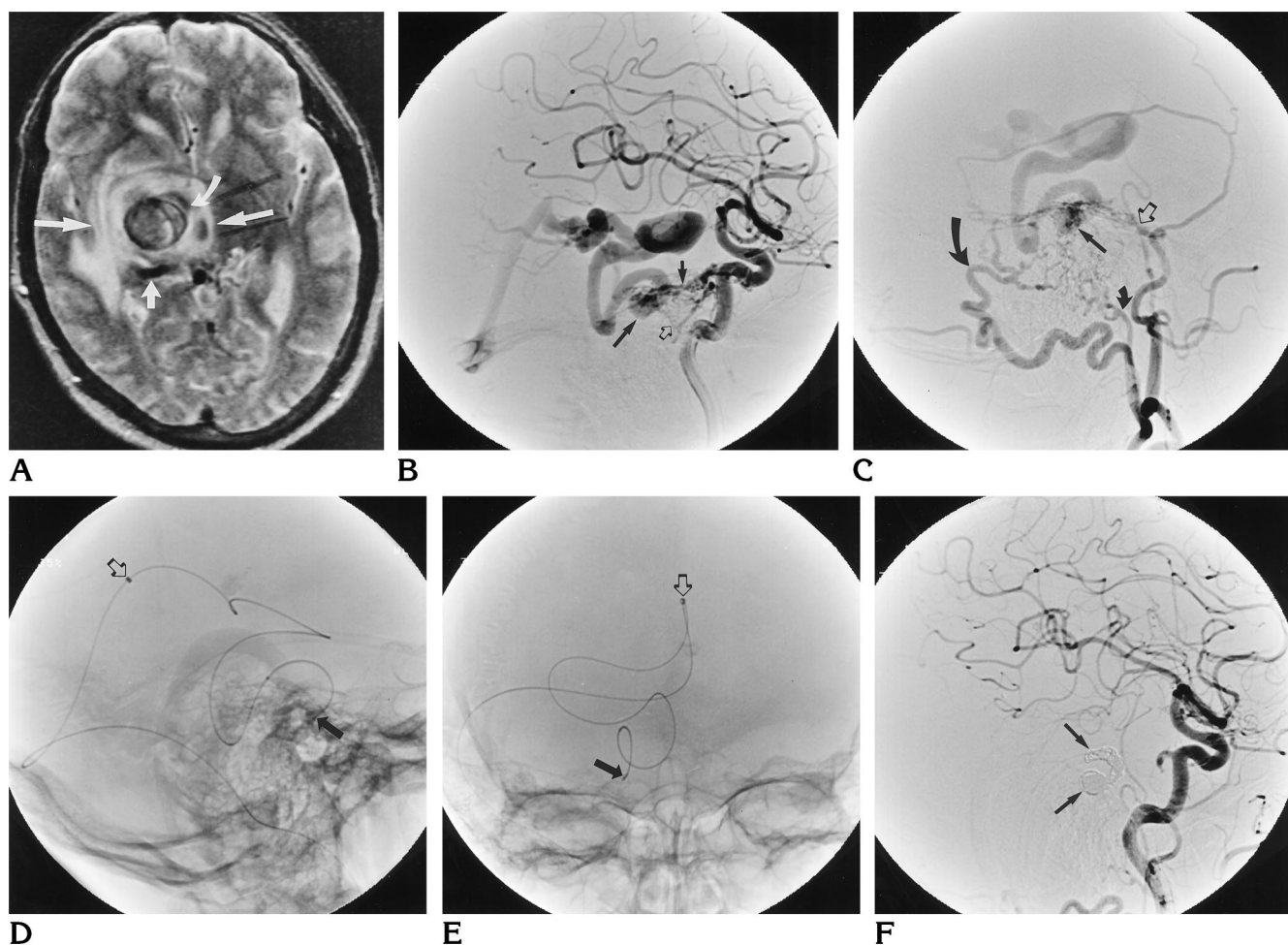


Fig 1. A 60-year-old man with tentorial dural AVM treated via percutaneous transvenous embolization.

A, Axial MR image (2000/80 [repetition time/echo time]) at the level of the third ventricle shows a large venous varix (*curved arrow*) with a significant amount of surrounding white matter edema (*long arrows*). An enlarged draining vein is noted posteriorly (*short arrow*).

B, Lateral view of an ICA digital subtraction angiogram, mid arterial phase, shows massively enlarged dural branches of the ICA, including the tentorial artery (*short solid arrow*) and dorsal clival artery (*open arrow*). These vessels converge at the site of the tentorial DAVM, which empties into a single venous pouch (*long solid arrow*) and drains via perimesencephalic veins into the straight sinus. Note the large venous varix, as seen on the MR image.

C, Lateral view of an external carotid artery digital subtraction angiogram, early arterial phase. The DAVM is fed via multiple branches of the external carotid artery, including the petrous branch (*open arrow*) and posterior division of the middle meningeal artery, the stylomastoid artery (*small curved arrow*), and the occipital artery (*large curved arrow*). As seen on the ICA injection, the site of the DAVM is along the tentorium, and drainage is into a single venous pouch (*straight solid arrow*).

D, Lateral plain radiograph after placement of the microcatheter. The navigation was via the jugular vein into the sigmoidal and transverse sinuses, and the tip of the Tracker 38 catheter rests within the straight sinus approximately 1 cm from the vein of Galen (*open arrow*). The tip of the TurboTracker microcatheter rests within the venous pouch immediately adjacent to the DAVM (*solid arrow*). The system is opacified by the Transcend microguidewire.

E, Anteroposterior view of the microcatheter system shows the tip of the Tracker 38 (*open arrow*) and TurboTracker (*solid arrow*) catheters.

F, Postprocedural lateral common carotid artery DSA shows obliteration of the DAVM. The coils (seen as subtraction artifacts) rest within the venous pouch immediately adjacent to the DAVM (*arrows*) as well as within the most proximal aspect of the deep leptomeningeal venous outlet. Note the truncated tentorial artery, which no longer feeds the DAVM.

venous pouch immediately adjacent to the DAVM (Fig 1D and E). Navigation of the final 2 cm required removal of the initial microguidewire in favor of a Transcend microguidewire (Meditech, Watertown, Mass). Once the tip of the microcatheter was within the venous pouch immediately adjacent to the DAVM, three Guglielmi detachable coils (GDCs) (Target Therapeutics) (total length, 55 cm) and a single 2 × 6-mm Vortex fibered platinum coil (Target Therapeutics) were deposited. A control angiogram showed obliteration of the DAVM (Fig 1F). The patient had no immediate complications. Within 48 hours he noted a marked increase in strength in his left upper extremity, and over the ensuing 3 weeks he gained significantly improved strength in his left lower extremity.

Discussion

Transvenous obliteration of a type 3 anterior cranial fossa DAVM with superficial leptomenigeal venous drainage has been performed safely (J. P. Pruvo, Lille, France, personal communication). Our experience demonstrates that tortuous, aneurysmal, deep leptomenigeal veins can be safely navigated with the use of a soft, hydrophilic microguidewire and a hydrophilic, braided microcatheter. The hydrophilic coatings on the microguidewires and microcatheters facilitate navigation of tortuous vessels. The nitinol braid in the wall of the microcatheter diminishes the tendency for the catheter to become oval or to kink. Many investigators have suggested that transversing leptomenigeal veins to approach a type 3 or 4 DAVM is either impossible or too dangerous (7–10). We agree that catheterization of these vessels is treacherous and should only be done with extreme care after carefully considering other therapeutic options. In our case, the venous structures were sufficiently dilated to allow catheterization.

We do not propose transvenous embolization as the primary mode of therapy for tentorial DAVMs. Rather, we suggest this approach as a potential alternative to transarterial embolization, surgery, or gamma knife therapy for these dangerous and complex lesions. Transarterial embolization alone will effect cure in only a minority of tentorial DAVMs (5, 7, 11, 12). Limited data suggest that partial embolization may not protect against the risk of hemorrhage in high-risk lesions, such as the case presented here (4). Also, most of the feeders to the DAVM in our case were from the ICA, so transarterial embolization would have carried with it some

risk of ischemic brain injury from reflux of embolic material into the ICA (11, 12).

Transvenous coil embolization of the DAVM reported here is analogous to the modified surgical approach initially proposed by Grisoli et al (13) and later reported by Thompson et al (14) and by Collice et al (5). These authors suggest that, instead of attempting complete excision of tentorial DAVMs, cure can be effected by ligating the draining veins as they enter the subarachnoid space. This approach is simpler than the standard surgical technique of complete excision of the fistula and adjacent dural sinus. Our procedure occludes the venous outlet in a similar location to that used in the modified surgical approach of Grisoli et al (13), albeit via an endovascular rather than surgical route.

Transvenous embolization carries with it the risk of aggravating the situation by partially occluding the venous outlet without obliterating the DAVM (8–10). Technically, coils should be deposited at the venous outlet, without any remaining vein interposed between the nidus and site of occlusion. For this reason, we suggest the use of soft, retractable GDCs at the start of the embolization, since these coils are unlikely to cause uncontrolled recoil of the tip of the microcatheter with resultant loss of access to the point of arteriovenous shunting. Fibered coils are complementary to GDCs, since the former offers increased thrombogenicity at the expense of a higher tendency to displace the catheter tip. The successful occlusion obtained in this case might have been related to the single venous outlet, so that even relatively hypothrombogenic GDCs were able to thrombose the venous pouch.

Combined direct surgical exposure and endovascular embolization has been described for approaching complex DAVMs (15). A similar approach could have been attempted in our case. This would have avoided the risk of perforation of the deep leptomenigeal vein at the expense of a craniotomy.

The use of a triaxial transvenous system reduces the tendency for herniation of the guiding catheter into the right atrium and ventricle by providing increased stiffness and stability as compared with coaxial arrangements. Other investigators have used direct puncture of the jugular vein when anticipating difficult retrograde transvenous approaches to DAVMs (16), and a similar approach may have been effective in our case.

References

1. Djindjian R, Merland JJ, Theron J. *Superselective Arteriography of the External Carotid Artery*. New York, NY: Springer-Verlag; 1977: 606–628
2. Awad IA, Little JR, Akrawi WP, Ahl J. Intracranial dural arteriovenous malformations: factors predisposing to an aggressive neurological course. *J Neurosurg* 1990;72:839–850
3. Cognard C, Gobin YP, Pierot L, et al. Cerebral dural arteriovenous fistulas: clinical and angiographic correlation with a revised classification of venous drainage. *Radiology* 1995;194:671–680
4. Borden JA, Wu JK, Shucart WA. A proposed classification for spinal and cranial dural arteriovenous fistulous malformations and implications for treatment. *J Neurosurg* 1995;82:166–179
5. Collice M, D'Alberti G, Talamonti G, et al. Surgical interruption of leptomeningeal drainage as a treatment for intracranial dural arteriovenous fistulas without dural sinus drainage. *J Neurosurg* 1996;84:810–817
6. Halbach VV, Higashida RT, Hieshima GB, Hardin CW, Pribam H. Transvenous embolization of dural fistulas involving the cavernous sinus. *AJNR Am J Neuroradiol* 1989;10:377–383
7. Pierot L, Chiras J, Meder JF, Rose M, Rivierez M, Marsault C. Dural arteriovenous fistulas of the posterior fossa draining into subarachnoid veins. *AJNR Am J Neuroradiol* 1992;13:315–323
8. Lewis AI, Tomsick TA, Tew JM. Management of tentorial dural arteriovenous malformations: transarterial embolization combined with stereotactic radiation or surgery. *J Neurosurg* 1994;81: 851–859
9. Awad IA. Tentorial incisura and brain stem dural arteriovenous malformations. In: Awad IA, Barrow DL, eds. *Dural Arteriovenous Malformations*. Park Ridge, Ill: American Association of Neurosurgeons Publication Committee; 1993;131–146
10. Lownie SP. Intracranial dural arteriovenous fistulas: endovascular therapy. *Neurosurg Clin North Am* 1994;5:449–458
11. Picard L, Bracard S, Islak C, et al. Dural fistulae of the tentorium cerebelli. *J Neuroradiol* 1990;17:161–181
12. Halbach VV, Higashida RT, Hieshima GB, Wilson CB, Hardin CW, Kwan E. Treatment of dural fistulas involving the deep cerebral venous system. *AJNR Am J Neuroradiol* 1989;10:393–399
13. Grisoli F, Vincentelli F, Fuchs S, et al. Surgical treatment of tentorial arteriovenous malformations draining into the subarachnoid space: report of four cases. *J Neurosurg* 1984;60:1059–1066
14. Thompson BG, Doppman JL, Oldfield EH. Treatment of cranial dural arteriovenous fistulae by interruption of leptomeningeal venous drainage. *J Neurosurg* 1994;80:617–623
15. Barnwell SL, Halbach VV, Dowd CF, Higashida RT, Hieshima GB, Wilson CB. A variant of arteriovenous fistulas within the wall of the dural sinuses. *J Neurosurg* 1991;74:199–204
16. Gobin YP, Houdart E, Rogopoulos A, Cascaso A, Bailly AL, Merland JJ. Percutaneous transvenous embolization through the thrombosed sinus in transverse sinus dural fistula. *AJNR Am J Neuroradiol* 1993;14:1102–1105