

---

# Proton MR Spectroscopy in Coats Disease

L. Eisenberg, M. Castillo, L. Kwock, S. K. Mukherji, and D. K. Wallace

**Summary:** We describe a case of acute left-sided visual loss in a 4-year-old boy. CT showed hyperdense retinal detachment with a tiny calcification, and MR imaging showed subretinal hyperintensity on both T1- and T2-weighted images. Proton MR spectroscopy showed a large peak between 1 and 1.6 ppm that we believe corresponds mainly to lipids, which are characteristic of the exudate present in Coats disease.

**Index terms:** Retina; Magnetic resonance, spectroscopy; Children, diseases

Coats disease is a rare congenital retinal disorder found mostly in boys 4 to 8 years of age (1, 2). Clinically, Coats disease presents with unilateral decreased visual acuity and leukokoria (3). At computed tomography (CT), the absence of calcifications is helpful in distinguishing Coats disease from the more common retinoblastoma. Coats disease is, however, indistinguishable from the noncalcifying variant of retinoblastoma by CT (1), and magnetic resonance (MR) imaging may be more helpful than CT in distinguishing these two entities. At MR imaging, Coats disease is seen as a retinal detachment that is hyperintense on T1- and T2-weighted images, while retinoblastoma is relatively hyperintense on T1-weighted images but hypointense on long-repetition-time long-echo-time sequences (4). Additionally, after administration of contrast material, retinoblastoma enhances in a masslike fashion while in Coats disease there is enhancement along the leaves of the detached retina and at the sites where the retina reinserts (4). We present a case of Coats disease in which the findings on proton MR spectroscopy corresponded closely to the known histopathology of this lesion.

## Case Report

A 4-year-old boy was noted by his mother to have "turning in" of his eyes for 6 months before he reported

decreased vision in his left eye. Family and medical history was unremarkable. Ophthalmoscopy of the left eye showed telangiectatic vessels and an exudative retinal detachment, suggesting Coats disease (Fig 1A). The right eye was normal. Noncontrast CT scans revealed a slightly hyperdense retinal detachment with a small focus of calcification. T1-weighted MR images (475/15/4 [repetition time/echo time/excitations]) showed a hyperintense retinal detachment that was also hyperintense on fast spin-echo T2-weighted images (3500/93/1) (Fig 1B). The boy's mother refused administration of contrast agent and proton MR spectroscopy of the abnormal eye was done at 1600/20/256 with a volume of  $1.5 \times 1.5 \times 1.5$ , and mixing time of 30 milliseconds (Fig 1C). Water suppression was accomplished with a presaturation chemical-shift selective water pulse before the spectra were obtained. Identical parameters were used to record spectra from the normal eye. The mother wished to avoid enucleation and sought a second opinion from another pediatric ophthalmologist, who confirmed the clinical diagnosis of Coats disease. Follow-up examination 6 months after presentation showed the patient to be stable with normal cosmesis.

## Discussion

In Coats disease, the formation of retinal telangiectasia leads to the breakdown of the retinal-blood barrier and to formation of subretinal exudates (Fig 1A). The progressive subretinal leakage of serum and lipids results in a lipoproteinaceous exudate that is characteristic of Coats disease (2, 5). The vascular anomaly is present at birth but loss of vision does not occur until enough exudate is present to cause retinal detachments. In some patients, these retinal detachments may lead to glaucoma and pain, and enucleation is eventually required. Vessel obliteration with laser or cryotherapy may delay or obviate enucleation in some patients (2). In the initial stages of the disease, imaging studies may be normal; in later stages, MR images show hyperintense retinal detachments on all sequences (Fig 1B). These features are different

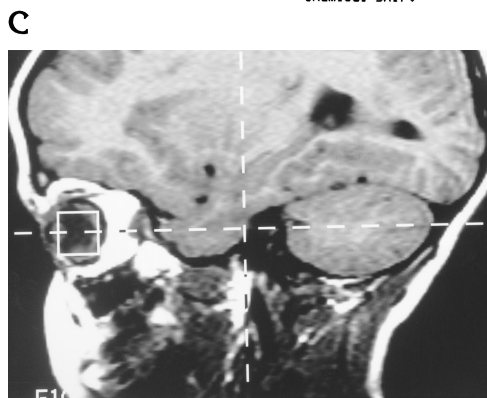
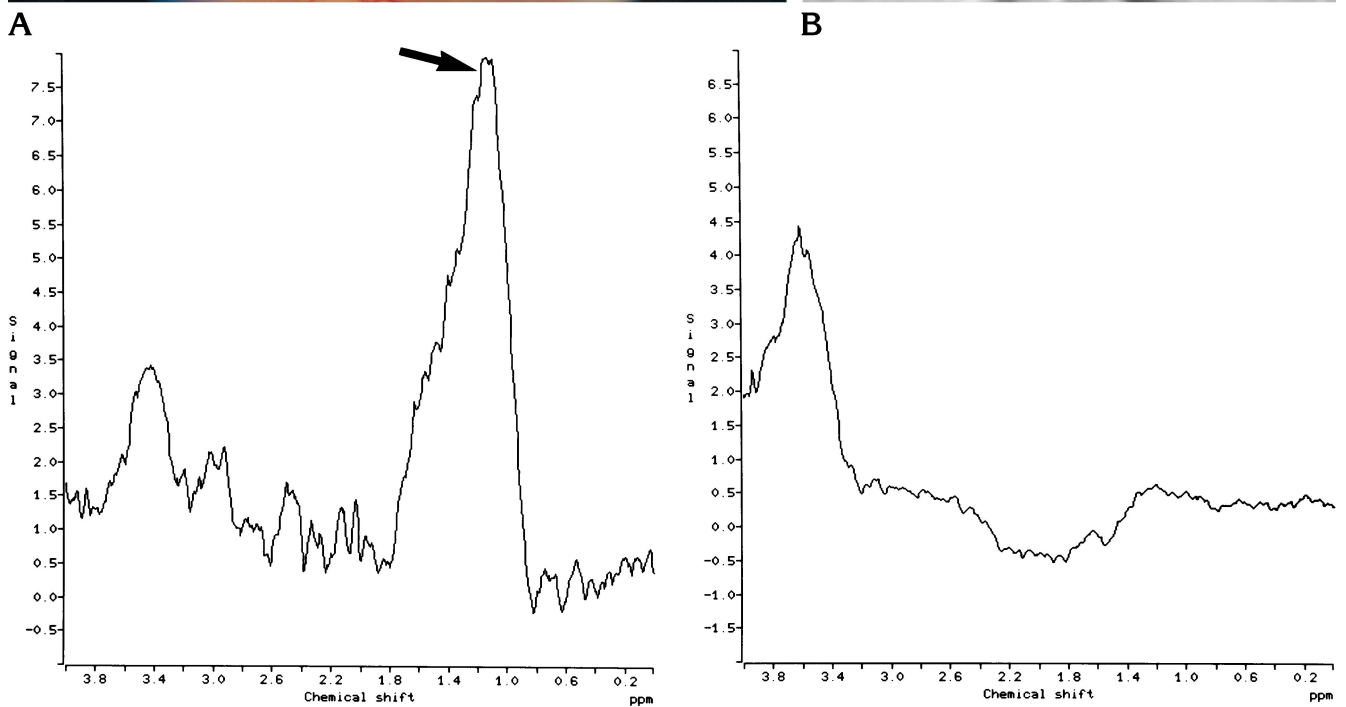
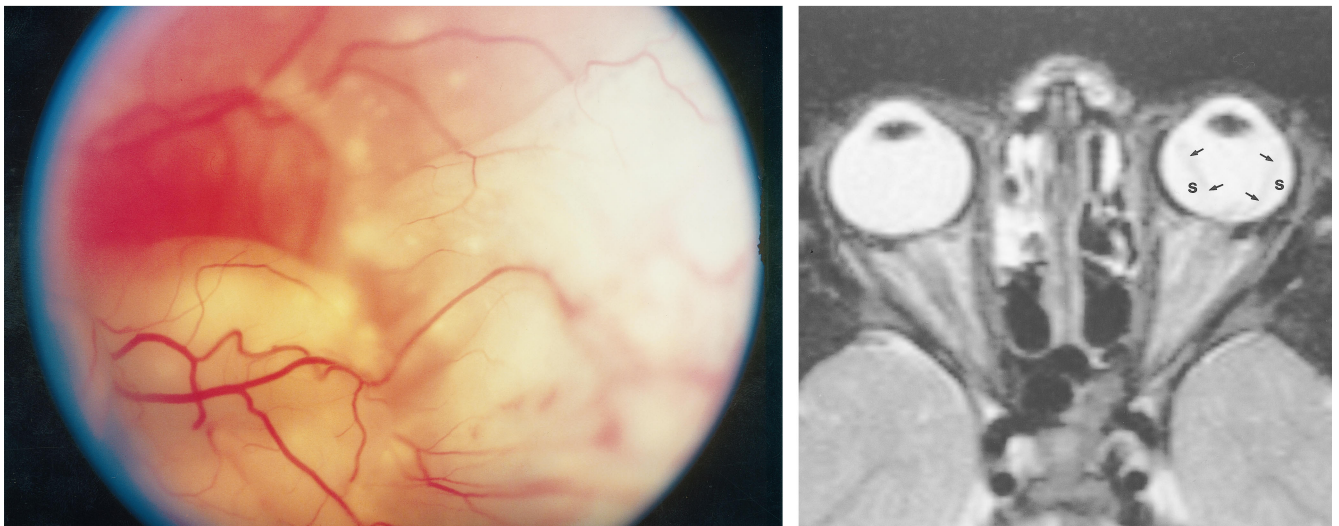
---

Received April 3, 1996; accepted after revision August 1.

From the Departments of Radiology (L.E., M.C., L.K., S.K.M.) and Ophthalmology (D.K.W.), University of North Carolina School of Medicine, Chapel Hill.

Address reprint requests to M. Castillo, MD, Department of Radiology, CB 7510, University of North Carolina at Chapel Hill, Chapel Hill, NC 27599.

AJNR 18:727-729, Apr 1997 0195-6108/97/1804-0727 © American Society of Neuroradiology



E

Fig 1. A 4-year-old boy with suspected Coats disease.

A, At ophthalmoscopy, peripheral fundus shows exudative retinal detachment and telangiectatic vessels (*right lower quadrant*), typical of Coats disease.

B, Axial T2-weighted MR image shows subretinal effusion (S) to be hyperintense. The leaves of detached retina (*arrows*) are seen as hypointense linear regions that converge in the location of the optic nerve head.

C, Proton MR spectrum of the abnormal left eye shows a large peak (*arrow*) that is probably due to lipids or complex proteolipids.

D, Spectrum from normal right eye shows that no significant lipids are present.

E, Parasagittal T1-weighted MR image shows position of voxel.

from those of retinoblastoma, which appears hyperintense on T1-weighted images and hypointense on T2-weighted images. After administration of contrast material, the detached leaves of the retina show linear enhancement in cases of Coats disease, whereas retinoblastoma enhances in a masslike fashion (4). It has been suggested that MR imaging with contrast administration is an ideal method by which to diagnose Coats disease (M. F. Mafee, J. S. Ecanow, D. B. Ecanow, P. F. Para, "MR Imaging of the Globe," presented at the annual meeting of the Radiological Society of North America, Chicago, Ill, November 1995).

Our case was challenging because CT showed a small focus of calcification. The presence of intraocular calcifications in a child should be considered a manifestation of retinoblastoma until proved otherwise (1). However, intraocular bone formation has also been reported in Coats disease (6). Because contrast administration was not possible in our patient and the parent refused enucleation, we chose to perform proton MR spectroscopy. MR spectroscopy has been used in enucleated eyes primarily to determine T1 and T2 relaxation times (7). In our patient, we used a stimulated-echo acquisition mode sequence with an echo time of 20 milliseconds because in our MR system this sequence is the only one that allowed the use of a small voxel, which could be entirely contained within the globe (Fig 1E). In the eye with Coats disease, proton MR spectroscopy showed a large peak at 1 to 1.6 ppm, which probably corresponds to lipids and/or complex proteolipids (5) (Fig 1C). The normal eye showed markedly different spectra without any significant lipids (Fig 1D). Although contamination from surrounding orbital fat is a consideration in spectroscopy of the eye, as seen in the normal eye described here, lipid contamination was not a problem. The proton MR spectra of retinoblastoma have not been reported, to our knowledge.

However, other primitive neuroectodermal tumors, such as cerebellar medulloblastoma, clearly have shown marked elevation of choline, low *N*-acetylaspartate, and the presence of lactate (8). These features are obviously different from those seen in our patient. However, it is known that retinoblastoma may result in a reaction similar to that of Coats disease subsequent to exudative retinopathy (9). In this extremely rare situation it is safe to assume that even MR spectroscopy would be unable to distinguish between the two diseases and that enucleation would be necessary.

In summary, we have described a patient with suspected Coats disease in whom proton MR spectroscopy revealed the presence of a large lipid peak. This peak is probably related to the presence of lipoproteinaceous subretinal exudate, which is typical of this disease.

## References

1. Mafee MF, Goldberg MF, Greenwald MJ, Shulman J, Malmel A, Flanders AE. Retinoblastoma and simulating lesions: role of CT and MR imaging. *Radiol Clin North Am* 1987;25:667-682
2. Shields JA, Parsons HM, Shields CL, Shah P. Lesions simulating retinoblastoma. *J Pediatr Ophthalmol Strabismus* 1991;28:338-340
3. Smirniotopoulos JG, Bargallo N, Mafee MF. Differential diagnosis of leukokoria: radiology-pathologic correlation. *Radiographics* 1994;14:1059-1079
4. Mafee MF, Ainbinder D, Afshani E, Mafee RF. The eye. *Neuroimaging Clin North Am* 1996;6:29-60
5. Woods AC, Duke JR. Coat's disease: review of the literature, diagnostic criteria, clinical findings and plasma lipid studies. *Br J Ophthalmol* 1963;47:385-391
6. Senft SH, Hidayat AA, Cavender JC. Atypical presentation of Coats disease. *Retina* 1994;14:36-38
7. Gomori JM, Grossman RI, Shields JA, Augsburger JJ, Joseph PM, DeSimeone D. Ocular MR imaging and spectroscopy: an ex vivo study. *Radiology* 1986;160:201-205
8. Wang Z, Sutton LN, Cnaan A, et al. Proton MR spectroscopy of pediatric cerebellar tumors. *AJNR Am J Neuroradiol* 1995;16:1821-1833
9. Jaffe MS, Shields JA, Canny CL, et al. Retinoblastoma simulating Coat's disease: a clinico-pathologic report. *Ann Ophthalmol* 1977;9:863-868