

# Duplex and Color Doppler Flow Sonography of Occlusion and Near Occlusion of the Carotid Artery

Donald H. Lee, Fu-Qiang Gao, Richard N. Rankin, David M. Pelz, and Allan J. Fox

**PURPOSE:** To determine whether color Doppler flow imaging with the use of slow-flow sensitivity improves sensitivity and specificity in the differentiation of occlusion and near occlusion of the internal carotid artery. **METHODS:** Color Doppler and duplex sonography were performed in symptomatic patients who had angiographically confirmed occlusion and/or near occlusion of the internal carotid artery. The study consisted of two phases: in the first, we assessed the usefulness of color Doppler flow imaging by retrospectively reviewing the records of 35 patients with 36 angiographically confirmed occlusions or near occlusions of the internal carotid artery who were examined with color Doppler flow imaging at our institution during a period of 4 years; in the second phase, we incorporated color Doppler sonography into the routine scanning protocols of 39 patients with 41 occluded or nearly occluded internal carotid arteries seen over a period of 2½ years. **RESULTS:** Overall, color Doppler imaging correctly showed all 34 of the near occlusions (sensitivity, 100%) and 36 of the 43 occlusions (specificity, 84%). Seven patients with angiographically confirmed occlusion had sonographic findings that suggested near occlusion. In the first phase, eight near occlusions were misinterpreted as occlusions with conventional duplex sonography, but were correctly shown with color Doppler flow imaging. In the second phase, sensitivity increased from 50% to 100% (18 of 18) because of better detection of the nearly occluded lumen. This was at the expense of a decrease in specificity (from 100% to 78%), owing to identification of apparent flow in the internal carotid artery on color Doppler flow images in five of 23 occlusions. **CONCLUSION:** Because of its ability to depict slow flow, color Doppler imaging with slow-flow sensitivity is superior to conventional duplex sonography for the noninvasive discrimination of occlusion from near occlusion of the internal carotid artery.

**Index terms:** Ultrasound, Doppler; Arteries, carotid, internal; Arteries, stenosis and occlusion

*AJNR Am J Neuroradiol* 17:1267-1274, August 1996

The differentiation of carotid artery occlusion from near occlusion by conventional duplex sonography has always been problematic (1, 2). Color Doppler flow imaging has decreased the operator dependence of conventional duplex sonography (both techniques are types of duplex sonography, combining imaging and

Doppler sampling) while retaining the sensitivity of duplex sonography for the detection of stenoses between 80% and 90% (2, 3). This is because the flow mapping of color Doppler flow imaging allows more accurate depiction of the lumen, areas of turbulence, and maximal flow velocity through stenoses. However, investigators using conventional color Doppler flow imaging have had problems in evaluating near occlusion of the carotid artery, as the flow through the residual lumen may be slow rather than fast, and in several series, as many as 50% of cases of near occlusion of the internal carotid artery have been shown as occlusion by both conventional duplex sonography and color Doppler sonography (2, 3). New technology pertaining to color Doppler machines has enabled an increased sensitivity to slow flow, on the order of 1 to 10 cm/s, by decreasing the

---

Received May 27, 1992; accepted after revision December 28, 1995.

Presented in part at the annual meeting of the American Society of Neuroradiology, Washington, DC, June 1991.

From the Departments of Diagnostic Radiology (D.H.L., F.-Q.G., R.N.R., D.M.P., A.J.F.) and Clinical Neurological Sciences (D.H.L., D.M.P., A.J.F.), University Hospital, University of Western Ontario, London, Ontario, Canada.

Address reprint requests to Donald H. Lee, MB, BCh, Radiology Department, University Hospital, 339 Windermere Rd, Box 5339, London, Ontario, Canada N6A 5A5.

AJNR 17:1267-1274, Aug 1996 0195-6108/96/1707-1267

© American Society of Neuroradiology

pulse repetition frequency and slowing the frame rate.

To determine whether this slow-flow color Doppler flow imaging technology does indeed improve sensitivity and specificity in differentiating near occlusion from occlusion of the internal carotid artery, we reviewed the records of all patients in our institution who were examined with slow-flow-sensitivity color Doppler flow imaging over a period of 6½ years.

## Materials and Methods

Because, to date, angiography has been the standard of reference by which to determine patency of the internal carotid artery, we accessed our hospital's angiographic reports to obtain potential patients.

We located 206 reports of internal carotid artery occlusion or near occlusion as demonstrated by selective common carotid angiography from July 1988 to December 1994. Near occlusion is defined here as 95% to 99% stenosis of the vessel's diameter with distal flow limitation such that the artery is smaller distal to the stenosis, there is delayed filling of the internal carotid artery compared with the external carotid artery, and there is no filling or poor filling of anterior or middle cerebral arteries and branches on selective common carotid angiography. In near occlusion, there will normally be some collateral supply to the ipsilateral hemisphere, either from the circle of Willis or the external carotid artery branches, most commonly to the ophthalmic artery.

The 206 cases comprised 70 near occlusions and 136 occlusions. All the patients had signs or symptoms referable to transient ischemia attack, stroke, or reversible neurologic deficit. Criteria for inclusion in our analysis were: angiographic correlation, examination by color Doppler flow imaging with low-flow sensitivity in both sagittal and axial planes if standard-flow-sensitivity color Doppler flow imaging showed apparent occlusion of the internal carotid artery, and examination by duplex sonography. Of the 206 cases found, 74 patients with 77 angiographic occlusions or near occlusions of the internal carotid artery met these criteria. The remainder either had not had color Doppler flow imaging and/or duplex sonography, had the study performed outside our institution, had color Doppler flow imaging performed only in the sagittal plane, or had high-flow-sensitivity color Doppler flow imaging alone in the case of apparent occlusion on color Doppler flow imaging. In addition, on review of the angiographic images, we found that some of the cases called near occlusion in the angiographic report did not meet the definition of near occlusion described above; that is, two patients had only a severe stenosis. The 74 patients included 23 women and 51 men ranging in age from 46 to 81 years. The mean age of the women was 67 years; for the men, the mean age was 66 years.

Duplex sonography was performed using a Dasonics (Milpitas, Calif) SPA 1000, Quantum (Issaquah, Wash)

QAD 1, Quantum 2000 (Siemens, Issaquah, Wash), or Ultramark 9 (Advanced Technologies, Bothell, Wash) system, as described below, with a 7.5-MHz linear transducer. Doppler shift was measured using a 3-MHz transducer. Color Doppler flow imaging was performed with three units: (a) a 7.5-MHz linear array transducer or, in patients with very deep vessels, a 5-MHz linear array transducer with a fluid-filled, plastic stand-off wedge attached to the transducer (QAD 1); (b) a 7.5-MHz linear array transducer or 5-MHz linear array transducer with fluid-filled, plastic stand-off wedge attached to the transducer (Quantum 2000); or (c) a 5-MHz linear array transducer (Ultramark 9 with vascular upgrades over the course of the study). In all color units, the returning echoes were analyzed for amplitude (giving a gray scale), as well as for phase (giving direction of flow) and frequency (Doppler information). Color saturation was given to the frequency shifts, and phase changes relative to the transducer were assigned by the operator as shades from red to blue. For ease of interpretation, arterial flow was assigned shades of red. By using slower frame rates and pulse repetition frequencies, slow flows of between 1 and 10 cm/s could be imaged. In a vascular phantom, using constant velocities, it has been shown that the units have excellent linearity for depicting slow flow of greater than 5 cm/s (4) and for depicting flow of lesser velocity, but with less certainty. Our current technique for the depiction of slow flow is a pulse repetition frequency of 700 Hz and a color sensitivity range of +5 cm/s to -5 cm/s on the Ultramark 9, and the "low flow" setting on the Quantum.

All color Doppler flow imaging examinations included axial (transverse) and sagittal (longitudinal) views of the vessels as well as image-directed Doppler sampling. The color Doppler flow imaging part of the examination was always performed after conventional duplex imaging, and, as the accuracy of the technology was uncertain, the duplex examination was never abbreviated because of the availability of color Doppler during the first 36 cases.

The study consisted of two phases. In the first phase, conducted between 1988 and 1991, we retrospectively reviewed the records of 35 patients with nearly occluded ( $n = 16$ ) or occluded ( $n = 20$ ) arteries. In the second phase, which took place between 1992 and 1994, we incorporated color Doppler flow imaging with slow-flow sensitivity into the routine sonographic protocol, with subsequent angiographic correlation. The second phase was undertaken because results of the first part of the study showed high sensitivity (100%) and specificity (90%) of the color examination. During the first phase, sonograms were reinterpreted without knowledge of the results of angiography, and the duplex and color Doppler findings were judged as showing either patent or occluded vessels. The duplex and color Doppler images were always evaluated together in this part of the study, as most used color Doppler flow imaging-based Doppler sampling. The duplex, color Doppler flow imaging, and angiographic results were then correlated.

Overall, the time between sonography and angiography ranged from 0 to 47 days, with a mean of 9 days. When

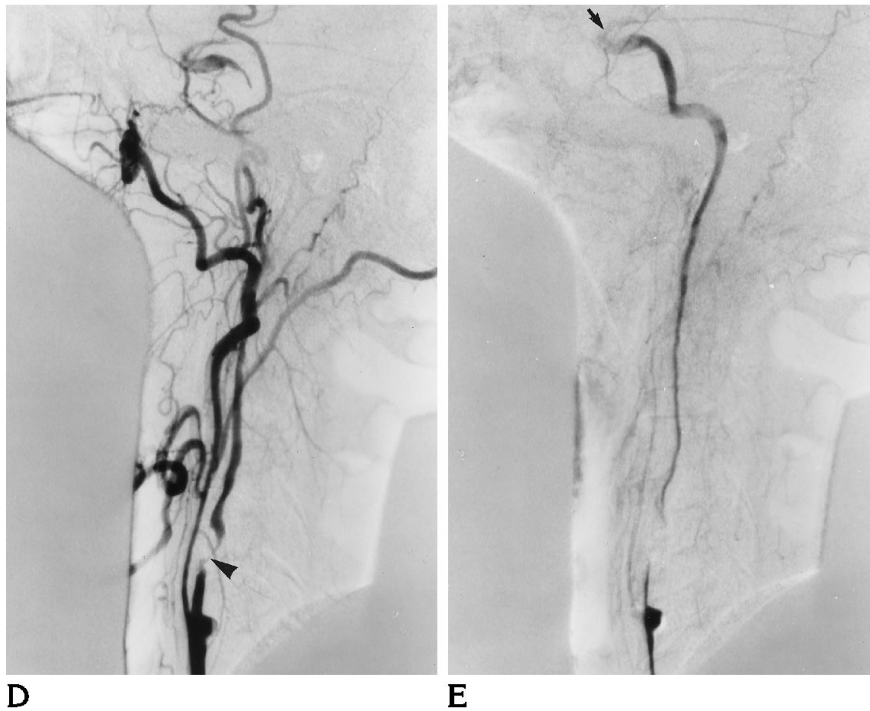
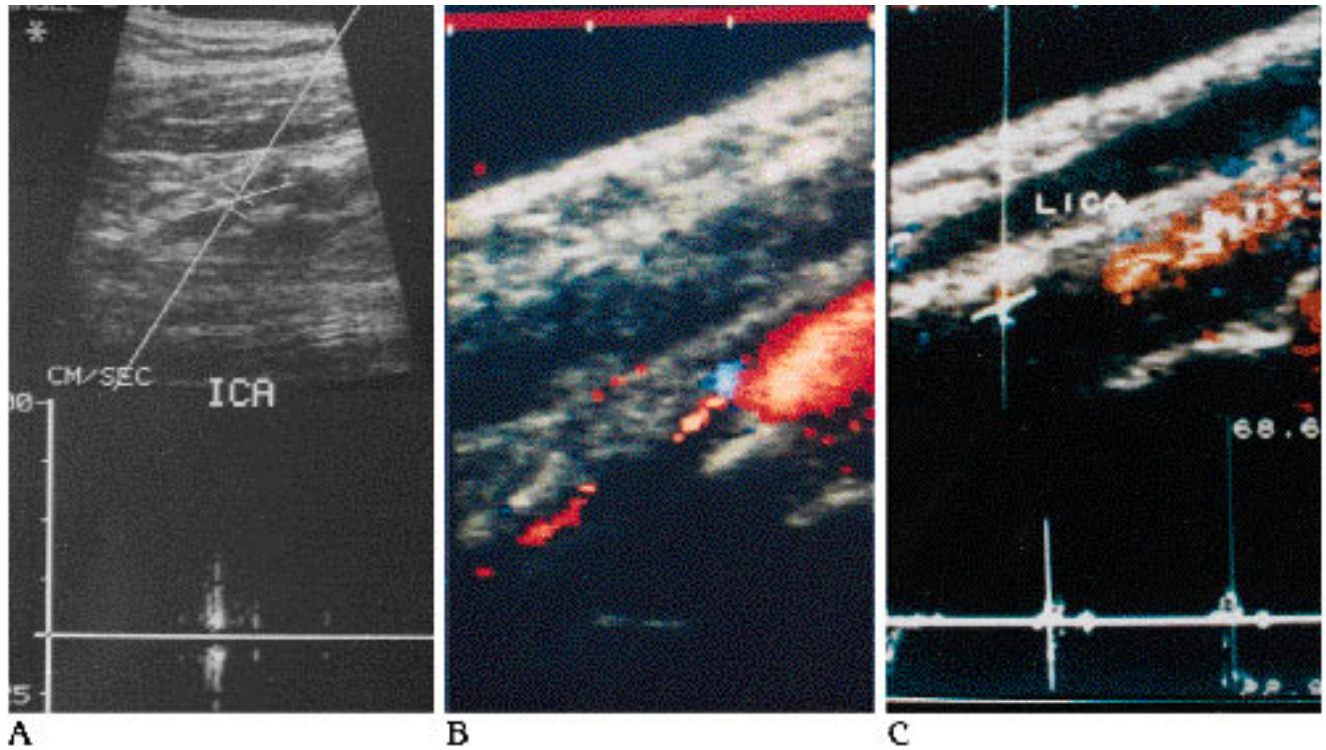


Fig 1. Near occlusion of the internal carotid artery.

A, Duplex sonogram shows absent waveforms.

B, Color Doppler flow image shows flow in the internal carotid artery.

C, Image-guided Doppler sampling shows definite forward flow, with damped internal carotid artery waveform and peak velocity measured at 10 cm/s.

D, Angiogram of common carotid artery shows near occlusion (arrowhead) in the left internal carotid artery.

E, Late subtraction image shows complete left internal carotid artery to supraclavoid region (arrow).

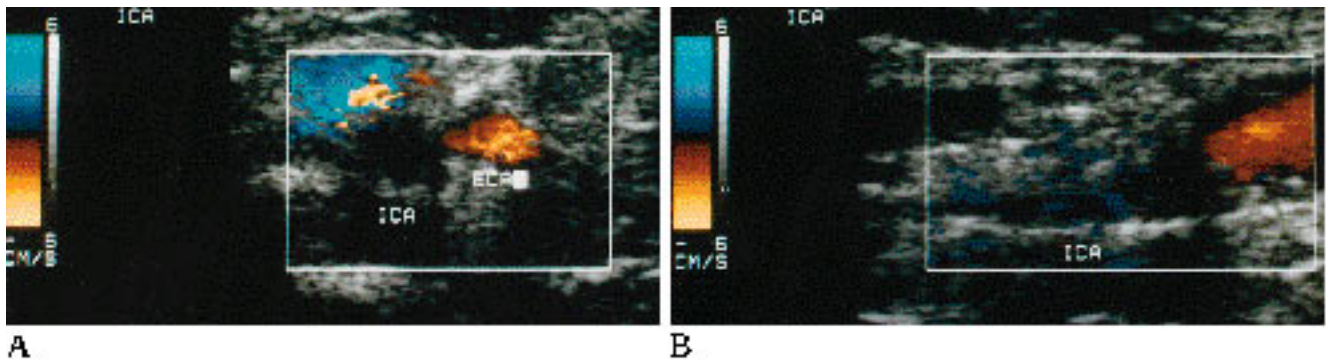
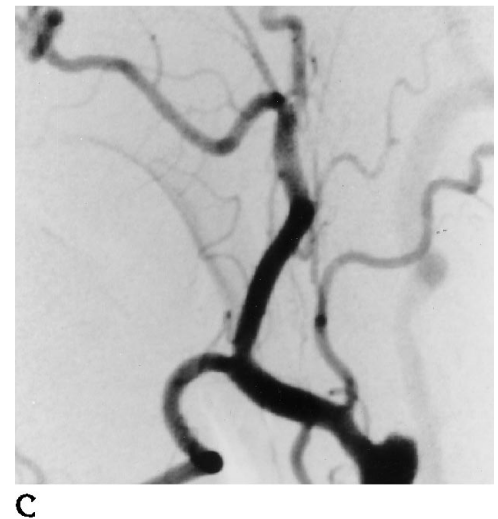


Fig 2. Occlusion of the internal carotid artery.  
 Axial (A) and sagittal (B) views of color Doppler sonogram show no evidence of flow. Note use of slow-flow sensitivity (+6 to -6 cm/s range on color Doppler scale to left of image and pulse repetition frequency of 700).  
 C, Angiogram confirms total occlusion of internal carotid artery.



sonography was performed after angiography ( $n = 15$ ), the delay time ranged from 1 to 15 days, with a mean of 3.5 days. In the first phase, 30 patients had sonography before angiography; two had it on the same day as angiography, two had it less than 2 weeks after angiography. One patient had sonography 8 months after angiography for signs and symptoms in the carotid artery contralateral to an angiographically proved internal carotid artery occlusion. In the second phase, 29 patients had sonography before angiography, 10 afterward (all less than 2 weeks). Color Doppler sonography was performed in all 43 cases of internal carotid artery occlusion and in all 34 cases of internal carotid artery near occlusion.

Cut-film or digital subtraction angiography was performed using the standard Seldinger technique, with selective catheterization of the common carotid artery, and filming was obtained in the anteroposterior and lateral planes. Standard film sequences were performed, with filming continued out into the venous phase. Late film subtractions were obtained in all cases of apparent occlusion to exclude near occlusion. Most patients had bilateral selective common carotid artery and aortic arch angiography, but when there was poor visibility of middle or anterior cerebral branches on the side of occlusion/near occlusion, vertebral or subclavian artery angiography was also performed.

## Results

Among the 74 patients in the first phase of the study, two had an occlusion on one side and a near occlusion on the other, and another patient had bilateral near occlusions of the internal carotid artery. There were 20 left-sided and 23 right-sided occlusions, and 19 left-sided and 15 right-sided near occlusions.

In the nearly occluded internal carotid arteries ( $n = 34$ ), color Doppler flow imaging and duplex sonography successfully indicated near occlusion in all cases in which both imaging methods were used. There were no cases in which near occlusion was called occlusion. In eight of 34 cases of near occlusion, color Doppler flow images were interpreted as showing vessel patency while the duplex sonograms were interpreted as showing occlusion. Figure 1 shows a typical case. After color Doppler sonography became part of the standard evaluation, image-directed Doppler sampling was done from the color Doppler flow image rather than from the gray-scale

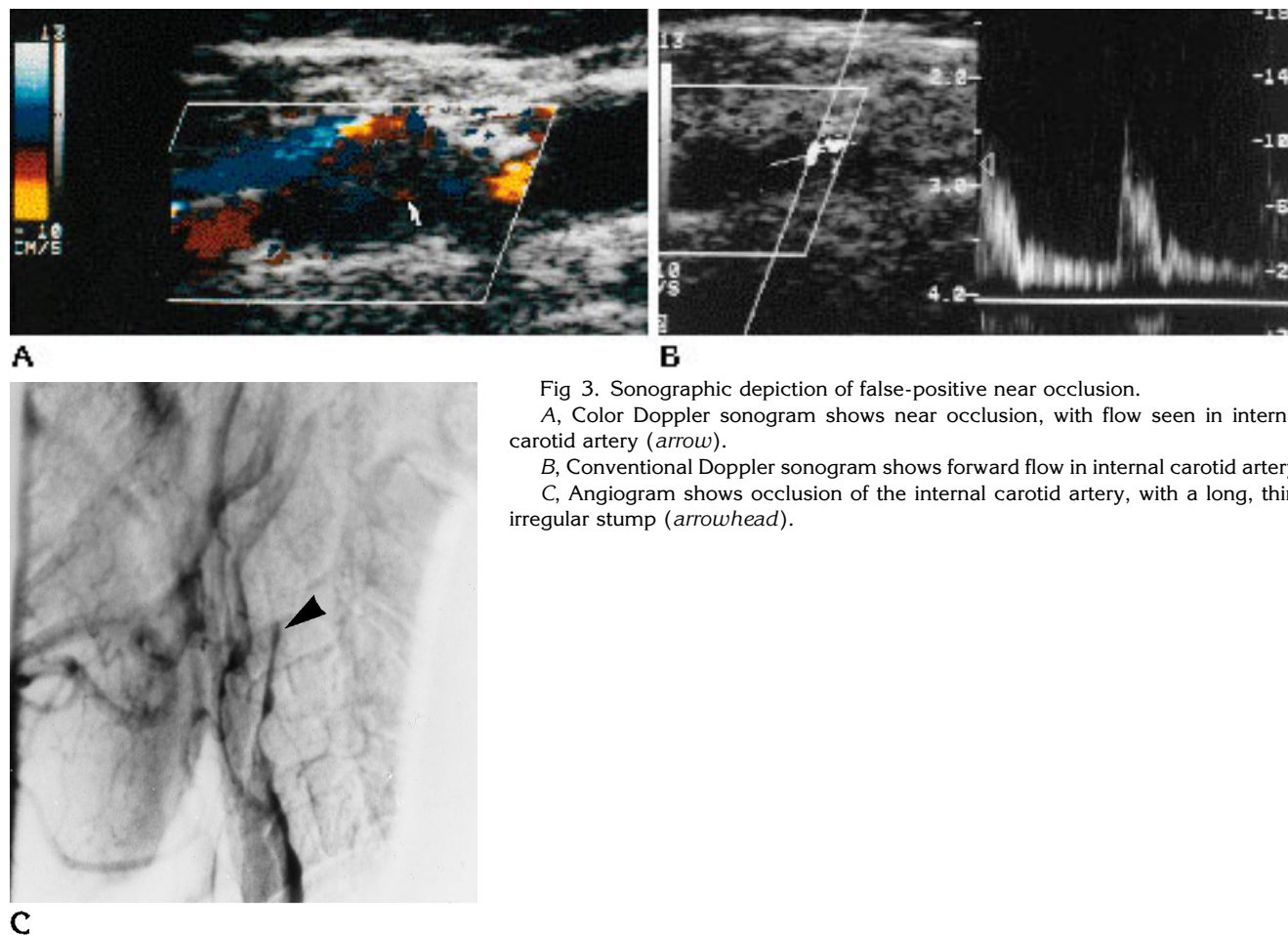


Fig 3. Sonographic depiction of false-positive near occlusion.  
 A, Color Doppler sonogram shows near occlusion, with flow seen in internal carotid artery (arrow).  
 B, Conventional Doppler sonogram shows forward flow in internal carotid artery.  
 C, Angiogram shows occlusion of the internal carotid artery, with a long, thin, irregular stump (arrowhead).

TABLE 1: Near occlusion and occlusion of the carotid artery as shown by conventional duplex sonography and color Doppler imaging, compared with angiography

	Near Occlusion	Occlusion
Angiography	34	0
Duplex sonography	26	8
Color Doppler imaging*	34	0
Angiography	0	43
Duplex sonography	5	38
Color Doppler imaging	7	36

\* The near occlusion detection rate for color Doppler imaging with low sensitivity is significantly higher than that for conventional duplex sonography ( $\chi^2 = 7.63, P < .01$ ).

image, as would have been done in conventional duplex sonography.

Among the 43 cases of occluded internal carotid arteries, 36 had duplex and color examinations that showed no flow in the distal internal carotid artery (Fig 2). Flow was shown in the other seven; and, of these, three had color

Doppler flow imaging done within 1 to 5 weeks before angiography, which showed occlusion of the vessel. The other four, done within 1 to 2 days of angiography, showed apparent internal carotid artery patency. An example of falsely patent internal carotid artery by sonography is shown in Figure 3.

The results of the interpretations of all 77 cases of occlusion and near occlusion of the internal carotid artery shown on conventional duplex and color Doppler sonograms as compared with angiographic findings are given in Table 1.

In comparing the first and second phases of the study, we found a significant difference in the detection of near occlusion between conventional duplex and color Doppler flow imaging with low-flow sensitivity ( $P < .05$ ) (Table 2). The sensitivity, specificity, positive predictive value, and negative predictive value of sonography in detecting near occlusion of the carotid artery are given in Table 3. Using our tech-

**TABLE 2: Near occlusion and occlusion of the carotid artery as shown by conventional duplex sonography and color Doppler imaging, compared with angiography in each part of the study**

Sonography	Angiography	
	Near Occlusion (n = 34)	Occlusion (n = 43)
Part 1 (1989–1991)		
Duplex near occlusion (gray-scale only)	8	0
Duplex occlusion*	8	20
Part 2 (1992–1994)		
Color Doppler near occlusion	18	5
Color Doppler occlusion	0	18

\* The false-positive rate for occlusion as shown by conventional duplex sonography is significantly higher than that shown by color Doppler flow imaging with low-flow sensitivity ( $\chi^2 = 6.225$ ,  $P < .05$ ).

**TABLE 3: Accuracy of diagnosis of carotid artery near occlusion by sonography**

Sonography	Sensitivity, % (95% CI)	Specificity, % (95% CI)	Positive Predictive Value, % (95% CI)	Negative Predictive Value, % (95% CI)
Part 1: duplex	50 (0.28–0.72)	100 (0.83–1.00)	100 (0.67–1.00)	71 (0.54–0.84)
Part 2: color flow Doppler	100 (0.82–1.00)	78 (0.58–0.91)	78 (0.58–0.91)	100 (0.82–1.00)
Overall duplex	76 (0.60–0.88)	88 (0.75–0.95)	84 (0.67–0.93)	83 (0.69–0.91)
Overall color flow Doppler	100 (0.89–1.00)	84 (0.70–0.92)	83 (0.68–0.92)	100 (0.90–1.00)

Note.—CI indicates confidence interval.

niques, for duplex examination alone, sensitivity was 76% and specificity was 88%; the positive predictive value was 84%, and the 95% confidence interval was 67% to 93%. For color Doppler flow imaging, sensitivity was 100% and specificity 84%; the positive predictive value was 83%, and the 95% confidence interval was 68% to 92%. Of particular note is the fact that no near occlusions were misdiagnosed as occlusions on the color Doppler flow images. Note also that the second part had color Doppler images guiding the Doppler sampling. In the first part of the study, slow flow was used in 26 of 36 cases; in the second part, it was used in all 41 cases.

## Discussion

It is important to ascertain patency of the internal carotid artery in patients with ipsilateral neurologic deficit (either reversible or permanent), because these patients can benefit from carotid endarterectomy (5), whereas patients with occlusion, even with carotid stumps, cannot. Our study does have selection bias in that only patients who had sonography and angiography in our institution were analyzed. However, it shows that, provided a thorough study is performed, the use of color Doppler flow imaging

with slow-flow sensitivity will ensure that there is little likelihood that near occlusion of the internal carotid artery will be misinterpreted as occlusion (100% sensitivity, 84% specificity). A thorough study means that Doppler images should be obtained in the axial and sagittal planes at, and distal to, the carotid bifurcation, which would eliminate one of the reasons for continuing to perform angiography in patients with sonographic occlusion. Our data, because they are selective, like those of Kirsch et al (6), show a positive predictive value of color Doppler sonography of 83%. Although our numbers are smaller than theirs, they show higher sensitivity but lower specificity, because we have included near occlusions in our analysis.

Our sensitivity is equivalent to that of Berman et al (7), who examined 27 near occlusions (but only 16 that were examined with color Doppler sonography). Because their series selected only patients undergoing carotid endarterectomy, it is difficult to know the specificity. Also, in their series, they maintained pulse repetition frequency at 5000 Hz, but decreased wall filter to 50 Hz. Wall filter is a software algorithm on the sonographic unit that removes very low frequency Doppler data from the display. Kirsch et al (6) also decreased wall filter, and they mention that the instrument was adjusted for maxi-

mum flow sensitivity; however, they do not mention specifically whether pulse repetition frequency was adjusted. We believe it is important to reduce the wall filter as well as the pulse repetition frequency to ensure maximum machine sensitivity to slow flow. Our data are similar to those of Mattos et al (8), who described color Doppler flow imaging in 109 vessels with 80% to 99% stenosis angiographically and 83 vessels with 100% stenosis (occlusion), although the angiographic method for measurement is not given. These researchers reported 100% sensitivity and specificity in a subgroup of 100 patients examined later in their 3½-year study period, when they had slow-flow technology in their color Doppler unit.

It is reassuring that, in our series, the only diagnostic errors made with the use of Doppler imaging were in misinterpreting angiographic occlusion of the internal carotid artery as near occlusion, thus explaining our lower specificity rate. Our results are similar to those of Gortler et al (9), in which three of 106 occlusions were misinterpreted on color Doppler flow images as near occlusion. The reasons for apparent vessel patency on color Doppler flow images are variable. Possible explanations are interpretative error in which the stump is called a patent vessel (see Fig 3) or another vessel is mistaken for the internal carotid artery (in particular, the ascending pharyngeal artery). This might be the explanation in the case in which there was a short interval between angiography and sonography. Other explanations include interval occlusion of the internal carotid artery (as might have been the situation for the patient in whom a month elapsed before angiography was performed) or iatrogenic occlusion of the vessel (although this possibility would be highly unlikely). Another theory, postulated by Gortler et al (9), involves "thrombus-supplying arteries," presumably vascularized thrombus, which may produce apparent flow in occluded vessels.

The apparently higher specificity of duplex sonography for detecting near occlusion is at the expense of a significant (20%) decrease in sensitivity. Also, in the second phase of our study, color Doppler imaging was almost always done, with conventional Doppler sampling obtained from the color Doppler information, so that it was not operator-dependent. This would raise the sensitivity of conventional duplex imaging, which is reflected in our figures.

Whether the cases of misinterpretation of occlusion by sonographic evaluation are important from a management aspect is difficult to determine, because the next investigative procedure would be angiography in almost all instances. Although the risks of cerebral angiography are low (10), it could be argued that if a patient with occlusion had a complication as a result of the angiography, the diagnosis of occlusion by sonographic examination exposes the patient to more risk, implying that the sonography is of limited value in patient treatment. However, with the increasing use of magnetic resonance (MR) angiography, there may come a time when MR angiography, rather than conventional angiography, is widely accepted as the next investigative step. Certainly, recent data suggest that MR angiography is a good complement to sonography in determining internal carotid artery occlusion (11). Moreover, the use of intravenous microparticle contrast material may assist in the sonographic detection of very slow flow near occlusions as well as in differentiating them from occlusions (12). In this way, the patient may not be subjected unnecessarily to the risks of angiography merely to verify arterial occlusion.

We had no cases in which angiography was inadequate for demonstrating near occlusion. Inadequate examinations could potentially occur with the use of nonselective angiography, improper timing of filming, causing very slow flow in the internal carotid artery (which would be seen only in the venous phase) to be missed, or nonsubtraction of the delayed images, with the residual lumen missed on the unsubtracted images.

We are not proposing that sonography alone replace arterial angiography. However, our findings do suggest that when thorough sonographic examination shows no evidence of flow in the internal carotid artery on the symptomatic side, conventional angiography need not be done. Transcranial Doppler sonography, especially color Doppler sonography (13, 14) of both the anterior and posterior circulation, and MR angiography may also be able to alleviate the concern of missing a nearly occluded vessel or to locate the disease more precisely, as has been suggested (15). Finally, while color Doppler flow imaging may more successfully depict near occlusions, it still has the inherent limitations of sonography; namely, that calcified plaque may obscure vessel patency or that ad-

ditional abnormalities, such as intraluminal thrombus, may be missed. We conclude that color Doppler flow imaging with slow-flow sensitivity is an essential component of the noninvasive differentiation of occlusion from near occlusion of the internal carotid artery.

## References

1. Scoutt LM, Zawin ML, Taylor KJW. Doppler US, II: clinical applications. *Radiology* 1990;174:309-319
2. Steinke W, Kloetsch C, Hennerici M. Carotid artery disease assessed by color Doppler flow imaging: correlation with standard Doppler sonography and angiography. *AJNR Am J Neuroradiol* 1990;11:259-266
3. Erickson SJ, Mewissen MW, Foley WD, et al. Stenosis of the internal carotid artery: assessment using color Doppler imaging compared with angiography. *AJR Am J Roentgenol* 1989;152:1299-1305
4. Rickey DW, Rankin RN, Fenster A. A velocity evaluation phantom for color and pulsed Doppler instruments. *Ultrasound Med Biol* 1992;18:479-494
5. North American Symptomatic Carotid Endarterectomy Trial Collaborators. Beneficial effect of carotid endarterectomy in symptomatic patients with high grade carotid stenosis. *N Engl J Med* 1991;325:445-453
6. Kirsch JD, Wagner LR, James EM, et al. Carotid artery occlusion: positive predictive value of duplex sonography compared with arteriography. *J Vasc Surg* 1994;19:642-649
7. Berman SS, Devine JJ, Erdoes LS, et al. Distinguishing carotid artery pseudo-occlusion with color-flow Doppler. *Stroke* 1995;26:434-438
8. Mattos MA, Hodgson KJ, Ramsey DE, et al. Identifying total carotid occlusion with colour flow duplex scanning. *Eur J Vasc Surg* 1992;6:204-210
9. Gortler M, Niethammer R, Widder B. Differentiating subtotal carotid artery stenosis from occlusions by colour-coded duplex sonography. *J Neurol* 1994;241:301-305
10. Dion JE, Gates PC, Fox AJ, et al. Clinical events following neuroangiography: a prospective study. *Stroke* 1987;18:997-1004
11. Currie IC, Murphy KP, Jones AJ, et al. Magnetic resonance angiography or IADSA for diagnosis of carotid pseudo occlusion? *Eur J Vasc Surg* 1994;8:562-566
12. Sitzer M, Furst G, Siebler M, et al. Usefulness of an intravenous contrast medium in the characterization of high-grade internal carotid stenosis with color Doppler-assisted duplex imaging. *Stroke* 1994;25:385-389
13. Tsuchiya T, Yasaka M, Yamaguchi T, et al. Imaging of the basal cerebral arteries and measurements of blood velocity in adults by using transcranial real-time color flow Doppler sonography. *AJNR Am J Neuroradiol* 1991;12:497-502
14. Hashimoto BE, Hatrick CW. New method of adult transcranial Doppler. *J Ultrasound Med* 1991;10:349-353
15. Caplan LR, Wolpert SM. Angiography in patients with occlusive cerebrovascular disease: views of a stroke neurologist and neuroradiologist. *AJNR Am J Neuroradiol* 1991;12:593-601