

# Dural Arteriovenous Fistula in Association with Heterotopic Brain Nodule in the Transverse Sinus

Christopher Kollar, Ian Johnston, Geoff Parker, and Clive Harper

**Summary:** We describe a 56-year-old woman with a dural arteriovenous fistula involving the transverse sinus in association with a nodule of heterotopic brain tissue in the sinus. This finding is discussed in light of a recent radiologic study of nodules in the transverse sinus.

In a recent report, Roche and Warner (1) described the radiologic appearance of nodules in the transverse sinus, which they assumed to be arachnoid granulations. The present report describes a nodule in this region, found to be cerebral tissue, which was associated with a symptomatic dural arteriovenous fistula (DAVF) involving the transverse sinus. This finding raises the issue of the nature of intrasinus nodules and their relationship to acquired DAVFs.

## Case Report

In May 1994, a 56-year-old woman reported a pulsatile noise in her left ear, which had been present for many weeks, increasing in loudness from being perceptible only at night to being present at all times. The patient's medical history included primary endometrial and ovarian carcinoma, treated with surgery, chemotherapy, and radiotherapy, with no evidence of residual disease.

Examination revealed a bruit heard loudest high in the left side of the neck below the ear, with decreasing amplitude over the left mastoid, temporal region, and orbits. The bruit was unaffected by jugular compression, but was abolished by pressure over the common carotid artery. Findings at neurologic examination were normal, with no proptosis, decrease in visual acuity, or changes in the fundi. Carotid Doppler studies were normal.

In October 1994, cerebral angiography was performed, revealing a large left-sided DAVF, fed predominantly by branches of the left external carotid artery and draining into the left transverse sinus. A partial filling defect was noted in the left transverse sinus and was thought to represent residual clot from a possible previous thrombus (Fig 1–C). There was no significant supply from the posterior circulation.

Having initially declined embolization, the patient was admitted in July 1995 for two sessions of transarterial embolization of the fistula on consecutive days and for surgical removal several days later. Left occipital and posterior fossa craniectomy was performed, with an en bloc resection of the DAVF, left transverse sinus, and the majority of the sigmoid sinus.

Only dural tissue was removed. The postoperative course was uneventful. Coil embolization of the remaining stump of the sigmoid sinus was performed, resulting in complete obliteration of the lesion (Fig 1D). The patient remains neurologically intact and is free from any bruit.

Examination of the tissue removed at surgery revealed a pale, rounded nodule approximately 5 mm in diameter attached to the wall of the transverse sinus and projecting into the lumen. Under microscopic examination, the nodule consisted of a covering of meningeal tissues continuous with the dura of the sinus. The nodule appeared to be distorting and compromising the lumen of the sinus. There was no evidence of previous thrombosis or organization. The body of the nodule consisted of neural tissue with both gray and white matter. There was no definite evidence of nerve cell laminations, and, apart from their location, the neurons were otherwise normal in appearance. Vessels of the fistula were seen in other parts of the sinus wall, and some of them were occluded with material used for embolization (Fig 1E and F).

## Discussion

Incidental polypoid findings in the dural sinuses are not uncommon (2, 3). Such findings may be divided into two groups: those that represent a normal anatomic variant and those that could be described as ectopic tissue in the sinuses. Roche and Warner (1) estimated their prevalence as between 0.3% and 1%, and stated that all are arachnoid granulations. Their study did not include any histologic examinations, but instead referred to previous reports in which radiologic and histologic examinations were compared (4, 5). Our review of findings in the literature indicates that many of the nodules described in their study may not have been arachnoid granulations.

Normal anatomic variants in the sinuses are represented not only by the relatively common arachnoid granulations but also by the firm polypoid nodules described by Browder et al (2, 3). These nodules differ from normal granulations in that they are present even in infancy, are much firmer, and are covered by a shiny, smooth capsule. They seem to be relatively common, found predominantly in the transverse sinuses in about 8% of autopsy cases. Several reports (6, 7) have indicated that the finding of a

Received June 4, 1997; accepted after revision August 19.

Supported by the Madeline Foundation for Neurosurgical Research.

From the Madeline Foundation Laboratory, University of Sydney (C.K.), and the Departments of Neurosurgery (I.J.), Radiology (G.P.), and Anatomical Pathology (C.H.), Royal Prince Alfred Hospital, Sydney, Australia.

Address reprint requests to Christopher Kollar, MD, Madeline Foundation Laboratory, Room 323, Bldg DO6, University of Sydney, Sydney 2006, Australia

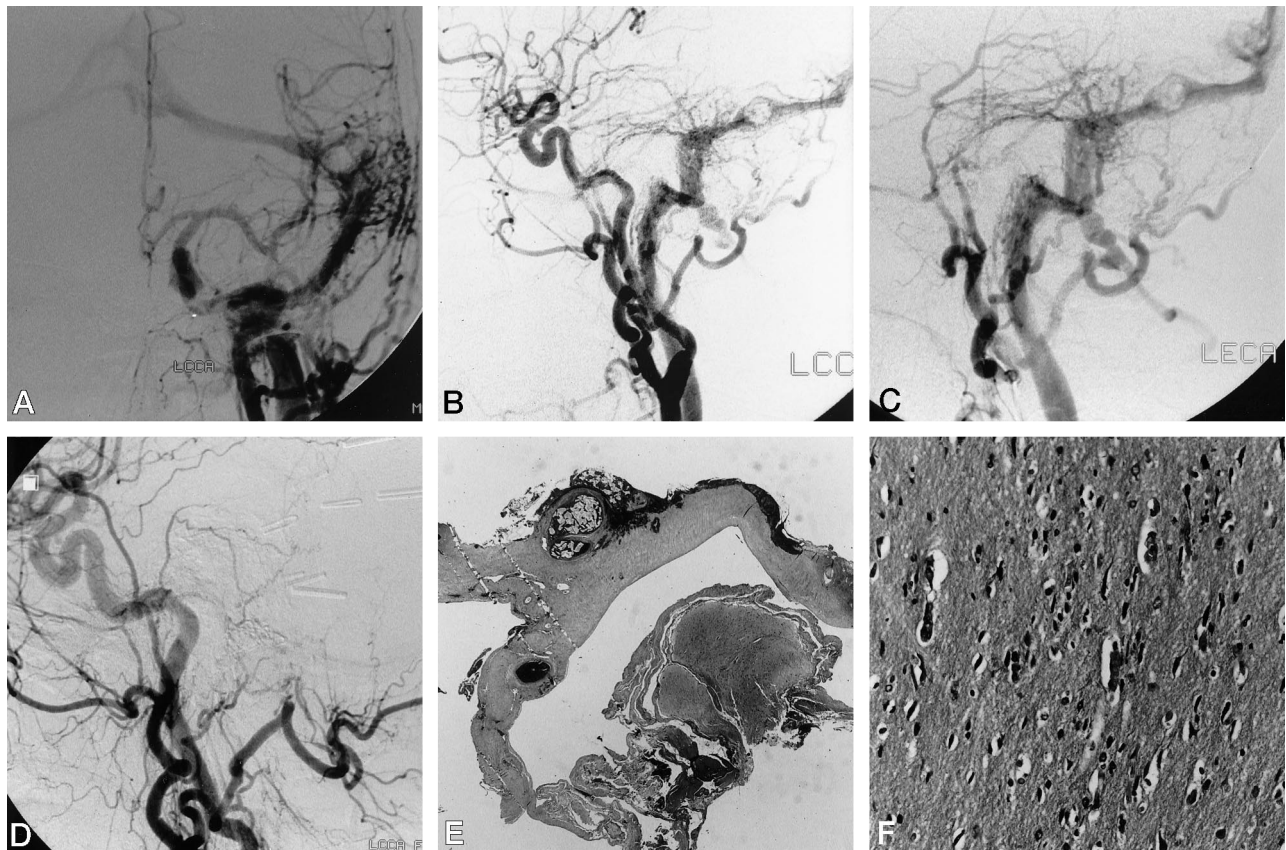


FIG 1. 56-year-old woman with several-week history of pulsatile bruit in left ear.

A and B, Anteroposterior (A) and lateral (B) projections of DAVF—left common carotid artery injection show a filling defect in the transverse sinus, corresponding to nodule.

C, Lateral projection of left external carotid artery injection shows the nodule filling and distorting the sinus.

D, Left common carotid artery injection after surgery and embolization of residual stump.

E, Pathologic specimen of DAVF shows embolization material (top left) (original magnification  $\times 2$ ).

F, Pathologic specimen at higher-power magnification shows normal-appearing neurons (original magnification  $\times 30$ ).

nodule composed of erectilelike tissue without elastic or muscular elements is a common occurrence in the sinuses, particularly at the junction of the vein of Galen and the straight sinus. While it has been reported that a nodule may be found in this location in up to 10% of autopsy examinations (8), other studies have indicated that this type of tissue is present in this and other locations in all persons (7, 8).

Descriptions of nodules of ectopic tissue found in the dural sinuses include reports of fat in the sinuses by Tokiguchi and others (9, 10), which can easily be distinguished from the nodules with a low-density appearance on CT scans reported by Roche and Warner (1). A report by Beatty et al (11) of two unusual nodules found in the sinuses of children, one of them an infant, describes pedunculated nodules protruding into the lumen, composed of fat, fibrous tissue, and psammoma bodies. These authors presume the nodules to be arachnoid granulations, but their appearance does not correlate well with the classic descriptions of granulations (12).

Our findings in the present case differ from all these descriptions and seem to be unique in that ectopic brain tissue was present. The nodule in our patient was presumably a hamartomatous lesion. Un-

fortunately, the history of DAVF was so strong that the patient proceeded straight to angiography, without a prior CT or MR imaging examination, so it is not possible to compare this finding with the radiologic descriptions of nodules given by Roche and Warner (1).

Although the unusual findings in the present case may be coincidental, it is also possible that there is some link between the two pathologic entities. Houser et al (13) presented two cases of DAVFs involving the transverse sinus that arose within 4 years of thrombosis of the ipsilateral transverse sinus. Neither fistula was present on angiograms at the time of thrombosis. The authors reviewed 14 cases of DAVF involving the transverse sinus and reported that the ipsilateral sinus lumen was occluded or compromised in 10 of these. They postulated that the increased venous pressure in the sinus may have forced the dysplastic vessels in the dura to dilate. This theory is supported by an experimental study in rats, in which an increase in venous pressure by carotid-jugular shunting resulted in acquired arteriovenous fistulas, of which one was dural (14). In the present case, the lumen of the left transverse sinus was seen to be compromised at angiography, and it is possible that

this could have been responsible for the development of the DAVF, either through an increase in venous pressure or through a predisposition to the development of transverse sinus thrombosis with subsequent DAVF formation. If this was the case, it is interesting to speculate on the natural history of the nodule, because the reports cited above indicate that the DAVF develops within, at most, a few years of the compromise to blood flow.

### References

1. Roche J, Warner D. **Arachnoid granulations in the transverse and sigmoid sinuses: CT, MR, and MR angiographic appearance of a normal variation.** *AJNR Am J Neuroradiol* 1996;17:677-683
2. Browder J, Browder A, Kaplan HA. **Benign tumors of the cerebral dural sinuses.** *J Neurosurg* 1972;37:576-579
3. Browder J, Kaplan HA, Howard EM. **Hyperplasia of the pacchionian granulations.** *Arch Pathol Lab Med* 1973;95:315-316
4. Tokiguchi S, Hayashi S, Takahashi H, Okamoto K, Ito J. **CT of the pacchionian body.** *Neuroradiology* 1993;35:347-348
5. Mamourian AC, Towfighi J. **MR of giant arachnoid granulation, a normal variant presenting as a mass within the dural sinus.** *AJNR Am J Neuroradiol* 1995;16:901-904
6. Clark WEL. **A vascular mechanism related to the great vein of Galen.** *BMJ* 1940;1:476
7. Baló J. **The dural venous sinuses.** *Anat Rec* 1950;106:319-325
8. Bergquist E, Willén. **Cavernous nodules in the dural sinuses.** *J Neurosurg* 1974;40:330-335
9. Tokiguchi S, Ando K, Tsuchiya T, Ito J. **Fat in the dural sinus.** *Neuroradiology* 1986;28:267-270
10. Tokiguchi S, Kurashima A, Ito J, Takahashi H, Shimbo Y. **Fat in the dural sinus: CT and anatomical correlations.** *Neuroradiology* 1988;30:78-80
11. Beatty RM, Hornig GW, Hanson EJ. **Protruding arachnoid granulations mimicking dermoid cysts.** *J Pediatr Surg* 1989;24:411-413
12. Upton ML, Weller RO. **The morphology of cerebrospinal fluid drainage pathways in human arachnoid granulations.** *J Neurosurg* 1985;63:867-875
13. Houser OW, Campbell JK, Campbell RJ, Sundt TM. **Arteriovenous malformation affecting the transverse dural sinus: an acquired lesion.** *Mayo Clin Proc* 1979;54:651-661
14. Terada T, Higashida RT, Halbach VV, et al. **Development of acquired arteriovenous fistulas in rats due to venous hypertension.** *J Neurosurg* 1994;80:884-889