

Basilar Artery Migraine and Reversible Imaging Abnormalities

Joseph Maytal, Richard B. Libman, and Elizabeth S. Lustrin

Summary: We report a case of a basilar artery migraine in a 17-year-old boy with transient CT and MR abnormalities after each of two migraine episodes. A repeat MR study 6 months after the last event showed complete resolution of the lesion. Transient abnormalities on brain images similar to those shown in our case have been reported in patients with migraine and other neurologic conditions and are most likely related to cerebral vasogenic edema.

Basilar artery migraine is a distinctive form of migraine characterized by neurologic signs referable to the brain stem, cerebellum, and occipital cortex, areas supplied by the basilar artery and its branches. This type of migraine was described initially in adolescent girls (1). The onset of each attack is sudden and the episode usually includes visual manifestations, vertigo, gait ataxia, dysarthria, tinnitus, and impairment of consciousness in varying combinations (2). Ischemic cerebral infarction that occurs during a migraine attack is rare and the mechanism is uncertain (3, 4). Ischemic strokes attributed to migraine most commonly occur within the territory of the middle cerebral artery (5). Strokes involving the basilar artery territory during migraine are infrequently reported (6-8). We describe a patient who had two episodes of basilar artery migraine in which transient CT, MR, and EEG changes were seen after each attack.

Case Report

A 17-year-old boy was well until he experienced a generalized tonic-clonic seizure while asleep. His initial physical examination was normal, as were MR studies of the brain, EEG, and routine blood tests. He was placed on phenytoin. Four months later, he had a second nocturnal seizure, and the medication was increased. He remained well until 3 months later, when he experienced acute-onset obscuration of his right visual field, which lasted several hours and was accompanied by vertigo, unsteadiness, and dysarthria. He also described a feeling of numbness in the perioral area and over the tips of his fingers. These signs and symptoms were followed by a headache over the left posterior part of his head.

On his initial physical examination the patient was found to be mildly drowsy, fully oriented, and had difficulty speaking. He had a dense right homonymous hemianopsia, right central seventh nerve weakness, bilateral dysmetria, and gait ataxia.

The rest of his neurologic examination was normal. All symptoms and findings resolved completely within 24 hours.

A noncontrast CT scan of the brain showed an area of low attenuation over the left medial occipital cortex. MR images showed a focal area of low signal intensity over the same area on T1-weighted sequences, which became hyperintense on the proton density- and T2-weighted studies (Fig 1A-C). No contrast enhancement was seen. An MR angiogram showed no abnormality. A laboratory evaluation that included routine CSF studies, antithrombin 3, antinuclear antibody, plasminogen, protein C, protein S, prothrombin time, activated partial thromboplastin time, Lyme titer, and serum lactic and pyruvic acid were normal. Cardiac evaluation that included a transesophageal echocardiogram was normal. EEG during wakefulness and sleep showed mild posterior background rhythmic slowing.

A diagnosis of "complicated" basilar artery migraine was made, and the patient was treated with propranolol. He was well until a month later, when he began experiencing headaches, which initially improved with minor analgesics but intensified the next day, mostly posteriorly, and were associated this time with vomiting. The patient described blurring of the left visual field.

Physical examination disclosed mild confusion and incomplete left homonymous hemianopsia. A repeat CT scan of the brain showed complete resolution of the previously noted low-density area in the left occipital region and a new area of low attenuation in the right medial occipital region. A repeat MR examination showed a high-intensity signal abnormality on T2-weighted images over the same area (Fig 1D and E). This finding had not been present on prior imaging studies. A four-vessel angiogram was normal, and a repeat EEG showed continuous polymorphic slowing over the right hemisphere, indicating involvement of white matter in this area. The propranolol dose was increased after the patient received a short course of heparin treatment. Eight months after the second episode, the patient reported only few mild headaches but no recurrence of the visual or cerebellar symptoms. A repeat MR examination of the brain and an EEG showed resolution of the previously described area of T2 hyperintensity in the right occipital lobe (Fig 1F and G), and disappearance of the focal EEG slowing previously present over the right hemisphere.

Discussion

The patient we describe had two rather stereotypical spells of confusion, visual disturbances, ataxia, and vertigo, consistent with the clinical picture of basilar artery migraine (1). Extensive evaluation failed to reveal other potential causes, such as cere-

Received January 21, 1997; accepted after revision August 18.

From the Division of Pediatric Neurology, Schneider Children's Hospital (J.M.), and the Departments of Neurology (R.B.L.) and Radiology (E.S.L.), Long Island Jewish Medical Center, the Albert Einstein College of Medicine, New Hyde Park, NY.

Address reprint requests to Joseph Maytal, MD, Division of Pediatric Neurology, Schneider Children's Hospital, Long Island Jewish Medical Center, New Hyde Park, NY 11040.

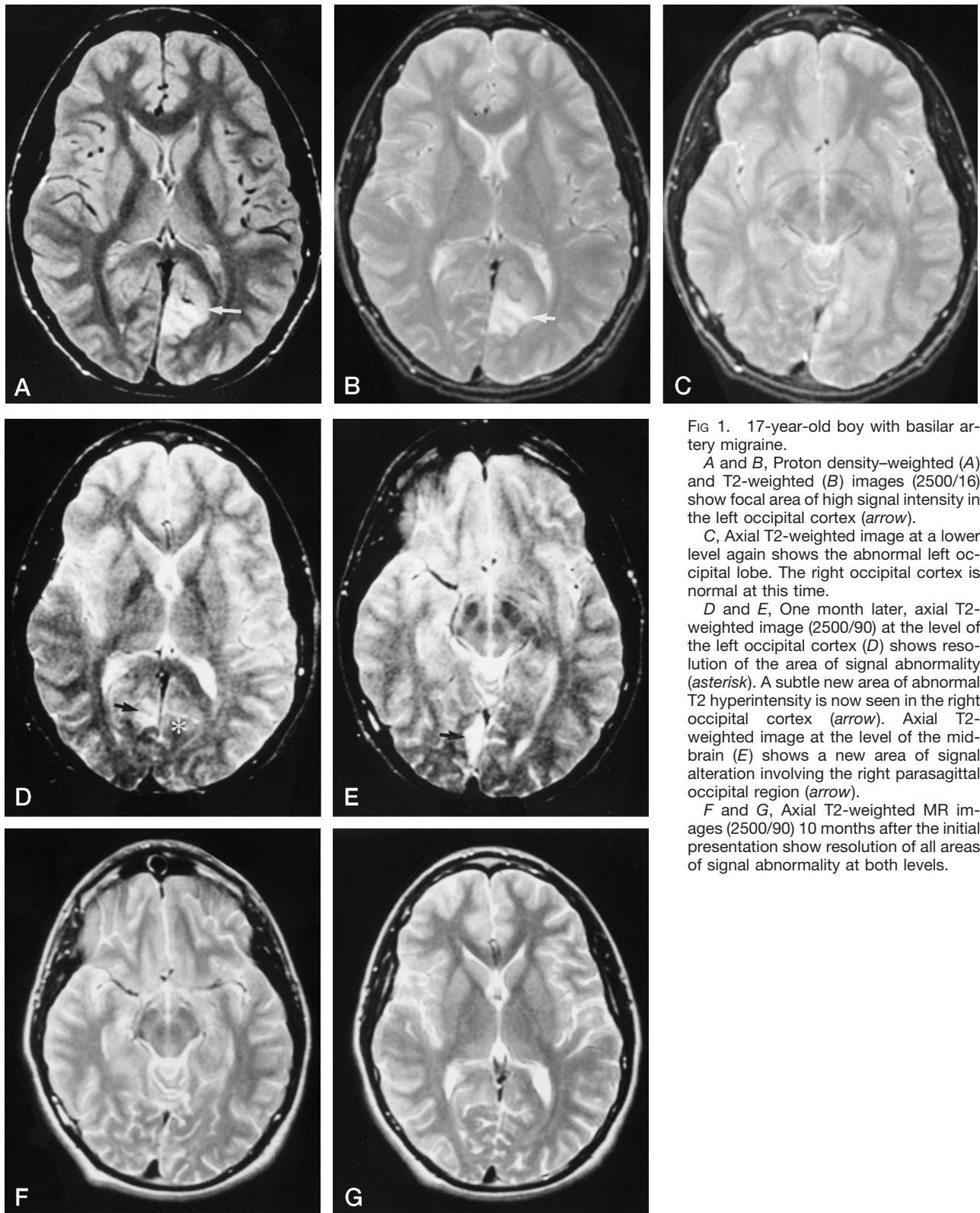


FIG 1. 17-year-old boy with basilar artery migraine.

A and B, Proton density-weighted (A) and T2-weighted (B) images (2500/16) show focal area of high signal intensity in the left occipital cortex (arrow).

C, Axial T2-weighted image at a lower level again shows the abnormal left occipital lobe. The right occipital cortex is normal at this time.

D and E, One month later, axial T2-weighted image (2500/90) at the level of the left occipital cortex (D) shows resolution of the area of signal abnormality (asterisk). A subtle new area of abnormal T2 hyperintensity is now seen in the right occipital cortex (arrow). Axial T2-weighted image at the level of the mid-brain (E) shows a new area of signal alteration involving the right parasagittal occipital region (arrow).

F and G, Axial T2-weighted MR images (2500/90) 10 months after the initial presentation show resolution of all areas of signal abnormality at both levels.

bral angiitis (9) or mitochondrial myopathy, encephalopathy, lactic acidosis, and stroke-like episodes (MELAS) (10) for these attacks. The coexistence of seizures and EEG abnormalities has previously been reported in association with basilar migraine (11).

Whether the primary mechanisms of migraine are vascular or neurogenic is as yet unresolved. Recent biochemical and pharmacologic advances have enhanced our understanding of the pathophysiology of migraine headaches. Headache pain can be generated centrally and, according to the currently prevailing neurogenic theory, involves the serotonergic and adrenergic pain-modulating systems. Neurologically mediated inflammation may account for some of the pain of migraine (12). Previously, migrainous strokes or ischemia have been attributed to arterial vasospasm (13, 14), cerebral edema (15), or to arterial wall dissection (16). No specific pathologic changes that characterize migraines have been consistently identified in any autopsied cases of migrainous stroke (17). Thus, the mechanism of migraine stroke remains open to debate (6).

Only a few case reports have addressed the issue of reversible ischemia in basilar artery migraine. Seto et al (18) reported a case of basilar artery migraine in a 33-year-old woman in whom MR imaging and cerebral angiography failed to show any pathologic findings but emergency technetium-99m single-photon emission CT (SPECT) of the brain showed a significant decrease of regional blood flow over the posterior temporal and occipital cortices, which reverted to normal during a symptom-free phase. Morimoto et al (19) reported a case of a 25-year-old woman with basilar artery migraine and transient MR and EEG changes. A T2-weighted MR study done immediately after the attack revealed a region of high signal intensity in the right occipital lobe. Cerebral hypoperfusion was detected by a SPECT scanner in the same region. MR images obtained 2 months after the last attack showed no abnormalities. The authors postulated that the transient changes seen on the images reflected vasogenic edema. Caplan (8) described nine patients (eight adults and one child) with migraine and posterior circulation ischemia. He reported that the occlusive process could be temporary, since on subsequent angiography two patients had apparent recanalization of previously occluded arteries and one patient had transcranial Doppler evidence of reperfusion. Whether the reperfusion resulted from recanalization, clot lysis, or relaxation of severe vasoconstriction is unknown.

Transient cerebral focal abnormalities on MR images have been reported in patients with intracranial cerebral occlusions stemming from a variety of causes, such as cerebral angiitis and MELAS (20). Resolution of zones of radiolucency on CT scans and of reversible regions of signal abnormalities on T2-weighted MR images has also been observed in patients with prolonged seizures, abnormalities that are thought to be caused by a metabolic disturbance around the ictal focus which result in abnormal vascular permeability and cerebral edema (21, 22).

The great sensitivity of MR imaging to acute ischemia both in the experimental and clinical setting suggests that reversible, transient alterations might be detectable (23). Indeed, experimental models of cerebral ischemia have shown that MR imaging can detect changes associated with ischemia in the first 2 hours after vascular occlusion. Reversibility of acute ischemia has been documented in an experimental model, providing that reperfusion of the ischemic region occurs before the onset of permanent damage (24).

Therapy in the context of migraine with neurologic complications remains poorly defined, and, as our case demonstrates, propranolol may not be the agent of choice. Several case reports have described migraine-associated stroke in patients treated with β -blockers (25). The effects of cerebral vasoconstriction of β -blockers have been implicated (anecdotally) in this complication. We speculate that calcium-channel blockers, or perhaps even tricyclics, may be more appropriate agents, but this subject remains unexplored.

Conclusion

We have presented a case of basilar migraine with reversible imaging abnormalities on CT and MR studies. While the pathogenesis remains uncertain, vasogenic edema may underlie the clinical and imaging findings in this disorder.

References

1. Bickerstaff ER. **Basilar artery migraine.** *Lancet* 1961;1:15
2. Golden GS, French JH. **Basilar artery migraine in young children.** *Pediatrics* 1975;56:722-726
3. Pessin Ms, Lathi ES, Cohen EB, et al. **Clinical features and mechanism of occipital infarction.** *Ann Neurol* 1987;21:290-299
4. Edmeads J. **Stroke in migraine (editorial).** *Headache* 1986;26:149-150
5. Featherstone HJ. **Clinical features of strokes in migraine.** *Headache* 1986;26:128-133
6. Moen M, Levine RS, Newman SD, et al. **Bilateral posterior cerebral artery strokes in a young migraine sufferer.** *Stroke* 1988;19:525-528
7. McDonald VJ. **Basilar artery migraine.** *J Neurosurg* 1990;72:289-291
8. Caplan RL. **Migraine and vertebrobasilar ischemia.** *Neurology* 1991;41:55-61
9. Moore PM. **Diagnosis and management of isolated angiitis of the central nervous system.** *Neurology* 1989;39:167-173
10. Kwock LC, Green C. **MELAS syndrome: imaging and proton MR spectroscopic findings.** *AJNR Am J Neuroradiol* 1995;16:233-239
11. Camfield RP, Metrakos K, Andermann F. **Basilar migraine, seizures, and severe epileptiform EEG abnormalities.** *Neurology* 1978;28:584-588
12. Silberstein SD. **Advances in understanding the pathophysiology of headache.** *Neurology* 1992;42(Suppl 2):6-10
13. Bartleson JD. **Transient and persistent neurological manifestations of migraine.** *Stroke* 1984;15:383-386
14. Mas JL, Baron JC, Boussier MG, Chiras J. **Stroke migraine and intracranial aneurysm: a case report.** *Stroke* 1986;17:1019-1021
15. Wolff HG. **Headache and Other Head Pain.** New York: Oxford University Press; 1972:270-271
16. Sinclair W. **Dissecting aneurysm of the middle cerebral artery with migraine syndrome.** *Am J Pathol* 1953;29:1083-1091
17. Tatemichi TK, Mohr JP. **Migraine and stroke.** In: Barnett HJM, Mohr JP, Stein BM, Yatsu FM, eds. *Stroke, Pathophysiology, Diagnosis, and Management.* New York: Churchill Livingstone; 1986;2: chap 42
18. Seto H, Shimizu M, Futatsuya R, et al. **Basilar artery migraine:**

- reversible ischemia demonstrated by Tc-99m HMPAO brain spect. *Clin Nucl Med* 1994;19:215-218
19. Morimoto Y, Nakajima S, Nishioka R, et al. **Basilar artery migraine with transient MRI and EEG abnormalities.** *Clin Neurol* 1993;33:61-67
 20. Aisen AM, Gabrielsen TO, McCune WJ. **MR imaging of systemic lupus erythematosus involving the brain.** *AJNR Am J Neuroradiol* 1985;6:197-201
 21. Kramer RE, Luders RP, Lesser MR, et al. **Transient focal abnormalities of neuroimaging studies during focal status epilepticus.** *Epilepsia* 1987;28:528-536
 22. Rao TH, Libman RB, Patel M. **Seizures and "disappearing" brain lesions.** *Seizure* 1995;4:61-65
 23. Brant-Zawadzki M, Weinstein P, Bartkowski H, Moseley M. **MR imaging and spectroscopy in clinical and experimental cerebral ischemia: a review.** *AJNR Am J Neuroradiol* 1987;148:579-588
 24. Bell BA, Symon L, Branston NM. **CBF and time thresholds for the formation of ischemic cerebral edema, and effect of reperfusion in baboons.** *J Neurosurg* 1985;62:31-41
 25. Bardwell A, Trott JA. **Stroke in migraine as a consequence of propranolol.** *Headache* 1987;27:381-383