

Small Rosarylike Infarctions in the Centrum Ovale Suggest Hemodynamic Failure

Hilmar Krapf, Bernhard Widder, and Martin Skalej

BACKGROUND AND PURPOSE: Lesions in the centrum ovale may be classified as microangiopathic (lacunar) lesions and hemodynamic infarctions. To distinguish between them, a size of more than 2 cm has been postulated for hemodynamic infarctions. The reliability of this criterion was assessed with MR imaging.

METHODS: In 16 patients with unilateral or bilateral occlusion or high-grade stenosis of the internal carotid artery (ICA), CO₂ testing revealed an ipsilateral hemodynamic failure. Each hemisphere in these patients was assessed separately for the presence and size of centrum ovale lesions.

RESULTS: Five of the 16 patients suffered from large cortical infarctions with a probable embolic pathogenesis. In the remaining 11 patients (22 hemispheres), a hemodynamic failure was found in 15 hemispheres, due to occlusion (13 hemispheres) or high-grade ICA stenosis (two hemispheres). MR imaging revealed centrum ovale infarctions with a size of more than 2 cm in three of the 15 hemispheres. In eight hemispheres, multiple small lesions (<1.5 cm; three to 30 per hemisphere) could be found with a rosarylike or sickle-shaped distribution. In none of these eight cases did MR images show lacunar infarctions in the typical regions of the brain.

CONCLUSION: Our results favor the assumption that the MR finding of multiple small (<1.5 cm) rosarylike lesions in the centrum ovale seems to be typical in patients with hemodynamic failure due to severe ICA disease.

Cranial CT is an established method for classifying cerebral ischemia (1–8). Infarctions have been divided into territorial lesions with a thromboembolic origin, lesions in the terminal and borderzones with a hemodynamic origin, and lacunar lesions due to cerebral microangiopathy. In instances of insufficient collateralization across the circle of Willis and leptomeningeal anastomosis, hemodynamic infarctions may develop in patients with high-grade internal carotid artery (ICA) stenosis or occlusion. Relative to other types of stroke, however, such hemodynamically induced infarctions are rare (5, 9, 10); only a few such cases have been reported (1, 11–15). Even in patients with ICA occlusion, embolic strokes are far more common than low-flow infarctions (1, 16, 17). CT studies have been used to separate hemodynamic infarctions into two main groups: 1) terminal zone infarctions with a strictly subcortical involvement and

a location in either the paraventricular (corona radiata) or the supraventricular (centrum ovale) white matter (18, 19); and 2) watershed or borderzone infarctions with a predominantly cortical and nonterritorial extension (4, 6, 7).

In contrast, lacunar lesions are usually characterized as small defects with a round or ovoid shape and a diameter of less than 1.5 cm (2, 3, 20). Such infarctions have been significantly associated with hypertension or diabetes and are thought to be caused by disease in the small arteries. Their predominant locations are the territories of the deep perforating arteries, especially the basal ganglia, the thalamus, the internal capsule, and the brain stem. However, a review of four pathologic studies comprising 994 lacunae, found 10% to be located in the centrum ovale, which is served by long medullary penetrating branches of the superficial cerebral arteries (21). Therefore, in differentiating hemodynamic infarctions from microangiopathic lacunar lesions in the centrum ovale, previous CT and MR imaging studies have postulated a characteristic size of more than 2 cm for the diagnosis of hemodynamically caused ischemia (5, 22).

To assess the reliability of this criterion, we retrospectively analyzed centrum ovale lesions on MR images in patients with severe carotid artery disease who were known to have insufficient intracranial collater-

Received November 4, 1997; accepted after revision March 16, 1998.

From the Department of Neuroradiology, University of Tübingen (H.K., M.S.), and the Department of Neurology, University of Ulm (B.W.), Germany.

Address reprint requests to Dr. Hilmar Krapf, Department of Neuroradiology, University of Tübingen, Hoppe-Seyler-Str.3, D-72076 Tübingen, Germany.

alization. The latter can be evaluated by measuring the relative increase in cerebral blood flow (CBF) during stimulation of the intracerebral arterioles either by augmentation of the arterial pCO₂ (CO₂ test) or by intravenous administration of acetazolamide (Diamox test). The resulting cerebrovascular reserve capacity (CVR) gives quantitative information as to whether the intracerebral arterioles can dilate further. In the case of hemodynamic failure due to insufficient collateralization, the arterioles are already maximally dilated at normal blood pressure levels and cannot react to drops in blood pressure with further dilation.

Methods

During a 15-month period, we investigated the ipsilateral CVR of each patient with asymptomatic/symptomatic high-grade stenosis (>70% luminal reduction) or occlusions of the extra- or intracranial ICA by transcranial Doppler sonography of the middle cerebral artery (MCA) using different states of normo-, hyper-, and hypocapnia (Doppler CO₂ test). In most cases the findings of vascular disease were based on color-coded duplex sonography, which has proved to have a high accuracy in depicting the degree of stenosis (23) as well as in differentiating subtotal stenosis from occlusion (24). Only in a few unclear cases was the diagnosis confirmed by intraarterial digital subtraction angiography.

The technical details of the Doppler CO₂ test have been published previously (10, 25, 26). Briefly, patients were asked to hold their breath as long as possible. Afterward, they were requested to hyperventilate moderately. If the relative increase in MCA blood flow velocity during hypercapnia, and respective decrease during hypocapnia, reached at least 15% as compared with normocapnia, a relevant reduction in CVR was excluded. Patients with abnormal and/or ambiguous findings underwent an additional, more sophisticated test, including continuous monitoring of end expiratory CO₂ and administration of carbon dioxide gas (5% CO₂ in 95% O₂) to produce a more defined hypercapnic state. A relative increase of at least 10% in MCA blood flow velocity per vol% CO₂ was considered sufficient CVR, while increases of 3% to 9% were assumed to be diminished. Increases below this value and/or a decrease in flow during hypercapnia were thought to represent an exhausted CO₂ reactivity. A decrease in MCA flow on the occluded side even during CO₂ stimulation may be due to physiological lowering of vascular resistance on the contralateral normal hemisphere; therefore, the collateral flow toward the affected side, which is already weak during normocapnia, is further reduced. This is erroneously called "intracerebral steal effect."

Of 64 patients with at least a unilateral highly diminished or exhausted CVR, MR images were available for 16. In these 16 patients, each hemisphere was examined on a 0.5- or 1-T MR system, and images were obtained with the following parameters: T1-weighted (600/30 [TR/TE]) and T2-weighted (2500/40,90) double spin-echo sequences with 5-mm-thick axial sections, continuously or with a 1-mm intersection gap, and a 256 × 256 image matrix.

Five of the 16 patients had cortical territorial infarctions of the MCA of probable thromboembolic origin. In the remaining 11 patients, lesions in the centrum ovale could be detected in at least one hemisphere. The MR images of these 11 patients were included in the final analysis. The diameter of each lesion was measured quantitatively, and all lesions were transferred to standardized axial sections (Fig 1).

Results

The clinical data for the 11 patients (seven men and four women; 34 to 63 years old; mean age, 48 years)

are summarized in the Table. Seven patients had unilateral ICA occlusion, three patients had bilateral ICA occlusions, and one patient had bilateral high-grade stenosis of the siphon. Thus, severe disease was found in 15 ICAs. CO₂ testing revealed hemodynamic failure in each corresponding hemisphere (eight = CVR exhausted, seven = CVR highly diminished).

In eight of 15 hemispheres in the centrum ovale, multiple small lesions (three to 30 per hemisphere) with a diameter of less than 1.5 cm could be detected ipsilateral to a hemodynamic failure. In most cases, especially in patient 1 (Fig 2), there was a rosarylike distribution of the lesions, meaning that the small infarcts were strung together like beads. In two of the eight hemispheres, there was also involvement of the cortex with infarctions in the borderzone between the territories of the middle and anterior cerebral arteries. Transient ischemic attacks (TIAs) (n = 5) and/or minor strokes (n = 3) were the most common events in this group (see Table).

In three of the 15 hemispheres with hemodynamic failure, MR imaging revealed centrum ovale infarctions with a maximal extension of 7.0 cm (patient 6), 6.2 cm (patient 7), and 2.8 cm (patient 2) (Fig 1). In all three cases there was involvement of the peri- and supraventricular white matter. An additional cortical infarct was found in the frontal borderzone in patient 6.

Three of the 15 hemispheres had no ischemic lesion. In one hemisphere, a cortical (thromboembolic) MCA infarction was seen (patient 9, left side); this case was not excluded owing to the presence of bilateral ICA occlusions with multiple small infarcts in the contralateral right centrum ovale.

Ipsilateral to a mildly (n = 6) or moderately (n = 1) stenosed ICA, CO₂ reactivity and MR imaging findings were normal.

Discussion

With the use of MR imaging, we have found that a clear-cut distinction between hemodynamic infarctions and microangiopathic lacunar lesions in the centrum ovale is more complex than previously thought. In the present study, only three hemispheres had infarctions with a diameter of more than 2 cm, fulfilling the postulated criterion for a hemodynamic lesion (5, 22). However, we believe that although they had diameters of less than 1.5 cm, the small lesions of the centrum ovale in eight hemispheres may be categorized as hemodynamic infarctions for the following reasons:

- All infarctions (n = 8) were located in the centrum ovale ipsilateral to an occluded or highly stenosed ICA. Ipsilateral to a mild or moderate ICA stenosis (n = 7), the centrum ovale was quite normal in all cases.
- Concomitant cortical infarcts involved the frontal borderzone (n = 2).
- None of these patients had additional lesions in the typical lacunar regions of the brain.
- The ipsilateral CO₂ reactivity was highly diminished (n = 4) or exhausted (n = 4) in all patients with small centrum ovale infarcts, and previous studies have shown

a close correlation between a highly diminished CVR and the presence of low-flow infarctions (12, 13, 15, 27).

Characteristically, we found only multiple small supraventricular lesions, none was isolated. In most patients, the lesions affected the terminal zone in a sickle-shaped distribution. Similar CT findings have

been reported in several studies using methods other than the Doppler CO₂ test to evaluate cerebral hemodynamics.

In their analysis of the angiographic occlusion pattern of the extra- or intracranial arterial system in 30 patients with low-flow infarcts on CT scans, Mull et al

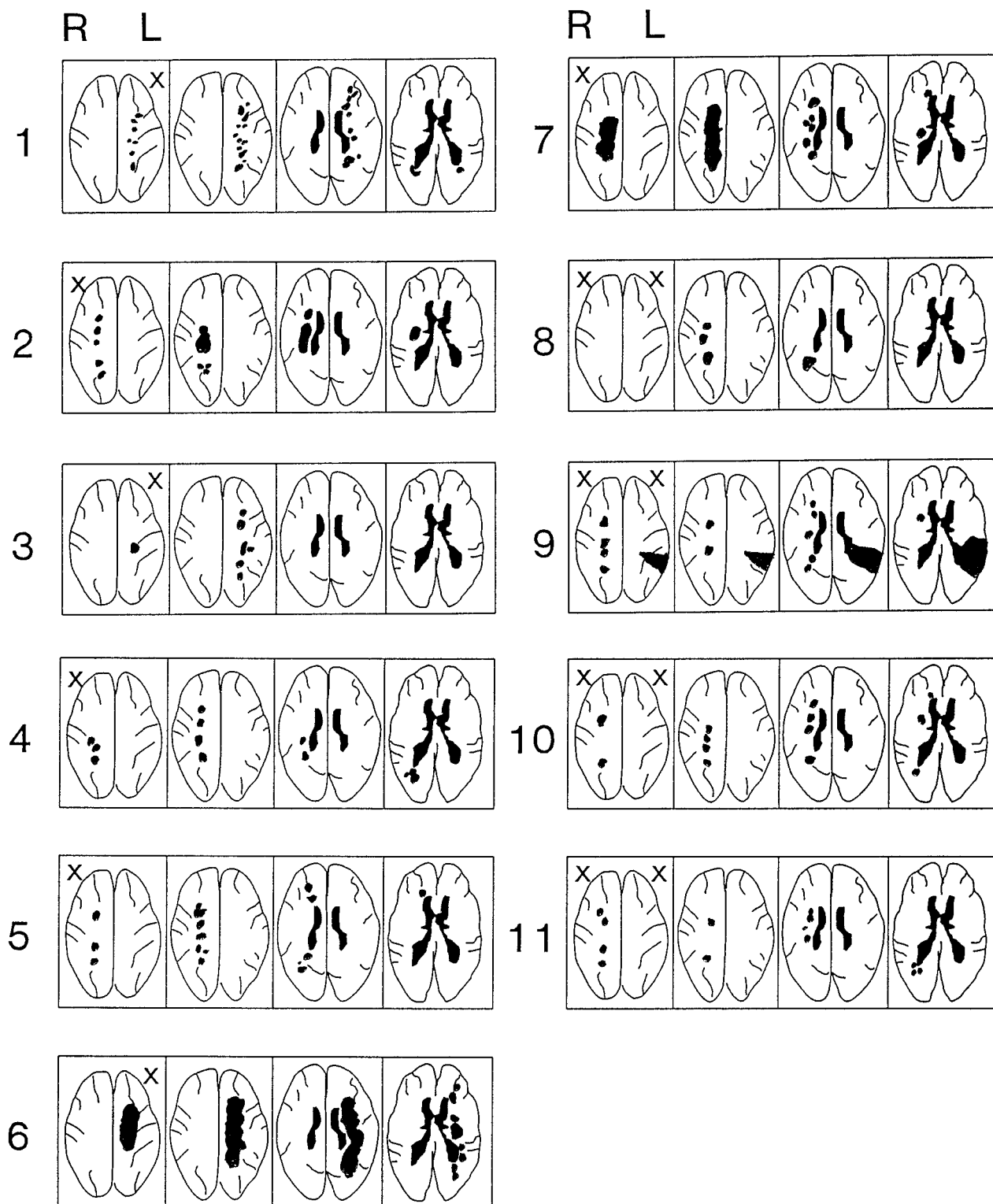


FIG 1. Synopsis of the MR findings in 11 patients with hemodynamic failure. R = right, L = left, X = hemodynamic failure.

(14) found a noncompetent circle of Willis in 29 of 30 cases. In their study, small chainlike lesions (<2 cm) were observed in 22 of 30 cases, whereas only eight of 30 patients in their study showed confluent infarctions of more than 2 cm. CVR was not investigated in every case, and MR images were available in only 14 of the 30 cases. Our results are in accordance with the study

of Dettmers et al (12), who used the xenon-133 method to determine the specific CO₂ reactivity in watershed and terminal supply infarctions. Bladin et al (11) also described large confluent lesions in only six of 18 patients with internal watershed infarctions. The other 12 patients had partial, small, nonconfluent lesions in the terminal zone on CT scans.

Synopsis of vascular and clinical findings in 11 patients with hemodynamic failure

Patient	Age, y/Sex	Percentage of ICA Stenosis/Occlusion	CO ₂ Reactivity	Corresponding Clinical Signs/Symptoms
1	55/F	100% L 40% R	Diminished	Recurrent TIA + minor stroke
2	50/F	100% R <30% L	Diminished	TIA, 2 episodes
3	34/F	100% L 0% R	Diminished	Hemicrania + TIA
4	42/M	100% R 0% L	Diminished	Dementia
5	41/M	100% R <30% L	Diminished	TIA
6	62/M	100% L <30% R	Exhausted	TIA + minor stroke
7	40/M	100% R <30% L	Exhausted	Major stroke
8	45/M	100% R 100% L	Exhausted Diminished	TIA + minor stroke None
9	63/M	100% R 100% L	Exhausted Diminished	TIA TIA + minor stroke (territorial infarct)
10	45/F	Bilateral high-grade siphon stenosis	Exhausted, R Exhausted, L	Minor stroke None
11	55/M	100% R 100% L	Exhausted Exhausted	None None

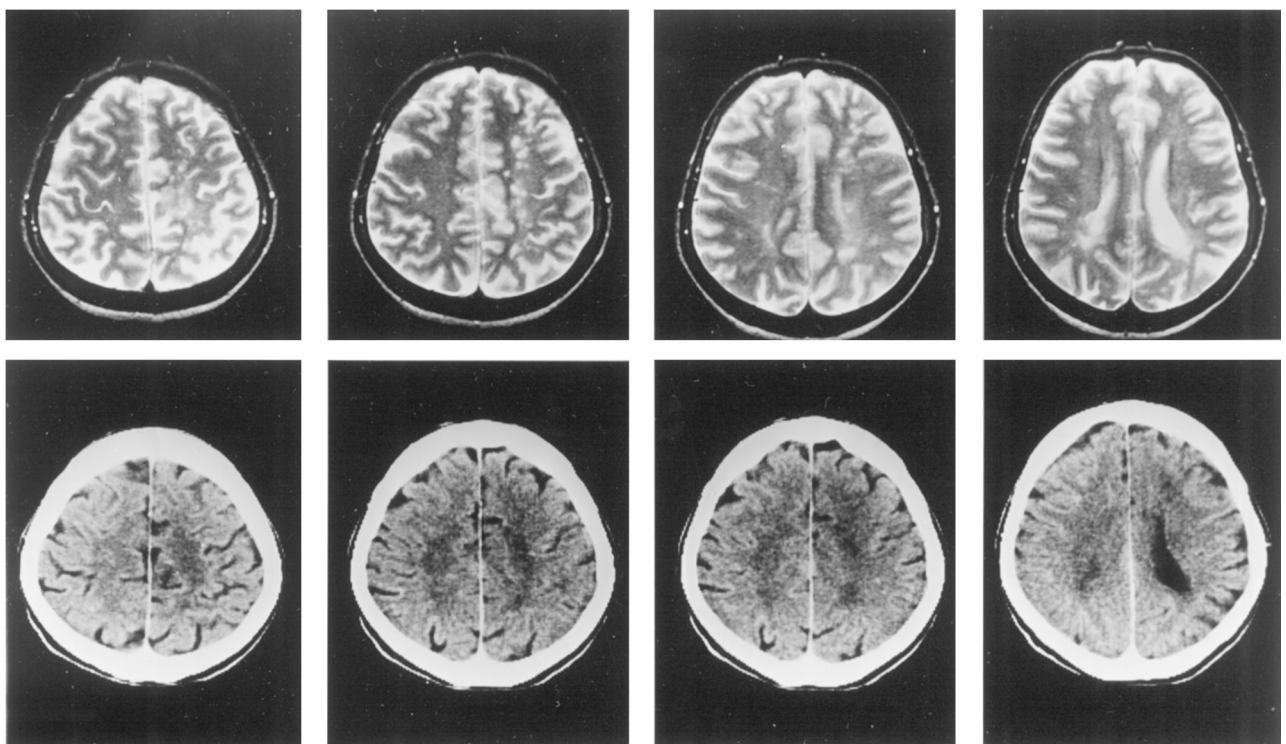


FIG 2. MR images (top row) and CT scans (bottom row) in patient 1.

Using positron emission tomography to study ICA occlusions, Yamauchi et al (15) found that in five patients with ICA occlusion, the presence of merging lesions (as seen on MR images) in the centrum ovale was associated with a decreased CBF and an elevated oxygen extraction fraction. A similar trend was found in our patients, indicating that there might be a correlation between the size of infarction and the degree of CVR impairment: in two of three patients with large hemodynamic lesions, the CO₂ reactivity was totally exhausted, with an intracerebral steal effect in case 7. Pathophysiologically, patients with an intracerebral steal effect seem to have the highest risk for hemodynamic stroke (28).

The small size of the lesions may be explained by the fact that in the case of an ICA occlusion the reduced blood flow may not have the same influence on the terminal medullary penetrating arteries of the superficial MCA branches. The territories of these arteries are not interdigitating and the vessels do not freely anastomose with one another nor with the deeper lenticulostriate perforators. Nevertheless, a continuous capillary network provides a weak collateral flow (29). Therefore, in some terminal arteries, the perfusion may still be sufficient, while in other territories the blood flow reaches critical values even during normal drops in blood pressure. From the pathophysiological point of view, the size of the lesions does not seem to be a reliable criterion for differentiating a hemodynamic from a microangiopathic origin. In the end, small and large centrum ovale infarcts may have similar pathogeneses, while small infarcts may result from slight, short drops in blood pressure in patients with impaired hemodynamics, large centrum ovale infarcts may be caused by a more acute and longer-lasting impairment of the cerebral perfusion. Therefore, small centrum ovale infarcts may be considered precursors to a more profound event (30).

The presence of small, *single* MR imaging lesions in the terminal zone has previously been documented by Bogousslavsky et al (18). In 26 of their 36 patients, however, they found no close correlation between the presence of single centrum ovale infarctions with a diameter of less than 1.5 cm and severe carotid artery disease. Hypertension and diabetes were thought to occur significantly more frequently in these patients than in the 10 patients with large centrum ovale infarctions (>1.5 cm). They therefore concluded that small, single infarctions in the centrum ovale should be related to microangiopathy. However, the statistical approach of the study has been the subject of some controversy (30). An analysis of the reported vascular sonographic findings shows that hemodynamic infarctions could not be excluded in five of the 26 patients with single, small infarcts: three patients had ipsilateral ICA occlusions and two others had high-grade stenoses.

In regard to the clinical findings in our study, seven of eight patients with small hemodynamic infarctions had a TIA or minor stroke, with mild neurologic deficits. In several cases the clinical symptoms could

not be distinguished from lacunar syndromes (2). Moreover, one patient (case 4) displayed diffuse neuropsychological symptoms, resulting in the initial and misleading diagnosis of dementia.

In the majority of cerebral ischemic events, CT may be sufficient to differentiate ischemic from hemorrhagic strokes and to depict thromboembolic ischemia. In six of our patients in whom both CT and MR imaging findings were available, however, CT scans failed to show the presence or the complete spread of small lesions in the centrum ovale. In patients with severe carotid artery disease, this may be a relevant restriction, since these infarctions may be considered persistent risks for a hemodynamic event. An increased stroke risk in patients with impaired cerebral hemodynamics has been established in several follow-up studies (26, 28, 31).

Conclusion

The MR imaging finding of multiple small sickle-shaped or rosarylike lesions involving the centrum ovale seems to be typical in patients with hemodynamic failure due to severe carotid artery disease.

References

1. Bogousslavsky J, Regli F. **Borderzone infarctions distal to internal carotid artery occlusion: prognostic implications.** *Ann Neurol* 1986; 20:346-350
2. Fisher CM. **Lacunar strokes and infarcts: a review.** *Neurology* 1982;32:871-876
3. Kappelle LJ, Ramos LM, van Gijn J. **The role of computed tomography in patients with lacunar stroke in the carotid territory.** *Neuroradiology* 1989;31:316-319
4. Ringelstein EB, Weiller C. **Hirnfarktmuster im Computertomogramm. Pathophysiologische Konzepte, Validierung und klinische Relevanz.** *Nervenarzt* 1990;61:462-471
5. Ringelstein EB, Zeumer H, Schneider R. **Der Beitrag der zerebralen Computertomographie zur Differentialtypologie und Differentialdiagnose des ischämischen Großhirninfarktes.** *Fortschr Neurol Psychiatry* 1985;53:315-336
6. Ringelstein EB, Zeumer H, Angelou D. **The pathogenesis of strokes from internal carotid artery occlusion: diagnostic and therapeutic implications.** *Stroke* 1983;14:867-875
7. Wodarz R. **Watershed infarctions and computed tomography: a topographical study in cases with stenosis or occlusion of the carotid artery.** *Neuroradiology* 1980;19:245-248
8. Zülch KJ. **Cerebrovascular pathology and pathogenesis as a basis of neuroradiological diagnosis.** In: Diethelm L, Wende S, eds. *Roentgen Diagnosis of the Central Nervous System.* New York: Springer; 1981:1-192
9. Levine RL, Lagreze HL, Dobkin JA, Turski PA. **Large subcortical hemispheric infarctions.** *Arch Neurol* 1988;45:1074-1077
10. Widder B, Kleiser B, Krapf H. **Course of cerebrovascular reactivity in patients with carotid artery occlusions.** *Stroke* 1994;25:1963-1967
11. Bladin CF, Chambers BR. **Clinical features, pathogenesis, and characteristics of internal watershed infarction.** *Stroke* 1993;24: 1925-1932
12. Dettmers C, Solymosi L, Hartmann A, Buermann J, Hagendorff A. **Confirmation of CT criteria to distinguish pathophysiologic subtypes of cerebral infarction.** *AJNR Am J Neuroradiol* 1997;18:335-342
13. Isaka Y, Nagano K, Narita M, Ashida K, Imaizumi M. **High signal intensity on T2-weighted magnetic resonance imaging and cerebral hemodynamic reserve in carotid occlusive disease.** *Stroke* 1997;28: 354-357
14. Mull M, Schwarz M, Thron A. **Cerebral hemispheric low-flow infarcts in arterial occlusive disease.** *Stroke* 1997;28:118-123
15. Yamauchi H, Fukuyama H, Yamaguchi S, Miyoshi M, Kimura J, Konishi J. **High-intensity area in the deep white mater indicating**

- hemodynamic compromise in internal carotid artery occlusive disorders. *Arch Neurol* 1991;48:1067-1071
16. Goto K, Fukasawa H, Takahashi S, Uemura K. **Internal carotid artery occlusion: computed tomographic, angiographic and pathological study.** *Neurol Med Chir (Tokyo)* 1982;22:547-462
 17. Krapf H, Kleiser B, Widder B. **Risk of thromboembolic and hemodynamic stroke in carotid artery occlusions.** *Klin Neuroradiol* 1997;7:205-211
 18. Bogousslavsky J, Regli F. **Centrum ovale infarcts: subcortical infarction in the superficial territory of the middle cerebral artery.** *Neurology* 1992;42:1992-1998
 19. Nakano S, Yokogami K, Ohta H, Goya T, Wakisaka S. **CT-defined large subcortical infarcts: correlation of location with site of cerebrovascular occlusive disease.** *AJNR Am J Neuroradiol* 1995;16:1581-1585
 20. Rothrock JF, Lyden PD, Hesselink JR, Brown JJ, Healy ME. **Brain magnetic resonance in the evaluation of lacunar stroke.** *Stroke* 1987;4:173-177
 21. Orgogozo JM, Bogousslavsky J. **Lacunar syndromes.** In: Toole JF, ed. *Vascular Diseases, II: Handbook of Clinical Neurology.* Amsterdam: Elsevier Science; 1989;54:235-269
 22. Bogousslavsky J. **Subcortical infarcts.** *Curr Rev Cerebrovasc Dis* 1993;1:31-40
 23. Görtler M, Widder B, Schuetz U. **Quantifying medium- and high-grade carotid artery stenosis by ultrasound.** *J Echogr Med Ultrasonogr (Paris)* 1996;17:235-239
 24. Görtler M, Niethammer R, Widder B. **Differentiating subtotal carotid artery stenoses from occlusions by colour-coded duplex sonography.** *J Neurol* 1994;241:301-305
 25. Widder B, Paulat K, Hackspacher J, Mayr E. **Transcranial Doppler CO₂-test for the detection of haemodynamically critical carotid artery stenoses and occlusions.** *Eur Arch Psychiatry Neurol Sci* 1986;236:162-168
 26. Kleiser B, Widder B. **Course of carotid artery occlusion with impaired cerebrovascular reactivity.** *Stroke* 1992;23:171-174
 27. Kleiser B, Krapf H, Widder B. **Carbon dioxide reactivity and patterns of cerebral infarction in patients with carotid artery occlusion.** *J Neurol* 1991;238:392-394
 28. Powers WJ. **Cerebral hemodynamics in ischemic cerebrovascular disease.** *Ann Neurol* 1991;25:231-240
 29. Moody DM, Bell MA, Challa VR. **Features of the cerebral vascular pattern that predict vulnerability to perfusion or oxygenation deficiency.** *AJNR Am J Neuroradiol* 1993;11:431-439
 30. Bladin CF. **Centrum ovale infarcts.** *Neurology* 1993;43:1625-1626
 31. Yonas H, Smith HA, Durham SIR, Pentheny SL, Johnson DW. **Increased stroke risk predicted by compromised cerebral blood flow reactivity.** *J Neurosurg* 1993;79:483-489