

# Abnormal Cerebral Activation Associated with a Motor Task in Tourette Syndrome

Bharat Biswal, John L. Ulmer, Robert L. Krippendorf, Harold H. Harsch, David L. Daniels, James S. Hyde, and Victor M. Haughton

**BACKGROUND AND PURPOSE:** In Gilles de la Tourette syndrome, PET scanning and EEG suggest an abnormal organization of the sensorimotor cortex and basal ganglia. The purpose of this study was to use functional MR imaging to study activation in the sensorimotor cortex in patients with Tourette syndrome.

**METHODS:** From echo-planar images acquired during intermittent performance of a finger-tapping task, the location of activated pixels was determined by means of conventional signal processing methods. In five patients with Tourette syndrome and five healthy volunteers, the number of activated pixels in the sensorimotor cortices and supplementary motor areas were counted. The area over which the activation was distributed was calculated.

**RESULTS:** In the five patients, the average number of pixels activated during the finger-tapping task in the sensorimotor cortices and supplementary motor area (69.4 pixels) exceeded that in the volunteers (49.2 pixels). The difference was significant. The area over which the pixels was distributed was significantly larger (25.4 vs 13.8 cm<sup>2</sup>).

**CONCLUSION:** Motor function is organized differently in patients with Tourette syndrome than in healthy subjects.

A biological basis for the syndrome described by Gilles de la Tourette has been inferred by many investigators, but the pathophysiology of the abnormality is not clearly understood (1). Positron emission tomography (PET) and EEG studies suggest that motor function is abnormally organized in patients with Tourette syndrome. With PET studies, significant tic-related brain activity in motor and language cortices in patients with Tourette syndrome was interpreted as evidence of abnormal organization of the motor cortex (2). EEG studies in patients with Tourette syndrome showed no negative EEG potentials usually detected before voluntary movement (3). To determine whether abnormal organization of motor functions could be detected with functional MR imaging in these patients, we studied the activation in the sensorimotor cortex from a standard motor task paradigm in comparison with healthy subjects.

## Methods

Subjects with a clinical diagnosis of Tourette syndrome were recruited from the psychiatry and medical psychiatry services and by contacting the Tourette's Association. Each subject completed a questionnaire regarding medical and social history and medications. Pertinent history and demographic information are presented in the Table. The following subjects were included: twins, aged 22 years, with Tourette syndrome and obsessive compulsive and attention deficit disorder symptoms; another sibling, aged 17 years; a 23-year-old man, working as a nurse, with a diagnosis of Tourette syndrome but no tics for the last 2 years; and one subject, aged 49 years, with mild Tourette syndrome and attention deficit disorder symptoms. Five healthy volunteers matched in age and sex were studied. None of the patients were on medication at the time of imaging. All were right-handed.

The functional MR images were obtained with a commercial 1.5-T imager equipped with a bird cage receiver and a three-axis gradient coil (4). A series of localizer images was obtained in axial, coronal, and sagittal planes. Anatomic reference images in the axial plane with a thickness of 1 cm were acquired with spin-echo sequences with imaging parameters of 600/20/2 (TR/TE/excitations), a 24-cm field of view, and a 128 × 256 matrix. For each anatomic image, a matched series of single-shot blipped echo-planar gradient images was acquired at intervals of 2 seconds. During the acquisition, three periods of task performance (each 20 seconds in length) were interspersed with four periods of rest. The functional images were acquired with imaging parameters of 2000/40, a 64 × 64 matrix, a 20-cm field of view, 1-cm-thick sections, and an acquisition time of 40 milliseconds (4). The time course of the signal intensity in each pixel was plotted and compared by a cross-correlation program to a reference function representing an idealized response to the task. The reference function was a modified square wave

Received November 4, 1997; accepted after revision April 6, 1998.

From the Departments of Biophysics (B.B., J.S.H.), Radiology (J.L.U., D.L.D., V.M.H.), Medicine (R.L.K.), and Psychiatry (H.H.H.), Medical College of Wisconsin, Milwaukee.

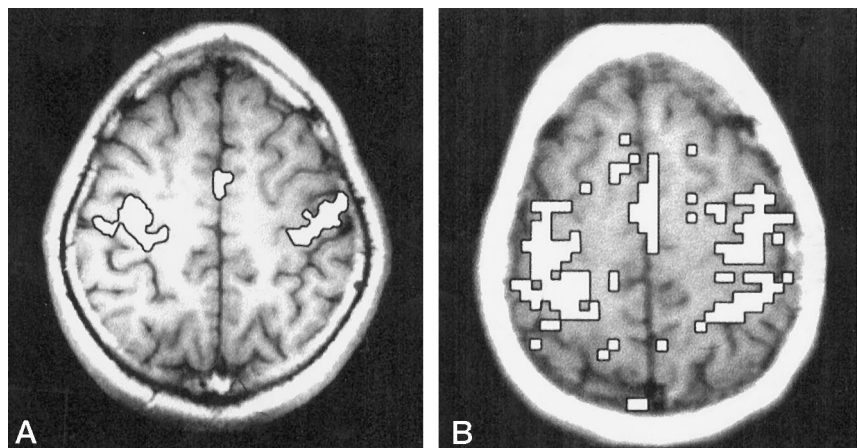
Address reprint requests to Victor M. Haughton, MD, Department of Radiology, Medical College of Wisconsin, Froedtert Memorial Lutheran Hospital, 9200 W Wisconsin Ave, Milwaukee, WI 53226.

## Number of activated pixels in patients with Tourette syndrome and in control subjects performing motor tasks

Subjects	Age (y)/Sex	No. of Activated Pixels				(L - R)/ (L + R)	SMA/ (SM Cortex)	Area of Activation (cm <sup>2</sup> )	Activated Pixels/ Unit Area
		L SM Cortex	R SM Cortex	SMA	Total				
Patient 1	22/M	31	36	9	76	-0.07	0.12	18.0	2.50
Patient 2	22/F	24	18	5	47	0.14	0.11	12.0	1.92
Patient 3	17/M	32	27	8	67	0.08	0.12	18.0	1.94
Patient 4	23/M	37	34	9	80	0.04	0.11	15.0	2.87
Patient 5	49/M	31	37	11	79	-0.09	0.14	18.0	2.67
Average		31.0	30.4	8.4	69.8	0.02	0.12	16.2	2.40
Control 1	22/M	21	18	5	44	0.08	0.11	8.0	2.88
Control 2	24/F	26	24	6	56	0.04	0.11	12.0	2.50
Control 3	25/M	21	19	4	44	0.05	0.09	6.0	3.83
Control 4	24/M	18	24	7	49	-0.14	0.14	12.0	2.58
Control 5	56/M	22	27	4	53	-0.10	0.08	6.0	5.17
Average		21.6	22.4	5.2	49.2	-0.02	0.11	8.8	3.14

Note.—L indicates left; R, right; SM, sensorimotor; SMA, supplementary motor area.

FIG 1. A and B, Functional MR images show pixels activated by a finger-tapping motor task in a healthy subject (A) and in a patient with Tourette syndrome (B). Thresholds for the two images are the same (0.3). The images are black and white versions of functional images in which activation is indicated by a color scale. The black border around regions of activation has been added by a computer program to improve the reproduction of activated pixels in black and white.



with a period of 40 seconds and the first 4 seconds of the time course of each rest and task period excluded in the cocorrelation calculation. Pixels passing a threshold of 0.35 (for an a priori significance of  $P < .0001$ ) were displayed as activated pixels. The activated pixels in the functional images were then overlaid on the exactly corresponding anatomic reference images by the image-processing program (4). The task used for each patient was a bilateral finger-thumb exercise (5), which consisted of repeated, self-paced, rapid (2 Hz or greater), rhythmic bilateral appositions of the thumb and first finger in response to a cue from the investigator.

For each study, the activated pixels in the sensorimotor cortex region (the lateral aspect of the hemisphere ventral and dorsal to the superior genu of the central sulcus) and the supplementary motor cortex area (the medial aspect of the hemisphere in the vicinity of the anterior cingulate gyrus) were tabulated. Standard methods of parcellation were used to define the central sulcus (6). The differences in the number of activated pixels between the groups was tested for significance by the two-tailed Student's *t*-test of means.

The area covered by the activation in the sensorimotor cortex was estimated. One investigator, using software in the imager's console, fit an ellipse to the activation in the right or left sensorimotor cortices to include all activated pixels while minimizing the area of the ellipse. The area of the ellipse was calculated from the major and minor axes.

## Results

Technically adequate data sets were obtained for all five patients and five volunteers. Activation from the motor task was identified consistently in the sensorimotor cortex region and in the supplementary motor area in both patients and volunteers (see Figure). The regions activated in the patients with Tourette syndrome and in the volunteers were similar; however, in the patients, the number and the dispersion of the activated pixels were greater (see Table). The number of activated pixels in the left or right motor cortex regions in the patients ranged from 18 to 37 (average, 30.7 pixels per region), whereas for the control group it ranged from 18 to 27 (average, 22.0 pixels per region). The difference between the patients and the control subjects was significant ( $P < .01$ ). The number of activated pixels in the supplementary motor area was between five and 11 in the patients (average, 8.4 pixels) and between four and seven for the control group (average, 5.2 pixels). The difference was significant ( $P = .02$ ). The ratio of activated pixels in the supplementary motor area to activated pixels in the sensorimotor cortex was 0.12

for the patients and 0.11 for the control group. This difference was not significant.

The area of activation for the sensorimotor cortex region was visibly larger in the patients than in the control subjects. The average area over which the activation was distributed was 16.2 cm<sup>2</sup> for the patients and 8.8 cm<sup>2</sup> for the control group. The difference was significant ( $P = .006$ ). The number of activated pixels per unit area was slightly smaller for the patients (2.4 pixels) than for the control group (3.1 pixels). The difference was not significant ( $P = .10$ ).

### Discussion

Tourette syndrome is a complex neurologic syndrome characterized generally by motor and focal tics and, less consistently, by attention deficit disorder, obsessive compulsive disorder, dyslexia, depression, and other neurologic or psychiatric manifestations. The most conspicuous features of the syndrome are coprolalia, echolalia, and pilialia. Tourette syndrome is genetically determined, apparently by autosomal dominance and incomplete penetrance (7–10). The tics in Tourette syndrome, unlike tics in other disorders, seem more compulsive than involuntary (9). For some interval of time, the tics can be suppressed. Even when the tics are not suppressed, they seldom result in injuries to the patient or to others, suggesting some voluntary control at all times. The genetic marker has not been determined, although approximately 80% of the genome has been excluded. The frequency of the disorder is determined at 0.5 per 1000 live births or as high as 1% of boys in grade school monitored closely for evidence of symptoms (7). The pathophysiology of Tourette syndrome is not known, although disordered dopamine function has been postulated (1, 11–13).

The findings of our functional MR imaging study show a significantly greater number and dispersion of pixels activated by finger tapping in patients with Tourette syndrome than in control subjects. The activated pixels are distributed over a larger region of the brain, so that the proportion of activated pixels in the left sensorimotor region, the right sensorimotor region, and the supplementary motor area is similar in the patients and in the control subjects.

Our preliminary study has limitations. The results were obtained in a small and diverse group of patients with Tourette syndrome. Duration of disease, age, and comorbid conditions were not controlled in order to collect sufficient data to compare with control subjects. In future studies, results in patients with Tourette syndrome should be stratified by severity of attention deficit and obsessive compulsive disorder (11). The study produced statistically significant results despite the diversity of the subjects and the small number. The least abnormal pattern was found in the patient with the fewest symptoms of Tourette syndrome.

Although this is, to our knowledge, the first functional MR imaging study of cerebral activation in Tourette syndrome, it confirms the findings of other

studies that suggest an abnormal organization of motor functions in the sensorimotor cortex in these patients. PET imaging studies of the tic activity in patients with Tourette syndrome reveal abnormalities localized to the sensorimotor cortex and supplementary motor areas (2). The results of our functional MR imaging study show abnormal activation also in the supplementary motor area, as have some EEG (3) and clinical (15) studies. The beneficial effect of anterior cingulotomy for Tourette syndrome also suggests a role of the supplementary motor area, at least in patients with obsessive compulsive symptoms (16–18). Although functional studies have identified abnormalities, anatomic studies, in general, have not. Results of postmortem examinations (19–21) do not show abnormalities in the sensorimotor or supplementary motor areas. Findings of microscopic and histochemical studies show abnormalities in the globus pallidus in patients with Tourette syndrome (19, 20). Volumetric studies with MR imaging have identified diminished basal ganglia volume in these patients (8). In future functional MR imaging studies of Tourette syndrome, basal ganglia activation should be tabulated.

The abnormal activation pattern in Tourette syndrome requires further investigation. One possible explanation for the increased activation is that these patients use more cerebral cortex to perform a motor task because additional work is required to suppress tic activity. If such suppression occurs, it must be temporally correlated with the performance of the task in order to appear as activation. Another possibility is that larger portions of the sensorimotor cortex and supplementary motor areas participate in the execution of motor tasks. This possibility is supported by other functional MR imaging studies of functional connectivity in Tourette syndrome (22). Other considerations unsupported by experimental evidence include the possibility that the motor regions receive less inhibitory output from frontal cortices or that venous drainage or blood flow linkage to neuronal activity are anomalous in this disorder.

### Conclusion

Functional MR imaging results show abnormal activation in the sensorimotor cortex and supplementary motor areas of patients with Tourette syndrome. The pathophysiology of this disorder can be explored safely and effectively with functional MR imaging. Further studies are indicated to determine the extent of functional abnormalities and the effect of comorbid features of Tourette syndrome on activation.

### References

1. Robertson MM. **D<sub>2</sub> be or not to be: neuroimaging of monozygotic twins with Tourette syndrome suggests that increased binding by dopamine D<sub>2</sub> receptors contributes to the disease phenotype (News and Views).** *Nature Medicine* 1996;2:1076–1077
2. Stern E, Silbersweig DA, Chee K-Y, Frith CD, Frackowiak RSJ, Dolan RJ. **Functional neuroanatomy of involuntary action in Tourette's syndrome (abstract).** *Book of Abstracts*. New York: Society of Magnetic Resonance in Medicine, 1996

3. Obeso JA, Rothwell JC, Marsden CD. **Simple tics in Gilles de la Tourette's syndrome are not prefaced by a normal premovement EEG potential.** *J Neurol Neurosurg Psychiatry* 1981;44:735-738
4. Bandettini PA, Jesmanowicz A, Wong EC, Hyde JS. **Processing strategies for time-course data sets in functional MRI of the human brain.** *Magn Reson Med* 1993;30:161-173
5. Yetkin Z, McAuliffe TL, Cox R, Haughton VM. **Test-retest precision of functional MR in sensory and motor task activation.** *AJNR Am J Neuroradiol* 1996;17:579-584
6. Sobel DF, Gallen CC, Schwartz BJ, et al. **Locating the central sulcus: comparison of MR anatomic and magnetoencephalographic methods.** *AJNR Am J Neuroradiol* 1993;14:915-925
7. Cummings DE. **Tourette Syndrome and Human Behavior.** Duarte, CA: Hope Press; 1990:5-20
8. Robertson MM. **The Gilles de la Tourette syndrome: the current status.** *Br J Psychiatry* 1989;154:147-169
9. Miguel EC, Coffey BJ, Baer L, Savage CR, Rausch SL, Jemike MA. **Phenomenology of intentional repetitive behaviors in obsessive compulsive disorder and Tourette's syndrome.** *J Clin Psychiatry* 1995;56:246-255
10. Pauls DL, Leckman JF. **The inheritance of Gilles de la Tourette's syndrome and associated behaviors.** *N Engl J Med* 1986;126:148-152
11. Butler IJ, Koslow SH, Seifert WE Jr, Caprioli RM, Singer HS. **Biogenic amine metabolism in Tourette syndrome.** *Ann Neurol* 1979;6:37-39
12. Cohen DJ, Shaywitz BA, Young JG, et al. **Central biogenic amine metabolism in children with the syndrome of chronic multiple tics of Gilles de la Tourette: norepinephrine, serotonin and dopamine.** *J Am Acad Child Psychiatry* 1979;18:320-341
13. Singer HS, Butler IJ, Tune LE, Seifert WE Jr, Coyle JT. **Dopaminergic dysfunction in Tourette syndrome.** *Ann Neurol* 1982;12:361-366
14. Leckman JF, Ridder MA, Harding MT, et al. **The Yale global tic severity scale: initial testing of a clinician-related scale of tic severity.** *J Am Acad Child Psychiatry* 1989;28:566-573
15. Nee LE, Caine ED, Polinsky RJ, Eldridge R, Ebert MH. **Gilles de la Tourette syndrome: clinical and family study in 50 cases.** *Ann Neurol* 1980;7:41-49
16. Baker EFW. **Gilles de la Tourette syndrome treated by bimedial frontal leucotomy.** *Can Med Assoc J* 1962;86:746-747
17. Kurlan R, Behr J, Medved L, Como P. **Transient disorder and the spectrum of Tourette's syndrome.** *Arch Neurol* 1988;45:1200-1201
18. Robertson M, Doran M, Trimble M, Lees AJ. **The treatment of Gilles de la Tourette by limbic leucotomy.** *J Neurol Neurosurg Psychiatry* 1990;53:691-694
19. Balthaser K. **Über das anatomische substrat der generalisiernten tic-krankheit (maladie des tics, Gilles de la Tourette): Entwicklungshemmung des corpus striatum.** *Arch Psychiatr Berl* 1957;195: 531-549
20. Haber SN, Kowall NW, Vonsattel JP, Bird ED, Richardson EP Jr. **Gilles de la Tourette syndrome: a post mortem pathological and immunohistochemical study.** *J Neurol Sci* 1986;75:224-241
21. Devinsky O. **Neuroanatomy of Gilles de la Tourette's syndrome: possible midbrain involvement.** *Arch Neurol* 1983;40:508-514
22. Biswal B, Yetkin FZ, Haughton VM, Hyde JS. **Functional connectivity in the motor cortex in patients with Tourette's syndrome (abstract).** *Book of Abstracts.* New York: Society of Magnetic Resonance in Medicine, 1996