

# Hemodynamic Effects of Middle Cerebral Artery Stenosis and Occlusion

Colin P. Derdeyn, William J. Powers, and Robert L. Grubb Jr

**BACKGROUND AND PURPOSE:** Middle cerebral artery (MCA) stenosis and occlusion may cause ischemic symptoms through both hemodynamic and embolic mechanisms. The purpose of this investigation was to determine the hemodynamic effects of these lesions.

**METHODS:** Ten patients with angiographically confirmed symptomatic occlusion (n = 5) or stenosis (n = 5) of the M1 segment of the MCA were studied by clinical examination, arteriography, and positron emission tomography (PET). Arterial supply to the distal MCA territory was classified from a review of the angiogram as being through the stenosis or from pial collaterals from anterior or posterior cerebral arteries. Regional measurements of cerebral blood flow, cerebral blood volume, cerebral rate of oxygen metabolism, oxygen extraction fraction, and ratio of cerebral blood volume/cerebral blood flow (mean vascular transit time, MTT) were obtained using PET. Hemodynamic status was categorized from PET scans as stage 0, normal hemodynamics; stage 1, autoregulatory vasodilatation (increased MTT); or stage 2, increased oxygen extraction fraction.

**RESULTS:** Of five patients with MCA occlusion, three had autoregulatory vasodilatation (stage 1) and two had increased oxygen extraction fraction distal to the lesion (stage 2). The MCA territory was supplied solely by pial collaterals in all five patients. Four of the five patients with focal MCA stenosis had normal hemodynamics (stage 0). One patient had stage 1 hemodynamic status. Blood flow to the MCA territory was through the stenosis in all patients; no pial collaterals were identified.

**CONCLUSION:** The frequency of hemodynamic compromise in patients with MCA occlusion is high. Pial collateralization is not a specific sign of increased oxygen extraction fraction in patients with MCA occlusion.

Early experience with intracranial transluminal angioplasty has shown beneficial effects in preventing further symptoms of ischemia and stroke in selected patients (1-3). However, the underlying pathogenesis of ischemic symptoms in patients with intracranial

stenosis or occlusion is not well defined. Both hemodynamic (4, 5) and embolic (6, 7) mechanisms may be involved.

The hemodynamic effect of an occlusive lesion on the distal circulation depends on both the degree of stenosis and the adequacy of the collateral circulation. These effects have been categorized into three stages (8, 9). Occlusive lesions often have no effect on the distal circulation, owing to good collateral circulation (stage 0, normal cerebral hemodynamics). For example, 10% to 60% of patients with complete occlusion of the internal carotid artery (ICA) have normal distal cerebral hemodynamics (10-15). When collaterals are not adequate, however, the perfusion pressure distal to the lesion will begin to fall. Decreases in perfusion pressure produce reflex vasodilatation in order to maintain normal blood flow (stage 1). This response, as well as the reflex vasoconstriction observed with increased perfusion pressure, is known as autoregulation. The presence of autoregulatory vasodilatation in humans can be detected by using two basic strategies (9). The first involves measurements of cerebral blood flow (CBF) or blood

Received October 28, 1997; accepted after revision February 25, 1998.

Supported in part by NIH NINDS grants NS28947 (R.L.G., W.J.P.) and NS06833 (W.J.P.); and by a Radiological Society of North America/Siemens Medical Systems Research Fellowship (C.P.D.).

Presented in part at the joint meeting of the American Society of Interventional and Therapeutic Neuroradiology and at the joint section on Cerebrovascular Surgery of the Congress of Neurological Surgeons and the American Association of Neurological Surgeons, Orlando, February 1998.

From the Mallinckrodt Institute of Radiology (C.P.D., W.J.P., R.L.G.), the Department of Neurology and Neurological Surgery (W.J.P., R.L.G.), and the Lillian Strauss Institute of the Jewish Hospital of St Louis (W.J.P.), Washington University School of Medicine, St Louis.

Address reprint requests to Colin P. Derdeyn, MD, Mallinckrodt Institute of Radiology, Washington University Medical Center, 510 S Kingshighway Blvd, St Louis, MO 63110.

velocity at rest and after a vasodilatory stimulus. An absent or diminished response indicates autoregulatory vasodilatation. The second method relies on quantitative measurements of resting CBF and cerebral blood volume (CBV). CBV increases with autoregulatory vasodilatation and the CBV/CBF ratio (the mean vascular transit time [MTT] of red cells) also increases.

When autoregulatory vasodilatation is not adequate to maintain normal CBF, CBF begins to fall. In this situation, the brain can increase the amount of oxygen it extracts from the blood (oxygen extraction fraction [OEF]) to maintain normal cerebral oxygen metabolism (CMRO<sub>2</sub>) (9). This stage (stage 2) of hemodynamic compromise has been termed "misery perfusion" (16). At present, the measurement of OEF is possible only with positron emission tomography (PET).

A better understanding of the hemodynamic consequences of intracranial stenosis and occlusion may help provide a more rational basis for treatment decisions or future clinical trials. We undertook this review of PET examinations of patients with middle cerebral artery (MCA) stenosis and occlusion in order to evaluate the hemodynamic consequences of these lesions.

## Methods

### Subjects

We selected from our laboratory records all PET studies of regional cerebral blood flow (rCBF), regional cerebral blood volume (rCBV), regional cerebral rate of oxygen metabolism (rCMRO<sub>2</sub>), and regional oxygen extraction fraction (rOEF) obtained in patients with either MCA stenosis or occlusion. All patients had acute or chronic ischemic symptoms and were being examined for possible extracranial-intracranial (EC/IC) bypass. All patients had arteriographic evidence of MCA stenosis or occlusion. PET studies performed after EC/IC bypass were excluded. PET studies in two patients could not be quantitatively processed for technical reasons. A study in one patient with multiple sites of intracranial stenosis subsequent to external-beam radiation therapy of the pituitary region was excluded. This left 11 PET studies obtained in 10 patients between 1981 and 1986. All patients had at least one cerebral angiogram prior to the PET examination. Presenting symptoms and neurologic findings at the time of the PET scan were recorded.

PET studies were also performed in 17 healthy volunteers aged 18 to 30 years. The volunteers were recruited by public advertisement, and none had a history or evidence of neurologic disease. Informed written consent was obtained from each subject before the PET measurements. All protocols were approved by the Human Studies Committee and the Radioactive Drug Research Committee of Washington University School of Medicine.

### Arteriograms

All arteriograms were reviewed by an investigator before the PET study. All studies were carotid only or carotid and vertebral selective cut-film arteriograms, obtained in two or more planes of view. Stenoses were measured as a percentage of narrowing relative to the normal distal lumen. The location of occlusion or stenosis was assigned by using conventional arteriographic terminology: M1, sphenoidal segment (from the origin to the sylvian fissure); M2, insular segment; M3, oper-

cular segment; and M4, cortical segment. Supply to the distal MCA territory was categorized as being through the stenosis or from pial collaterals from anterior and posterior cerebral arteries.

### PET Studies

Regional measurements of CBF, CBV, and OEF were performed on a PETT VI tomograph in the low-resolution mode with a reconstructed transverse resolution of 18 mm full width at half-maximum intensity (17). This tomograph collects seven parallel sections 1.4 cm apart (14-mm section thickness). After the patient was positioned on the scanner gantry, an individually molded thermoplastic face mask was applied to ensure that the head remained in a constant position during the scanning period. The exact position of the patient's head relative to the scanning plane was recorded on a lateral skull film obtained after head immobilization. Venous and arterial catheters were placed for intravenous radiotracer administration and for arterial blood gas analyses and arterial time-activity curve determination, respectively (18).

A transmission scan was obtained before radiotracer administration using a germanium-68/gallium-68 ring source. The skull film and attenuation data from this scan were used to define the limits of the calvaria for quantitative processing of PET data. Each PET study consisted of three separate physiological studies. During each, arterial blood samples were drawn by hand in order to convert quantitative regional radioactivity data to quantitative physiological measurements. CBF was measured using a bolus intravenous injection of oxygen-15-labeled water (18, 19). CBV was measured by inhalation of air containing trace amounts of carbon monoxide labeled with oxygen-15 (20). After the patient took one or two breaths of the oxygen-15-labeled air, OEF was measured in combination with data from the CBV and CBF measurements (21). The PET scans were converted to quantitative measurements of these parameters on a voxel-by-voxel basis. CMRO<sub>2</sub> was calculated as the product of OEF, CBF, and arterial oxygen content (21). The entire PET examination could be performed within 1 hour because of the short half-life (123 seconds) of oxygen-15. All radionuclides were produced in the cyclotron facility of our institution (22).

### Data Analysis

For each physiological PET study, seven 1.43 × 1.43-cm regions of interest were placed in the cortical territory of the MCA in each hemisphere using stereotactic coordinates (23, 24). Areas of prior infarction were identified by review of CMRO<sub>2</sub> images as well as CT scans. CT studies were obtained in all patients. Neither the regions within these infarcted areas nor the corresponding contralateral regions were used for analysis. The mean vascular transit time (MTT) was calculated as the CBV/CBF ratio for each of the seven regions of interest. The mean hemispheric values of CBF, CBV, CMRO<sub>2</sub>, OEF, and CBV/CBF ratio were then calculated.

The hemodynamic status of the cerebral circulation in the hemisphere ipsilateral to the symptomatic MCA lesion was determined on the basis of the CBV/CBF ratio and the rOEF, as described previously (8). Ratios outside the normal range obtained from the 17 healthy subjects were considered to be abnormal (8). Hemodynamic status was classified into three stages according to the PET data. Stage 0 (normal): normal CBV/CBF and OEF ratios; stage 1 (autoregulatory vasodilatation, normal flow): increased CBV/CBF ratio, normal OEF ratio; and stage 2 (reduced flow): increased CBV/CBF and OEF ratios (8).

## Results

The range of left-to-right hemispheric ratios for the 17 healthy subjects were as follows: CBF, 0.902 to

TABLE 1: Middle cerebral artery stenosis

Patient No.	Age, y/ Sex	Symptoms	Time of Most Recent Symptom Relative to PET, days	Degree of M1 Stenosis at Angiography, %	Time Relative to PET, days	Associated Lesions	MCA Supply	Time to Repeat Angiography	CT Findings	Time Relative to PET, days	Hemodynamic Stage
1	60/F	TIA	-3	50L	-2	40% L ICA stenosis	M1	-2 wk/NC	Normal	-14,0	0
4	82/M	TIA	-92	50R	-91	Diffuse mild intracranial stenoses	M1	None	Normal	-91	0
5	52/M	TIA	-4	83L	-2	None	M1	+2 wk/NC	Normal	-2	1
6	64/F	CI	-29	80R	-27	40% R ICA stenosis	M1	None	Lacunar infarction	-37, +11	0
7	37/M	CI	-15	70L	-1	None	M1	-1 mo, 20% L M1	Normal	-12	0

Note.—ICA, internal carotid artery; NC, no change; TIA, transient ischemic attack; CI, cerebral infarction.

TABLE 2: Middle cerebral artery occlusion

Patient No.	Age, y/ Sex	Symptoms	Time of Most Recent Symptom Relative to PET, days	Time of Arteriography Relative to PET, days	Associated Lesions	MCA Supply	Repeat Angiography	CT Findings	Time Relative to PET, days	Hemodynamic Stage
2	49/F	TIA	-2	0	None	ACA (pial)	+2 mo/NC	Normal	-19, -6	1
3	35/M	CI	-16	-9	Mild proximal MCA stenosis	ACA/PCA (pial)	+2 wk/NC	Parietal/occipital	-14	2
8	59/M	CI	-57	-1	None	ACA/PCA (pial)	+1 mo/NC	Putamen/internal capsule	-2, +27	1
	Repeat		-92	-35					-35	2
9	51/F	CI	-270	-270	25% opposite CCA	ACA/PCA (pial)	None	Putamen and posterior temporal	-15	1
10	44/M	CI	-3	0	None	ACA (pial)	None	Central sulcus	-3, -2	1

Note.—CCA, common carotid artery; ACA, anterior cerebral artery; PCA, posterior cerebral artery; NC, no change; TIA, transient ischemic attack; CI, cerebral infarction.

TABLE 3: Average hemispheric values and ratios of CBF, CBV, MTT, CMRO<sub>2</sub>, and OEF

	Patient No.										
	1 Left Stenosis	4 Right Stenosis	5 Left Stenosis	6 Right Stenosis	7 Left Stenosis	2 Left Occlusion	3 Right Occlusion	8 Right Occlusion	2nd Scan	9 Left Occlusion	10 Right Occlusion
CBF											
Avg L	38.115	22.212	42.411	32.365	39.36	28.147	54.54	37.23	35.3	33.16	36.36
Avg R	38.274	23.82	48.578	35.49	37.33	35.689	45.455	29.24	25.26	37.47	28.57
L/R ratio	0.996	0.933	<b>0.873</b>	0.912	1.054	<b>0.789</b>	<b>1.2</b>	<b>1.274</b>	<b>1.393</b>	<b>0.898</b>	<b>1.272</b>
CBV											
Avg L	5.712	3.84	5.286	5.596	4.012	2.731	4.153	2.595	3.362	4.42	2.71
Avg R	5.709	3.83	4.167	5.737	3.759	2.607	4.101	2.992	3.498	3.49	2.87
L/R ratio	1.001	1.003	<b>1.269</b>	1.038	1.067	1.047	1.013	<b>0.868</b>	0.961	<b>1.268</b>	0.945
MTT											
Avg L	9.187	10.373	7.548	11.315	6.225	5.921	4.638	4.595	5.876	8.05	4.54
Avg R	9.099	9.647	5.087	9.897	6.16	4.417	5.587	2.992	8.511	5.54	6.36
L/R ratio	1.01	1.0789	<b>1.484</b>	1.143	1.011	<b>1.341</b>	<b>0.83</b>	<b>0.683</b>	<b>0.69</b>	<b>1.452</b>	<b>0.713</b>
CMRO <sub>2</sub>											
Avg L	2.187	1.95	2.267	2.026	1.406	1.991	2.912	2.237	2.599	2.23	2.57
Avg R	2.328	2.13	3.103	2.319	1.502	2.407	2.795	1.823	2.171	2.3	2.01
L/R ratio	0.939	0.915	<b>0.732</b>	0.874	0.936	<b>0.827</b>	1.042	<b>1.227</b>	<b>1.197</b>	0.968	<b>1.278</b>
OEF											
Avg L	0.32	0.516	0.313	0.387	0.283	0.32	0.303	0.304	0.405	3.78	0.429
Avg R	0.34	0.526	0.322	0.406	0.322	0.34	0.352	0.317	0.472	3.53	0.432
L/R ratio	0.94	0.981	0.969	0.953	0.877	0.94	<b>0.864</b>	0.959	<b>0.858</b>	1.069	0.994
Stage	0	0	1	0	0	1	2	1	2	1	1

Note—Bold indicates values beyond the range observed in the normal population. CBF is expressed in milliliters per 100 g tissue per minute. CBV is expressed in milliliters per 100 g tissue. The unit for mean transit time (MTT) is seconds. CMRO<sub>2</sub> is expressed as milliliters per O<sub>2</sub> per 100 g tissue per minute. Oxygen extraction fraction (OEF) is unitless.

1.057; CBV, 0.913 to 1.150; MTT, 0.871 to 1.175; CMRO<sub>2</sub>, 0.875 to 1.080; and OEF, 0.909 to 1.097.

The clinical, angiographic, and CT characteristics and the hemodynamic stage for each patient are given in Tables 1 and 2. All patients had either stenosis (n = 5, Table 1) or occlusion (n = 5, Table 2) of the M1 segment of the symptomatic MCA. No significant proximal ICA stenosis was observed in either group. The pattern of flow to the MCA territory beyond the lesion was through the stenosis in all patients with stenoses. Pial collaterals from the anterior cerebral artery or both the anterior and posterior cerebral arteries supplied the cortical territory of the MCA in all patients with occlusion. Repeat arteriography was obtained in three of the five patients with stenosis. The stenotic lesion remained stable in two patients and regressed from 70% to 20% in the third. Three patients with MCA occlusion underwent repeat arteriography. No evidence of interval recanalization was observed. The intervals between each patient's most recent symptom, cerebral arteriogram, CT scan, and PET scan are given in Tables 1 and 2.

The hemispheric mean values and left-to-right ratios of CBF, CBV, MTT, CMRO<sub>2</sub>, and OEF for each patient are shown in Table 3. Only one of the five patients with symptomatic M1 stenosis had PET evidence of hemodynamic compromise (Fig 1). None of the patients with MCA occlusion had normal cerebral hemodynamics. The CBV/CBF ratio was elevated in three patients with normal CBF and OEF (hemodynamic stage 1). Ipsilateral OEF and CBV/CBF ratios

were elevated beyond the normal range in the remaining two patients (hemodynamic stage 2).

## Discussion

These data raise several important points. First, they show that the presence of occlusion in the MCA is frequently associated with hemodynamic impairment of the distal cerebral circulation. Stage 1 or 2 hemodynamic compromise was observed in the distal MCA territory in all six PET studies of the five patients with MCA occlusion. This is not the case for extracranial atherosclerotic carotid stenosis and occlusion. The availability of circle of Willis and external carotid to internal carotid collaterals often provides normal perfusion pressure distal to an occluded or stenotic ICA. Only pial or meningeal to pial collaterals are available in patients with MCA occlusion, however; and the present data indicate that pial collaterals are not adequate to maintain normal cerebral hemodynamics.

Second, the presence of pial collateralization may not be associated solely with stage 2 hemodynamic compromise. In a study by Powers et al (8) of 19 patients with extracranial carotid stenosis or occlusion, pial collaterals were observed only with increased OEF in the MCA territory (hemodynamic stage 2). In the present study, stage 2 hemodynamic compromise was seen on two of six PET examinations in five patients with MCA occlusion. The remaining four studies revealed only increased MTT ratios and

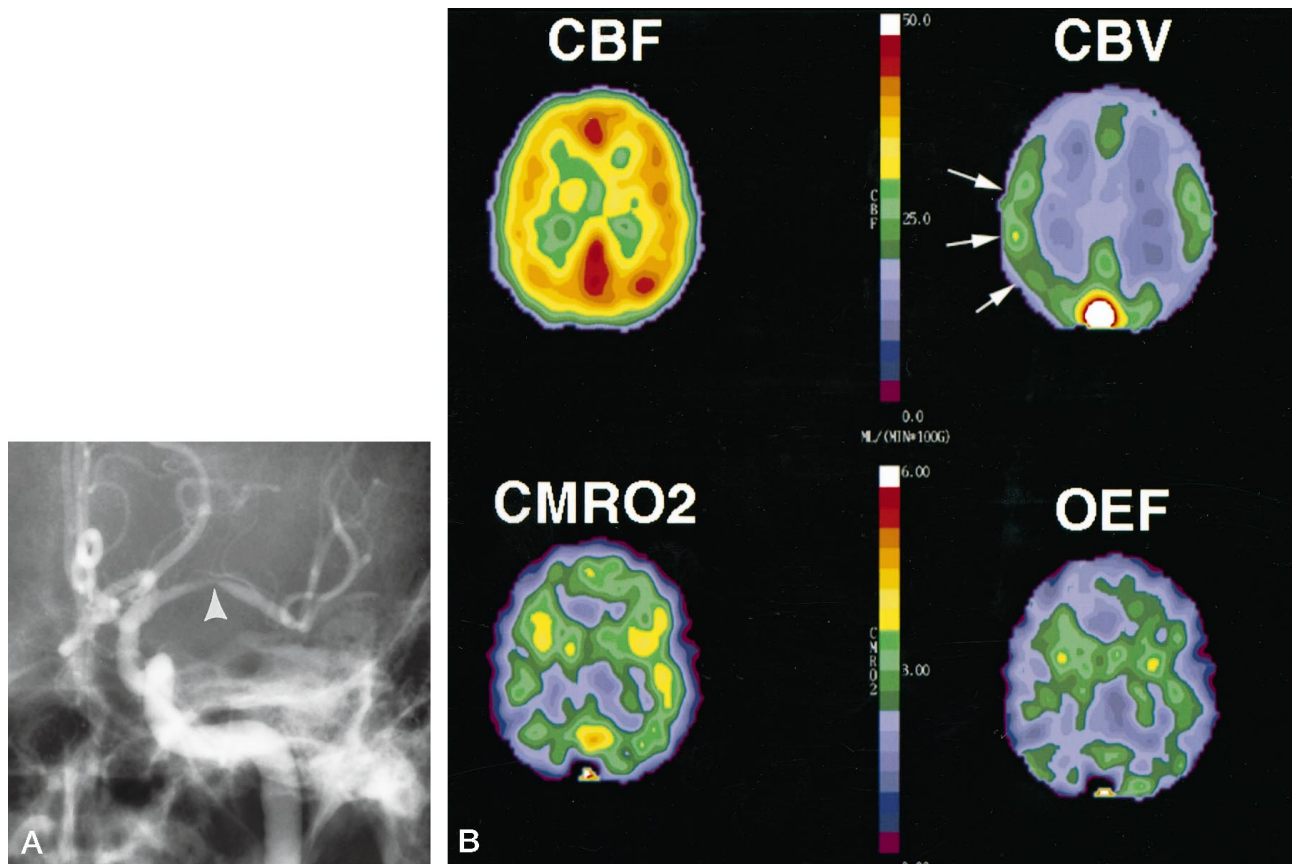


FIG 1. Patient 5: 52-year-old man with symptomatic left M1 stenosis. He was the only one of five patients with MCA stenosis who had PET evidence of distal hemodynamic compromise.

A, Anteroposterior projection from the selective arteriogram shows the site of narrowing (arrowhead) in the midportion of the left M1 trunk; the luminal diameter narrowing measured 83%.

B, Quantitative PET images of CBF, CBV, CMRO<sub>2</sub>, and OEF show the regionally increased blood volume (arrows on CBV image), consistent with autoregulatory vasodilatation. Note that left and right are reversed on the PET images relative to the arteriogram. The quantitative regional values for this patient are listed in Table 3.

normal OEF ratios (stage 1). All five patients had arteriographic evidence of pial collateralization. One explanation for this apparent discordance is the small sample size in the data presented by Powers et al (four patients with increased OEF and eight patients with autoregulatory vasodilatation) (8).

The third point raised by this data is the relative infrequency of hemodynamic compromise observed in the patients with symptomatic MCA stenosis. Only one of the five patients had evidence of distal autoregulatory vasodilatation. However, MCA stenosis can be quite dynamic (25–28). Three patients with MCA stenosis underwent repeat arteriography to confirm the stability of their lesions. The only patient with MCA stenosis and hemodynamic abnormality (patient 5) was studied within days of symptom onset. Repeat angiography 2 weeks later confirmed the stability of the lesion. The degree of stenosis in one patient who had repeat imaging (patient 7) improved from 70% before the PET examination to 20% 1 month later. Therefore, the actual degree of stenosis at the time of PET examination in three of five patients with MCA stenosis is not certain.

These data add support to the hypothesis that many ischemic events caused by MCA stenosis are embolic

in nature. Embolism from MCA stenosis has been documented (6, 7). EC/IC bypass, which improves cerebral hemodynamics, is detrimental to patients with MCA stenosis. In one study (29), 50 patients with MCA stenosis treated with EC/IC bypass experienced a statistically significant increase in subsequent stroke as compared with 59 patients treated with aspirin (22 versus 14; Mantel-Haenszel  $\chi^2$ -test, 4.74). On the other hand, recent data from a study designed to monitor patients for emboli suggest that hemodynamic factors may be important, particularly in long-standing rather than acute disease (5). These investigators used transcranial Doppler sonography to monitor 58 patients with 78 chronic MCA stenoses (mean follow-up period, 53 months) for microembolic signals. They found no sonographic evidence of emboli during 30 minutes of monitoring in each patient and concluded that hemodynamic factors are most likely responsible for recurrent ischemia in these patients. However, only patients with both high-grade and symptomatic stenoses had recurrent symptoms ( $n = 11$ ). The number and distribution of patients who were symptomatic were not reported. None of the patients with low-grade or moderate stenosis suffered a transient ischemic attack or stroke.

The results obtained in the present study are also consistent with findings by Sgouropoulos and coworkers (4), who used PET to measure rCBF, rCMRO<sub>2</sub>, and rOEF in the distal MCA cortical territory in three patients with MCA occlusion and three with high-grade (>90%) stenosis. Significantly increased rOEF was found in one patient with occlusion and in one with stenosis. rCBF was significantly reduced in all MCA regions of interest in the three patients with occlusion and in one region of interest in two patients with stenosis. No rCBV measurements (or rMTT calculations, consequently) were made, and the arteriographic pattern of collateralization was not reported.

Several important issues regarding the validity of the observations in this report should be mentioned. First, the PET examinations were performed on an older-generation scanner with less resolution than available on more modern equipment. However, large regions of interest, including both gray and white matter, were used in the data analysis for this study. The resolution of the scanner does not affect the accuracy of these quantitative measurements. The issue of interval changes in the degree of stenosis has been discussed above.

Finally, there is evidence that hemodynamic compromise may change over time if no interval stroke occurs. Derdeyn and coworkers (30) studied 22 patients with unilateral carotid artery occlusion by serial PET examinations. Patients with normal cerebral hemodynamics at entry remained hemodynamically normal (n = 9). Selected patients with no interval stroke and increased OEF on entry showed interval improvement in OEF ratios relative to baseline (n = 10, P = .023). These data are consistent with observations from Widder and colleagues (31), who used transcranial Doppler measurements before and after CO<sub>2</sub> challenge. They found that CO<sub>2</sub> reactivity improved in over half their patients (28 of 55) with unilateral carotid occlusion and diminished or exhausted cerebrovascular reserve. On the other hand, Hasegawa and colleagues (32) reported improvement in vasoreactivity in only three of 20 patients studied with single-photon emission CT using <sup>123</sup>I-iodoamphetamine and an acetazolamide challenge. Note, however, that in all three patients who improved, the underlying disease was stenotic not occlusive (two stenoses of the MCA and one of the ICA). The chronicity of the lesions in these patients was not described.

### Conclusion

The presence of symptomatic occlusion of the MCA was associated with hemodynamic compromise (stage 1 or 2) in all patients studied. This was not the case for patients with ICA occlusion, presumably because of the inability of pial collaterals to maintain normal cerebral hemodynamics. However, pial collateralization does not necessarily indicate exhausted vasodilatory capacity and increased OEF (stage 2 hemodynamic compromise). Finally, symptomatic

MCA stenosis was frequently associated with normal cerebral hemodynamics, although the actual degree of underlying stenosis at the time of the PET examination was not known in all patients.

### References

1. Higashida RT, Heishema GB, Tsai FY, Halbach VV, Norman D, Newton TH. **Transluminal angioplasty of the vertebral and basilar artery.** *AJNR Am J Neuroradiol* 1987;8:745-749
2. Ferguson R, Ferguson J, Schwarten D, et al. **Immediate angiographic results and in-hospital central nervous system complications of cerebral percutaneous transluminal angioplasty (CPTA) (abstr).** *Circulation* 1993;88:393
3. Tsai FY, Berberian B, Matovich V, Lavin M, Alfieri K. **Percutaneous transluminal angioplasty adjunct to thrombolysis for acute middle cerebral artery rethrombosis.** *AJNR Am J Neuroradiol* 1994; 15:1823-1829
4. Sgouropoulos P, Baron JC, Samson Y, Boussier MG, Comar D, Castaigne P. **Stenoses serrees et occlusions persistantes de l'artere cerebrale moyenne: consequences hemodynamiques et metaboliques etudiees par tomographie a positons.** *Rev Neurol (Paris)* 1985;141:698-705
5. Sliwka U, Klotzsch C, Popescu O, et al. **Do chronic middle cerebral artery stenoses represent an embolic focus? A multirange transcranial Doppler study.** *Stroke* 1997;28:1324-1327
6. Adams HP Jr, Gross CE. **Embolism distal to stenosis of the middle cerebral artery.** *Stroke* 1981;12:228-229
7. Masuda J, Ogata J, Yutani C, Miyashita T, Yamaguchi T. **Artery-to-artery embolism from a thrombus formed in stenotic middle cerebral artery: report of an autopsy case.** *Stroke* 1987;18:680-684
8. Powers WJ, Press GA, Grubb RL, Gado M, Raichle ME. **The effect of hemodynamically significant carotid artery disease on the hemodynamic status of the cerebral circulation.** *Ann Intern Med* 1987;106:27-35
9. Norving B, Nilsson B, Risberg J. **rCBF in patients with carotid occlusion: resting and hypercapnic flow related to collateral pattern.** *Stroke* 1982;13:155-162
10. Gibbs JM, Wise RJS, Leenders KL, Jones T. **Evaluation of cerebral perfusion reserve in patients with carotid-artery occlusion.** *Lancet* 1984;1:310-314
11. Samson Y, Baron JC. **PET studies in internal carotid artery occlusion patients: baseline hemodynamic and metabolic alterations, effects of surgical revascularization and induced arterial hypertension.** In: Heiss W-D, Pawlik G, Herholz R, Weinhard K, eds. *Clinical Efficacy of Positron Emission Tomography.* Boston: Nijhoff; 1987:55-66
12. Levine RL, Lagreye HL, Dobkin JA, et al. **Cerebral vasopacitance and TIAs.** *Neurology* 1989;39:25-29
13. Powers WJ, Temple LW, Grubb RL Jr. **Influence of cerebral hemodynamics on stroke risk: one year follow up of 30 medically treated patients.** *Ann Neurol* 1989;25:325-330
14. Powers WJ, Grubb RL, Raichle ME. **Clinical results of extracranial-intracranial bypass surgery in patients with hemodynamic cerebrovascular disease.** *J Neurosurg* 1989;70:61-67
15. Powers WJ. **Cerebral hemodynamics in ischemic cerebrovascular disease.** *Ann Neurol* 1991;29:231-240
16. Baron JC, Boussier MG, Rey A, Guillard A, Comar D, Castaigne P. **Reversal of focal "misery perfusion syndrome" by extra-intracranial artery bypass in hemodynamic cerebral ischemia: a case study with 0-15 positron emission tomography.** *Stroke* 1981;12:454-459
17. Ter-Pogossian MM, Ficke DC, Hood JT Sr, Yamamoto M, Mullani NA. **PETT VI: a positron emission tomograph utilizing cesium fluoride scintillation detectors.** *J Comput Assist Tomogr* 1982;6: 125-133
18. Raichle ME, Martin WRW, Herscovitch P, Mintun MA, Markham J. **Brain blood flow measured with intravenous H<sub>2</sub><sup>15</sup>O, II: implementation and validation.** *J Nucl Med* 1985;24:790-798
19. Herscovitch P, Markham J, Raichle ME. **Brain blood flow measured with intravenous H<sup>15</sup>O, I: theory and error analysis.** *J Nucl Med* 1983;24:782-789
20. Martin WRW, Powers WJ, Raichle ME. **Cerebral blood volume measured with inhaled C15-0 and positron emission tomography.** *J Cereb Blood Flow Metab* 1987;7:421-426
21. Mintun MA, Raichle ME, Martin WRW, Herscovitch P. **Brain oxygen utilization measured with O-15 radiotracers and positron emission tomography.** *J Nucl Med* 1984;25:177-187
22. Welch MJ, Kilbourne MR. **A remote system for the routine pro-**

- duction of oxygen-15 radiopharmaceuticals. *J Labeled Compds Radiopharm* 1985;22:1193-1200
23. Fox PT, Perlmutter JS, Raichle ME. A stereotactic method of anatomical localization for positron emission tomography. *J Comput Assist Tomogr* 1985;9:141-153
  24. Powers WJ, Grubb RL Jr, Darriet D, Raichle ME. Cerebral blood flow and cerebral metabolic rate of oxygen requirements for cerebral function and viability in humans. *J Cereb Blood Flow Metab* 1985;5:600-608
  25. Day AL, Rhoton AL, Quisling RG. Resolving siphon stenosis following endarterectomy. *Stroke* 1980;11:278-281
  26. Craig DR, Meguro K, Watridge C, Robertson JT, Barnett HJ, Fox AJ. Intracranial internal carotid artery stenosis. *Stroke* 1982;13:825-828
  27. Awad I, Furlan AJ, Little JR. Changes in intracranial stenotic lesions after extracranial-intracranial bypass surgery. *J Neurosurg* 1984;60:771-776
  28. Fox JL. Cerebral arterial revascularization: the value of repeated angiography in selection of patients for operation. *Neurosurgery* 1978;2:205-209
  29. The EC/IC Bypass Group. Failure of extracranial-intracranial arterial bypass to reduce the risk of ischemic stroke: results of an international randomized trial. *N Engl J Med* 1985;313:1191-1200
  30. Derdeyn CP, Yundt KD, Videen TO, Grubb RL, Carpenter DA, Powers WJ. Temporal stability of hemodynamic stage in patients with carotid occlusion (abstr). *J Neurosurg* 1998;88:196A-197A
  31. Widder B, Kleiser B, Krapf H. Course of cerebrovascular reactivity in patients with carotid artery occlusions. *Stroke* 1994;25:1963-1967
  32. Hasegawa Y, Yamaguchi T, Tsuchiya T, Minematsu K, Nishimura T. Sequential change of hemodynamic reserve in patients with major cerebral artery occlusions or severe stenosis. *Neuroradiology* 1992;34:15-21