

MR Findings in Growth Hormone Deficiency: Correlation with Severity of Hypopituitarism

Liora Kornreich, Gadi Horev, Liora Lazar, Michael Schwarz,
Jacquelin Sulkes, and Athalia Pertzalan

BACKGROUND AND PURPOSE: Growth hormone deficiency may present as an isolated deficit (IGHD) or in association with multiple deficiencies (MPHD). Previous studies have not compared the MR imaging findings with the severity of hypopituitarism. Our purpose was to determine whether MR imaging can distinguish between IGHD and MPHD.

METHODS: Forty-four patients with growth hormone deficiency who were examined by MR imaging were included in this retrospective study. On the basis of the endocrinologic findings, 21 were determined to have IGHD and 23 to have MPHD. The presence, size, location, and morphologic characteristics of the stalk, the neurohypophysis, and the adenohypophysis were recorded in each case. Findings in the two groups were compared. Statistical significance was determined by *t*-test.

RESULTS: The stalk was normal in one patient with IGHD and in none of those with MPHD; it was truncated or thin in 19 patients with IGHD (90%) and in only one with MPHD (4%); it was absent in 22 patients with MPHD (96%) and in only one patient with IGHD (5%). These differences between the two groups were highly significant. In 81% of the IGHD patients and in 91% of the MPHD patients the location of the neurohypophysis was ectopic. This difference between the two groups was not significant. Among IGHD patients, the adenohypophysis was of normal size in 13 patients (62%), small in six (29%), and absent in two (9%); the corresponding findings in MPHD patients were seven (30%), six (26%), and 10 (44%).

CONCLUSION: The majority of IGHD patients had a truncated or thin stalk and a normal or small adenohypophysis. An absent stalk and adenohypophysis are characteristic of MPHD. MR imaging can contribute to the prediction of the pattern and severity of hypopituitarism in patients with growth hormone deficiency.

Growth hormone deficiency (GHD) presents a spectrum of findings both clinically and anatomically. The endocrine abnormality may be either an isolated deficiency (IGHD) or it may be multiple deficiencies (MPHD) (1). It is known that more males than females suffer from GHD (1). Findings on MR images range from normal pituitary-hypothalamic anatomy to an absent pituitary and stalk and an ectopic neurohypophysis (2); however, because of the considerable overlap in the reported MR findings between IGHD and MPHD, the relationship between mor-

phology (neuroradiologic findings) and severity of endocrine dysfunction has not yet been clarified (2–10).

IGHD may progress to MPHD. Because clinical and laboratory findings are not reliable prognosticators of this progression, it would be useful to differentiate the two groups by their imaging characteristics (1, 11). With the continuing improvement in MR resolution and the widespread use of contrast material, it is now possible to discern anatomic details of the pituitary-hypothalamic region. The purpose of our retrospective study was to characterize the MR findings in patients with GHD and to determine whether these findings can be used to distinguish IGHD from MPHD.

Methods

The study group comprised 44 patients (35 males and nine females) with idiopathic GHD. Patients' ages ranged from 4 months to 33 years. The diagnosis had been established by the referring physician on the basis of clinical findings of short stature (<2.5 SD), decreased growth velocity (<2.5 SD), and

Received October 22, 1997; accepted after revision January 30, 1998.

From the Department of Imaging (L.K., G.H., M.S.) and the Institute of Endocrinology (L.L., A.P.), Schneider Children's Medical Center of Israel, Institute of Epidemiology (J.S.), Rabin Medical Center, Beilinson Campus, Petah Tikvah, and Sackler Faculty of Medicine, Tel Aviv University, Tel Aviv, Israel.

Address reprint requests to L. Kornreich, MD, Department of Imaging, Schneider Children's Medical Center of Israel, Beilinson Campus, 49 202 Petah Tikvah, Israel.

TABLE 1: Clinical data of 23 patients with multiple pituitary growth hormone deficiencies

Patient	Age, y/Sex	Neonatal Diagnosis	Hormonal Profile					Stalk
			GH	TSH	Gn	ACTH	ADH	
1	13/M	-	D	N	D	N	N	A
2	12/F	-	D	N	D	N	N	A
3	11/M	-	D	D	N	N	D	A
4	17/M	-	D	D	D	N	N	A
5	21/F	-	D	D	D	N	N	A
6	15/M	-	D	D	D	N	N	A
7	19/M	-	D	D	D	N	N	A
8	18/M	-	D	D	D	N	N	A
9	33/M	-	D	D	D	D	N	A
10	20/M	-	D	D	D	D	N	A
11	21/M	-	D	D	D	D	N	A
12	17/M	-	D	D	D	N	N	T
13	14/F	-	D	D	D	N	N	A
14	27/M	-	D	D	D	N	N	A
15	18/M	-	D	D	D	N	N	A
16	13/M	-	D	D	N	N	N	A
17	13/M	+	D	D	D	D	N	A
18	13/M	+	D	D	D	N	N	A
19	10/M	+	D	D	D	N	N	A
20	11/M	+	D	N	N	D	D	A
21	11/F	+	D	D	D	D	N	A
22	0.3/M	+	D	D	D	D	N	A
23	14/F	+	D	D	D	D	D	A

Note.—D, deficiency; N, normal level; -, no; +, yes; A, absent; T, truncated; GH, growth hormone; TSH, thyroid stimulating hormone; Gn, gonadotropin stimulating hormone; ACTH, adrenocortical stimulating hormone; ADH, antidiuretic hormone.

biochemical findings of lack of GH response (GH < 2.5 ng/mL) on at least two stimulation tests (1). Patients with hereditary GHD or GHD associated with midline anomalies or tumors were excluded. Each patient had undergone a complete evaluation of hypothalamic-pituitary axis function (1), resulting in the diagnosis of IGHD in 21 patients and MPH in 23. Eight of the IGHD patients were prepubertal and 13 were pubertal or postpubertal. In the MPH group, six were prepubertal and 17 were pubertal or postpubertal. In seven patients, MPH was diagnosed in the neonatal period. The endocrinologic data of the patients with MPH are summarized in Table 1.

MR examinations were performed using 0.5-T systems. The imaging protocol included coronal and sagittal T1-weighted images of the pituitary (400–500/12–20/3–4 [TR/TE/excitations]). In a few cases, a sagittal T1-weighted gradient-echo sequence was used instead of the spin-echo (400/4.7–18/2; flip angle = 70°) sequence. The sagittal sections were planned on the coronal cut depicting the pituitary, so that the central sagittal section was positioned at the expected location of the stalk. Other imaging parameters included a section thickness of 2.9 to 4.0 mm with a gap of 0.6 to 1.0 mm (the thinnest section available), a 200 × 256 or 256 × 256 matrix, and an 18 × 20-mm field of view.

The presence of the stalk was determined and its width was evaluated on both the coronal and sagittal images. The stalk was graded as normal, thin (<3.25 + 0.56 mm) (12), truncated, or absent. The T1 hyperintense focus of the neurohypophysis was defined as normally located, ectopic, or absent. The maximal craniocaudal height of the adenohypophysis was measured at the actual or expected site of stalk insertion. The adenohypophysis was graded as absent, normal, or small in relation to pubertal status. Its normal height was considered to be at least 2 mm prepubertally and at least 5 mm pubertally and postpubertally (2). Contrast agent was injected at the discretion of the examining radiologist to depict more clearly the anatomic abnormalities of the pituitary and/or stalk; it was used in half the patients.

TABLE 2: Appearance of stalk and hypophysis in patients with an isolated pituitary growth hormone deficiency (IGHD) and multiple pituitary hormone deficiencies (MPHD)

	IGHD, No. (%)	MPHD, No. (%)
Stalk		
Normal	1 (5)	0
Thin or truncated	19 (90)	1 (4)
Absent	1 (5)	22 (96)
		<i>P</i> <.0001
Neurohypophysis		
Normal	3 (14)	0
Ectopic	17 (81)	21 (91)
Absent	1 (5)	2 (9)
		<i>P</i> >.05
Adenohypophysis		
Normal	13 (62)	7 (30)
Small	6 (29)	6 (26)
Absent	2 (9)	10 (44)
		<i>P</i> <.03

The MR findings of the group with IGHD were compared with those of the group with MPH.

Results

The patients with IGHD were significantly younger than those with MPH (mean ages, 12 and 16 years, respectively; *P* < .04).

As shown in Table 2, there were highly significant differences between the two groups with respect to both the appearance of the stalk and its presence or

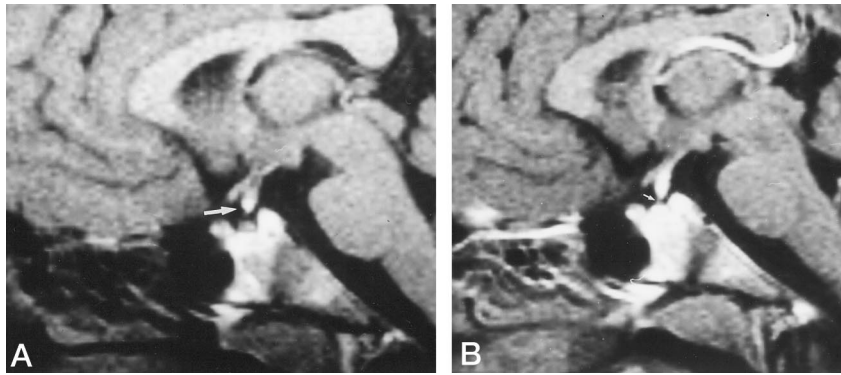


FIG 1. 12-year-old boy with IGHD.

A and B, Sagittal unenhanced (A) and contrast-enhanced (B) T1-weighted (400/25/4) MR images show typical findings of IGHD: a truncated stalk with an ectopic neurohypophysis at its caudal end (arrow, A). After contrast injection, the stalk looks thickened and a thin thread is seen extending to the gland (arrow, B). The height of the adenohypophysis is normal.

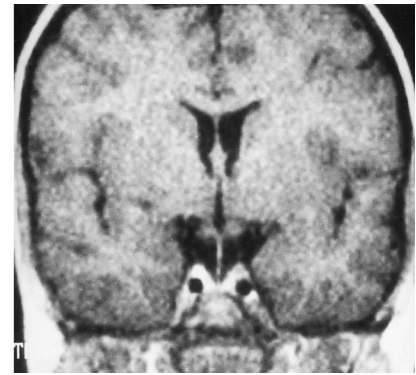


FIG 2. 6-year-old boy with IGHD. Coronal unenhanced T1-weighted image (400/20/3) shows a thin but complete stalk, also characteristic of IGHD.

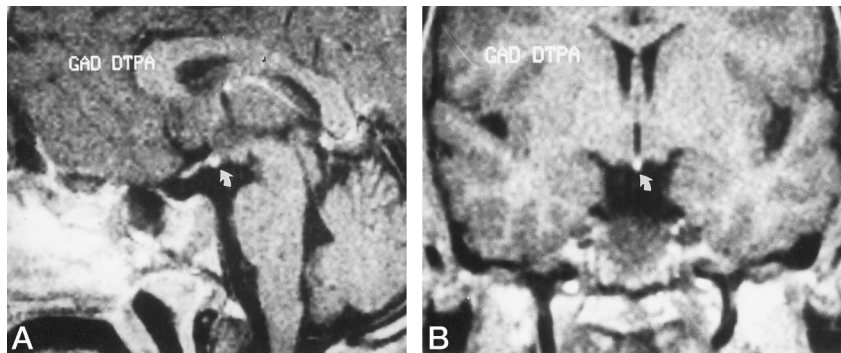


FIG 3. 33-year-old man with MPHD.

A and B, Sagittal (A) and coronal (B) contrast-enhanced T1-weighted images (400/20/3) show typical findings of MPHD; namely, an ectopic neurohypophysis (arrow) and an absent stalk and adenohypophysis.

absence ($P < .0001$). In the IGHD group, the stalk was truncated or very thin in 19 of 21 patients; it appeared normal in only one patient, and was absent in one. The truncated stalk seen in 14 patients (66%) was short and thickened, often with a thin threadlike remnant extending caudally from the end of the stalk to the pituitary (Fig 1). This appearance could be easily confused with that of a normal stalk. In five patients (24%), a thin but complete stalk could be seen (Fig 2). In the MPHD group, the stalk was absent in 22 patients and was truncated in only one; none of these patients had a normal or thin stalk (Fig 3).

The neurohypophysis was seen in an ectopic location in 17 of the patients with IGHD and in 21 with MPHD (Table 2). The difference between them was not significant ($P > .05$). In cases in which the stalk was truncated, the bright spot of the neurohypophysis was found to be ectopic but was located along the stalk or at its caudal end. Where the stalk was thin, the neurohypophysis was at the median eminence of the hypothalamus in four patients and normally located in one.

No significant difference in the mean height of the adenohypophysis was observed between the two groups ($P > .05$); however, quantitative evaluation of the gland (normal, small, or absent) in relation to pubertal status showed a significant difference between them ($P < .03$). Among patients with IGHD, the adenohypophysis was normal in 13, small in six,

and absent in two; in MPHD patients, it was normal in seven, small in six, and absent in 10 (Table 2).

Discussion

Anomalies of the pituitary-hypothalamic region may be manifested in the stalk, the neurohypophysis, and/or the adenohypophysis. The stalk is usually categorized as normal or abnormal; in most of the published studies, abnormal includes invisible, truncated, and thin stalks as a single group (4, 9). The neurohypophysis is generally described as normally located or ectopic. The ectopic position is usually at the median eminence of the hypothalamus.

Improved MR imaging and resolution enable the radiologist to recognize more subtle anomalies of the stalk. Injection of contrast material also contributes to a better delineation. In 66% of our patients with IGHD we observed a partial (truncated) stalk. In these cases, the bright spot of the neurohypophysis was ectopic, but was located along the truncated stalk or at its caudal end. In an additional 24% of the IGHD patients we observed a continuous but very thin stalk. Therefore, in 90% of IGHD patients the stalk was present but abnormal. In a previous study of IGHD, a thin stalk was observed in six of 22 patients (13). Other authors have also noted variations in stalk length and thickness, but did not examine their relationship to the pattern of endocrinopathy (IGHD

versus MPHD) (5, 9). Ulmann (14) was the first to report that the appearance of a thick truncated stalk was associated with less severe hormonal deficiencies. In our opinion, these anomalies of the stalk are characteristic of IGHD.

Most authors, in considering anomalies of the stalk and the neurohypophysis together, conclude that the findings of ectopic neurohypophysis and absent stalk are more common in MPHD than in IGHD (3, 4, 6–10, 15), and that a stalk is only rarely present in patients with MPHD (3, 4, 9). In our study, we analyzed the precise position of the neurohypophysis and the appearance of the stalk separately, and found that whereas an ectopic bright spot is not an indicator of MPHD, absence of the stalk is associated almost exclusively with MPHD. We had only one patient with IGHD in whom the stalk was not visible (5%), while not a single patient with MPHD had a normal stalk ($P < .0001$).

In two recent reports, one group of investigators (16, 17) stressed the importance of contrast injection as a means of optimizing visualization of a thin stalk. They commented that in a previous study of the same patients, these filiform stalks were not observed and were listed as absent (7). Their conclusion, based on their later studies, is similar to ours; namely, that the presence of a thin stalk is highly suggestive of IGHD. They estimated that patients with an absent pituitary stalk were at 27 times greater risk of incurring MPHD than were those who had an identifiable pituitary stalk (15). Absence of the stalk results in disruption of the periinfundibular hypophyseal portal venous system; the impaired vascular supply and its possible causative relationship to the dysfunction of the adenohypophysis have been investigated (16–18). The dynamic studies were unable to distinguish between IGHD and MPHD (16, 17).

The adenohypophysis is evaluated in terms of its size. It is generally accepted that the size of the gland in patients with GHD will be smaller than normal (3, 4, 5). Nevertheless, most authors agree that a small adenohypophysis does not distinguish prognostically between IGHD and MPHD (3, 5–8). In a recent study, however, the size of the gland was evaluated in relation to puberty, and a small gland was found to be significantly related to MPHD only after puberty (15). Similar findings were obtained in our study; the size of the gland did not differ in the two groups as a whole, but when correlated with pubertal status the prevalence of an adenohypophysis of normal size was twice as high in patients with IGHD than in those with MPHD (62% versus 30%; $P < .03$). We found that nonvisualization of the gland was an even more specific sign of MPHD, occurring in 44% of these patients and in 9% of patients with IGHD ($P < .03$). Thus, the absence of an adenohypophysis is highly suggestive of MPHD.

The pathogenesis of the neuroradiologic anomalies in GHD was postulated originally as a traumatic transection of the stalk during birth. A high prevalence of breech deliveries had been reported in the endocrinologic literature, but later reports noted a lower

prevalence of traumatic deliveries in these patients (5). Moreover, this theory cannot explain the spectrum of findings in GHD, including a normally positioned neurohypophysis and a truncated or complete but very thin stalk. An alternative hypothesis of a congenital defect due to an embryonic failure in the normal development of the hypothalamus and hypophysis has been suggested (5). Pituitary gland organogenesis is classically described as a fusion between the adenohypophysis, which is derived from an ectodermal evagination of the roof of the stomodeum, and the neurohypophysis, which develops as a downward projection of the neuroectoderm of the base of the brain. Recent reinvestigation of the early embryogenesis of the rostromedial brain suggests, however, that the pituitary gland is formed as a single structure from the surface and neural ectoderm in a small area on the ventral surface of the rostral neural fold (5, 19). The hypothalamic floor has a crucial influence on the development of the adenohypophysis, which from an early stage (day 41) is wrapped around the primordium of the posterior hypophysis. After week 8 of gestation there is differentiation of the latter into stalk and neurohypophysis, as well as penetration of blood vessels into the adenohypophysis, which becomes glandular tissue (19). An insult that occurs during this period may result in GHD. The nature of the anatomic anomalies will determine the types and severity of the hormonal deficiencies.

Conclusion

The pathogenesis of GHD is still unclear, but much experience has been gained in recognizing the spectrum of the imaging findings and their clinical implications. It is our impression that nonvisualization of the anterior hypophysis and/or the stalk are indicative of MPHD. A truncated or thin stalk is highly suggestive of IGHD. These are reliable and easily recognizable signs that can be helpful in the clinical management of patients with GHD.

References

1. Ranke MB. **Growth hormone insufficiency: clinical features, diagnosis and therapy.** In: De Groot LJ, ed. *Endocrinology* 3rd ed. Philadelphia: Saunders; 1995:330–339
2. Elster AD. **Modern imaging of the pituitary.** *Radiology* 1993;187:1–14
3. Bressani N, Di Natale B, Pellini C, Triulzi F, Scotti G, Chiumello G. **Evidence of morphological and functional abnormalities in the hypothalamus of growth-hormone-deficient children: a combined magnetic resonance imaging and endocrine study.** *Horm Res* 1990;34:189–192
4. Argyropoulou M, Perignon F, Brauner R, Brunelle F. **Magnetic resonance imaging in the diagnosis of growth hormone deficiency.** *J Pediatr* 1992;120:886–891
5. Triulzi F, Scotti G, Di Natale B, et al. **Evidence of a congenital midbrain anomaly in pituitary dwarfs: a magnetic resonance imaging study in 101 patients.** *Pediatrics* 1994;93:409–416
6. Cacciari E, Zucchini S, Carla G, et al. **Endocrine function and morphological findings in patients with disorders of the hypothalamic-pituitary area: a study with magnetic resonance.** *Arch Dis Child* 1990;65:1199–1202
7. Maghnie M, Triulzi F, Larizza D et al. **Hypothalamic-pituitary dysfunction in growth hormone deficient patients with pituitary abnormalities.** *J Clin Endocrinol Metab* 1991;73:79–83
8. Abrahams JJ, Trefelner E, Boulware SD. **Idiopathic growth hor-**

- hormone deficiency: MR findings in 35 patients.** *AJNR Am J Neuroradiol* 1991;156:599-604
9. Scotti G, Triulzi F, Chiumello G, Di Natale B. **New imaging techniques in endocrinology: magnetic resonance of the pituitary gland and sella turcica.** *Acta Paediatr Scand* 1989;356:4-14
 10. Vannelli S, Avataneo T, Benso L, et al. **Magnetic resonance and the diagnosis of short stature of hypothalamic-hypophyseal origin.** *Acta Paediatr* 1993;82:155-161
 11. Crowne EC, Shalet SM. **Adult panhypopituitarism presenting as idiopathic growth hormone deficiency in childhood.** *Acta Paediatr Scand* 1991;80:255-258
 12. Simmons GE, Suchnicki JE, Rak KM, Damiano TR. **MR imaging of the pituitary stalk: size, shape, and enhancement pattern.** *AJR Am J Roentgenol* 1992;159:375-377
 13. Marwaha R, Menon PS, Jena A, Pant C, Sethi AK, Sapra ML. **Hypothalamo-pituitary axis by magnetic resonance imaging in isolated growth hormone deficiency patients born by normal delivery.** *J Clin Endocrinol Metab* 1992;74:654-659
 14. Ultmann MC, Siegel SF, Hirsch WL, Finegold DN, Foley P Jr. **Pituitary stalk and ectopic hyperintense T1 signal on magnetic resonance imaging.** *Am J Dis Child* 1993;147:647-652
 15. Bozzola M, Adamsbaum C, Biscaldi I, et al. **Role of magnetic resonance imaging in the diagnosis and prognosis of growth hormone deficiency.** *Clin Endocrinol* 1996;45:21-26
 16. Maghnie M, Genovese E, Villa A, et al. **Dynamic MRI in the congenital agenesis of the neural pituitary stalk syndrome: the role of the vascular pituitary stalk in predicting residual anterior pituitary function.** *Clin Endocrinol* 1996;45:281-290
 17. Genovese G, Maghnie M, Beluffi G, et al. **Hypothalamic-pituitary vascularization in pituitary stalk transection syndrome: is the pituitary stalk really transected?** *Pediatr Radiol* 1997;24:48-53
 18. Liu HM, Li Y-W, Tsai WY, Su CT. **Dynamic enhancement MRI of anterior lobe in pituitary dwarfism.** *Neuroradiology* 1995;37:486-490
 19. Kollias SS, Ball WS, Prenger EC. **Review of the embryologic development of the pituitary gland and report of a case of hypophyseal duplication detected by MRI.** *Neuroradiology* 1995;37:3-12