



# Severe psittacosis progressing to suspected organizing pneumonia and the role of corticosteroids

Rachael Zuzek<sup>a,b,\*</sup>, Malcolm Green<sup>a</sup>, Stephen May<sup>a</sup>

<sup>a</sup> Tamworth Rural Referral Hospital, Tamworth, Australia

<sup>b</sup> Wollongong Hospital, Wollongong, Australia

## ARTICLE INFO

### Keywords:

Chlamydia psittaci  
Psittacosis  
Atypical pneumonia  
Cryptogenic organizing pneumonia  
Organizing pneumonia  
Corticosteroid

## ABSTRACT

**Background:** Psittacosis is a systemic disease usually with respiratory involvement, caused by the obligate intracellular bacterium *Chlamydia psittaci*. Exposure to birds, the main zoonotic reservoir, is a major risk factor for infection. The spectrum of disease is highly variable, ranging from subclinical infection to severe pneumonia requiring mechanical ventilation. There is limited data on psittacosis progressing to organizing pneumonia and management of such cases.

**Case presentation:** A 63-year-old man was referred to a rural hospital with 11 days of fevers to 39 °C, myalgia, lethargy and several days of dry cough. After initial treatment with benzylpenicillin and doxycycline for left lower pneumonia found on CXR, the patient deteriorated with extensive bilateral consolidation on chest CT requiring mechanical ventilation. Atypical pneumonia screening was negative, however, exposure to a sick bird prior to symptom onset triggered testing for *C. psittaci* which was positive. Doxycycline was recommenced with minimal benefit, and organizing pneumonia was later suspected. The patient slowly improved with a weaning course of corticosteroids started after 19 days and was discharged from hospital. He unfortunately was re-admitted and died several months later.

**Conclusion:** Severe pneumonia is a rare, but potentially life-threatening complication of psittacosis. We present a case of psittacosis which progressed to suspected organizing pneumonia despite appropriate antibiotics, and subsequent treatment with corticosteroids. This case suggests it may be useful to consider corticosteroids early in therapy for patients with severe psittacosis. Our paper underlines the need for further research to determine the best management of severe psittacosis to improve patient outcomes.

## 1. Case presentation

A 63-year-old Caucasian man was referred to a rural hospital with 11 days of fevers, myalgia, lethargy and anorexia, and several days of dry cough. His medical history included chronic urinary tract infections secondary to hypospadias, asthma, recurrent sinusitis requiring surgery, and anxiety. He previously was a smoker with a minimal pack-year history, and had an excellent exercise tolerance. He had no history of recent travel or intravenous drug use.

On presentation the patient was febrile at 39.0 °C (Fig. 1) with an oxygen saturation of 94 % on room air, but otherwise normotensive and neither tachypnoeic nor tachycardic. He had decreased breath sounds at the left base, associated with dullness to percussion. Chest x-ray (CXR)

confirmed consolidation in the left lower zone with a moderate left-sided pleural effusion (Fig. 2). C-Reactive Protein (CRP) was markedly elevated at 456mg/dL, with a white cell count of  $12.4 \times 10^9/L$  (differential  $11.4 \times 10^9/L$ ). Liver enzymes were also elevated with GGT 521 U/L, ALP 596 U/L, ALT 162 U/L and AST 82 U/L. Testing for SARS-CoV-2 was negative.

He was started on intravenous benzylpenicillin and oral doxycycline for community acquired pneumonia, with initial improvement. After five days the patient rapidly deteriorated with hypoxia (SpO<sub>2</sub> 91 % on 8L O<sub>2</sub>, RR 30/min), hypotension (BP 107/61 mmHg) and ongoing fever (39.2 °C). Arterial blood gas demonstrated type I respiratory failure with respiratory alkalosis and incomplete compensatory metabolic acidosis (pH 7.55, pCO<sub>2</sub> 19, pO<sub>2</sub> 52, bicarbonate 17.8 mmol/L). His CXR had

**Abbreviations:** ARDS, Acute respiratory distress syndrome; COP, Cryptogenic organizing pneumonia; CRP, C-reactive protein; CT, computed tomography; CXR, chest X-ray; ICU, intensive care unit; MV, mechanical ventilation; OP, Organizing pneumonia; PCR, polymerase chain reaction.

\* Corresponding author. Tamworth Rural Referral Hospital, Tamworth, Australia.

E-mail address: [rachael.zuzek@health.nsw.gov.au](mailto:rachael.zuzek@health.nsw.gov.au) (R. Zuzek).

<https://doi.org/10.1016/j.rmcr.2021.101486>

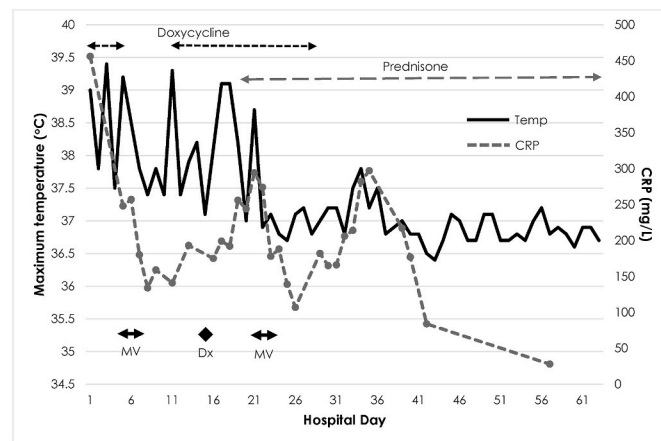
Received 28 March 2021; Received in revised form 26 June 2021; Accepted 23 July 2021

Available online 27 July 2021

2213-0071/Crown Copyright © 2021 Published by Elsevier Ltd.

This is an open access article under the CC BY-NC-ND license

(<http://creativecommons.org/licenses/by-nc-nd/4.0/>).



**Fig. 1.** CRP and temperature charting and relationship to doxycycline and prednisone prescribing. MV, mechanical ventilation; Dx, diagnosis of psittacosis made via serology and PCR testing.

progressed with near complete consolidation of the left lung with pleural effusion and new consolidation in the right upper lobe (Fig. 2); confirmed with computed tomography (CT) (Fig. 3). The patient was placed on high flow nasal oxygen and then intubated for retrieval to a larger rural intensive care unit (ICU). Antibiotic treatment was changed to piperacillin/tazobactam and azithromycin with a loading dose of vancomycin to cover hospital acquired pneumonia. He was extubated after 48 hours of mechanical ventilation, azithromycin was ceased (piperacillin/tazobactam continued for 5 days) and subsequently stepped down to the ward.

Over the following 4 days the patient had persistent fever and increasing oxygen requirement prompting additional investigation for atypical pneumonia aetiologies (Table 1). Once off the ventilator a history of exposure to a sick *Eolophus roseicapilla* “gallah” days prior to symptom onset triggered testing for *C. psittaci* and the patient was recommenced on doxycycline (day 11 admission, day 22 illness). Psittacosis was confirmed by serology (titre of 256) and PCR 4 days later. Despite another 6 days of doxycycline therapy the patient continued to deteriorate with extensive multi-lobe consolidation (Fig. 2). Meropenem and vancomycin were added and he was returned to ICU. Given the minimal response to extended antibiotics, a trial of corticosteroid therapy was commenced with prednisone 50mg daily (day 19 admission). However, re-intubation was required 2 days later for another 48 hours, during which a bronchoscopy was performed. Bronchoalveolar lavage recovered a small amount of fluid with neutrophilia and the presence of macrophages. This, in combination with the fluctuating patchy air-space consolidation on imaging and clinical features led to a suspected diagnosis of organizing pneumonia, though lung biopsy was not performed. Prednisone was continued at a weaning dose and an 18-day course of doxycycline was completed (total 23 days including initial 5 days of therapy).

The patient remained very fragile with an extremely poor respiratory reserve, critical illness myopathy and deconditioning with 20-kg weight loss. His admission was further complicated by a positive sputum culture for *Pseudomonas aeruginosa* treated with a 5-day course of piperacillin/tazobactam; development of a hydropneumothorax managed conservatively; and a right arm deep venous thrombosis secondary to a long line managed with anticoagulation. His recovery was slow and the potential need for lung transplant was discussed, however, it was decided to reconsider when the patient’s general condition improved. After a

total of 63 days, including 44 days in ICU, the patient was discharged home with a supply of home oxygen and continued on a weaning dose of prednisone.

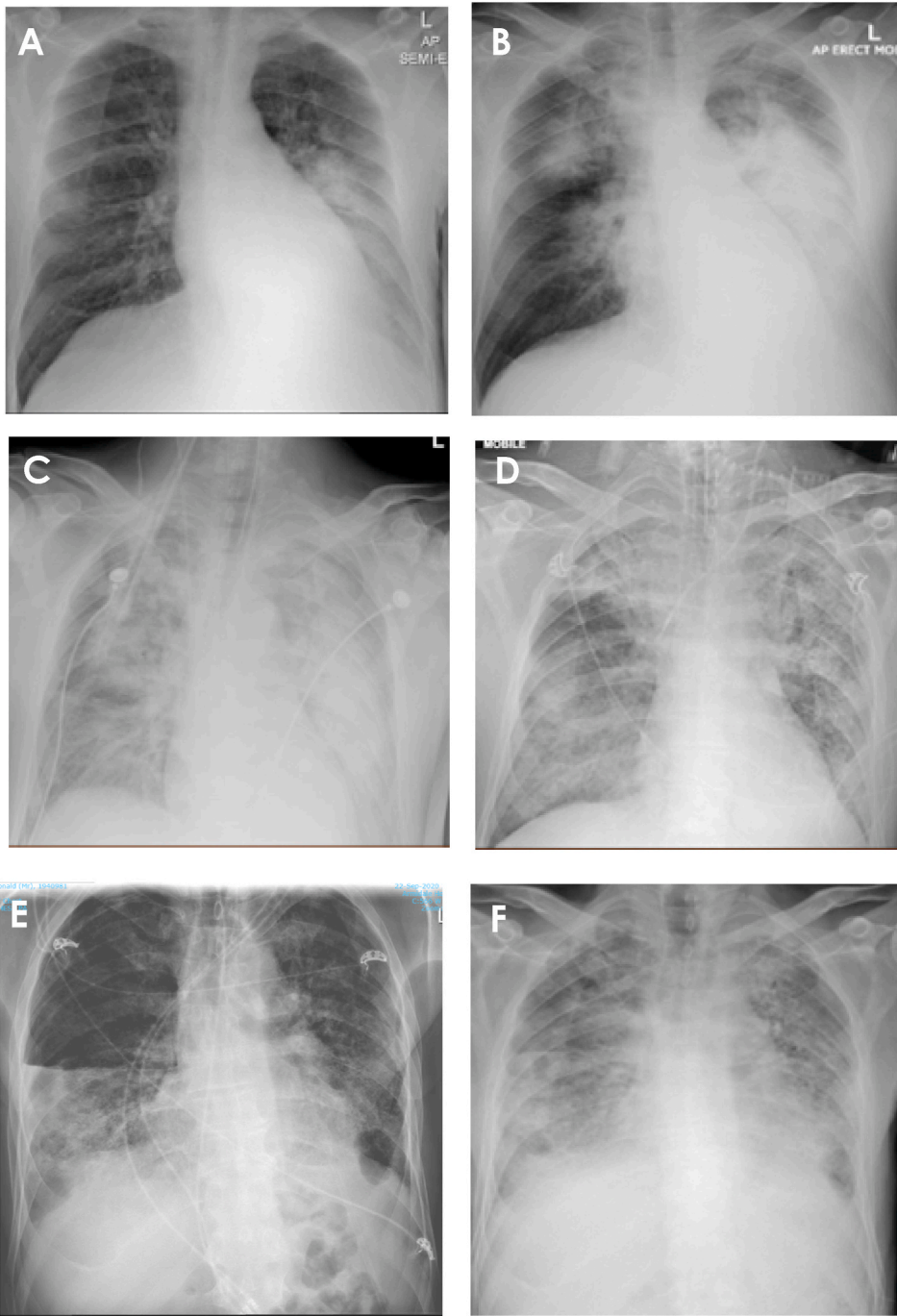
At follow up one month later, the patient was still desaturating on exertion and though repeat CT demonstrated improvement in the extent of consolidation, there were some new subpleural infiltrates, an area of associated traction bronchiectasis and a persistent right sided hydro-pneumothorax, likely secondary to a bronchopleural fistula (Fig. 3). Prednisone was ceased after 11 weeks. Unfortunately, the patient was re-admitted to hospital a month later for worsening dyspnoea. Despite initial discussion of potential lung transplantation, the patient made the decision for palliative measures. He died peacefully several weeks later.

## 2. Discussion

Psittacosis is caused by the obligate intracellular bacterium *Chlamydia psittaci*. The condition has been documented globally and is estimated to cause ~1 % of cases of community acquired pneumonia [1]. Exposure to birds, the main zoonotic reservoir, is a major risk factor with transmission occurring by inhalation of aerosolised bacteria from infected secretions, droppings or feathers [2].

The spectrum of disease is highly variable, ranging from subclinical infection in many, to rare severe cases associated with multi-organ failure. After an incubation period of usually 5–14 days, patients typically present with systemic symptoms including fevers, rigors, sweats, headache and myalgias, with respiratory symptoms such as cough and dyspnoea often developing late [3–6]. Whilst the above may be seen with other respiratory infections, clues for suspecting psittacosis include a history of contact with birds, headache as an early symptom, which is often severe [4], hepatomegaly or splenomegaly on examination (which may occur in 10 % of patients [4]) and a lack of response to beta-lactam antibiotics. Severe cases can result in hypoxic respiratory failure requiring mechanical ventilation, even in patients who are previously healthy, and may also be associated with neurologic, renal, gastrointestinal and haematological complications [3,7]. In such cases, mortality can be as high as 66–70 % [4,7].

Common laboratory findings include left shift of neutrophils often with normal white cells, elevated ESR and CRP [4], and deranged liver enzymes [3]. Chest x-ray (CXR) is abnormal in 80 % of patients, usually with consolidation affecting a single, often lower, lobe [4,8], and less

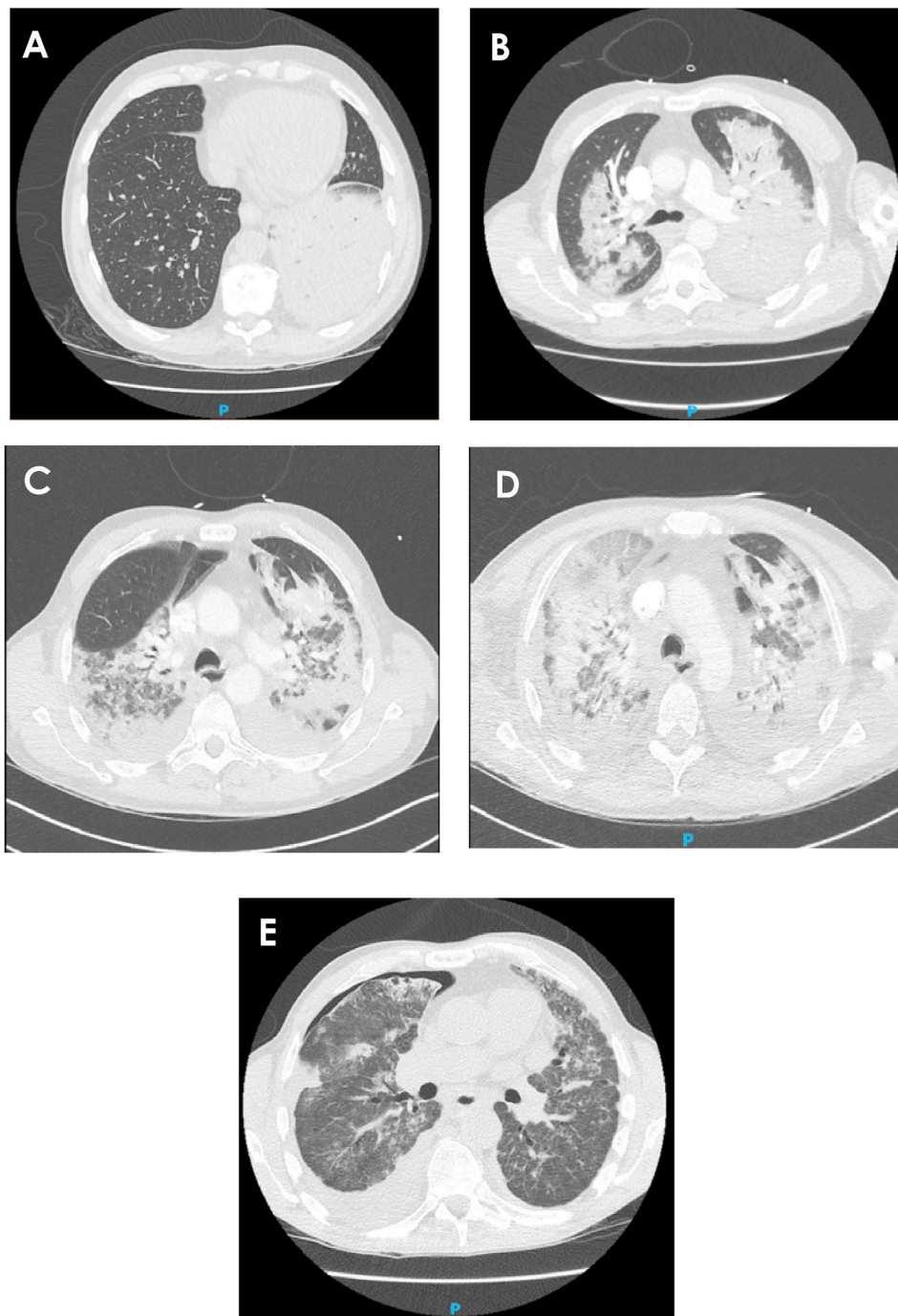


**Fig. 2.** Serial chest x-rays; A – hospital day 1: consolidation in the left lower zone with a moderate left-sided pleural effusion, B – hospital day 5: near complete consolidation of the left lung with pleural effusion, new consolidation in the right upper lobe, C – hospital day 5 (after first intubation): rapidly worsening and severe bilateral consolidation, D – hospital day 21 (re-intubation): diffuse bilateral airspace opacification, E – 1 month follow up: diffuse bilateral reticulations, right sided hydropneumothorax, corticosteroids ceased, F – deterioration at 3 months post discharge: recurrence of bilateral airspace opacification and small left pleural effusion.

frequently, multilobar changes [8]. Diagnosis is usually by serology testing, with a fourfold rise between acute and convalescent sera at least 2 weeks apart considered significant [9]. PCR and monoclonal antibody techniques have also been developed [10]. Culture is not recommended due to the highly infectious nature of *C. psittaci* [10].

Tetracycline therapy is recognised as first line treatment for psittacosis [11], with a duration of generally 7–14 days [3,11]. Doxycycline (100mg BD) often produces a rapid response, with patients usually

becoming afebrile and defervescing by 48 hours [4]. Even for severe cases, improvement is usually seen once tetracycline therapy is commenced. A recent case review of nine patients in China with severe psittacosis pneumonia found all patients' fevers generally subsided within three days after commencing minocycline therapy, and their respiratory function gradually improved [12]. This is in contrast to our case, where the patient continued to deteriorate despite doxycycline treatment and progressed to suspected organizing pneumonia.



**Fig. 3.** Serial chest computed tomography; A – hospital day 2: consolidation left lower lobe with moderate pleural effusion, B – hospital day 5: severe bilateral consolidation with bilateral pleural effusions, C – hospital day 17 and D – hospital day 19: both show worsening airspace consolidation with areas of ground-glass appearance, migratory infiltrates and pleural effusions, E – 1 month follow up: improvement in the extent of consolidation, moderately pronounced bilateral pulmonary infiltrates, new areas of subpleural opacity in both upper lobes, loculated right sided hydropneumothorax likely secondary to a bronchopleural fistula.

We believe the commencement of corticosteroid therapy was significant in improving our patient's clinical recovery. There is limited data on the role of corticosteroids in severe psittacosis. Compared to other Chlamydiales species, *C. psittaci* is more pathogenic and causes a more severe inflammatory reaction [13]. Given the role of inflammation, it is reasonable corticosteroid therapy may offer some benefit. Price & Harrison [14] described a case of severe psittacosis pneumonia complicated by severe restrictive lung function, which subsequently

resolved with a weaning course of prednisone (Table 2). Two Japanese case reports documented the successful treatment of fulminant psittacosis with simultaneous administration of minocycline and corticosteroids [15,16]. Interestingly, another Japanese report of severe psittacosis found despite starting corticosteroids early for suspicion of cryptogenic organizing pneumonia (COP), significant improvement was not seen until minocycline was commenced [17]; whilst in another case despite antibiotics, corticosteroids were required for clinical

**Table 1**  
Investigations performed for atypical pneumonia aetiologies.

Investigation	Result
<b>Polymerase chain reaction (PCR)</b>	
Chlamydia pneumoniae DNA	Negative
Chlamydia psittaci DNA	Detected
Legionella longbeachae DNA	Negative
Legionella pneumophila DNA	Negative
Mycoplasma pneumoniae PCR	Negative
<b>Serology</b>	
Brucella abortus-V	<20
Leptospirosis IgM-V	<1.0
Q fever IgM index-V	<0.9
Q fever ph2 IgG EIA	<0.9
Mycoplasma IgG ind-V	Non-reactive
Mycoplasma IgM ind-V	Non-reactive
<b>C. psittaci immunofluorescence</b>	
Initial titre (hospital day 11)	256
Repeat titre (hospital day 38)	512

improvement [18] (Table 2).

In our case, the response to prednisone was gradual and raises the question whether earlier and more aggressive treatment may have been beneficial. Corticosteroid use is associated with reduced mortality for critically ill patients with COVID-19 [19], though the optimal dose and duration is not known, with a recent meta-analysis finding similar benefits with both dexamethasone and hydrocortisone, and no evidence suggesting higher doses are associated with greater benefit compared with lower doses [19]. For patients with persistent COP, oral corticosteroids usually produce a rapid improvement, with 12 studies (total of 160 patients) showing a complete response to prednisone in 60 % and a partial response in 27 % [20]. Additionally, intravenous therapy with methylprednisolone may be appropriate in cases of rapidly progressive

and extensive COP [20], though this is recommended after infection is excluded. Whether the use IV therapy or the commencement of corticosteroids earlier in admission may have avoided further deterioration in our case is not clear. Prednisone was continued for 11 weeks and at follow up the patient was found to have ongoing lung infiltrates, though with marked improvement to previous. Overall, given the severity of our patient's disease, we believe the use of prednisone was significant in his initial discharge from hospital, giving him time with family prior to his re-admission and unfortunate death.

### 3. Conclusion

In conclusion, severe pneumonia is a rare complication of psittacosis, and in cases with limited response to tetracyclines, it may be useful to consider the use of corticosteroids early in therapy. This is an area which requires further research to determine the best therapy for severe psittacosis to optimise patient outcomes.

### 4. Consent to publish

Written informed consent was obtained from the patient's partner for publication of this Case Report and any accompanying images. A copy of the written consent is available for review by the Co-Editors-in-Chief of this journal.

### Funding

This research did not receive any specific grant from funding agencies in the public, commercial, or not-for-profit sectors.

### Declaration of competing interest

The authors declare that they have no competing interests, financial or otherwise.

**Table 2**  
Case reports of severe psittacosis and use of corticosteroids.

Age/ Sex	Risk factors	Clinical features	Diagnosis	Treatment	MV	Year/ Ref
53 F	Eviscerated 4 ducks 10 days before admission	Dyspnea Night sweats	Serology 4 weeks after admission	Initially ampicillin, cloxacillin, gentamicin Oxytetracycline started day 26 of admission as not improving Prednisone started day 33 for suspicion of post-infective alveolitis – tapered over 4.5 months	Yes	1982 [14]
65 M	No contact history with birds	Shock Altered consciousness Hypothermia Multiple organ dysfunction	Positive sputum PCR and serology day 6 of admission	Initially flomoxef, followed by imipenem/cilastatin After diagnosis, IV erythromycin High-dose methylprednisolone started day 39 of admission for ARDS	Yes	2004 [18]
40 F	Cared for 2 budgerigars which died 1 week before admission	Severe dyspnea Cough	Serology day 10 of admission Confirmed with isolation of <i>C. psittaci</i> from throat swab	IV minocycline day 1 admission due to high clinical suspicion of psittacosis and corticosteroids for ARDS – weaned after 2 weeks	Yes	1989 [15]
52 F	Parakeet recent died at patient's home	Fever High fever Non-productive cough General fatigue	Serology, diagnosed after bird history known	Initially cefpirom, followed by methylprednisolone and then prednisolone for suspicion of COP Minocycline commenced later after bird history obtained	Yes	2007 [17]
47 F	Hundreds of parrots and budgerigars at home	Fever Non-productive cough	Serology day 17 of admission	Commenced on methylprednisolone and minocycline day 2 of admission	Yes	1988 [16]

F: female, M: male, PCR: polymerase chain reaction, ARDS: acute respiratory distress syndrome, COP: cryptogenic organizing pneumonia, MV: mechanical ventilation.

## References

- [1] L. Hogerwerf, B. De Gier, B. Baan, Van Der Hoek W. Chlamydia psittaci (psittacosis) as a cause of community-acquired Pneumonia: a systematic review and meta-analysis, *Epidemiol. Infect.* 145 (15) (2017) 3096–3105.
- [2] J. Mair-Jenkins, T. Lamming, A. Dziadosz, D. Flecknoe, T. Stubington, M. Mentasti, et al., A psittacosis outbreak among English office workers with little or no contact with birds, *PLoS Curr* 2018 (10) (August 2015) 646.
- [3] A.J. Stewardson, M.L. Grayson, Psittacosis. *Infect Dis Clin North Am.* 24 (1) (2010) 7–25.
- [4] A.P. Yung, M.L. Grayson, Psittacosis - a review of 135 cases, *Med. J. Aust.* 148 (5) (1988) 228–233.
- [5] J. Schmähmann, Psittacosis centenary – “pneumotyphus” reviewed, *S. Afr. Med. J.* 62 (24) (1982) 898–901.
- [6] J. Moroney, R. Guevara, C. Iverson, F. Chen, S. Skelton, T. Messmer, et al., Detection of chlamydiosis in a shipment of pet birds, leading to recognition of an outbreak of clinically mild psittacosis in humans, *Clin. Infect. Dis.* 26 (6) (1998) 1425–1429.
- [7] P. Verweij, J. Meis, R. Eijk, W. Melchers, J. Galama, Severe human psittacosis requiring artificial ventilation: case report and review, *Clin. Infect. Dis.* 20 (2) (1995) 440–442.
- [8] S. Sahn, Pleural effusions in the atypical pneumonias, *Semin. Respir. Infect.* 3 (4) (1988) 322–334.
- [9] K. Smith, K. Bradley, M. Stobierski, L. Tengelsen, Committee NA of SPHVP. Compendium of measures to control Chlamydia psittaci (formerly Chlamydia psittaci) infection among humans (psittacosis) and pet birds, *J Am Vet Med Assoc.* 2005 226 (4) (2005) 532–539.
- [10] A. Nieuwenhuizen, F. Dijkstra, D. Notermans, W. Van Der Hoek, Laboratory methods for case finding in human psittacosis outbreaks: a systematic review, *BMC Infect. Dis.* 18 (1) (2018) 442.
- [11] D. Beekman, D. Vanrompay, Zoonotic Chlamydia psittaci infections from a clinical perspective, *Clin. Microbiol. Infect.* 15 (1) (2009) 11–17.
- [12] X. Chen, K. Cao, Y. Wei, Y. Qian, J. Liang, D. Dong, et al., Metagenomic next-generation sequencing in the diagnosis of severe pneumonias caused by Chlamydia psittaci, *Infection* 48 (4) (2020) 535–542.
- [13] M. Knittler, K. Sachse, Chlamydia psittaci: update on an underestimated zoonotic agent, *Pathog Dis* 73 (1) (2015) 1–15.
- [14] M.E. Price, B.D.W. Harrison, Restrictive pattern of lung function following psittacosis treated with corticosteroids, *Br. J. Dis. Chest* 76 (C) (1982) 199–201.
- [15] N. Chonabayashi, T. Nakatani, M. Otani, M. Noguchi, Y. Yoshimura, Y. Nakamori, et al., [Successful treatment of a patient with fulminant psittacosis], *Nihon Kyobu Shikkan Gakkai Zasshi* 27 (3) (1989) 357–366.
- [16] M. Hirata, M. Noto, K. Oda, Y. Tofuku, R. Takeda, S. Kitagawa, [A case of psittacosis presenting as adult respiratory distress syndrome and successfully treated with steroid pulse therapy], *Kokyu Junkan* 36 (8) (1988) 898, 897.
- [17] T. Okubo, E. Miyazaki, M. Ueo, F. Okubo, M. Ando, T. Fukami, et al., [A case of psittacosis with wandering infiltrates developing to acute respiratory distress syndrome], *Nihon Kyobu Shikkan Gakkai Zasshi* 45 (5) (2007) 419–423.
- [18] M. Toyokawa, T. Kishimoto, Y. Cai, M. Ogawa, S. Shiga, I. Nishi, et al., Severe Chlamydia psittaci pneumonia rapidly diagnosed by detection of antigen in sputum with an immunochromatography assay, *J. Infect. Chemother.* 10 (4) (2004) 245–249.
- [19] WHO Rapid Evidence Appraisal for COVID-19 Therapies (REACT) Working Group, J. Sterne, S. Murphy, J. Diaz, Association between administration of systemic corticosteroids and mortality among critically ill patients with COVID-19: a meta-analysis, *JAMA, J. Am. Med. Assoc.* 324 (13) (2020) 1330–1341.
- [20] B. Bradley, H. Branley, J. Egan, M. Greaves, D. Hansell, N. Harrison, et al., Interstitial lung disease guideline: the British thoracic society in collaboration with the thoracic society of Australia and New Zealand and the Irish thoracic society, *Thorax* 63 (11) (2008) 1029.