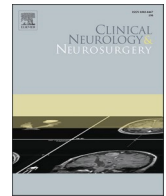




Since January 2020 Elsevier has created a COVID-19 resource centre with free information in English and Mandarin on the novel coronavirus COVID-19. The COVID-19 resource centre is hosted on Elsevier Connect, the company's public news and information website.

Elsevier hereby grants permission to make all its COVID-19-related research that is available on the COVID-19 resource centre - including this research content - immediately available in PubMed Central and other publicly funded repositories, such as the WHO COVID database with rights for unrestricted research re-use and analyses in any form or by any means with acknowledgement of the original source. These permissions are granted for free by Elsevier for as long as the COVID-19 resource centre remains active.



Case report

Guillain-Barré syndrome after AstraZeneca COVID-19-vaccination: A causal or casual association?

Alessandro Introna^{*,1}, Francesca Caputo¹, Carlo Santoro, Tommaso Guerra, Maria Ucci, Domenico Maria Mezzapesa, Maria Trojano

Department of Basic Medical Sciences, Neurosciences and Sense Organs, University of Bari "Aldo Moro", piazza Giulio Cesare 11, 70100 Bari, Italy



ARTICLE INFO

Keywords:

Guillain-Barré syndrome
COVID-19
Vaccine
AstraZeneca

ABSTRACT

We report a case of Guillain-Barré syndrome (GBS) following the first dose of Oxford/AstraZeneca COVID-19 vaccine with papilledema as atypical onset. As the COVID-19 vaccination campaign progresses worldwide, GBSs vaccine-related have been increasingly reported. After reviewing the available literature, considering the annual incidence of GBS, in this historical moment, the public health systems cannot afford an unjustified distrust in vaccines, caused by misinterpretation of epidemiological data. Nonetheless, it is important for clinicians to promptly recognize neurological complications potentially associated with COVID-19 vaccinations and report them to pharmacovigilance agencies.

1. Introduction

Guillain-Barré syndrome (GBS) is an acquired inflammatory polyradiculoneuropathy that frequently occurs after recent infections [1]. GBS has been described during or after severe acute respiratory syndrome coronavirus 2 (SARS-CoV-2) infection. Moreover, GBS is also associated with any vaccination [1]. As the COVID-19 vaccination campaign progresses worldwide, GBSs vaccine-related have been increasingly reported. GBS with time-closely association to COVID-19 vaccinations has been described for both messenger-RNA vaccine [2] and adenovirus-vectored COVID-19 vaccine [3–5]. Herein, we report a case of GBS following the first dose of Oxford/AstraZeneca COVID-19 vaccine with visual impairment as atypical onset.

2. Case report

A 62-year-old Caucasian man with a previous medical history relevant for blood pressure hypertension referred to Emergency Department because of the onset of visual discomfort lasting from two days. His neurological examination was normal except for absent deep tendon reflexes and severe bilateral optic disc edema on fundus examination. Ten days before symptoms onset he received the first dose of the chimpanzee adenovirus-vectored COVID-19 vaccine, ChAdOx1. No previous flu-like or gastrointestinal episodes were reported.

Nasopharyngeal SARS-CoV2 swab tested negative. Brain computed tomography scan with multiphasic and venous angiography and magnetic resonance imaging (MRI) with venous angiography were normal. His hospitalization was complicated by lower back pain and then progressively worsening sensory ataxia. Three days after the admission, his neurological examination revealed a new ascending tetraparesis with proximal predominant involvement (MRC sum-score 34/80), bilateral facial weakness, dysphagia, urinary retention, and distal paresthesia. Spinal cord MRI comprehensive of STIR and post contrast T1-weighted images was normal. Cerebrospinal fluid (CSF) examination showed albumin-cytologic dissociation (total protein count 101 mg/dl, five white blood cells) with high opening pressure (29 cms H₂O) and normal glucose at day-six from symptoms onset. Real-time PCR for herpes simplex virus, varicella-zoster, cytomegalovirus, Epstein-Barr virus, enterovirus and adenovirus and CSF microscopy and culture were negative. Serology for *Campylobacter jejuni*, *Mycoplasma pneumoniae*, Lyme syphilis and human immunodeficiency virus were normal. Four days after admission electrophysiologic study showed severe sensorimotor mixed polyneuropathy (demyelination with predominant axonal changes) (see Table 1). Needle electromyography did not show pattern of acute denervation. The antiganglioside antibodies test (line blot assay, Generic Assay GmbH - Dahlewitz, Germany) was positive for IgG GM1 (titer 39). A GBS diagnosis was performed and modified Erasmus GBS outcome score- (mEGOS) was 8. Intravenous immunoglobulins (2

* Corresponding author.

E-mail address: ale.introna@gmail.com (A. Introna).¹ These authors contributed equally.

g/kg over 5 days) were promptly started. On day two of therapy, the patient developed severe euvoletic hyponatremia, suggesting a syndrome of inappropriate antidiuretic hormone secretion (SIADH), autonomic dysfunction with the onset of high-frequency atrial fibrillation and progressively respiratory distress, requiring intensive care assistance, with Erasmus GBS respiratory insufficiency score of 4. On the seventh day after the start of the intravenous immunoglobulin treatment, the neurological examination remarkably improved: bilateral facial weakness persisted with mild proximal paraparesis (MRC sum-score 50/80, mEGOS 5). At four weeks the patient was bedridden (GBS disability scale 4) and continued his recovery in the rehabilitation unit.

3. Discussion

GBS is an acute immune-mediated disease of peripheral nerves that is usually triggered by infections: the commonest triggering infections include *Campylobacter jejuni*, cytomegalovirus, Epstein-Barr virus, influenza, *Mycoplasma pneumoniae*, the flaviviruses Zika and dengue, and the alphavirus chikungunya [1]. Based on previous epidemic outbreak, namely Zika virus epidemic in Latin America which caused a sharp rise in cases of GBS confirmed by strict epidemiological analysis, the possibility of an increasing global GBS incidence has been expected. Even if a recent epidemiological study failed to find a sure causal link between GBS and COVID-19 [6], there are several pieces of evidence suggesting that COVID-19-associated GBS seems to share most features of classic post-infectious GBS and possibly the same immune-mediated pathogenetic mechanisms.

Although cases of GBS have been described after Hepatitis B, tetanus, polio, meningitis, rabies and orally administered adenovirus vaccines, possible association between GBS and vaccines has been assumed after H1N1 swine flu vaccination campaign in 1976, and again but with less evidence in 2009; some authors instead suggested that published case reports may represent coincidental temporal associations rather than casual associations.

Considering the global COVID-19 vaccination campaign which is considered the largest in the history of humanity, neurologists should

eagerly monitor and report GBS potentially related to it. To our best knowledge, few cases of GBS have been reported closely after the first dose of any COVID-19 vaccines.²⁻⁵ and many others have been reported to pharmacovigilance agencies without literature reporting (http://www.adrreports.eu/en/search_subst.html). Recently, two independently case series of GBS after first dose of ChAdOx1 have highlighted some recurrent characteristics, such as the severe bilateral facial paresis, as in the abovementioned case. Considering that COVID-19 vaccines induce immunization against SARS-CoV-2 spike proteins and SARS-CoV-2 spike protein can bind to sialic acid-containing glycoprotein and gangliosides on cell surfaces [6], an antibody cross-reaction may be the casual link between GBS and immunization to SARS-CoV-2. Since SARS-CoV-2 infection seems to be not related to a particular increase of GBS incidence [7], as happened in the case of Zika virus epidemic, we cannot conclude for a certain causal link between COVID-vaccine and GBS. Moreover, from a statistical point-of-view, considering an annual global incidence of 1–2 per 100,000 persons-years [1] and an auspicious vaccination campaign of 5 billion persons, only by chance we could expect about 10,000–20,000 GBS in any 10-week period, including the four weeks between the two doses of vaccine. Thus is inevitable that many thousands of sporadic cases of GBS caused by other non-evident factors will appear temporally associated with COVID-19 vaccination. In this historical moment, the public health systems cannot afford an unjustified distrust in vaccines, caused by misinterpretation of epidemiological data.

Nonetheless, it is important for clinicians to promptly recognize neurological complications potentially associated with COVID-19 vaccinations and report them to pharmacovigilance agencies.

Indeed, the pharmacovigilance surveillance allowed to recognize the new disease-entity of thrombosis with thrombocytopenia syndrome (TTS), also known as vaccine-induced immune thrombotic thrombocytopenia (VITT), caused by ChAdOx1 nCov-19 vaccine.

Considering the absence at the beginning of clues of sensorimotor ascending symptoms and given the previous history of ChAdOx1 nCov-19 vaccination, a neurologist might have pointed as the cause of bilateral papilledema a condition of intracranial hypertension (IH) due to cerebral venous thrombosis in the context of TTS. Indeed, the present

Table 1
Electrophysiological study.

Nerve	Stimulation point	Record point	Latency, ms	Amplitude, mV	Velocity, m/s	F wave minimal latency, ms
Motor NCS						
Median (L)	Wrist	APB	absent	absent	absent	
	Elbow	APB				
Median (R)	Wrist	APB	absent	absent	absent	
	Elbow	APB				
Ulnar (L)	Wrist	ADM	3.1 (3.2 ± 0.5)	11.1 (6.4 ± 1.9)		28.4 (30.5 ± 3.0)
	Elbow	ADM		10.1 (5.6 ± 2.0)	45.5 (61.8 ± 5.0)	
Ulnar (R)	Wrist	ADM	3.7 (3.2 ± 0.5)	5.2 (6.4 ± 1.9)		
	Elbow	ADM		6.0 (5.6 ± 2.0)	44.8 (61.8 ± 5.0)	31.1 (30.5 ± 3.0)
Peroneal (L)	Ankle	EDB	absent	absent	absent	
	Head of fibula	EDB				
Peroneal (R)	Ankle	EDB	absent	absent	absent	
	Head of fibula	EDB				
Tibial (R)	Ankle	AH	9.6 (3.8 ± 0.5)	1.3 (15 ± 3.2)	33.0 (54.9 ± 7.6)	absent
	Knee	AH		0.9		
Tibial (L)	Ankle	AH	absent	absent	absent	
	Knee	AH				
Antidromic sensory NCS						
Median (L)	Wrist	2nd digit	absent	absent	absent	
Ulnar (R)	Wrist	5th digit	absent	absent	absent	
Ulnar (L)	Wrist	5th digit	absent	absent	absent	
Sural (L)	Calf	Lat. Malleolus	2.3 (3.5 ± 0.2)	22.7 (5–30)	41.3 (46 ± 0.5)	
Superf. Peroneal (L)	Leg	Foot	2.50 (3.4 ± 0.4)	12.8 (18.3 ± 8.0)	40 (51.2 ± 5.7)	

Motor nerve conduction study: increased distal motor latency and slowing in the right ulnar nerve and right tibial nerve (with reduction of CMAP amplitude in the right tibial nerve), and slight slowing in the left ulnar nerve (with normal amplitude of the CMAP). Absence of CMAP of the left and right median nerve, left and right peroneal nerve and left tibial nerve. Absence of F wave in the right tibial nerve. Normal F wave minimal latency in the left and right ulnar nerve. Sensory nerve conduction study: absence of SNAP of the right and left ulnar nerve and left median nerve. Slowing in the left sural nerve and left superficial peroneal nerve

case had a troublesome onset that might have led to a misdiagnosis. Bilateral papilledema is a rare complication of GBS mainly described in younger women or children and even more rarely is reported as presenting symptom of GBS [8].

In literature, GBS associated to papilledema had an higher concentration of CSF protein and intracranial hypertension (IH); some had involvement of cranial nerves and frequently tested positive for anti-ganglioside antibodies [8]. In Johnson & Johnson phase 3 clinical trial for COVID-19 vaccine, the GBS presented with an increased opening CSF pressure and the patient suffered from multiple cranial nerves palsy too without mention of papilledema [3]. Several mechanisms have been proposed to explain the association of papilledema to GBS, among which the most truthful seem to be an impairment of the CSF reabsorption by arachnoid villi due to the high CSF protein level and an immunological dysfunction [8]. If the high level of CSF protein was responsible for the high CSF opening pressure, we would have a disproportionate incidence of IH-related symptoms considering that hyperproteinorachia is a cardinal finding in GBS patients. Therefore, it could be hypothesized that GBS with IH-related symptoms could have a different immunological framework than those with a typical presentation [8]. One could speculate that viral-vectored vaccines may have triggered a systemic immunological reaction through molecular mimicry mechanisms [6], which may explain previously assumed association giving a specific “immunological signature” to GBS induced by COVID-19 vaccine. The few described cases are obviously not able to give us a statistical significance, so in the future it is urgent to pay attention to an underestimated parameter of CSF during the diagnostic workup of a GBS, namely the opening pressure, to confirm or refuse this association.

4. Conclusion

As physicians, we are called to report potentially related complications of COVID-19 vaccine, without forgetting the benefit of vaccination.

Ethical standard

Informed consent was obtained from the patient. The case was reported to AIFA.

Funding

Nothing to report.

Author contributions

AI, FC and MT conceptualized the study, had full access to all data and take responsibility for the integrity of the data. AI, FC, CS and DM contributed to the writing of the manuscript. All the authors contributed to the data interpretation and reviewed and approved the final version.

Declaration of Competing Interest

Nothing to report.

References

- [1] S.E. Leonhard, M.R. Mandarakas, F.A.A. Gondim, K. Bateman, M.L.B. Ferreira, D. R. Cornblath, P.A. van Doorn, M.E. Dourado, R.A.C. Hughes, B. Islam, S. Kusunoki, C.A. Pardo, R. Reisin, J.J. Sejvar, N. Shahrizaila, C. Soares, T. Umaphathi, Y. Wang, E. M. Yiu, H.J. Willison, B.C. Jacobs, Diagnosis and management of Guillain-Barré syndrome in ten steps, *Nat. Rev. Neurol.* 15 (11) (2019) 671–683.
- [2] S. Waheed, A. Bayas, F. Hindi, Z. Rizvi, P.S. Espinosa, Neurological complications of COVID-19: Guillain-Barré syndrome following Pfizer COVID-19 vaccine, *Cureus* 13 (2) (2021), 13426. Published 2021 Feb 18.
- [3] Alejandra M. Márquez Loza, Kathryn B. Holroyd, Stephen A. Johnson, David M. Pilgrim, Anthony A. Amato, Guillain-Barré syndrome in the placebo and active arms of a COVID-19 vaccine clinical trial: temporal associations do not imply causality, *Neurology* 10 (2021).
- [4] B.V. Maramattom, P. Krishnan, R. Paul, S. Padmanabhan, S. Cherukudal Vishnu Nampoothiri, A.A. Syed, H.S. Mangat, Guillain-Barré syndrome following ChAdOx1-S/nCoV-19 vaccine, *Ann. Neurol.* 90 (2021 10) 312–314, <https://doi.org/10.1002/ana.26143>.
- [5] C.M. Allen, S. Ramsamy, A.W. Tarr, P.J. Tighe, W.L. Irving, R. Tanasescu, J.R. Evans, Guillain-Barré syndrome variant occurring after SARS-CoV-2 vaccination, *Ann. Neurol.* 90 (2021 10) 315–318.
- [6] X.L. Sun, The role of cell surface sialic acids for SARS-CoV-2 infection, *cwab032*, *Glycobiology* (2021 28), <https://doi.org/10.1093/glycob/cwab032>.
- [7] S. Keddie, J. Pakpoor, C. Mousele, M. Pipis, P.M. Machado, M. Foster, C.J. Record, R. Keh, J. Fehmi, R.W. Paterson, V. Bharambe, L.M. Clayton, C. Allen, O. Price, J. Wall, A. Kiss-Csenki, D.P. Rathnasabapathi, R. Geraldles, T. Yermakova, J. King-Robson, M. Zosmer, S. Rajakulendran, S. Sumaria, S.F. Farmer, R. Nortley, C. R. Marshall, E.J. Newman, N. Nirmalanathan, G. Kumar, A.A. Pinto, J. Holt, T. M. Lavin, K.M. Brennan, M.S. Zandi, D.L. Jayaseelan, J. Pritchard, R. Hadden, H. Manji, H.J. Willison, S. Rinaldi, A.S. Carr, M.P. Lunn, Epidemiological and cohort study finds no association between COVID-19 and Guillain-Barré syndrome, *awaa433*, *Brain* 144 (2021) 682–693, <https://doi.org/10.1093/brain/awaa433>.
- [8] T. Wang, Z. Wang, Z. Guo, Headache and intracranial hypertension in Guillain-Barré syndrome: a case report and literature review, *Int J. Neurosci.* 129 (12) (2019) 1179–1182.