

Lesion reduction with intralesional deoxycholic acid in Dercum disease with radiographic evidence



Shauna Rice, BS,^a Renata Dalla Costa, MD,^b Joseph Caravaglio, MD,^b and A. Shadi Kourosh, MD, MPH^{a,b,c}
Boston, Massachusetts and Providence, Rhode Island

Key words: adipolysis; adiposis dolorosa; deoxycholic acid; Dercum disease; lipoma; ultrasound.

INTRODUCTION

Dercum disease, also known as adiposis dolorosa, is a rare disorder characterized by multiple painful lipomas most often arising in women aged 35 to 50 years.¹ There are currently no approved treatments for Dercum disease. Therapies tried with variable efficacy for symptom management include analgesics, excision, and liposuction.¹ For patients who continually develop widespread lesions, surgical excision is not feasible, posing a conundrum for patients and providers. Thus, the development of effective, less invasive therapies is needed.

In this report, we suggest the use of intralesional deoxycholic acid (DCA) to mitigate pain and lipoma size in patients with Dercum disease and demonstrate radiographic evidence of the success of lipoma reduction in a patient.

CASE REPORT

A 45-year-old woman with Dercum disease underwent administration of 2 mL DCA (10 mg/mL) to a 1.64-cm × 0.55-cm × 1.63-cm painful lipoma in her left forearm (Figs 1 and 2). A 1.3-cm × 1.2-cm × 0.4-cm lipoma of the right wrist was monitored as an untreated control. After the procedure, the patient reported 1 week of swelling and tenderness of the treated area. Repeat imaging performed 4 months later demonstrated a reduction of the treated lesion to 1.48 cm × 0.60 cm × 0.80 cm (Fig 3) and the growth of the untreated lesion to 2.17 cm × 1.32 cm × 0.52 cm. Measurements were reviewed by 3 radiologists for consensus. The patient also reported decreased pain in the treated area at the 4-month follow-up.

Abbreviation used:

DCA: deoxycholic acid

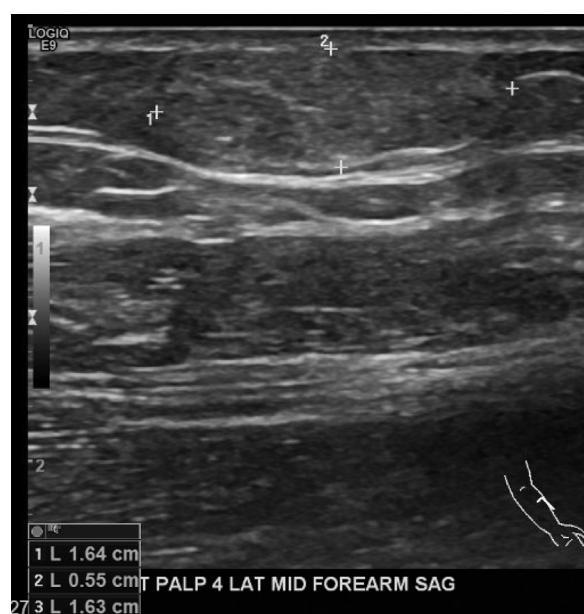


Fig 1. Lipoma of the volar aspect of the left forearm of a patient with Dercum disease before treatment.

DISCUSSION

DCA, when injected subcutaneously, disrupts cell membranes in adipocytes and destroys fat cells.² DCA is currently approved to treat submental fat but has been increasingly explored for its off-label utility in nonsurgical body contouring and lipoma

From the Department of Dermatology, Massachusetts General Hospital, Boston^a; Department of Dermatology, Brown University, Providence^b; and Harvard Medical School, Boston.^c

Funding sources: None.

IRB approval status: Not applicable.

Correspondence to: Shauna Rice, BS, Department of Dermatology, Massachusetts General Hospital, 55 Fruit St, BAR 622, Boston, MA 02114. E-mail: shaunamrice@gmail.com.

JAAD Case Reports 2021;15:73-5.

2352-5126

© 2021 by the American Academy of Dermatology, Inc. Published by Elsevier, Inc. This is an open access article under the CC BY-NC-ND license (<http://creativecommons.org/licenses/by-nc-nd/4.0/>).

<https://doi.org/10.1016/j.jdc.2021.07.009>

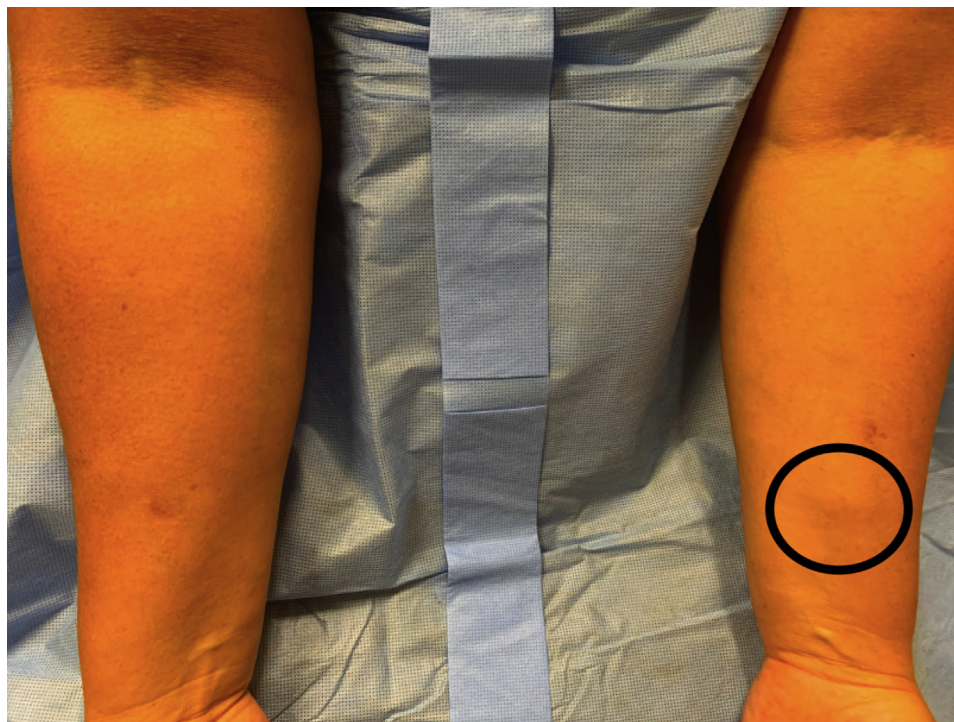

Fig 2. Clinical image of lipoma before treatment.

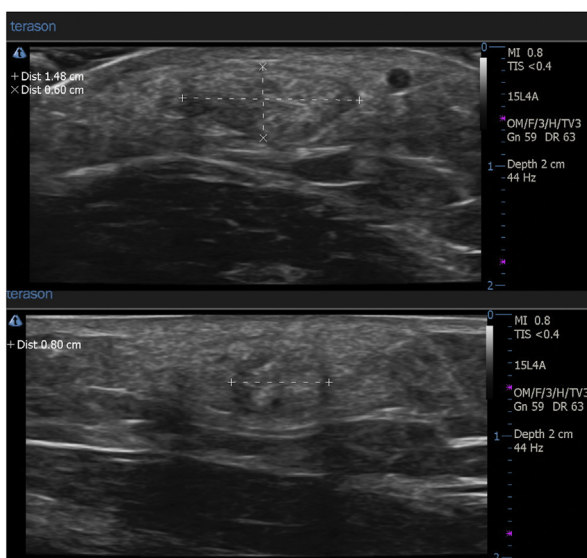


Fig 3. Lipoma of the volar aspect of the left forearm of a patient with Dercum disease 4 months after treatment with deoxycholic acid showed approximately 1-cm reduction in the size.

reduction.³ Isolated reports of lipoma treatment using DCA in the literature range from 30% to 100% reduction in size, with evidence of fat necrosis on pathology supporting the role of DCA in facilitating lipolysis of the tumor.³ DCA has been attempted in 1 case of suspected Dercum disease, with a reduction in pain of a 6-cm lipoma that was injected in the

abdomen but without clinically appreciable change, and no objective measurements were taken.⁴ It is possible that 1 treatment session might be insufficient given the size of that lipoma, as larger treatment areas seen in body contouring often require multiple treatments to appreciate results.

In our patient, ultrasound measurements were used to track treatment progress. The 0.8-cm reduction in the longitudinal axis of the lesion after only 1 treatment suggests the efficacy of intralesional DCA in reducing lipoma size in Dercum disease. It is possible that the size reduction was even greater than 0.8 cm, given that the original radiographic measurements were taken several months prior to treatment and the untreated lipoma nearly doubled in size during that period. Although excision may be used intermittently, it is not a solution for patients with multiple lesions that continuously develop. Thus, intralesional DCA could offer a minimally invasive solution to reduce lipomas and disease burden, particularly in patients with extensive disease. Further studies are required to determine appropriate dosing and safety recommendations.

Conflicts of interest

None disclosed.

REFERENCES

1. Kucharz EJ, Kopeć-Mędrak M, Kramza J, Chrzanowska M, Kotyla P. Dercum's disease (adiposis dolorosa): a review of

- clinical presentation and management. *Reumatologia*. 2019; 57(5):281-287.
2. National Center for Biotechnology Information. PubChem Compound Summary for CID 222528, Deoxycholic acid. Accessed July 3, 2021. <https://pubchem.ncbi.nlm.nih.gov/compound/Deoxycholic-acid>
 3. Dubin DP, Farberg AS, Lin MJ, Khorasani H. Intralesional deoxycholic acid as neoadjuvant treatment of a large lipoma. *Dermatol Surg*. 2020;46(5):715-717.
 4. Wipf A, Lofgreen S, Miller DD, Farah RS. Novel use of deoxycholic acid for adiposis dolorosa (Dercum disease). *Dermatol Surg*. 2019;45(12):1718-1720.