

## Complete withdrawal of glucocorticoids after dupilumab therapy in allergic bronchopulmonary aspergillosis: A case report

Tadashi Nishimura, Tomohito Okano, Masahiro Naito, Chikashi Tsuji, Soichi Iwanaka, Yasumasa Sakakura, Taro Yasuma, Hajime Fujimoto, Corina N D'Alessandro-Gabazza, Yasuhiro Oomoto, Tetsu Kobayashi, Esteban C Gabazza, Hidenori Ibata

**ORCID number:** Tadashi Nishimura 0000-0002-1688-1602; Tomohito Okano 0000-0002-1570-4233; Masahiro Naito 0000-0002-0097-3537; Chikashi Tsuji 0000-0003-2782-0052; Soichi Iwanaka 0000-0003-0396-3892; Yasumasa Sakakura 0000-0002-3812-1794; Taro Yasuma 0000-0002-9117-5679; Hajime Fujimoto 0000-0002-4141-0538; Corina N D'Alessandro-Gabazza 0000-0003-2164-5775; Yasuhiro Oomoto 0000-0001-7128-5072; Tetsu Kobayashi 0000-0003-4397-6137; Esteban C Gabazza 0000-0003-2536-898X; Hidenori Ibata 0000-0002-0006-3605.

**Author contributions:** Nishimura T, Okano T, Tsuji C, Iwanaka S, and Sakakura Y were responsible for clinical treatment and clinical follow-up and manuscript preparation; Naito M, Ibata H, and Oomoto Y contributed with resources and acquisition of data; Fujimoto H, D'Alessandro-Gabazza CN, Yasuma T, Kobayashi T, and Gabazza EC contributed to interpreting the data and made an intellectual contribution to the manuscript's preparation. All Authors reviewed and approved the final manuscript.

**Informed consent statement:**

Informed consent was obtained from the subject involved in the study.

**Tadashi Nishimura, Masahiro Naito, Chikashi Tsuji, Soichi Iwanaka, Yasumasa Sakakura, Yasuhiro Oomoto, Hidenori Ibata,** Department of Pulmonary Medicine, Mie Chuo Medical Center, Tsu 514-1101, Mie, Japan

**Tomohito Okano, Hajime Fujimoto,** Department of Pulmonary and Critical Care Medicine, Mie University, Tsu 514-8507, Mie, Japan

**Taro Yasuma, Corina N D'Alessandro-Gabazza, Esteban C Gabazza,** Department of Immunology, Mie University School of Medicine, Mie University, Tsu 514-8507, Mie, Japan

**Tetsu Kobayashi,** Department of Pulmonary and Critical Care Medicine, Graduate School of Medicine Mie, Mie University, Tsu 514-8507, Mie, Japan

**Corresponding author:** Esteban C Gabazza, MD, PhD, Director, Full Professor, Department of Immunology, Mie University School of Medicine, Mie University, Edobashi 2-174, Tsu 514-8507, Japan. [gabazza@doc.medic.mie-u.ac.jp](mailto:gabazza@doc.medic.mie-u.ac.jp)

### Abstract

#### BACKGROUND

Allergic bronchopulmonary aspergillosis (ABPA) is an allergic reaction to *Aspergillus* species that aggravates bronchial asthma. Previous studies demonstrated the glucocorticoid-sparing effect of dupilumab in patients with ABPA. There is no report of complete withdrawal of glucocorticoids after dupilumab.

#### CASE SUMMARY

The patient was a 54-year-old woman with bronchial asthma treated with inhaled corticosteroids and a long-acting beta-2 agonist. She consulted our institution for productive cough and fever in March 2017. Chest computed tomography scan revealed mucoid impaction, and the bronchial lavage fluid culture was positive for *Aspergillus fumigatus*. The diagnosis was ABPA. The patient was treated with oral glucocorticoids from April 2017 to November 2017. In January 2019, she had bronchial asthma exacerbation, and a chest computed tomography scan showed recurrent mucoid impaction. She was treated with oral glucocorticoids and itraconazole. In February 2020, during tapering of oral glucocorticoid, she had the third episode of bronchial asthma exacerbation and a mucoid impaction. The

**Conflict-of-interest statement:**

None of the authors declared no conflict of interest concerning this case report.

**CARE Checklist (2016) statement:**

The authors have read the CARE Checklist (2016), and the manuscript was prepared and revised according to the CARE Checklist (2016).

**Open-Access:** This article is an open-access article that was selected by an in-house editor and fully peer-reviewed by external reviewers. It is distributed in accordance with the Creative Commons Attribution NonCommercial (CC BY-NC 4.0) license, which permits others to distribute, remix, adapt, build upon this work non-commercially, and license their derivative works on different terms, provided the original work is properly cited and the use is non-commercial. See: <http://creativecommons.org/licenses/by-nc/4.0/>

**Manuscript source:** Unsolicited manuscript

**Specialty type:** Allergy

**Country/Territory of origin:** Japan

**Peer-review report's scientific quality classification**

Grade A (Excellent): 0  
Grade B (Very good): B  
Grade C (Good): C  
Grade D (Fair): 0  
Grade E (Poor): 0

**Received:** April 25, 2021

**Peer-review started:** April 25, 2021

**First decision:** June 6, 2021

**Revised:** June 8, 2021

**Accepted:** June 22, 2021

**Article in press:** June 22, 2021

**Published online:** August 16, 2021

**P-Reviewer:** Panaitescu C, Zhuo ZQ

**S-Editor:** Wu YXJ

**L-Editor:** Filipodia

**P-Editor:** Zhang YL



patient was treated with dupilumab in addition to oral glucocorticoid and itraconazole. The clinical response improved, and oral glucocorticoid was discontinued in June 2020.

**CONCLUSION**

This is the first case of ABPA in which complete withdrawal of glucocorticoid was possible after treatment with dupilumab.

**Key Words:** Allergic bronchopulmonary aspergillosis; Dupilumab; Asthma; Interleukin-13; Interleukin-4; Case report

©The Author(s) 2021. Published by Baishideng Publishing Group Inc. All rights reserved.

**Core Tip:** Allergic bronchopulmonary aspergillosis (ABPA) is an allergic reaction to antigen from *Aspergillus* species that causes exacerbation of bronchial asthma, eosinophilic pneumonia, and bronchiectasis. Conventional therapy includes the administration of oral glucocorticoids and other antiasthmatic therapy. However, there are intractable cases showing repeated clinical exacerbations of bronchial asthma despite therapy with oral glucocorticoids. Previous reports have shown that the addition of monoclonal antibodies against interleukin (IL)-4/IL-13 or dupilumab to the treatment is effective and allows the reduction in the dose of glucocorticoids in ABPA patients. However, there is no report of complete withdrawal of oral glucocorticoids after therapy with dupilumab in these patients. Here, we report the first case of ABPA in which complete withdrawal of oral glucocorticoid was possible after treatment with dupilumab.

**Citation:** Nishimura T, Okano T, Naito M, Tsuji C, Iwanaka S, Sakakura Y, Yasuma T, Fujimoto H, D'Alessandro-Gabazza CN, Oomoto Y, Kobayashi T, Gabazza EC, Ibata H. Complete withdrawal of glucocorticoids after dupilumab therapy in allergic bronchopulmonary aspergillosis: A case report. *World J Clin Cases* 2021; 9(23): 6922-6928

**URL:** <https://www.wjgnet.com/2307-8960/full/v9/i23/6922.htm>

**DOI:** <https://dx.doi.org/10.12998/wjcc.v9.i23.6922>

**INTRODUCTION**

Allergic bronchopulmonary aspergillosis (ABPA) is an allergic reaction to *Aspergillus* species[1]. ABPA causes exacerbation of bronchial asthma, eosinophilic pneumonia, and bronchiectasis[1]. Treatment of ABPA is critical for the clinical control of bronchial asthma. The administration of oral glucocorticoid alone or in combination with antifungal drugs are effective therapeutic approaches[1]. However, ABPA is highly prone to relapse when the oral glucocorticoid dose is reduced or is completely discontinued. Patients with ABPA have also been reported to respond to the treatment with anti-immunoglobulin E (IgE) or anti-interleukin (IL)-5 antibody[2-4]. However, most cases of ABPA require therapy with oral glucocorticoids to control clinical exacerbations of bronchial asthma. The oral glucocorticoid-sparing effect of anti-IL-4/IL-13 antibody (dupilumab) has been previously reported[5]. However, there is no report on the complete withdrawal of glucocorticoids following dupilumab therapy. Here, we report a case of ABPA in which glucocorticoids were completely unnecessary to control bronchial asthma exacerbation after dupilumab therapy.

**CASE PRESENTATION****Chief complaints**

The patient was a 54-year-old woman that consulted the Mie Chuo Medical Center because of fever and productive cough.

### **History of present illness**

In April 2017, she presented at the outpatient clinic of Mie Chuo Medical Center for fever and productive cough. A chest computed tomography (CT) scan revealed consolidation, ground-glass opacity, and mucoid impaction of the right upper lung (Figure 1A). The culture of the bronchial lavage fluid was positive for *Aspergillus fumigatus* (*A. fumigatus*) (Figure 1B). The anti-aspergillus antibody was positive with a serum anti-aspergillus-specific IgE concentration of 28.9 UA/mL. The diagnosis was ABPA. Treatment with oral prednisolone at a dose of 0.5 mg/kg/d was started in April 2017. The clinical symptoms of the patient improved, and the oral glucocorticoid therapy was discontinued in November 2017.

However, in January 2019, she presented again with fever and exacerbation of her bronchial asthma. The chest CT scan showed a recurrence of mucoid impaction. The CT finding improved after treating the patient with oral (0.5 mg/kg/d) glucocorticoid and oral itraconazole in January 2019. The dose of oral glucocorticoid was then gradually reduced.

However, in November 2019, she had another episode of bronchial asthma exacerbation in association with increased serum total IgE, eosinophilia, and recurrent mucoid impaction by CT scan (Figure 1C and D). In February 2020, we started treating the patient with dupilumab (300 mg/2-wk) in addition to oral glucocorticoid (0.5 mg/kg/d) and itraconazole (100 mg/d). The mucoid impaction disappeared after the combined therapy of dupilumab and oral glucocorticoid (Figure 1E and F). We continued treating the patient with dupilumab, but discontinued the administration of oral glucocorticoid in June 2020. During follow-up, the patient showed no symptoms of bronchial asthma exacerbation or recurrence of mucoid impaction. IgE levels and the eosinophil count in peripheral blood were not increased after discontinuation of oral glucocorticoids and maintenance with dupilumab (Figure 2).

### **History of past illness**

She had no medical history of any disease.

### **Personal and family history**

No history.

### **Physical examination**

The patient's physical examination showed symptoms and signs of airway obstruction.

### **Laboratory examinations**

During her first consultation, the culture of the bronchial lavage fluid was positive for *A. fumigatus* (Figure 1B), and the anti-aspergillus antibody was positive with a serum anti-aspergillus-specific IgE concentration of 28.9 UA/mL. The total serum levels of IgE (3387 IU/mL) were also increased during her second consultation.

### **Imaging examinations**

A chest CT scan revealed consolidation, ground-glass opacity, and mucoid impaction of the right upper lung (Figure 1A). During her second and third consultations for clinical exacerbation of bronchial asthma, her chest CT scan findings were compatible with a recurrence of mucoid impaction.

---

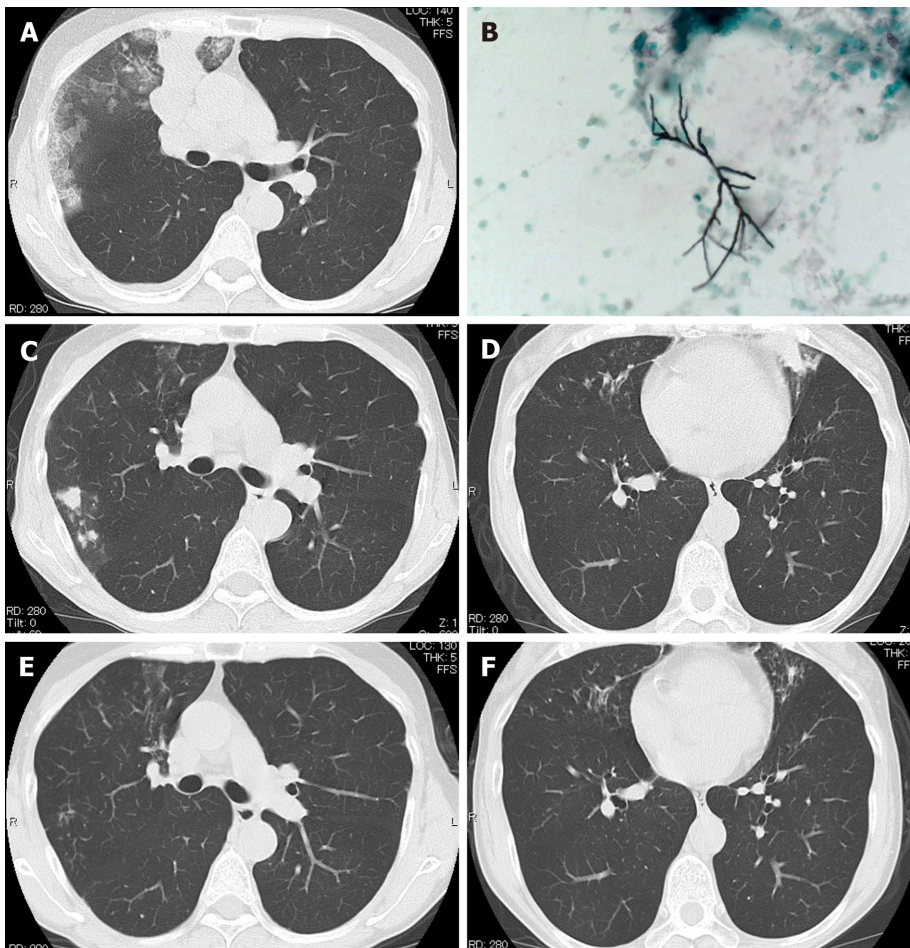
## **FINAL DIAGNOSIS**

The final diagnosis was ABPA with repeated clinical exacerbations of bronchial asthma.

---

## **TREATMENT**

The patient was initially treated with oral prednisolone at a dose of 0.5 mg/kg/d in April 2017. The clinical symptoms of the patient improved, and the oral glucocorticoid therapy was discontinued in November 2017. The patient received treatment with oral (0.5 mg/kg/d) glucocorticoid and oral itraconazole (100 mg/d) in January 2019 during her second consultation for bronchial asthma exacerbation. The dose of oral glucocorticoid was then gradually reduced. During her third episode of bronchial asthma



**Figure 1** Chest computed tomography scan. A: At presentation, the computed tomography (CT) of the patient showed consolidation, ground-glass opacity, and mucoid impaction in the right upper lung; B: Grocott's staining of the mucoid impaction tissue showed septate fungal hyphae, and *Aspergillus fumigatus* was confirmed by culture; C and D: Chest CT during the third recurrence of allergic bronchopulmonary aspergillosis showing mucoid impaction in the upper lobe of the right lung and lower lobe of the left lung; E and F: The CT findings in C and D disappeared 1 mo after dupilumab administration.

exacerbation, we treated the patient with dupilumab (300 mg/2-wk) in addition to oral glucocorticoid (0.5 mg/kg/d) and itraconazole (100 mg/d).

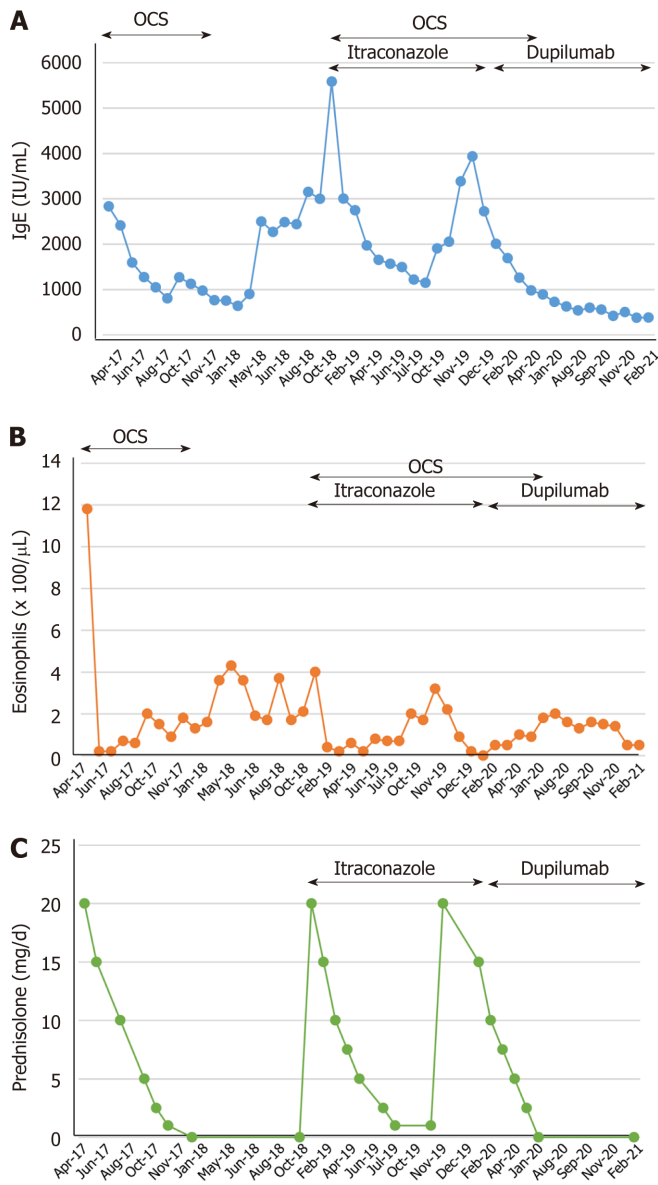
## OUTCOME AND FOLLOW-UP

The mucoid impaction detected by the chest CT scan disappeared after the combined therapy of dupilumab and oral glucocorticoid (Figure 1E and F). We then continued treating the patient with dupilumab, but discontinued the administration of oral glucocorticoid in June 2020. Despite discontinuing her treatment with oral glucocorticoids, inhaled glucocorticoids, and a long-acting beta-2 agonist inhalation for 4 mo after starting therapy with dupilumab, she had no symptoms of bronchial asthma exacerbation or mucoid impaction by chest CT scan.

## DISCUSSION

The pathogenesis of ABPA is not completely clear. Deficient fungal clearance from the airways and excessive activation of CD4+ T helper 2 (Th2) cells play important roles [1]. A predominant activation of Th2 cells in ABPA leads to increased inflammatory cytokines, including IL-4, IL-5, IL-13, CCL-17, and IL-9[6]. Failure to eradicate the fungus leads to a sustained immune response in the airways of patients with ABPA [7]. This excessive immune response induces an inflammatory response characterized by elevated serum levels of IgE, increased mast cell degranulation, enhanced activation of eosinophils and neutrophils that ultimately causes mucoid impaction,





**Figure 2 Laboratory data and dose of oral prednisolone.** Changes in the serum total immunoglobulin E (IgE) levels, peripheral blood eosinophil count and dose of oral corticosteroids (OCS).

eosinophilic pneumonia, or bronchiectasis[8].

The therapeutic efficacy of monoclonal antibodies against Th2 mediators including IgE (omalizumab), IL-5 (mepolizumab), IL-5R (benralizumab), and anti-IL-4/IL-13 (dupilumab) has been reported in patients with ABPA[2-4]. The administration of dupilumab decreases the peripheral blood count of eosinophils and the serum levels of IgE in patients with severe bronchial asthma[9]. Several reports have also demonstrated the efficacy of dupilumab in ABPA (Table 1)[5,9-11]. For example, Mümmeler *et al*[5] reported a case of bronchial asthma associated with ABPA in which the administration of omalizumab or dupilumab reduced the dose of oral glucocorticoids. Also, Mikura *et al*[9] and Ramonell *et al*[10] reported cases of ABPA in which the administration of dupilumab, but not that of mepolizumab and benralizumab suppress eosinophil activation, but they are unable to inhibit IgE pro-inflammatory activity. However, dupilumab inhibits the upstream of the Th2-mediated immune response, and thus it is effective in ABPA patients with elevated serum total IgE. Omalizumab is also effective in ABPA, but its indication is restricted to cases showing serum IgE levels less than 1500 IU/mL[1,3]. These observations support the therapeutic efficacy and the oral glucocorticoid-sparing effect of monoclonal antibodies against Th2 mediators in ABPA patients. Unlike previous cases in the present study, we report the first case of ABPA in which the therapy with dupilumab was so effective that oral glucocorticoids,

**Table 1** Reported cases of allergic bronchopulmonary aspergillosis treated with dupilumab

Ref.	Age, yr	Sex	Timing of dupilumab therapy	Treatment in combination with dupilumab	Baseline IgE (IU/mL)	Baseline eosinophil count ( $\mu\text{L}$ )	Chest CT findings
Ramonell <i>et al</i> [10], 2020	60	Female	Disease recurrence	OCS	561	90	Cylindrical bronchiectasis
Ramonell <i>et al</i> [10], 2020	51	Female	Disease recurrence	OCS	> 2000	90	Bilateral central bronchiectasis
Ramonell <i>et al</i> [10], 2020	33	Male	Disease diagnosis	Voriconazole	11290	1750	Mild diffuse bronchiectasis
Mümmeler <i>et al</i> [5], 2020	49	Female	Disease recurrence	OCS	7000	950	Pulmonary infiltrates, diffuse pulmonary bronchiectasis and bronchial wall thickening
Tashiro <i>et al</i> [11], 2021	72	Female	Disease diagnosis	None	2525	5637	Centrilobular nodules, infiltrations, and high-attenuation mucus in the bronchi with central dilatation
Mikura <i>et al</i> [9], 2021	45	Male	Disease recurrence	OCS, itraconazole	2306	1914	High-attenuation mucus and ground glass opacity
Present case	54	Female	Disease recurrence	OCS, itraconazole	2833	1180	Consolidation, ground-glass opacity, and high-attenuation mucus

IgE: Immunoglobulin E; CT: Computed tomography; OCS: Oral corticosteroids.

inhaled glucocorticoids, and long-acting beta-2 agonists became completely unnecessary to control recurrence of clinical exacerbations and improve radiological abnormalities in bronchial asthma. Phase III clinical trials should be undertaken in the future to confirm these beneficial effects of dupilumab in ABPA patients.

## CONCLUSION

This is the first report of a case of ABPA in which reduction in the dose and, subsequently, complete withdrawal of glucocorticoids was possible after treatment with dupilumab.

## REFERENCES

- 1 Agarwal R, Sehgal IS, Dhooria S, Muthu V, Prasad KT, Bal A, Aggarwal AN, Chakrabarti A. Allergic bronchopulmonary aspergillosis. *Indian J Med Res* 2020; **151**: 529-549 [PMID: 32719226 DOI: 10.4103/ijmr.IJMR\_1187\_19]
- 2 Altman MC, Lenington J, Bronson S, Ayars AG. Combination omalizumab and mepolizumab therapy for refractory allergic bronchopulmonary aspergillosis. *J Allergy Clin Immunol Pract* 2017; **5**: 1137-1139 [PMID: 28279664 DOI: 10.1016/j.jaip.2017.01.013]
- 3 Li JX, Fan LC, Li MH, Cao WJ, Xu JF. Beneficial effects of Omalizumab therapy in allergic bronchopulmonary aspergillosis: A synthesis review of published literature. *Respir Med* 2017; **122**: 33-42 [PMID: 27993289 DOI: 10.1016/j.rmed.2016.11.019]
- 4 Soeda S, Kono Y, Tsuzuki R, Yamawaki S, Katsube O, To M, To Y. Allergic bronchopulmonary aspergillosis successfully treated with benralizumab. *J Allergy Clin Immunol Pract* 2019; **7**: 1633-1635 [PMID: 30513359 DOI: 10.1016/j.jaip.2018.11.024]
- 5 Mümmeler C, Kemmerich B, Behr J, Kneidinger N, Milger K. Differential response to biologics in a patient with severe asthma and ABPA: a role for dupilumab? *Allergy Asthma Clin Immunol* 2020; **16**: 55 [PMID: 32944023 DOI: 10.1186/s13223-020-00454-w]
- 6 Schuyler M. The Th1/Th2 paradigm in allergic bronchopulmonary aspergillosis. *J Lab Clin Med* 1998; **131**: 194-196 [PMID: 9523841 DOI: 10.1016/s0022-2143(98)90089-0]
- 7 Romani L. Immunity to fungal infections. *Nat Rev Immunol* 2011; **11**: 275-288 [PMID: 21394104 DOI: 10.1038/nri2939]
- 8 Knutsen AP, Slavin RG. Allergic bronchopulmonary aspergillosis in asthma and cystic fibrosis. *Clin Dev Immunol* 2011; **2011**: 843763 [PMID: 21603163 DOI: 10.1155/2011/843763]
- 9 Mikura S, Saraya T, Yoshida Y, Oda M, Ishida M, Honda K, Nakamoto K, Tamura M, Takata S, Shimoyamada H, Fujiwara M, Ishii H. Successful Treatment of Mepolizumab- and Prednisolone-

- resistant Allergic Bronchopulmonary Aspergillosis with Dupilumab. *Intern Med* 2021 [PMID: 33642487 DOI: 10.2169/internalmedicine.6679-20]
- 10 **Ramonell RP**, Lee FE, Swenson C, Kuruville M. Dupilumab treatment for allergic bronchopulmonary aspergillosis: A case series. *J Allergy Clin Immunol Pract* 2020; **8**: 742-743 [PMID: 31811944 DOI: 10.1016/j.jaip.2019.11.031]
  - 11 **Tashiro H**, Takahashi K, Kurihara Y, Sadamatsu H, Kimura S, Sueoka-Aragane N. Efficacy of dupilumab and biomarkers for systemic corticosteroid naïve allergic bronchopulmonary mycosis. *Allergol Int* 2021; **70**: 145-147 [PMID: 32917523 DOI: 10.1016/j.alit.2020.08.006]



Published by **Baishideng Publishing Group Inc**  
7041 Koll Center Parkway, Suite 160, Pleasanton, CA 94566, USA  
**Telephone:** +1-925-3991568  
**E-mail:** [bpgoffice@wjgnet.com](mailto:bpgoffice@wjgnet.com)  
**Help Desk:** <https://www.f6publishing.com/helpdesk>  
<https://www.wjgnet.com>

