


When the balloon goes up, blood transfusion goes down: a pilot study of REBOA in placenta accreta spectrum disorders

Yevgeniya J M Ioffe ,¹ Sigrid Burruss,² Ruofan Yao,³ Beverly Tse,⁴ Alicia Cryer,⁴ Kaushik Mukherjee,^{2,5} Linda J Hong¹

► Additional supplemental material is published online only. To view, please visit the journal online (<http://dx.doi.org/10.1136/tsaco-2021-000750>).

¹Gynecology and Obstetrics, Division of Gynecologic Oncology, Loma Linda University School of Medicine, Loma Linda, California, USA

²Department of Surgery, Divisions of Acute Care Surgery and Critical Care, Loma Linda University Medical Center, Loma Linda, California, USA

³Gynecology and Obstetrics, Division of Maternal Fetal Medicine, Loma Linda University School of Medicine, Loma Linda, California, USA

⁴Gynecology and Obstetrics, Loma Linda University Medical Center, Loma Linda, California, USA

⁵Loma Linda University Medical Center

Correspondence to

Dr Yevgeniya J M Ioffe; yjioffe@gmail.com

Received 24 March 2021

Accepted 26 July 2021

© Author(s) (or their employer(s)) 2021. Re-use permitted under CC BY-NC. No commercial re-use. See rights and permissions. Published by BMJ.

To cite: Ioffe YJM, Burruss S, Yao R, *et al.* *Trauma Surg Acute Care Open* 2021;**6**:e000750.

ABSTRACT

Background Patients with placenta accreta spectrum (PAS) disorders often suffer massive hemorrhage during cesarean hysterectomies (CHyst). A novel strategy to decrease blood loss and minimize perioperative morbidity associated with PAS is utilization of ER-REBOA Catheter intraoperatively. In this study, we explore the use of ER-REBOA Catheter during CHyst with the goal of minimizing perioperative morbidity and packed red blood cell (PRBC) transfusions.

Methods We conducted a retrospective case–control study at a regional referral center of consecutive patients with PAS undergoing CHyst. The primary outcomes were PRBC transfusions of ≥ 4 units. Secondary outcomes included surgical intensive care unit admissions, postoperative length of stay (LOS), postoperative ileus, and vascular complication rate. We also explored utilization of manual palpation and omission of precesarean fluoroscopy for resuscitative endovascular balloon occlusion of the aorta (REBOA) placement verification in distal aortic zone 3.

Results 90 patients were included in the study. REBOA and non-REBOA cases were similar in clinicodemographic characteristics. 17.7% of REBOA cases received ≥ 4 units of PRBC compared with 49.3% of non-REBOA cases ($p=0.03$). Zero REBOA patients developed postoperative ileus, whereas 18 (25%) non-REBOA patients did ($p=0.02$). LOS was reduced in the REBOA group. Postplacement fluoroscopy was omitted in all REBOA cases. Two postoperative arterial thrombotic events (2 of 19, 11% of REBOA patients) were identified in the REBOA group, one requiring a thrombectomy (1 of 19, 5%).

Discussion Decrease in blood transfusions of ≥ 4 units of PRBC is demonstrated when ER-REBOA Catheter is placed in distal aortic zone 3 during CHyst performed for severe PAS disorders. The incidence of postoperative ileus and LOS are reduced in the ER-REBOA Catheter group. Placement and utilization of ER-REBOA Catheter during CHyst may be feasible without fluoroscopy when manual placement verification is performed by an experienced operator. Protocol modifications focusing on reducing thrombotic rate are ongoing.

Level of evidence IV.

INTRODUCTION

Postpartum hemorrhage is the leading cause of pregnancy-related death in the USA.¹ Placenta accreta and its more severe variants occur in 1 of every 272 pregnancies² and are a major cause

of massive peripartum hemorrhage, accounting for 46% of cesarean hysterectomies (CHyst) performed.³ Placenta accreta spectrum (PAS) disorder is further subclassified into placenta accreta, increta, and percreta, based on the extent of myometrial and extrauterine pelvic invasion. With PAS, the absence of the decidua basalis layer inhibits the typical separation of the placental unit from the uterus, after delivery of the fetus. This, in turn, leads to significant maternal morbidity, including increased blood loss, hemorrhage, and need for blood transfusions. Placenta accreta cases involve abnormal attachment of the placental villi into but limited to the myometrial layer, with placenta increta cases exhibiting deep myometrial invasion. Placenta percreta cases exhibit placental villi penetrating through the myometrium to the serosa of the uterus and beyond (figure 1).

Prior studies have demonstrated that in patients undergoing CHyst due to PAS disorder, 90% required blood transfusion, with over 40% requiring massive blood transfusion. Massive transfusion was defined as more than 10 units packed red blood cells (PRBCs) administered intraoperatively, as per Wright *et al.*^{4–6} Different methods, including aortic occlusive balloon use and clamping, have been used in an attempt to decrease blood loss.^{7–9} Resuscitative endovascular balloon occlusion of the aorta (REBOA) is one such mechanism for achieving temporary aortic occlusion. REBOA was originally used in the military, with now improved technology and expanded use in the civilian trauma population.^{10–11} The ER-REBOA Catheter was approved by the Food and Drug Administration in 2015 for temporary occlusion of large vessels in patients requiring emergency control of hemorrhage as an alternative to open aortic occlusion.^{12–13} This minimally invasive procedure involves placement of an endovascular balloon through a French femoral arterial line into the abdominal aorta, offering an alternative to abdominal aortic clamping. Temporary occlusion of the abdominal aorta is achieved, allowing for proximal vascular control while still providing cardiac and cerebral perfusion. Furthermore, for the purposes of pelvic bleeding control, the balloon can be positioned in the distal portion of aortic zone 3, ideally between the aortic bifurcation and the inferior mesenteric artery^{14–15} (figure 2).

The use of REBOA has expanded from trauma to emergency surgery with non-traumatic intra-abdominal hemorrhage.^{16–17} More recently, there

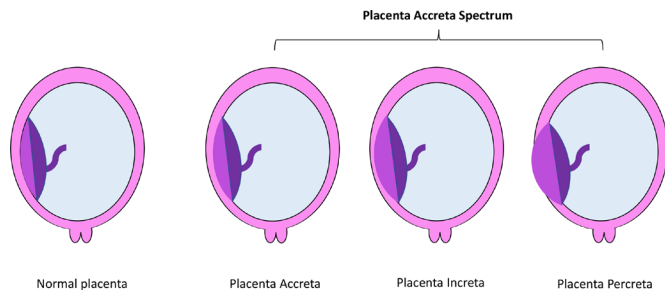


Figure 1 Normal placental implantation versus placental implantation in placental accreta spectrum disorders.

has been an interest in the use of the REBOA procedure for obstetrical patients, given the risk of significant hemorrhage with complicated deliveries, namely CHyst deliveries. Given the novelty of this procedure in the obstetrical population, there is limited literature regarding the use of this modality with CHyst performed for PAS disorders, especially in the US population. The use of REBOA in patients with PAS disorder is mainly limited to case series and systematic reviews of the available literature. The reported data combine both prophylactic and emergent placements of REBOA, with reported studies conducted outside the USA.^{18–21}

Ordoñez *et al*²¹ reported on the experience at a Colombian level I trauma center which prophylactically used REBOA in 12 women undergoing an elective cesarean section for morbid placentation with a median estimated blood loss (EBL) of 1500mL. The authors found the use of REBOA decreased intraoperative blood loss and the number of PRBCs transfused, without REBOA-associated complications. Manzano-Nunez and colleagues²⁰ performed a systematic review of the

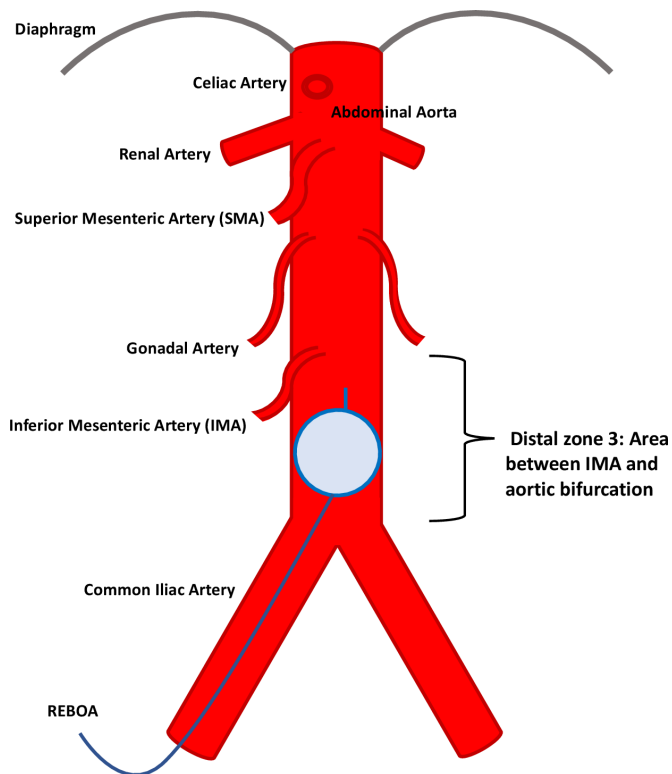


Figure 2 Abdominal aorta with REBOA balloon deployed in the distal portion of aortic zone 3. REBOA, resuscitative endovascular balloon occlusion of the aorta.

use of REBOA in morbidly adherent placental cases and found REBOA decreased the amount of blood loss with a low complication rate. The use of aortic occlusive procedures, however, has raised concern due to the associated complications of pseudoaneurysm and distal embolic events with the potential for limb ischemia requiring additional interventions.¹² A recent study by Whittington *et al*²² appears to be first in describing a US series with the use of REBOA both prophylactically and emergently in a population of patients with PAS disorder. There were no vascular complications in the study patients who underwent REBOA placement in a prophylactic setting, with three of four surviving emergent placement patients experiencing vascular complications.

The available literature has established that the use of REBOA is feasible during CHyst and is associated with decreased blood loss. In the current investigation, we studied several relatively unexplored concepts pertaining to prophylactic REBOA utilization in a population of patients with PAS disorder. We measured whether decrease in PRBC transfusion requirements is preserved when REBOA is placed in distal aortic zone 3; we assessed the feasibility of avoiding fluoroscopy use for REBOA placement confirmation in distal zone 3 with utilization of manual palpation instead. We also examined differences in postoperative length of stay (LOS), onset of postoperative ileus, and admission to surgical intensive care unit (SICU) between REBOA and non-REBOA groups, all points yet to be defined in the literature.

METHODS

This was a single-center retrospective cohort study of consecutive patients with prenatal diagnosis of PAS disorder between January 2013 and October 2020. The study took place at a regional referral center at Loma Linda University Medical Center in California, USA. Patients were excluded if they were suspected of having PAS disorder prenatally but did not deliver at our center or the final pathology did not show evidence of PAS disorder. Before 2013, electronic medical records were not available at our center and therefore difficult to obtain and ascertain for accuracy.

The primary outcome of this retrospective cohort study was necessity for ≥ 4 units of PRBC transfusions. After 4 units of PRBCs are given, the surgery is declared a massive hemorrhage case and the institutional massive transfusion protocol is initiated. Our secondary outcomes included necessity for SICU stay, and overall postoperative LOS, presence of postoperative ileus, and vascular complication rate. Third, we omitted precesarean fluoroscopy for REBOA placement verification with substitution of manual placement guidance by palpation and real-time feedback to the acute care surgeon (ACS) team. REBOA was placed in distal zone 3 of the aorta to avoid hypoperfusion of the intestinal and ovarian circulation while preserving hypoperfusion to the pelvic circulation. Manual palpation was used to tailor balloon occlusion of the distal abdominal aorta and iliac circulation with prevention of balloon overinflation.

REBOA has been used at our institution since 2019 in planned CHysts for severe cases of PAS, including placenta increta and percreta, in which the predicted risk of hemorrhage was high. Please see online supplemental appendix 1 for a description of our institutional protocol of management of PAS used uniformly in this study. All REBOA procedures were performed by the ACS with credentialing via the Basic Endovascular Skills in Trauma course administered through the American College of Surgeons Committee on Trauma. Patients who were deemed to be of high hemorrhage risk were identified by the maternal fetal medicine

specialist using ultrasonography and in some cases MRI. Once identified, the patients were referred to the ACS team and consented preoperatively for the REBOA procedure. Intraoperatively, the femoral artery was accessed using ultrasound and a micropuncture kit. This was upsized to a 7 French arterial sheath with an ongoing heparinized saline infusion. The ER-REBOA Catheter (Prytime Medical, TX) distance was estimated via external measurement from the groin to the xyphoid for zone 3 placement (online supplemental appendix 2). The obstetrics team then proceeded with the cesarean delivery. The REBOA catheter threading and REBOA balloon inflation did not take place until cesarean delivery was complete and the hysterectomy commenced (please see below for further details). The femoral arterial line was placed preoperatively.

The hysterectomy portion of the surgery was led by one of five gynecologic oncologists. After ligation of the upper pedicles including the bilateral round ligaments, the mesosalpinx, and the utero-ovarian ligaments, the REBOA was advanced through the 7 French sheath and inflated with manual palpation to verify placement in distal zone 3 of the abdominal aorta. Aortic bifurcation was localized and the tip of the catheter was palpated. The balloon was to be inflated just above the aortic bifurcation (approximately 2 cm), that is, in the distal portion of zone 3. The iliac arteries were palpated preplacement and postplacement to ensure avoidance of placement in zone 4. Kidneys were palpated and the gonads were traced also to ensure placement accuracy below zone 2. The catheter was then sutured to the skin. The balloon of the REBOA was inflated and perfusion occlusion was verified by the gynecologic oncologist. Centimeter distance and number of milliliters used for occlusion were recorded. We aimed for incomplete occlusion, and the balloon could be further occluded if ongoing hemorrhage was noted in the operative field and balloon volume decreased for a partial occlusion if blood loss was minimal. The maximum balloon inflation time was 45 minutes. At the end of REBOA use, the arterial sheath was removed and pressure held at puncture site for 30 minutes. Patients were admitted with vascular checks every hour for the first 24 hours in the specialized obstetrical care unit. Every patient received an ultrasound of the femoral vessels approximately 24 hours postoperatively.

The medical records of patients who did and did not undergo REBOA placement were reviewed and data were abstracted demographic information (maternal age, parity, body mass index (BMI), number of previous cesarean deliveries, presence of placenta previa), subtype of PAS disorder, surgical outcomes such as EBL, PRBC transfusion and number of total units, total hospital LOS, reoperation, and other surgical complications including presence of postoperative ileus. Postoperative ileus was defined as presence of multiple episodes of nausea/emesis, along with abdominal distension and hypoactive bowel sounds more than 24 hours postoperatively, and if available radiographic data. Surgical complications of interest were postoperative ileus and bowel obstruction, and development of venous and arterial thrombosis, including interventions required for thrombosis management.

Basic demographic information was compared between REBOA cases and non-REBOA cases. Continuous variables were assessed for normal distribution. Normally distributed variables were compared using t-test, otherwise the Wilcoxon rank-sum test was used. Categorical variables were compared using the Fisher's exact test. The number of units of PRBCs transfused, LOS, and SICU admissions were compared between REBOA and non-REBOA cases using the Wilcoxon rank-sum test. Additionally, EBL was compared and PRBCs transfused was categorized

Table 1 Demographics of patients with PAS disorder who underwent cesarean hysterectomy with or without REBOA placement

(N=90)	REBOA (n=17)	No REBOA (n=73)	P value
Maternal age (years)	32.2±5.4	32.0±5.4	0.93
Gestational age (weeks)	34 (32–35)	34 (33–35)	0.28
Parity	3 (2–3)	3 (2–4)	0.53
BMI (kg/m ²)	32.8±6.4	33.3±9.0	0.83
Number of CD	3 (2–3)	2 (2–3)	0.78
Known PAS disorder	17 (100)	70 (95.9)	1
Increta/percreta	15 (88.2)	57 (78.1)	0.51
Presence of previa	12 (70.6)	65 (89)	0.07
Bleeding before surgery	4 (23.5)	17 (23.3)	1
Surgery on planned date	13 (76.5)	47 (64.4)	0.41

Data are mean±SD, n (%), or median (IQR).

BMI, body mass index; CD, cesarean delivery; PAS, placenta accreta spectrum; REBOA, resuscitative endovascular balloon occlusion of the aorta.

as ≥4 units or <4 units, according to the massive transfusion requirement cut-off. These categorical variables along with ICU admission were then compared between the two groups using Fisher's exact test. Based on the analyzed results from comparing demographic and clinical information, further regression analysis to adjust for confounding variables were deemed not necessary. All analyses were performed using Stata V.14 (College Station, TX).

RESULTS

Between January 2013 and October 2020 there were 90 patients diagnosed with PAS and delivered at our institution. Seventeen (19%) patients underwent prophylactic REBOA during surgery. In two patients (11%), the REBOA was not able to be placed successfully and the procedure was aborted. The majority of REBOAs (53%) were placed by the same surgeon. All historic control CHysts and CHysts with REBOA placement were performed by the same group of five gynecologic oncologists. All CHysts involving REBOA placement were performed by the same two gynecologic oncologists (LJH and YJMI).

All cases undergoing REBOA placement were performed in 2019 and 2020 and done in an elective manner. REBOA was used in 49% of PAS cases delivered at our institution since utilization of REBOA for CHyst starting in 2019. REBOA was not used in 51% of cases due to lower risk of PAS (refer to online supplemental appendix 1 for details) or lack of availability of the ACS team or emergent presentation not allowing time for consent and placement.

REBOA and non-REBOA cases were similar in maternal age, gestational age at delivery, parity, number of prior cesarean deliveries, BMI, PAS severity, presence of previa, and bleeding before delivery (table 1).

The median unit of PRBCs transfused in REBOA cases was 1 (IQR: 0–2) compared with 3 (IQR: 1–6) in non-REBOA cases (p=0.01). Of the REBOA cases, 17.7% received ≥4 units of PRBC compared with 49.3% in non-REBOA cases (p=0.03). The median estimated EBL in REBOA cases was 1450 mL (IQR: 800–2000 mL) compared with 1800 mL (IQR: 1100–3000 mL) in non-REBOA cases (p=0.11).

LOS was lower in the REBOA group compared with the non-REBOA group (median 4 (IQR: 3–4) vs. median 4 (IQR: 4–5), p=0.03). There were no differences in postoperative SICU admissions and stay. None of the patients who underwent

Table 2 Comparison of perioperative outcomes of patients with PAS disorder with or without REBOA placement during cesarean hysterectomy

(N=90)	REBOA (n=17)	No REBOA (n=73)	P value
EBL (in mL)	1450 (750–2000)	1800 (1100–3000)	0.11
EBL >1500 mL	8 (47.1)	53 (72.6)	0.08
Number of PRBCs transfused	1 (0–2)	3 (1–6)	0.01
PRBC transfusions \geq 4 units	4 (17.7)	36 (49.3)	0.03
ICU admission	2 (11.8)	14 (19.2)	0.73
Postoperative LOS	4 (3–4)	4 (4–5)	0.03
Postoperative ileus	0 (0)	18 (24.7)	0.02
Bladder injury	2 (11.8)	16 (21.9)	0.51

Data are mean \pm SD, n (%), or median (IQR).

EBL, estimated blood loss; ICU, intensive care unit; LOS, length of stay; PAS, placenta accreta spectrum; PRBC, packed red blood cells; REBOA, resuscitative endovascular balloon occlusion of the aorta.

REBOA placements developed postoperative ileus, whereas 18 (25%) of non-REBOA cases did ($p=0.02$) (table 2).

There were no mortalities in any of the patients in this review. None of the patients in the REBOA group experienced loss of ovarian function or mesenteric ischemia leading to colonic compromise. Balloon occlusion times ranged from 13 to 52 minutes, with a median of 40 minutes. Occlusion volume used for REBOA balloon occlusion ranged from 3 mL to 10 mL, with a median of 3.75 mL.

Two postoperative arterial thrombotic events were identified (2 of 19, 11%). For the purpose of this article, the two patients will be identified as patient 1 and patient 2. Both patient 1 and patient 2 had normal dorsalis pedis/posterior tibialis pulses on leaving the operating room. In patient 1, as in all patients in the REBOA cohort, a routine duplex ultrasound was obtained on postoperative day 1. A small intraluminal linear structure was noted from the mid-left femoral artery to the anterior tibial artery on this ultrasound. CT angiogram was performed and showed a small thrombus involving the left superficial femoral, popliteal, and anterior tibial artery. The patient received 3 months of anti-coagulation with negative follow-up duplex ultrasound. Patient 2, on postoperative day 2, was noted to have weak right pedal pulses and duplex ultrasound indicated occlusion of the right external iliac artery. She was taken to the operating room where adventitial hematoma with thrombus was located just distal to the access site just beneath the inguinal ligament in the common femoral artery to the distal external iliac artery. She underwent a right iliofemoral and femoropopliteal thromboemblectomy with palpable dorsalis pedis and posterior tibial pulses at the conclusion of the case. She did well after surgery with no vascular compromise and negative follow-up duplex ultrasound.

DISCUSSION

The findings of the current study report a decrease in transfusion requirement of \geq 4 units of PRBCs during CHysts performed for severe PAS disorders with prophylactic utilization of ER-REBOA Catheter. In addition, this study found a modest but significant decrease in patients' LOS and significantly decreased incidence of postoperative ileus in patients who underwent prophylactic REBOA placement. Manual palpation for REBOA balloon placement verification was used in our study without evidence of error in placement.

The placement verification protocol used in our study was carefully developed to avoid the use of fluoroscopy in pregnant women. Previously, fluoroscopy-free placement during postpartum hemorrhage has been described by Stensaeth and colleagues,²³ as well as in trauma surgery literature while relying on surface landmarks as guidance for placement.²⁴ An experienced gynecologic oncologist can use their knowledge of pelvic/lower abdominal anatomy garnered from advanced surgical training to guide balloon inflation in distal aortic zone 3 in partnership with ACS team members. Our study illustrated that REBOA can also be placed distally in aortic zone 3 without compromising the decrease in PRBC requirement and avoiding occlusion of circulation to vital abdominopelvic organs. Although thrombotic complications were noted, we do not think those were due to errors in balloon palpation. REBOA balloons were localized in distal zone 3 intraoperatively manually and iliac arteries were carefully checked preballoon and postballoon inflation to rule out erroneous placement.

As described above, verification of appropriate REBOA position and vascular occlusion can be accomplished after delivery of the fetus. This technique minimized the possible toxicity associated with fluoroscopy to the fetus and the mother, and reduced a procedural step (fluoroscopy) that delays life-saving procedure and decreases overall operating room time. The risks of intraoperative fluoroscopy would include exposure of the unborn fetus to radiation, which carries unknown and disputed risks and creates anxiety for the mother and the treatment team. In addition, time to delivery of the fetus is extended, which can lead to complications, such as terminal bradycardia. If left unrecognized, terminal bradycardia can lead to hypoxia and can have dire fetal consequences. In summary, there were no identifiable complications associated specifically with verification by palpation in our study, arguing that fluoroscopic confirmation of REBOA placement can be omitted from the protocol as previously illustrated in the literature as well.^{23 24}

Another advantage of manual verification of placement of the REBOA balloon deployment and inflation postdelivery was the ability to individually tailor the position of the balloon. If anatomy is anomalous, the surgeon can assist the ACS team in guiding the catheter placement and avoidance of injury and degree of aortic occlusion based on blood loss in the operative field. In our study, the median occlusive volume was 3.75 mL as compared with a median of 10 mL recently reported in the literature.²⁵

A recent US study by Whittington *et al* reported no vascular injuries in the prophylactic group. Three of four patients undergoing emergent REBOA placement experienced vascular complications. One patient described in this cohort required an iliofemoral bypass after undergoing emergent REBOA placement due to balloon rupture.²² It can be deduced that emergent REBOA placement itself may be a confounder for increased vascular complication rate. The coagulation cascade may be highly active at the point of emergent REBOA placement and contribute to high thrombotic formation rate. This is in particular applicable to the pregnant, and thus hypercoagulable, patient population. In our study REBOA placements were elective, but the rate of thrombosis was not analyzed with respect to its relation to EBL/blood transfusions. The sample size did not allow for a meaningful analysis in that respect.

In our study, no balloon ruptures causing damage to the great vessels occurred. The details of thrombotic complications are outlined in the Results section. In summary, the cause of thrombus for patient 1 was likely that a thrombus from the REBOA insertion site in the femoral artery embolized on withdrawal of the

balloon at the end of the procedure. In patient 2, the thrombus occurred at the arteriotomy site, likely due to trauma with the REBOA insertion.

In response to these two thrombotic events, we have revised our REBOA protocol in collaboration with the ACS team and vascular surgeons. The instituted changes to our protocol are heparinized saline flush of the arterial line, aspiration and discarding of the blood at puncture site, and 50 units/kg heparin bolus with REBOA balloon inflation. Also, after the evaluation of this preliminary data, we plan to drop tranexamic acid administration to avoid further increase in hypercoagulability. The decrease in thrombotic events with this protocol is to be assessed in a prospective trial that is currently underway at our institution.

We would like to highlight that despite inflation of the balloon in the lower portion of aortic zone 3, the benefit of occlusion remains significant. All patients were spared colonic or gonadal compromise with our low balloon placement. Placement below the gonadal vessels and the inferior mesenteric artery minimizes the risk of ischemic events due to poor perfusion of the large bowel and the ovaries. At the same time, with occlusion of the anterior and posterior iliac circulation, a significant decrease in blood loss can be achieved. A further prospective study is, as mentioned above, underway at our institution to verify that the new protocol with heparinization is safe and can avoid vascular thrombosis while minimizing blood loss and radiation exposure and operative time for the unborn fetus and the mother.

Earlier studies reported in the literature examining vascular complication rates, including a large study by Wu *et al*,²⁶ have previously demonstrated that balloon occlusion resulted in marked decrease in blood loss with a low rate of vascular adverse events. Wu *et al* found 0.87% incidence of vein thrombosis of the lower limbs (2 of 230 patients) in those receiving balloon occlusion and 0% in those with no balloon occlusion. The vein thrombosis resolved with conservative treatment with no operative interventions and no maternal or fetal mortality noted in either group. The rate of thrombotic events and necessity for vascular surgical interventions is variable in the literature, with further investigation needed on establishing the rate and safety of the technique. The variability in the rate of thrombosis and overall vascular complications may be due, at least in part, to variations in REBOA placement/utilization protocols. We have revised our protocol as outlined above. Again, we would like to study this in a prospective, randomized fashion to answer the question of best practices for minimizing vascular complications.

Our study also highlights a decrease in ileus and modest decrease in LOS of patients in the REBOA cohort. The significant trend toward lower LOS may be associated with the benefits of decreased fluid overload and intestinal edema due to avoidance of massive transfusions allowing for faster mobilization and return of bowel function. As discussed above, our study did show statistically lower requirement for high-volume PRBC transfusions and decrease in EBL, although the latter finding is more elusive and difficult to quantitate. Our goal was also to compare the rate of SICU admission with utilization of REBOA protocol. Although no significant differences were found, this is a trend toward decrease in SICU admissions ($p=0.08$) that warrants further investigation. A larger randomized investigation will be needed to address this question and further highlight the role of REBOA in patient safety.

Although our study was not randomized, which is an inherent weakness of our study, the REBOA cases were compared with historic cohorts. All the cases were performed at the same institution by the same group of providers, allowing for some

homogeneity of technique. Yet it is also a weakness of our study, the inherent heterogeneity in surgical techniques between the different surgeons, as our CHyst practices evolved over the years with more experience and expertise garnered by the faculty gynecologic oncologists.

This cohort study with historic controls furthers our expertise in obstetrical utilization of ER-REBOA Catheter. Although highlighting the previously shown benefits of decreased EBL and demonstrating decrease in PRBC transfusion of ≥ 4 units, it also highlights the improved outcomes in prophylactic REBOA placement of decreased LOS, postoperative ileus, and avoidance of intraoperative fluoroscopy. This study highlights potential safe avenues for improvement of utilization and further areas of research. If confirmed by data analysis from the ongoing prospective study, the results of our study can be applied broadly; diagnosis of PAS disorders is encountered at most, if not all, medical centers that have labor and delivery units. However, further modifications to the protocol decreasing the odds of thrombotic events in this hypercoagulable cohort are necessary and are currently being investigated.

Acknowledgements We would like to thank Stephanie Han for her assistance with this project.

Contributors YJMI, SB, KM, and LJH were involved in concept design, as well as in the majority of data collection and processing. YJMI, RY, LJH, and KM prepared and edited most of the article, with input from the other authors. AC, SB, and BT were responsible for data collection and data interpretation. RY, YJMI, and LJH led the data analysis.

Funding The authors have not declared a specific grant for this research from any funding agency in the public, commercial or not-for-profit sectors.

Competing interests YJMI – consulting for Tesaro in 2018, consulting for Immunogen in 2018, consulting for AstraZeneca in 2019, consulting for Seagen Inc 2021.

Patient consent for publication Not required.

Ethics approval This was approved for consent exemption by the institutional review board (IRB) (IRB #5190329), "Investigator initiated retrospective analysis of resuscitative Endovascular Balloon Occlusion (REBOA) use in placental disorder to minimize blood loss and other morbidities."

Provenance and peer review Not commissioned; externally peer reviewed.

Data availability statement Data are available upon reasonable request.

Open access This is an open access article distributed in accordance with the Creative Commons Attribution Non Commercial (CC BY-NC 4.0) license, which permits others to distribute, remix, adapt, build upon this work non-commercially, and license their derivative works on different terms, provided the original work is properly cited, appropriate credit is given, any changes made indicated, and the use is non-commercial. See: <http://creativecommons.org/licenses/by-nc/4.0/>.

ORCID iD

Yevgeniya J M Ioffe <http://orcid.org/0000-0003-1531-2894>

REFERENCES

- Chichakli LO, Atrash HK, MacKay AP, Musani AS, Berg CJ. Pregnancy-related mortality in the United States due to hemorrhage: 1979-1992. *Obstet Gynecol* 1999;94:721-5.
- American College of Obstetricians and Gynecologists, Society for Maternal-Fetal Medicine. Obstetric care consensus No. 7: placenta accreta spectrum. *Obstet Gynecol* 2018;132:e259-75.
- Flood KM, Said S, Geary M, Robson M, Fitzpatrick C, Malone FD. Changing trends in Peripartum hysterectomy over the last 4 decades. *Am J Obstet Gynecol* 2009;200:632.e1-632.e6.
- Wright JD, Pri-Paz S, Herzog TJ, Shah M, Bonanno C, Lewin SN, Simpson LL, Gaddipati S, Sun X, D'Alton ME, *et al*. Predictors of massive blood loss in women with placenta accreta. *Am J Obstet Gynecol* 2011;205:38.e1-38.e6.
- Silver RM, Barbour KD. Placenta accreta spectrum: accreta, increta, and percreta. *Obstet Gynecol Clin North Am* 2015;42:381-402.
- Blumenthal E, Rao R, Murphy A, Gornbein J, Hong R, Moriarty JM, Kahn DA, Janzen C. Pilot study of intra-aortic balloon occlusion to limit morbidity in patients with adherent placentation undergoing cesarean hysterectomy. *AJP Rep* 2018;8:e57-63.
- Chou M-M, Ke Y-M, Wu H-C, Tsai C-P, Ho ES-C, Ismail H, Palacios Jaraquemada JM. Temporary cross-clamping of the infrarenal abdominal aorta during cesarean

- hysterectomy to control operative blood loss in placenta previa increta/percreta. *Taiwan J Obstet Gynecol* 2010;49:72–6.
- 8 Harma M, Harma M, Kunt AS, Andac MH, Demir N. Balloon occlusion of the descending aorta in the treatment of severe post-partum haemorrhage. *Aust N Z J Obstet Gynaecol* 2004;44:170–1.
 - 9 Greenberg JJ, Suliman A, Iranpour P, Angle N. Prophylactic balloon occlusion of the internal iliac arteries to treat abnormal placentation: a cautionary case. *Am J Obstet Gynecol* 2007;197:470.e1–470.e4.
 - 10 Hughes CW. Use of an intra-aortic balloon catheter tamponade for controlling intra-abdominal hemorrhage in man. *Surgery* 1954;36:65–8.
 - 11 White JM, Cannon JW, Stannard A, Markov NP, Spencer JR, Rasmussen TE. Endovascular balloon occlusion of the aorta is superior to resuscitative thoracotomy with aortic clamping in a porcine model of hemorrhagic shock. *Surgery* 2011;150:400–9.
 - 12 DuBose JJ, Scalea TM, Brenner M, Skiada D, Inaba K, Cannon J, Moore L, Holcomb J, Turay D, Arbabi CN, et al. The AAST prospective aortic occlusion for resuscitation in trauma and acute care surgery (aorta) registry: data on contemporary utilization and outcomes of aortic occlusion and resuscitative balloon occlusion of the aorta (REBOA). *J Trauma Acute Care Surg* 2016;81:409–19.
 - 13 Food and Drug Administration. ER-REBOA Catheter approval letter. 2017. https://www.accessdata.fda.gov/cdrh_docs/pdf17/K170411.pdf.
 - 14 Stannard A, Eliason JL, Rasmussen TE. Resuscitative endovascular balloon occlusion of the aorta (REBOA) as an adjunct for hemorrhagic shock. *J Trauma* 2011;71:1869–72.
 - 15 Czerny M, Pacini D, Abovans V, Al-Attar N, Eggebrecht H, Evangelista A, Grabenwöger M, Stabile E, Kolowca M, Lescan M, et al. Clinical cases referring to current options and recommendations for the use of thoracic endovascular aortic repair in acute and chronic thoracic aortic disease: an expert consensus document of the European Society for Cardiology (ESC) Working Group of Cardiovascular Surgery, the ESC Working Group on Aorta and Peripheral Vascular Diseases, the European Association of Percutaneous Cardiovascular Interventions (EAPCI) of the ESC and the European Association for Cardio-Thoracic Surgery (EACTS). *Eur J Cardiothorac Surg* 2021;59:74–9.
 - 16 Hoehn MR, Hansraj NZ, Pasley AM, Brenner M, Cox SR, Pasley JD, Diaz JJ, Scalea T. Resuscitative endovascular balloon occlusion of the aorta for non-traumatic intra-abdominal hemorrhage. *Eur J Trauma Emerg Surg* 2019;45:713–8.
 - 17 Martinelli T, Thony F, Decléty P, Sengel C, Broux C, Tonetti J, Payen J-F, Ferretti G. Intra-Aortic balloon occlusion to salvage patients with life-threatening hemorrhagic shocks from pelvic fractures. *J Trauma* 2010;68:942–8.
 - 18 Stubbs MK, Wellbeloved MA, Vally JC. The management of patients with placenta percreta: a case series comparing the use of resuscitative endovascular balloon occlusion of the aorta with aortic cross clamp. *Indian J Anaesth* 2020;64:520–3.
 - 19 Wei X, Zhang J, Chu Q, Du Y, Xing N, Xu X, Zhou Y, Zhang W. Prophylactic abdominal aorta balloon occlusion during caesarean section: a retrospective case series. *Int J Obstet Anesth* 2016;27:3–8.
 - 20 Manzano-Nunez R, Escobar-Vidarte MF, Naranjo MP, Rodriguez F, Ferrada P, Casallas JD, Ordoñez CA. Expanding the field of acute care surgery: a systematic review of the use of resuscitative endovascular balloon occlusion of the aorta (REBOA) in cases of morbidly adherent placenta. *Eur J Trauma Emerg Surg* 2018;44:519–26.
 - 21 Ordoñez CA, Manzano-Nunez R, Parra MW, Rasmussen TE, Nieto AJ, Herrera-Escobar JP, Fernandez P, Naranjo MP, García AF, Carvajal JA, et al. Prophylactic use of resuscitative endovascular balloon occlusion of the aorta in women with abnormal placentation: a systematic review, meta-analysis, and case series. *J Trauma Acute Care Surg* 2018;84:809–18.
 - 22 Whittington JR, Pagan ME, Nevil BD, Kalkwarf KJ, Sharawi NE, Hughes DS, Sandlin AT. Risk of vascular complications in prophylactic compared to emergent resuscitative endovascular balloon occlusion of the aorta (REBOA) in the management of placenta accreta spectrum. *J Matern Fetal Neonatal Med* 2020:1–4.
 - 23 Stensaeth KH, Sovik E, Haig INY, Skomedal E, Jorgensen A. Fluoroscopy-free resuscitative endovascular balloon occlusion of the aorta (REBOA) for controlling life threatening postpartum hemorrhage. *PLoS One* 2017;12:e0174520.
 - 24 Weng D, Qian A, Zhou Q, Xu J, Xu S, Zhang M. A new method using surface landmarks to locate resuscitative endovascular balloon occlusion of the aorta based on a retrospective cta study. *Eur J Trauma Emerg Surg* 2021. [Epub ahead of print: 21 May 2021].
 - 25 Meyer DE, Mont MT, Harvin JA, Kao LS, Wade CE, Moore LJ. Catheter distances and balloon inflation volumes for the ER-REBOA™ catheter: a prospective analysis. *Am J Surg* 2020;219:140–4.
 - 26 Wu Q, Liu Z, Zhao X, Liu C, Wang Y, Chu Q, Wang X, Chen Z. Outcome of pregnancies after balloon occlusion of the infrarenal abdominal aorta during caesarean in 230 patients with placenta praevia accreta. *Cardiovasc Intervent Radiol* 2016;39:1573–9.